

Focused Review

Ultrasound-Guided Interventional Procedures for Patients with Chronic Pelvic Pain — A Description of Techniques and Review of Literature

Philip W.H. Peng, MBBS, FRCPC, and Paul S. Tumber, MD, FRCPC

From: Department of Anesthesia and Pain Management, Toronto Western Hospital, University of Toronto, Toronto, Ontario, Canada.

Dr. Peng is with the Department of Anesthesia and Pain Management, Toronto Western Hospital, University of Toronto, Toronto, Ontario, Canada.

Dr. Tumber is with the Department of Anesthesia and Pain Management, Toronto Western Hospital, University of Toronto, Toronto, Ontario, Canada.

Address correspondence:
Department of Anesthesia and Pain Management
McL 2-405 TWH
399 Bathurst St
Toronto, Ontario
Canada M5T 2S8
E-mail: Philip.peng@uhn.on.ca

Disclaimer: There was no external funding in the preparation of this manuscript.

Conflict of interest: None.

Manuscript received: 12/05/2007

Revised manuscript received:

01/14/2008

Accepted for publication: 01/21/2008

Free full manuscript:
www.painphysicianjournal.com

Chronic pelvic pain can present in various pain syndromes. In particular, interventional procedure plays an important diagnostic and therapeutic role in 3 types of pelvic pain syndromes: pudendal neuralgia, piriformis syndrome, and "border nerve" syndrome (ilioinguinal, iliohypogastric, and genitofemoral nerve neuropathy). The objective of this review is to discuss the ultrasound-guided approach of the interventional procedures commonly used for these 3 specific chronic pelvic pain syndromes.

Piriformis syndrome is an uncommon cause of buttock and leg pain. Some treatment options include the injection of the piriformis muscle with local anesthetic and steroids or the injection of botulinum toxin. Various techniques for piriformis muscle injection have been described. CT scan and EMG-guidance are not widely available to interventional physicians, while fluoroscopy exposes the performers to radiation risk. Ultrasound allows direct visualization and real-time injection of the piriformis muscle.

Chronic neuropathic pain arising from the lesion or dysfunction of the ilioinguinal nerve, iliohypogastric nerve, and genitofemoral nerve can be diagnosed and treated by injection to the involved nerves. However, the existing techniques are confusing and contradictory. Ultrasonography allows visualization of the nerves or the structures important in the identification of the nerves and provides the opportunities for real-time injections.

Pudendal neuralgia commonly presents as chronic debilitating pain in the penis, scrotum, labia, perineum, or anorectal region. A pudendal nerve block is crucial for the diagnosis and treatment of pudendal neuralgia. The pudendal nerve is located between the sacrospinous and sacrotuberous ligaments at the level of ischial spine. Ultrasonography, but not the conventional fluoroscopy, allows visualization of the nerve and the surrounding landmark structures.

Ultrasound-guided techniques offer many advantages over the conventional techniques. The ultrasound machine is portable and is more readily available to the pain specialist. It prevents patients and healthcare professionals from the exposure to radiation during the procedure. Because it allows the visualization of a wide variety of tissues, it potentially improves the accuracy of the needle placement, as exemplified by various interventional procedures in the pelvic regions aforementioned.

Key words: Pudendal nerve, piriformis muscle, ilioinguinal nerve, iliohypogastric nerve, genitofemoral nerve, ultrasound

Pain Physician 2008; 11:215-224

Chronic pelvic pain can be defined as non-cyclic pain that is localized to the anatomic pelvis, anterior abdominal wall at or below the umbilicus, the lumbosacral back, or the buttocks lasting longer than 6 months in duration. It must be of sufficient severity to cause functional disability or lead to medical care (1). Although the prevalence of chronic pelvic pain in both genders of the general population is not fully established, it is estimated that 15–20% of women ages 18–50 years are affected (2). Approximately 8% of visits to the urologist and 1% of primary care physician visits are related to chronic pelvic pain in men (3).

Chronic pelvic pain can present in various pain syndromes (4). In particular, interventional procedures play an important diagnostic and therapeutic role in 3 types of pelvic pain syndromes: pudendal neuralgia, piriformis syndrome, and “border nerve” syndrome (ilioinguinal, iliohypogastric, and genitofemoral nerve neuropathy). In the present review, we describe the role and technique of ultrasound-guided interventional procedures in these particular pain syndromes.

PIRIFORMIS SYNDROME

First introduced by Robinson in 1947 (5), piriformis syndrome is an uncommon and often under-diagnosed cause of buttock and leg pain. Clinical presentation of this syndrome has been well described elsewhere in the literature and will not be detailed here (6,7). The management of piriformis syndrome includes the injection of the piriformis muscle with local anesthetic and steroids (7) or the injection of botulinum toxin (8).

Anatomy

The piriformis muscle originates from the anterior surface of the second, third, and fourth sacral vertebrae and the capsule of the sacrioliac joint. It runs laterally and exits the pelvis through the greater sciatic foramen, becomes tendinous, and inserts into the upper border of the greater trochanter (Fig. 1). The piriformis acts as an external rotator in the erect position and as an abductor in the supine position.

There are 6 possible anatomical relationships between the sciatic nerve and the piriformis muscle. The most common arrangement is found when the undivided nerve passes below the piriformis muscle (78–84%) (9,10). The second most common arrangement is found when the divided nerve passes through and below the muscle (12–21%). The aberrant course of the sciatic nerve through the piriformis muscle can cause

sciatica and may suggest the important role of a nerve stimulator in the injection of piriformis muscle.

Problems with Existing Techniques

In general, the conventional techniques for piriformis muscle injection can be grouped into 2 types: (1) imaging techniques to guide the needle to the proximity of the piriformis muscle, such as CT scan and fluoroscopy; (2) electrophysiological techniques to confirm the activation of the piriformis muscle or sciatic nerve, such as the use of the electromyography (EMG) and nerve stimulation. Quite often, physicians combine both groups of techniques to improve the accuracy of needle placement. For example, both EMG and nerve stimulation have been used in conjunction with fluoroscopy (11). When the nerve stimulator is used, the technique involves inserting a stimulator needle in the greater sciatic notch to elicit gluteal maximum contraction. Upon further advancement of the stimulating needle, marked diminution of gluteal stimulation and a subtle twitch of the needle can be noted (12). The latter is caused by stimulation of the piriformis. Another technique of nerve stimulation is to primarily seek for a sciatic twitch by advancing the nerve stimulator needle 2 cm lateral and 1 cm inferior to the caudal end of sacroiliac joint under fluoroscopic guidance. The needle is then withdrawn until the muscle twitch resulting from the sciatic nerve stimulation disappears (7).

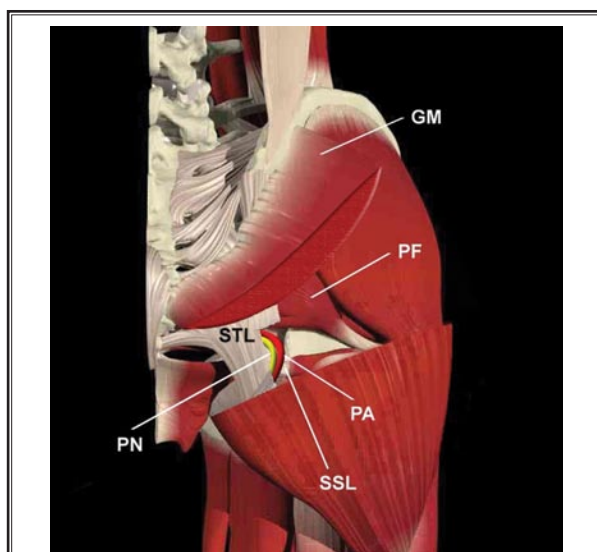


Fig. 1. *Anatomy of pelvic region. Gluteus maximus (GM) was partially removed to expose the piriformis muscle (PF), sacrospinous ligament (SSL), sacrotuberous ligament (STL), pudendal artery and nerve (PA and PN).*

There are many disadvantages of the aforementioned techniques. CT scan and EMG-guidance are not widely available to interventional physicians, while fluoroscopy exposes the performers to radiation risk. Fluoroscopy displays the sciatic notch and sacroiliac joint, but not the piriformis muscle itself. When the needle placement within the piriformis muscle is required such as in the situation of botulinum toxin injection, additional techniques are used to identify the intramuscular location of the needle. However, contrast is used to “outline” the piriformis muscle, confirming the needle placement in the fascia plane around the muscle (Fig. 2). Nerve stimulators can stimulate the muscle when the needle is in contact with or within the muscle itself. Both of these approaches do not offer direct visualization of the muscle and cannot assure the accurate placement of the needle within the piriformis muscle.

Ultrasound-guided Technique for Piriformis Muscle Injection

Ultrasound-guided injection offers a technique with a direct visualization of the piriformis muscle, real-time guidance of needle insertion, and the confirmation of injectate inside or around the piriformis muscle. This procedure is performed without exposing the patient and physician to the risks of radiation. It is also a simple technique to learn.

The ultrasound-guided technique was only reported twice in the literature (13,14). In one article, the description was confusing as it blended ultrasound, fluoroscopy,

nerve stimulation, and contrast injection techniques together, when the piriformis muscle injection can simply be performed with a nerve stimulating needle under ultrasound guidance. The key step for ultrasound-guided injection is to align the ultrasound probe in the longitudinal axis of the piriformis muscle above the ischial spine.

Recommended Technique

During the ultrasound-guided technique, the patient is placed in a prone position. A curvilinear probe with low frequency (2 – 5Hz) is used due to the depth of the structure. After the skin is prepared with Povidone-iodine and a sterile probe placed within a transparent plastic sheath, scanning is performed in the transverse plane with the probe placed over posterior superior iliac spine so that the sacroiliac joint can be seen. The probe is then moved in the lateral direction to follow the ilium, which is visualized as a hyperechoic line running across the scan image from medial to lateral positions. As the probe begins to move caudally, the ischium is seen only in the lateral part of the scan image. The ischium is initially seen as a curved line as it forms the posterior aspect of the acetabulum. When the probe is at the ischial spine level, the ischium will begin to appear as a straight line. This will approximate the lower margin of the piriformis muscle. The probe will then move cephalad slightly. Two layers of muscles, with hypoechoic marbled appearance, will be visualized. The muscle above, which is quite sizable, is the gluteus maximus muscle. A thinner muscle

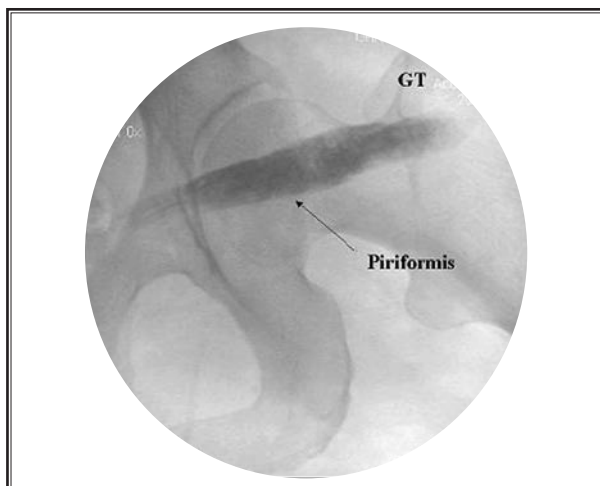


Fig. 2. Use of radio-opaque contrast to outline the piriformis muscle. The contrast was shown to spread along the muscle because the needle tip stays outside the muscle.

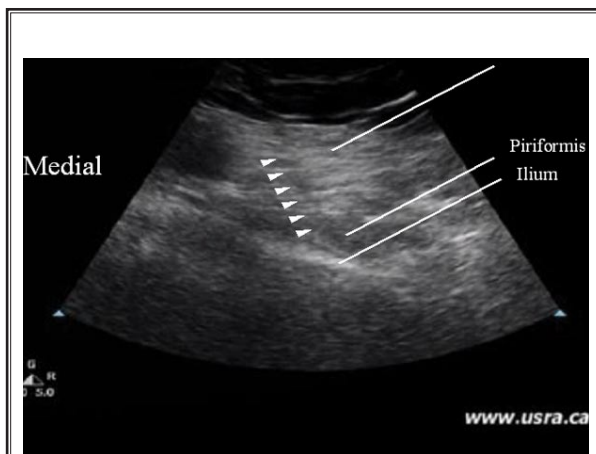


Fig. 3. Figure showing the needle insertion in the piriformis muscle.

underneath the gluteus maximus is the piriformis muscle (Fig. 3). By rotating the hip internally and externally with the knee flexed, the piriformis muscle will be seen gliding underneath the gluteus maximus muscle. The probe will then be moved in a medial to lateral position to trace the piriformis muscle running anterior to the sacrum medially and attaching to the greater trochanter laterally. It is important to scan the ilium to define the ischial spine and thus the lower margin of piriformis, as the 3 muscles forming the tricipital tendons below the ischial spine (obturator internus, superior and inferior gemellus muscle) can mimic the appearance of the piriformis and these muscles also attach to the greater trochanter.

With the probe over the piriformis muscle in the sciatic notch (thicker portion of the belly), a 22-gauge, 12 cm insulated peripheral nerve stimulating needle is inserted from the medial aspect of the probe and advanced in line with the ultrasound probe. The nerve stimulator is set at 1.2 mA. When the needle is in the gluteus maximus muscle, a very profound muscle twitch in the gluteal region is seen. Once the needle is passed through the gluteus muscles, the observable gluteal contraction stops and the needle is advanced further towards the piriformis muscle. When the needle is in contact with the piriformis muscle, muscle contraction is often observed.

For injection into the sheath, a small amount of normal saline (< 0.5mL) is injected, which is collected between the 2 muscle layers (gluteus maximus and piriformis). If intramuscular injection is attempted, the needle should be advanced further to elicit strong muscle contractions. A very small amount of normal saline (<0.5 mL) is injected to confirm the intramuscular location of the needle. It is not uncommon for sciatic nerve stimulation to be observed when the needle is advanced through the piriformis muscle. Because of the anatomical anomalies of the sciatic nerve within and below the piriformis muscle, the nerve stimulator is very useful in preventing inadvertent injection around the sciatic nerve.

BORDER NERVE SYNDROME (ILIOINGUINAL, ILIOHYPOGASTRIC AND GENITOFEMORAL NERVES)

Iliohypogastric, ilioinguinal, and genitofemoral nerves are known as "border nerves" because these nerves supply the skin between the abdomen and thigh (15). Because of the course of the nerve, they

are at risk to injury from the lower abdominal incision (Pfannenstiel incision, appendectomy, inguinal herniorrhaphy) or trocar insertion performed in laparoscopic surgery (16-18). Patients with neuropathy following injury to these nerves will present with groin pain that may extend to the scrotum or testicle in men, the labia majora in women, and the medial aspect of the thigh. Accurate diagnostic block of those nerves is important in understanding the etiology of the clinical problem.

Anatomy

Both the iliohypogastric and ilioinguinal nerves arise from the anterior rami of L1 with contributing filaments from the T12 (Fig. 4). Emerging from the lateral border of the psoas major muscle, both nerves run subperitoneally in front of quadratus lumborum before piercing the transverse abdominis muscle above the iliac crest (19).

The iliohypogastric nerve runs downward and forward in the neurovascular plane and pierces the internal oblique muscle above the anterior superior iliac spine. It gradually pierces and gives motor fibers to the internal oblique muscle. It lies between the internal oblique muscle and the external oblique muscle. The iliohypogastric nerve then pierces the aponeurosis of the external oblique muscle an inch or so above the

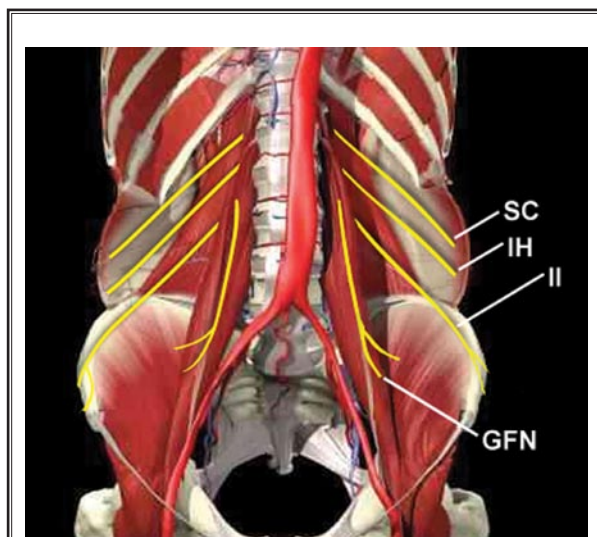


Fig. 4. Genitofemoral nerve, ilioinguinal and iliohypogastric nerves all arise from the lumbar plexus.

SC – subcostal nerve, IH – iliohypogastric nerve, II – ilioinguinal nerve, GFN – genitofemoral nerve.

superficial inguinal ring and provides sensory fibers to the skin over the lower part of the rectus abdominis (the skin of mons).

The ilioinguinal nerve runs parallel and below the iliohypogastric nerve and pierces the lower border of internal oblique muscle. It passes between the crura of the superficial inguinal ring in front of the spermatic cord. It supplies the skin of the superomedial area of the thigh, the skin over the root of the penis and anterior scrotum (the mons pubis and labium majus in the female).

The genitofemoral nerve arises from the first and second lumbar nerve roots. The nerve penetrates the psoas muscle at the level of the L3-4 intervertebral disc and comes to lie on its anterior surface, either as a single trunk or separate genital and femoral branch (Fig. 4) (15). It then divides into a femoral and genital branch at a variable distance above the level of the inguinal ligament.

The femoral branch of the genitofemoral nerve follows the external iliac artery and passes with it under the inguinal ligament. It also penetrates the fascia lata in order to supply skin sensations to the femoral triangle. The genital branch of the genitofemoral nerve passes through the internal inguinal ring of the transversalis fascia and then continues into the inguinal canal. The relationship of the genital branch to the spermatic cord in the inguinal canal is highly variable. It can either run outside the spermatic cord in the ventral (15), dorsal, and inferior locations (20), or incorporate with the cremaster muscle (19).

It is important to note that there are many variations of sensory nerves within the inguinal region, with free communication between the branches of the genitofemoral, ilioinguinal, and iliohypogastric nerves. In one cadaver study, it was shown that the ilioinguinal nerve was solely responsible for cutaneous innervation of the genital branch of genitofemoral nerve in 28% of the dissections and shared innervation with the genital branch of genitofemoral nerve in 8% (15). The site where the ilioinguinal and iliohypogastric nerves penetrate the different layers of abdominal muscle is highly variable (17). The size of the ilioinguinal nerve is inversely proportional to the iliohypogastric nerve. In some patients, the ilioinguinal nerve joins with the iliohypogastric nerve, or one of the nerves is entirely absent.

Problems with Existing Techniques

Because of the variable anatomy between the 3 nerves, it is not surprising that the existing techniques, based on landmarks, are very confusing (Fig. 5). Most techniques requiring injection of the ilioinguinal and iliohypogastric nerves use the anterior superior iliac spine (ASIS) as a landmark. One technique described the needle insertion point as 1 inch medial to the ASIS on a line joining the ASIS and umbilicus. The needle was suggested to “pierce the fascia of oblique muscles” using “fanwise and up-and-down infiltration” (21). Another technique described the landmarks as 3 cm medial and inferior to the ASIS. It suggested the needle insertion to be in the cephalolateral direction until contacting the inner surface of the ilium. The investigator of this technique suggested infiltration of local anesthetic as the needle is withdrawn “through the layers of abdominal wall.” Repeated needle entry at a steeper angle was also suggested to penetrate all

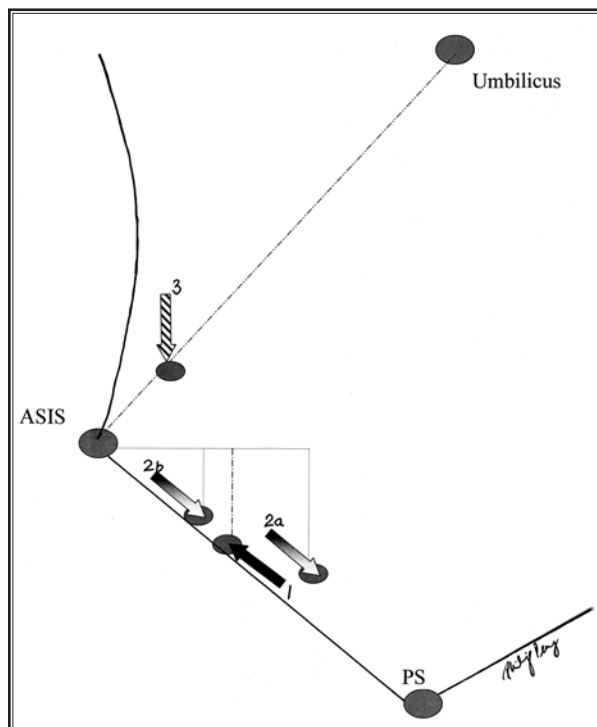


Fig. 5. The 3 methods (4 landmarks) described for ilioinguinal and iliohypogastric nerves injection. Methods 1, 2 and 3 were described by DL Brown (22), SD Waldman (23), and J Katz and JW Brown (21). PS- Pubic symphysis; ASIS-Anterior superior iliac spine.

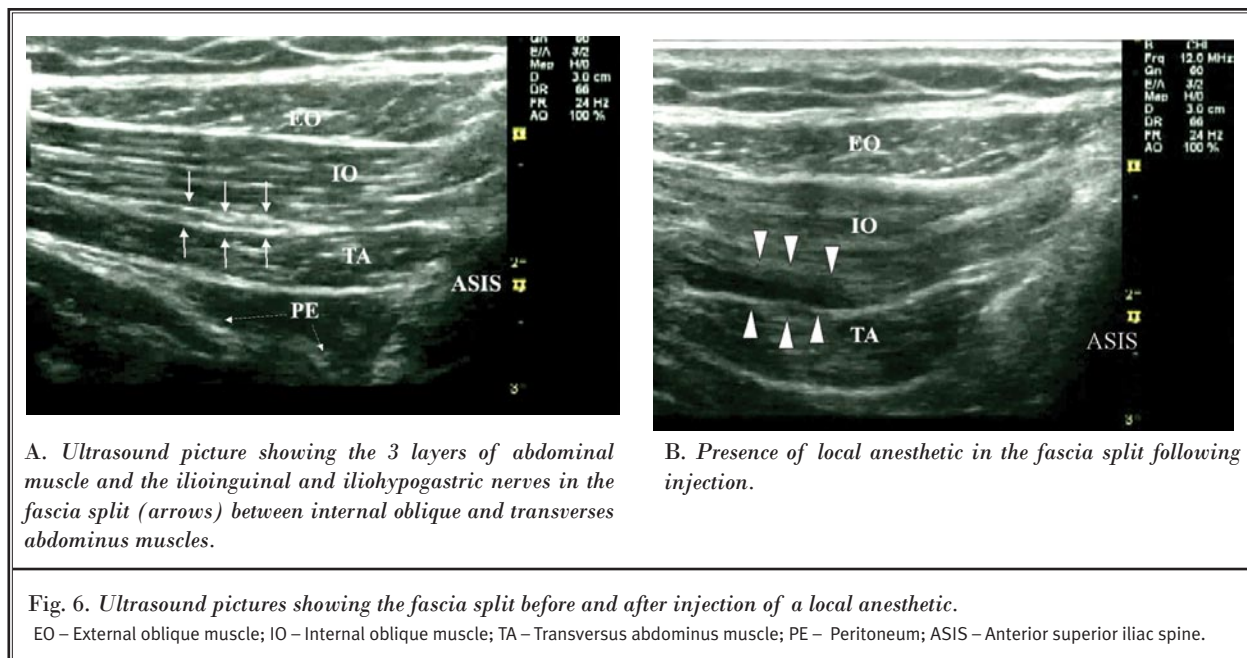
3 layers of abdominal muscles (22). Another investigator, who described separate procedures for Ilioinguinal and Iliohypogastric nerves, suggested a completely different approach. The needle entry point for the Ilioinguinal nerve was 2 inches medial and inferior to the ASIS. The needle was then directed "towards the pubic symphysis in a fan-like manner," piercing through the fascia of the external oblique muscle. The needle entry point for the Iliohypogastric is 1 inch medial and inferior to the ASIS. The direction and depth of needle insertion was similar to that of the Ilioinguinal blockade (23). Because the Ilioinguinal and Iliohypogastric nerves can be located at different fascia planes among the 3 muscles (IO, EO and TA), these blind techniques have low success rates (24).

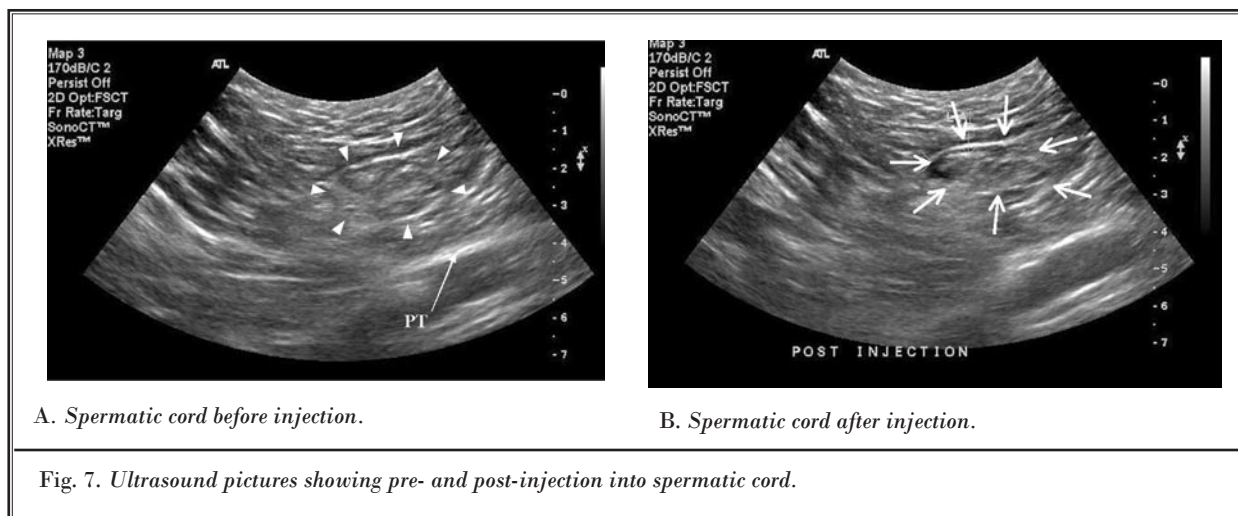
The description of a genitofemoral nerve block mainly refers to the injection of the genital branch of genitofemoral nerve. The landmark described is the pubic tubercle. The needle is suggested to be directed to a point 1 cm superior and lateral to the tubercle with a field block following. Although the philosophy of this landmark is not clear, the needle is likely directed toward the spermatic cord in the inguinal canal. With a blind technique, important structures of the spermatic cord (testicular artery and vas deferens) or the peritoneum are at risk.

Ultrasound-guided Technique for Ilioinguinal, Iliohypogastric and Genitofemoral nerves

The technique for Ilioinguinal and Iliohypogastric injection, under ultrasound guidance in adults, has only been reported twice in the literature (25,26). Because of the superficial nature of the nerve, a linear probe of high frequency will be sufficient. The lateral end of the probe should be placed just above ASIS. The orientation of the probe should be perpendicular to the inguinal line. Once the probe is placed in this position, the hyperechoic shadow of ASIS can be visualized. The probe is then tilted until all 3 layers of muscles (TA, IO, EO) are visualized (Figs. 6A, B). The peritoneum can be seen as the fascia layer underneath the TA muscles. Between the layers of TA and IO muscle, splitting of the fascia layer is usually observed. It is on this plane where Ilioinguinal and Iliohypogastric nerves pass through. Sometimes, both nerves pierce the IO and appear between the IO and EO muscles. Both nerves can run together or run at a distance of approximately 1 cm. In this case, more than 1 fascia split will be seen.

The nerve can be approached by in-plane or out-of-plane techniques. With in-plane techniques, a nerve-stimulating needle is inserted toward the splitting fascia from the lateral end of the probe. Stimula-





A. Spermatic cord before injection.

B. Spermatic cord after injection.

Fig. 7. Ultrasound pictures showing pre- and post-injection into spermatic cord.

tion of the nerve may then produce paresthesia of the groin area. Five mL of local anesthetic is injected into the split fascia plane. If it is used for chronic pain patients, steroid can also be added.

The technique for blocking the genital branch of the genitofemoral nerve under ultrasound guidance has not yet been published. The following technique is based on the authors' experience. Similar to the Ilio-inguinal nerve block, a linear probe of high frequency is used. The orientation of the probe is perpendicular to the inguinal ligament. The final position of the probe is about 1 finger-breadth lateral to the pubic tubercle. However, inexperienced practitioners may have difficulty spotting the spermatic cord, which is oval or circular in shape (Fig. 7A) with 1 or 2 arteries within it (the testicular artery and the artery to vas deferens). The vas deferens is often seen as a thick tubular structure within the spermatic cord. It is suggested to start scanning with the probe in the internal inguinal ring, at which the femoral artery can be visualized in the longitudinal scan (along the length of the femoral artery). By moving the probe in the cephalad direction, the artery is seen as diving deep toward the inguinal ligament. At this point, an oval or circular structure can easily be seen superficial to the femoral artery. The probe is then moved slightly in the medial direction away from the femoral artery. An out-of-plane technique is also used with the needle approaching the skin from the lateral aspect of the probe. Local anesthetic without epinephrine is used to avoid the possible vasoconstriction effect on the testicular artery. Because of the anatomical anomalies found with the location of the genital branch in the

genitofemoral nerve, we suggest depositing 5 mL of local anesthetic inside and another 5 mL outside the spermatic cord (Fig. 7B).

PUDENDAL NEURALGIA

Pudendal neuralgia commonly presents as chronic debilitating pain in the penis, scrotum, labia, perineum or anorectal region (27). The pain in patients with pudendal neuralgia is classically exacerbated by sitting, but is partially relieved by standing, lying down or sitting on the toilet seat. It is mainly caused by pudendal nerve entrapment, which can occur during its path either 1) between the sacrotuberous and the sacrospinous ligaments (28), or 2) through the Alcock's canal (29).

A pudendal nerve block is crucial for the diagnosis and treatment of pudendal neuralgia, as no widely accepted confirmatory laboratory test is available.

Anatomy

The pudendal nerve is formed from the anterior rami of the second, third, and fourth sacral nerves. Emerging from the anterior sacral foramina, the pudendal nerve is accompanied by the internal pudendal artery and exits the pelvis through the greater sciatic notch. The nerve then runs posterior to the sacrospinous ligament at the level of the ischial spine and passes between the sacrospinous and sacrotuberous ligament (interligamentous plane) (27,30), with the pudendal artery on the lateral side (Figs. 1, 8A) (31). The nerve then swings anteriorly to enter the pelvis through the lesser sciatic notch and Alcock's canal (32). The Alcock's canal is the fascia tunnel formed by

the duplication of the obturator internus muscle under the plane of the levator ani muscle on the lateral wall of the ischiorectal fossa (33). The pudendal nerve subsequently splits into 3 terminal branches: the dorsal nerve of the penis (or clitoris), the inferior rectal nerve, and the perineal nerve, providing the sensory branches to the skin of the penis (or clitoris), the perianal area, and the posterior surface of the scrotum or labia majora. It also innervates the external anal sphincter (inferior rectal nerve) and deep muscles of the urogenital triangle (perineal nerve) (34).

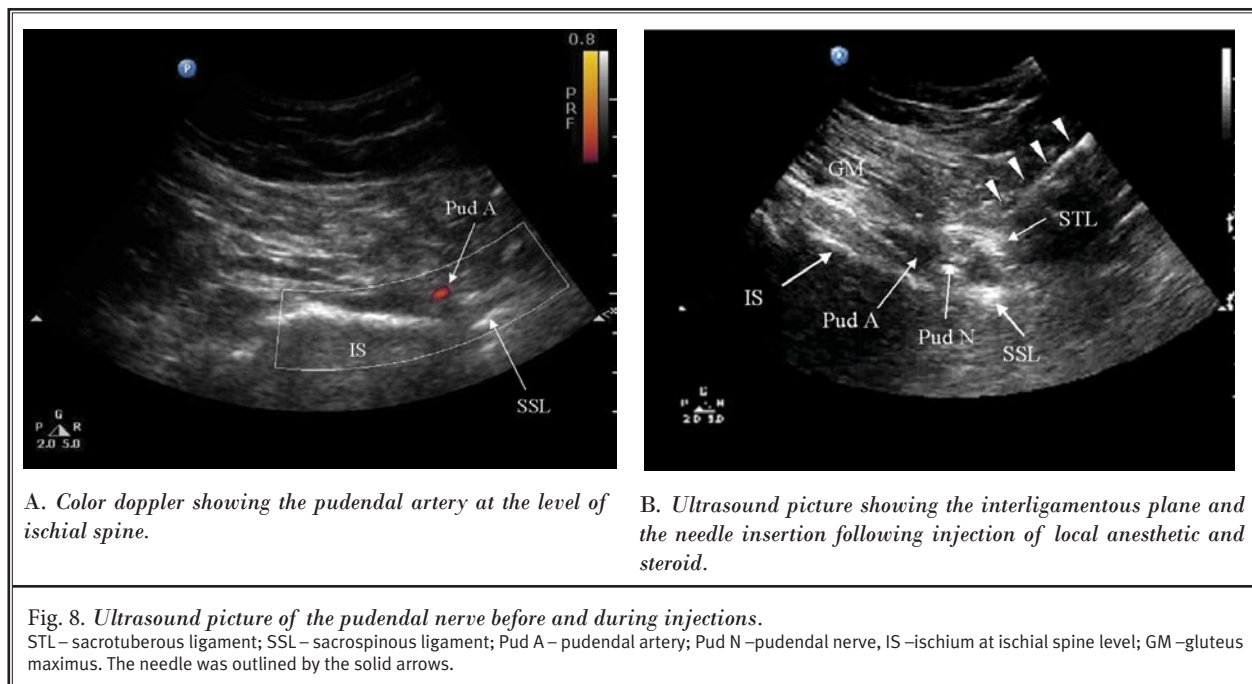
Problems with Existing Technique

The interligamentous plane is the key location for needle placement. The use of CT scan allows the visualization of the interligamentous plane (35). However, CT scan is not usually available to interventional pain specialists. A fluoroscopy-guided technique is popular (27), however, fluoroscopy cannot be used to visualize the interligamentous plane. Instead, it involves the use of a surrogate landmark, the ischial spine. Since the pudendal nerve is principally found medial to the pudendal artery (76-100%) at the level of the ischial spine (31,36), injection at this bony landmark may result in failure to disperse solution to the pudendal nerve.

Ultrasound-guided technique for pudendal nerve injection

There are only three reports on the use of ultrasound in the visualization of the pudendal nerve (31,36,37). Of these, only one described the ultrasound-guided injection technique (37). Ultrasonography allows the visualization of important landmarks: the ischial spine, pudendal artery, sacrospinous ligament, sacrotuberous ligament and pudendal nerve. It also allows real-time needle advancement and confirmation of injectate spread within the interligamentous plane.

A low frequency 2-5 MHz curved array ultrasound probe is used. After skin preparation with Povidone-iodine and sterile probe preparation within a transparent plastic sheath, scanning is performed in transverse planes to visualize the ischium forming the lateral border of the sciatic notch. By moving the ultrasound probe in a cephalad-caudal direction, the ischium appears as a progressively lengthening hyperechoic line that is widest at the ischial spine level. The ischium is initially seen as a curved line as it forms the posterior aspect of the acetabulum. When the probe is at the ischial spine level, the ischium will appear as a straight line. At this level, a color Doppler is used to localize the internal pudendal artery pulsations in close proximity



to the ischial spine. Another arterial pulsation is often seen lateral to the tip of the ischial spine and is accompanied by the sciatic nerve. This is the inferior gluteal artery. Mistaking this artery for the pudendal artery will result in sciatic nerve block. The sacrospinous ligament appears as a hyperechoic line in continuity with the ischial spine, with lower echogenicity than bone. Similarly, the sacrotuberous ligament is seen as a light hyperechoic line deep within gluteus maximus muscle and appears parallel and superior to the sacrospinous ligament in ultrasound images.

Localization of the pudendal nerve is targeted in the plane between these 2 ligaments. Under ultrasound guidance, a 22-gauge, 12 cm insulated peripheral nerve stimulating needle (Pajunk® Gelsingen, Germany) is inserted from the medial aspect of the probe. It is advanced in line with the ultrasound probe to the medial aspect of the internal pudendal artery (Fig. 8B). Once the needle passes through the sacrotuberous ligament, a “click” is usually felt and a small volume (1 – 2 mL) of D5W is injected. The solution appears as a hypoechoic collection, in order to identify the plane between the sacrotuberous and the sacrospinous ligaments and to accentuate the pudendal nerve appearance (Fig. 8b).

In a recent feasibility study, it was shown that the pudendal nerve could only be clearly visualized in 30% of the subjects tested (37). This limited visibility may be due to a few reasons. The average diameter of the pudendal nerve at the level of the ischial spine is approximately 4 – 6mm (30,31,38). Nerves of this size are generally difficult to detect with an ultrasound at a depth of 5.2 ± 1.1 cm. At the level of the ischial spine, 30-40% of pudendal nerves are 2-trunked or 3-trunked (30,38,39). This reduces the chance of a direct depiction

of the nerve with an ultrasound and may also account for the poor response to the nerve stimulator. Lastly, the pudendal nerve itself may be embedded in dense connective or fatty tissue (31), which may also limit direct delineation of the nerve. Although visualization of the pudendal nerve was not possible in all cases, the 2 ligaments and internal pudendal artery can be easily identified. The needle is inserted medially toward the pudendal artery as the pudendal nerve is principally located medial to this artery (76 –100%) (31,36). With this technique, Rofaeel et al (37) were able to produce a sensory block in 100% of the patients tested.

Nerve stimulation is used once the needle is positioned in the interligamentous plane medial to the pudendal artery, as the pudendal nerve is in proximity to the sciatic nerve. Absence of muscle stimulation in the sciatic distribution avoids subsequent blockade of the sciatic. Following satisfactory positioning of the needle tip, an admixture of local anesthetic (5 mL of 0.25% bupivacaine in 1:200,000 epinephrine) and steroid (40 mg depo-medrol; Pharmacia & Upjohn, Kalamazoo, MI) is injected and the adequacy of local anesthetic dispersion around the nerve during injection is reassessed.

CONCLUSION

Ultrasound-guided techniques offer many advantages over the conventional techniques. The ultrasound machine is portable and is more readily available to pain specialist. It prevents patients and healthcare professionals from exposure to radiation during the procedure. Because it allows the visualization of a wide variety of tissues, it potentially improves the accuracy of the needle placement, as exemplified by various interventional procedures in the pelvic regions aforementioned.

REFERENCES

1. ACOG committee on practice bulletins. Chronic pelvic pain. *ACOG Practice Bulletin* 2004; 103:589-605.
2. Mathias SD, Kuppermann M, Liberman RF, Lipschutz RC, Steege JF. Chronic pelvic pain: Prevalence, health related quality of life, and economic correlates. *Obstet Gynecol* 1996; 87:321-327.
3. Schaeffer AJ. Etiology and management of chronic pelvic pain syndrome in men. *Urology* 2004; 63:75-84.
4. Wesselman U, Burnett AL, Heinberg LJ. The urogenital and rectal pain syndromes. *Pain* 1997; 73:269-294.
5. Robinson DR. Piriformis syndrome in relation to sciatic pain. *Am J Surg* 1947; 73:335-358.
6. Papadopoulos EC, Khan SN. Piriformis syndrome and low back pain: a new classification and review of the literature. *Orthop Clin N Am* 2004; 35:65-71.
7. Benzon HT, Katz JA, Benzon HA, Iqbal MS. Piriformis syndrome: Anatomic considerations, a new injection technique, and a review of the literature. *Anesthesiology* 2003; 98:1442-1448.
8. Fishman LM, Anderson C, Rosner B. Bo-tex and physical therapy in the treatment of piriformis syndrome. *Am J Phys Med Rehabil* 2002; 81:936-942.
9. Beason LE, Anson BJ. The relation of the sciatic nerve and its subdivisions to the piriformis muscle. *Anat Record* 1937; 70:1-5.
10. Pecina M. Contribution to the etiological explanation of the piriformis syndrome. *Acta Anat* 1979; 105:181-187.
11. Fishman SM, Caneris OA, Bandman TB, Audette JF, Borsook D. Injection of the piriformis muscle by fluoroscopic and electromyographic guidance. *Reg Anesth Pain Med* 1998; 23:554-559.

12. Betts A. Combined fluoroscopic and nerve stimulator technique for injection of the piriformis muscle. *Pain Physician* 2004; 7:279-281.
13. Smith J, Hurdle M-F, Locketz AJ, Wisniewski SJ. Ultrasound-guided piriformis injection: Technique description and verification. *Arch Phys Med Rehabil* 2006; 87:1664-1667.
14. Huerto APS, Yeo SN, Ho KY. Piriformis muscle injection using ultrasonography and motor stimulation – report of a technique. *Pain Physician* 2007; 10:687-690.
15. Rab M, Ebmer J, Dellon AL. Anatomic variability of the ilioinguinal and genitofemoral nerve: Implications for the treatment of groin pain. *Plast Reconstr Surg* 2001; 108:1618-1623.
16. Seid AS, Amos E. Entrapment neuropathy in laparoscopic herniorrhaphy. *Surg Endosc* 1994; 8:1050-1053.
17. Whiteside JL, Barber MD, Walters MD, Falcone T. Anatomy of ilioinguinal and iliohypogastric nerves in relation to trocar placement and low transverse incisions. *Am J Obstet Gynecol* 2003; 189:1574-1578.
18. Alfieri S, Rotondi F, Di Giorgio A, Fumagalli U, Salzano A, Di Miceli D, Ridolfini MP, Sgadari A, Doglietto G, and the Groin Pain Trial Group. Influence of preservation versus division of ilioinguinal, iliohypogastric, and genital nerves during open mesh herniorrhaphy prospective multicentric study of chronic pain. *Ann Surg* 2006; 243:553-558.
19. Liu WC, Chen TH, Shyu JF, Chen CH, Shih C, Wang JJ, Kung SP, Lui WY, Wu CW, Liu JC. Applied anatomy of the genital branch of the genitofemoral nerve in open inguinal herniorrhaphy. *Eur J Surg* 2002; 168:145-149.
20. Ducic I, Dellon AL. Testicular pain after inguinal hernia repair: An approach to resection of the genital branch of genitofemoral nerve. *J Am Coll Surg* 2004; 198:181-184.
21. Katz, J, Brown JW. *Atlas of Regional Anesthesia*. Appleton-Century-Crofts and Fleschner Pub. Co., Norwalk, CT. 1985.
22. Brown DL. *Atlas of Regional Anesthesia*. WB Saunders, Philadelphia, PA. 1999.
23. Waldman SD. *Atlas of Interventional Pain Management*. Saunders, Philadelphia, PA. 2004.
24. van Schoor AN, Boon JM, Bosenberg AT, Abrahams PH, Meiring JH. Anatomical considerations of the pediatric ilioinguinal/iliohypogastric nerve block. *Paediatr Anaesth* 2005; 15:371-377.
25. Eichenberger U, Greher M, Kirchmair L, Curatolo M, Morigg B. Ultrasound-guided blocks of the ilioinguinal and iliohypogastric nerve: Accuracy of a selective new technique confirmed by anatomical dissection. *Br J Anaesth* 2006; 97:238-243.
26. Gofeld M, Christakis M. Sonographically guided ilioinguinal nerve block. *J Ultrasound Med* 2006; 25:1571-1575.
27. Robert R, Prat-Pradal D, Labat JJ, Besignor M, Raoul S, Rebai R, Leborgne J. Anatomic basis of chronic perineal pain: Role of the pudendal nerve. *Surg Radiol Anat* 1998; 20:93-98.
28. Labat JJ, Robert R, Besignor M, Buzelin JM. Neuralgia of the pudendal nerve. Anatomic-clinical considerations and therapeutic approach. *J Urol (Paris)* 1990; 96:239-244.
29. Amarenco G, Lanoe Y, Ghnassia RT, Goudal H, Perrigot M. Alcock's canal syndrome and perineal neuralgia. *Rev Neurol (Paris)* 1988; 144:523-526.
30. Mahakkanukrauh P, Surin P, Vaidhaya-karn P. Anatomical study of the pudendal nerve adjacent to the sacrospinous ligament. *Clin Anat* 2005; 18:200-205.
31. Gruber H, Kovacs P, Piegger J, Brenner E. New, simple, ultrasound-guided infiltration of the pudendal nerve: Topographic basics. *Dis Colon Rectum* 2001; 44:1376-1380.
32. Thompson JR, Gibb JS, Genadry R, Burrows L, Lambrou N, Buller JL. Anatomy of pelvic arteries adjacent to the sacrospinous ligament: Importance of the coccygeal branch of the inferior gluteal artery. *Obstet Gynecol* 1999; 94:973-977.
33. Myology: Fascia of the trunk. In: Warwick R, Williams PL, ed. *Gray's Anatomy*. 36th ed. Edinburgh, UK, Churchill 1980; 542-564.
34. Schraffordt SE, Tjandra JJ, Eizenberg N, Dwyer PL. Anatomy of the pudendal nerve and its terminal branches: A cadaver study. *ANZ J Surg* 2004; 74:23-26.
35. Hough DM, Wittenberg KH, Pawlina W, Maus TP, King BF, Vrtiska TJ, Farrell MA, Antolak SJ Jr. Chronic perineal pain caused by pudendal nerve entrapment: Anatomy and CT-guided perineural injection technique. *Am J Roentgenol* 2003; 181:561-567.
36. Kovacs P, Gruber H, Piegger J, Bodner G. New, simple, ultrasound-guided infiltration of the pudendal nerve: Ultrasoundographic technique. *Dis Colon Rectum* 2001; 44:1381-1385.
37. Rofaeel A, Peng P, Louis I, Chan V. Feasibility of real-time ultrasound for pudendal nerve block in patients with chronic perineal pain. *Reg Anesth Pain Med (In press)*.
38. O'Bichere A, Green C, Phillips RK. New, simple approach for maximal pudendal nerve exposure: Anomalies and prospects for functional reconstruction. *Dis Colon Rectum* 2000; 43:956-960.
39. Shafik A, el-Sherif M, Youssef A, Olfat ES. Surgical anatomy of the pudendal nerve and its clinical implications. *Clin Anat* 1995; 8:110-115.