

Case Report

Pulsed Radiofrequency of the Median Nerve under Ultrasound Guidance

Naeem Haider, MD, Daniel Mekasha, MD, Srinivas Chiravuri, MD,
and Ronald Wasserman, MD

From: University of Michigan,
Ann Arbor, MI.

Dr. Haider is Assistant Professor,
Department of Anesthesiology, and
Director of Regional Anesthesia with
the University of Michigan,
Ann Arbor, MI.

Dr. Mekasha is in the Department
of Anesthesiology, University of
Michigan, Ann Arbor, MI.

Dr. Chiravuri is Director
Pain Medicine Fellowship Program
Department of Anesthesiology,
University of Michigan, Ann Arbor, MI.
Dr. Wasserman is Assistant Professor
Chief, Pain Service Director, Back and
Pain Clinic, University of Michigan,
Ann Arbor, MI

Address correspondence:
Naeem Haider, MD
University of Michigan
1H247 UH Box 0048
1500 East Med Ctr Dr
Ann Arbor, MI 48109-0048.
Email: nhaider@med.umich.edu

Disclaimer: There was no external
funding in the preparation of this
manuscript.

Conflict of interest: None.

Manuscript received: 06/08/2007
Revisions received: 08/24/07
Accepted for publication:
09/04/2007

Free full manuscript:
www.painphysicianjournal.com

Neuropathy of the median nerve within the carpal tunnel (carpal tunnel syndrome) has an age adjusted incidence of 105 cases per 100,000 person years. Treatment of carpal tunnel syndrome ranges from conservative management with medication and exercise to surgical release of the median nerve. Conservative treatment accounts for a significant portion of resources utilized and includes splinting, nerve gliding, ultrasound, and carpal bone mobilization.

Recurrent symptoms of carpal tunnel syndrome have been shown to occur in 0% to 19% of patients following carpal tunnel release, with up to 12% requiring re-exploration. Prognosis for re-exploration is not as good as for primary carpal tunnel release, with a high recurrence rate in some populations. Ultrasound has seen increasing use in regional anesthesia and has been shown to improve the quality of regional anesthetic blocks.

Pulsed radiofrequency was developed with the goal of providing reduction in pain from the use of electrical fields in the absence of neural injury. The use of ultrasound guidance for positioning radiofrequency probes over peripheral nerves has not been reported.

This case report describes the use of ultrasound guided pulsed radiofrequency in the treatment of recurrent carpal tunnel syndrome. Following revision carpal tunnel surgery, the patient in this report was unable to obtain relief of pain in either hand with medication therapy alone. After a successful diagnostic median nerve block at the cubital fossa, pulsed radiofrequency of the median nerve was performed on the left side at the cubital fossa, under ultrasound guidance. Radiofrequency probe adjustment around the nerve was conducted under live ultrasound guidance and multiple pulsed treatments were applied at anatomically distinct sites over the nerve. A 70% reduction in pain was reported over the follow up period of 12 weeks.

Key words: Pulsed radiofrequency, carpal tunnel, ultrasound, median nerve.

Pain Physician 2007; 10:765-770

Neuropathy of the median nerve within the carpal tunnel (carpal tunnel syndrome) has an age adjusted incidence of 105 cases per 100,000 person years (1). The incidence increases with age in men and peaks at age 45 to 54 years in women (1). Surveys have shown a prevalence of 1% in men and 7% in women or an average of 3–4% for both sexes (2-4). Symptoms include numbness, tingling, burning, or pain in at least 2 of the 3 digits supplied by the median nerve (thumb, index, and middle finger) (5). The combination of symptoms, physical findings, and electrophysiologic studies are used to confirm the diagnosis (6). Although most cases are idiopathic, a variety of secondary causes of carpal tunnel syndrome have been reported, including lesions within the carpal tunnel, metabolic and physiologic causes, infection, neuropathies, and inherited disorders (7). Repetitive stress, obesity, dieting, hysterectomy without oophorectomy, recent menopause, and short stature have been reported as associated risk factors in one study (8).

Pulsed radiofrequency developed with the goal of providing reduction in pain from the use of electrical fields in the absence of neural injury (9). The first report of its use on the dorsal root ganglion appeared in the *Pain Clinic* in 1998 (10). Prospective trials have shown a benefit in pain reduction with the use of pulsed radiofrequency in a variety of chronic pain states (11-14). Mechanisms underlying the effect of pulsed radiofrequency continue to be debated in the literature (15,16). Exposure of rat cervical dorsal root ganglia to pulsed radiofrequency shows an increase in c-Fos immunoreactivity in the dorsal horn up to 1 week after treatment (17). The long-term effect on the targeted nerve is a potential matter of concern. In vitro and in vivo studies have both failed to demonstrate local tissue destruction with the application of pulsed radiofrequency (18,19). Hamann et al concluded that pulsed radiofrequency has a biological effect unlikely to be related to overt thermal damage and that it targets small diameter C and A delta nociceptive fibres (20).

Ultrasound guidance continues to find utility in regional anesthetic blocks (21-23). Recent reports of its use in the localization of nerves for treatment of chronic pain states have been published in the literature (24,25). Use of ultrasound guidance for positioning radiofrequency probes over peripheral nerves has not been reported. This case report describes the use of ultrasound guided pulsed radiofrequency in the

treatment of recurrent carpal tunnel syndrome resistant to medical therapy.

CASE REPORT

Mr. G is a right-handed male with a long-standing complaint of bilateral hand pain diagnosed as carpal tunnel syndrome. Surgery completed in 1996 bilaterally provided good pain relief until early 2000. Weak opioids were ineffective in treating pain and revision surgery of bilateral carpal tunnels was completed in mid 2000. Symptoms progressively worsened after the second operation. Weak opioids were combined with non-steroidal medication and muscle relaxants over time from multiple providers. Pain continued unabated until his presentation to our clinic.

On arrival, pain was determined to be in the distribution of the median nerve in both hands, worse on the left than the right. It was described as sharp and achy, accompanied by numbness. Pain was continuous ranging from 3 to 9 on a scale of 0 to 10 on the Visual Analog Scale, worsening with activity and relieved with rest. Activities of daily living were affected, and grip strength had diminished resulting in an inability to grasp objects reliably. Sleep was disturbed secondary to numbness and pain. The patient had applied for Social Security disability.

An electromyograph in February 2006 revealed bilateral carpal tunnel syndrome, moderate on the left, and mild on the right, as well as mild ulnar tunnel syndrome on the left. Medications included Vicodin ES 0.5/750 (3/day), Ibuprofen 800 mg PRN (3-4/day). Examination of the upper extremities revealed diminished light touch and pinprick in the median nerve distribution of the right and left hand. There was weakness in wrist flexors bilaterally. Deep tendon reflexes were 1+ and symmetrical bilaterally. Lhermitte sign was negative. Phalen's and Tinel's tests were positive bilaterally. Well-healed surgical incisions were noted at the wrists. The skin was pink, cool, and dry, with no evidence of hyperesthesia or allodynia. Normal hair and nail distribution was apparent.

Initial conservative treatment included the use of Neurontin in an escalating dose. This was deemed ineffectual. A diagnostic median nerve block was performed at a later visit on the left side using nerve stimulation at the elbow. This resulted in complete relief of pain in the left hand. The decision to block the median nerve at the cubital fossa in contrast to

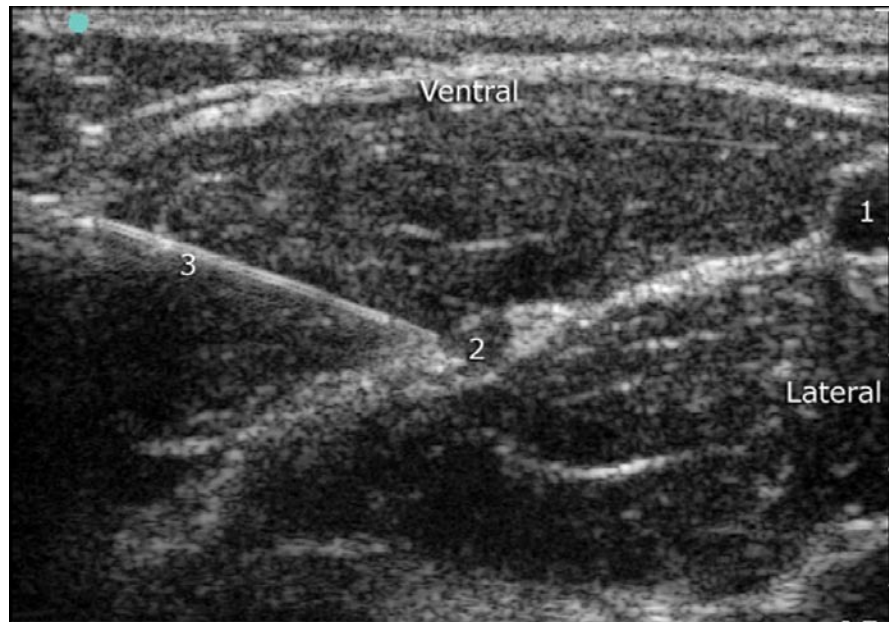

Fig. 1. Cross section of left cubital fossa using 12 mHz, 38 mm ultrasound probe demonstrating brachial artery (1) and median nerve (2).

the flexor retinaculum of the wrist was made based on post-surgical scarring at the wrist, along with significant tenderness over the median nerve at that site. On a return visit, pulsed radiofrequency of the left median nerve was scheduled under ultrasound guidance. Following the application of standard monitors with the patient supine on the procedure table, the left cubital fossa was prepped with betadine and draped. Sonosite Micromax II, utilizing a 12 mHz 38 mm linear probe, was used to identify the median nerve in cross section medial to the biceps tendon and brachial artery (Fig. 1). Skin was anesthetized with 1% lidocaine and a 54 mm radiofrequency probe with a 4 mm active tip was directed under ultrasound guidance to the ventral surface of the median nerve. The median nerve was stimulated at 2Hz and 0.3mA and contraction of finger flexors was observed. Pulsed radiofrequency (PRF) was applied at this point at a temperature of 42 degrees Celsius for 90 seconds. During application of

the pulsed treatment, contraction of the finger flexors continued. The patient reported that this was not painful. Following repositioning of the needle to the medial aspect of the median nerve under ultrasound guidance, stimulation of the median nerve at 2 Hz and 0.3 mA was assessed (Fig. 2). PRF was again performed for 90 seconds at 42 degrees Celsius. Motor contractions of the finger flexors was again observed and seen to diminish towards the end of the treatment. A third PRF was performed on the dorsal surface of the median nerve again utilizing ultrasound to guide needle placement.

During the procedure, the patient reported a reduction in pain in the hand. Following all 3 applications of PRF to the median nerve a 70% reduction in pain was reported on the verbal rating scale. Follow up assessment via telephone revealed continuing pain relief at 12 weeks with a gradual return to baseline pain after the 12-week period.

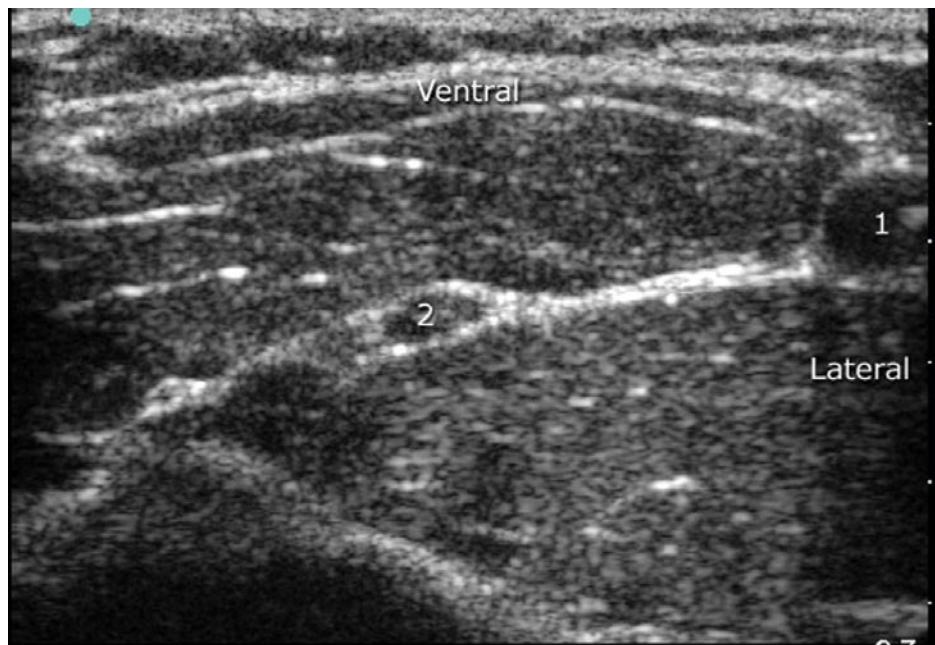


Fig. 2. Cross section of left cubital fossa using 12 mHz, 38 mm ultrasound probe, demonstrating RF probe (3) approaching median nerve (2) medial to brachial artery (1).

DISCUSSION

Treatment of carpal tunnel syndrome ranges from conservative management with medication and exercise to surgical release of the median nerve. Conservative treatment accounts for a significant portion of resources utilized and includes splinting, nerve gliding, ultrasound, and carpal bone mobilization (26,27). Surgical release in the United States amounts to 400,000 to 500,000 cases per year (27). Success rates from surgical release reportedly range from 70 to 90% (26). Although clinical symptoms and signs have been used traditionally as outcome measures, a number of disease specific questionnaires (Boston Carpal Tunnel Questionnaire, Michigan Hand Outcome Questionnaire, Disability of Arm, Shoulder and Hand, Upper Extremity Functional Scale amongst others) have been developed (28). However, none of the questionnaires can be considered to be the best or ideal outcome measure and there is little agreement on how the results should be evaluated (28). Recurrent symptoms

of carpal tunnel syndrome have been shown to occur in 0% to 19% of patients following carpal tunnel release, with up to 12% requiring re-exploration (29). Common causes include incomplete release, fibrous proliferation, or recurrent tenosynovitis (29). Prognosis for re-exploration is not as good as for primary carpal tunnel release, with a high recurrence rate in some populations.

Pulsed radiofrequency of mixed motor and sensory nerves has been reported in some case series involving the suprascapular nerve with results lasting from 4 to 5 months (10,30, 31). Multiple radiofrequency treatments are applied during the procedure. Some authors have described rotating or moving the needle to a different position over the target nerve, allowing for additional pulsed treatments over the target nerve. Ultrasound has seen increasing use in regional anesthesia and has been shown to improve the quality of regional anesthetic blocks (21-23). Di-

rect visualization of target nerves may limit neural trauma, allowing for improved onset and duration of regional anesthetic blocks. Needle guidance for chronic pain intervention under ultrasound has received increasing attention in recent years (24,25). However the use of ultrasound in peripheral nerves has not yet been reported in conjunction with Pulsed radiofrequency. Visualization of non radio-opaque

neural structures allows the ability to reposition a radiofrequency probe at anatomically distinct points on the target nerve. This may provide an improvement in duration and/or success of the treatment. Further evaluation of the use of ultrasound guidance in performance of pulsed radiofrequency of peripheral nerves will require randomized trials to determine any benefit that this technique may provide.

REFERENCES

1. Stevens JC, Witt, JC, Smith BE, Weaver AL. Carpal tunnel syndrome in Rochester, Minnesota, 1961 to 1980. *Neurology* 1988; 38:134-138.
2. Dumitru D, Amato AA, Zwarts MJ. *Electrodiagnostic medicine*. 2nd ed. 2002, Philadelphia: Hanley & Belfus. xi, p. 1524
3. Atroshi S, Gummesson C, Johnsson R, Ornstein E, Ranstam J, Rosén I. Prevalence of carpal tunnel syndrome in a general population. *JAMA* 1999; 282: 153-158.
4. Atroshi I, Gummesson C, Johnsson R, Ornstein E, Ranstam J, Rosen I. [Prevalence for clinically proved carpal tunnel syndrome is 4 percent]. *Lakartidningen*, 2000; 97:1668-1670.
5. Rempel D, Evanoff B, Amadio P C, de Krom M, Franklin G, Franzblau A, Gray R, Gerr F, Hagberg M, Hales T, Katz J N, Pransky G. Consensus criteria for the classification of carpal tunnel syndrome in epidemiologic studies. *Am J Public Health* 1998; 88: 1447-1451.
6. Practice parameter for electrodiagnostic studies in carpal tunnel syndrome: Summary statement. *Muscle Nerve* 2002; 25:918-922.
7. von Schroeder HP, Botte MJ. Carpal tunnel syndrome. *Hand Clin* 1996; 12: 643-655.
8. de Krom MC, Kester AD, Knipschild PG, Spaans F. Risk factors for carpal tunnel syndrome. *Am J Epidemiol* 1990; 132:1102-1110.
9. Cosman ER. A comment on the history of the pulsed radiofrequency technique for pain therapy. *Anesthesiology* 2005; 103:1312; author reply 1313-1314.
10. Rohof OJ. Radiofrequency treatment of peripheral nerves. *Pain Pract* 2002; 2: 257-260.
11. Martin DC, Willis ML, Mullinax LA, Clarke, NL, Homburger JA, Berger IH. Pulsed radiofrequency application in the treatment of chronic pain. *Pain Pract* 2007; 7:31-35.
12. Van Zundert J, Patijn J, Kessels A, Lamé I, van Suijlekom H, van Kleef M. Pulsed radiofrequency adjacent to the cervical dorsal root ganglion in chronic cervical radicular pain: a double blind sham controlled randomized clinical trial. *Pain* 2007; 127:173-182.
13. Mikeladze G, Espinal R, Finnegan R, Routon J, Martin D. Pulsed radiofrequency application in treatment of chronic zygapophyseal joint pain. *Spine J* 2003; 3:360-362.
14. Cohen SP, Sireci A, Wu CL, Larkin TM, Williams KA, Hurley RW. Pulsed radiofrequency of the dorsal root ganglia is superior to pharmacotherapy or pulsed radiofrequency of the intercostal nerves in the treatment of chronic postsurgical thoracic pain. *Pain Physician* 2006; 9:227-235.
15. Gallagher RM. Pulsed radiofrequency treatment: What is the evidence of its effectiveness and should it be used in clinical practice? *Pain Med* 2006; 7:408-410.
16. Cahana A. Pulsed radiofrequency: A neurobiologic and clinical reality. *Anesthesiology* 2005; 103:1311; author reply 1313-1314.
17. Van Zundert, J de Louw AJA, Joosten EA. Pulsed and continuous radiofrequency current adjacent to the cervical dorsal root ganglion of the rat induces late cellular activity in the dorsal horn. *Anesthesiology* 2005; 102:125-131.
18. Heavner JE, Boswell MV, Racz GB. A comparison of pulsed radiofrequency and continuous radiofrequency on thermocoagulation of egg white in vitro. *Pain Physician* 2006; 9:135-137.
19. Podhajsky RJ, Sekiguchi Y, Kikuchi S, Myers RR. The histologic effects of pulsed and continuous radiofrequency lesions at 42 degrees C to rat dorsal root ganglion and sciatic nerve. *Spine* 2005; 30:1008-1013.
20. Hamann W, Abou-Sherif S, Thompson S, Hall S. Pulsed radiofrequency applied to dorsal root ganglia causes a selective increase in ATF3 in small neurons. *Eur J Pain* 2006; 10:171-176.
21. Kapral S, Krafft P, Eibenberger K. Ultrasound-guided supraclavicular approach for regional anesthesia of the brachial plexus. *Anesth Analg* 1994; 78:507-513.
22. Sites BD, Brull R. Ultrasound guidance in peripheral regional anesthesia: Philosophy, evidence-based medicine, and techniques. *Curr Opin Anaesthesiol* 2006; 19:630-639.
23. Marhofer P, Schrogendorfer K, Koinig H, Kapral S, Weinstabl C, Mayer N. Ultrasonographic guidance improves sensory block and onset time of three-in-one blocks. *Anesth Analg* 1997; 85:854-857.
24. Eichenberger U, Greher M, Kapral S, Marhofer P, Wiest R, Remonda L, Bogduk N, Curatolo M. Sonographic visualization and ultrasound-guided block of the third occipital nerve: Prospective for a new method to diagnose C2-C3 zygapophysial joint pain. *Anesthesiology* 2006; 104:303-308.
25. Eichenberger U, Greher M, Kirchmair L, Curatolo M, Moriggl B. Ultrasound-guided blocks of the ilioinguinal and iliohypogastric nerve: Accuracy of a selective new technique confirmed by anatomical dissection. *Br J Anaesth* 2006;

- 97:238-243.
26. Jerosch-Herold C, Leite JC, Song F. A systematic review of outcomes assessed in randomized controlled trials of surgical interventions for carpal tunnel syndrome using the International Classification of Functioning, Disability and Health (ICF) as a reference tool. *BMC Musculoskelet Disord* 2006; 7:96.
 27. Muller M, Tsui D, Schnurr R, Biddulph-Deisroth L, Hard J, MacDermid JC. Effectiveness of hand therapy interventions in primary management of carpal tunnel syndrome: A systematic review. *J Hand Ther* 2004; 17:210-228.
 28. Sambandam SN, Priyanka P, Gul A, Ilango B. Critical analysis of outcome measures used in the assessment of carpal tunnel syndrome. *Int Orthop* 2007; Mar 17 (EPub).
 29. Botte MJ, von Schroeder HP, Abrams RA, Gellman H. Recurrent carpal tunnel syndrome. *Hand Clin* 1996; 12:731-743.
 30. Gurbet A, Türker G, Bozkurt M, Keskin E, Uçkunkaya N, Sahin S. [Efficacy of pulsed mode radiofrequency lesioning of the suprascapular nerve in chronic shoulder pain secondary to rotator cuff rupture]. *Agri* 2005; 17:48-52.
 31. Shah RV, Racz GB. Pulsed mode radiofrequency lesioning of the suprascapular nerve for the treatment of chronic shoulder pain. *Pain Physician* 2003; 6:503-506.