

Prospective Evaluation

Total Cervical Translation as a Function of Impact Vector as Measured by Flexion-Extension Radiography

Christopher J. Centeno, MD¹, Whitney Elkins, MPH¹, Michael Freeman, PhD², James Elliott, PhD, MSPT³, Michele Sterling, PhD⁴ and Evan Katz, DC¹

From: ¹The Spinal Injury Foundation, Westminster, CO; ²University of Queensland, Australia ³Regis University, Denver, CO; ⁴University of Oregon Health Sciences Center, Portland, OR.

¹Dr. Centeno, Dr. Elkins and Dr. Katz are with The Spinal Injury Foundation, Westminster, CO.

²Dr. Sterling is with The University of Queensland, Brisbane, Australia.

³Elliott is with Regis University, Denver, CO.

⁴Dr. Freeman is with the University of Oregon Health Sciences Center, Portland, OR.

Address correspondence:
Christopher J Centeno
The Spinal Injury Foundation
11080 Circle Point Road, Suite 140
Westminster, CO 80020
E-mail: centenooffice@centenoclinic.com

Disclaimer: There was no external funding in the preparation of this manuscript.

Conflict of interest: None.

Manuscript received: 02/27/2007
Accepted for publication:
07/27/2007

Free full manuscript:
www.painphysicianjournal.com

Background: Clinical and cadaveric studies have implicated that sub-failure cervical instability likely occurs in a subset of whiplash injury patients. Cadaveric studies have suggested that female specimens suffer from more ligamentous stretch injury than males when exposed to simulated rear end crash vectors. However, these findings have never been tested in an in-vivo clinical setting.

Design: A prospective evaluation of total cervical translation on sagittal flexion radiographs versus impact vector in a late whiplash population.

Objectives: To determine if total cervical translation on radiographs is correlated with impact crash vector.

Methods: Consecutive late whiplash patients in a subspecialty pain clinic setting were sent for radiographs using a strict stress flexion-extension protocol. Information concerning crash vector and damage was recorded. Vertebral translation was read by a blinded reader and recorded.

Results: Males did not significantly differ in total translation in flexion-extension radiographs when involved in sagittal plane crashes (n=75) compared to coronal plane crashes (n=10). In a front end collision, males (n=16) and females (n=26) did not differ in total translation in flexion-extension radiographs. In a rear end collision, females (mean translation 4.61 mm, n=103) did differ significantly in total translation in flexion-extension radiographs from their male counterparts (mean translation 3.29, n=48) ($P<0.001$).

Conclusion: This investigation suggests that specific crash vectors lead to particular patterns of radiographic translation in female subjects. A realization that sub-failure cervical instability occurs in whiplash may help design more effective treatments.

Key words: Cervical translation, impact vector, radiograph, flexion, extension, whiplash

Pain Physician 2007; 10:667-671

Several authors have postulated that vertebral instability is a significant cause of post-traumatic (whiplash trauma) spinal pain. Dvorak et al (1) reported increased upper and mid-cervical hypermobility in a cervical spine trauma group in a comparison of traumatic versus degenerative pain. In addition, Panjabi et al (2) have reported a biomechanical investigation of increases in the "neutral zone" of the cervical spine as a result of trauma, with significant increases noted in the neutral zone with experimental rear accelerations of as low as 4.5 g's. Panjabi et al and Ivancic et al (2,3) both have also produced anterior longitudinal ligament strain and rupture in cadavers as a result of simulated whiplash trauma, experimentally producing the pathologic link between the pathomechanics of whiplash and the clinical observation of instability. Most recently, Kristjansson et al (4) published a report showing that whiplash patients demonstrated objectively increased translational and rotational movements when compared with controls. Significantly more women in the whiplash-associated disorders group (35.3%) had abnormal increased segmental motions compared to the insidious onset neck pain group (8.6%).

The idea that instability may be associated with pain and neurologic compromise is not new. Grob et al (5) performed an experimental surgical protocol on patients with post-traumatic cervical spine pain by applying external vertebral fixation in random patterns. The external fixation applied in a single blinded fashion over presumed unstable segments gave pain relief, while fixation over normal segments provided no relief.

Cervical spinal instability may have a more profound impact than simply causing local pain. Ebraheim et al (6) have determined that lower cervical translation in flexion can have a negative impact on spinal canal diameter. In addition, spinal canal volume in normal patients is reduced by both flexion and extension, potentially compounding the stenosis through spinal instability (7).

The purpose of the present study is to examine the relationship of cervical spine instability, as measured by a stressed flexion-extension radiographic method, to motor vehicle crash impact vector and severity as well as intrinsic patient variables such as gender. The rationale for the study is the theory that impacts aligned in the sagittal plane (front and rear impacts) are more likely to result in sagittal instability (flexion-extension or excessive sagittal movement on

x-ray) than coronal plane impacts (impacts from the side).

METHODS

The standard for measuring cervical instability is usually considered to be cervical flexion extension radiography. However, Dvorak et al (8) have determined that routine non-stress films may have a significant false-negative rate. This study confirmed that routine active flexion-extension radiographs missed some 39% of levels determined to be unstable when passive examination with over-pressure was utilized. Several authors have produced normal values for flexion-extension radiography. White et al (9) studied an isolated cervical segment by cutting ligamentous constraints and determining movement. They determined that the segment became unstable at 2.7 mm of absolute movement or 3.5 mm of magnified movement on a 72-inch lateral x-ray. Since that time, normal studies in vivo have been performed. Knopp et al (10) defined abnormal motion as more than 2 mm of movement at end range flexion. Lin et al (11) also published a series of 100 normals with population norms for patients. If one factors out the "hypermobile" individuals (randomly defined by Lin as having significant translation at the C2-C3 level), the amount of normal translation was always less than 1 mm.

Consecutive MVC (motor vehicle crash) and non-MVC patients presenting to a subspecialty pain management practice for evaluation of cervical pain were evaluated. Of those patients whom the evaluating physician made the diagnosis to rule out instability, flexion-extension radiographs were taken. To rule out any effect of muscular spasm on segmental mobility, each patient was provided with a 10 mg oral Diazepam tablet to be taken 1-2 hours prior to the radiographs. Each was also told that because of the sedation, a driver would be required. Upon arrival to the clinic, each patient was asked several questions by the technician. These included:

- Age
- Sex
- Etiology of injury (MVC or non-MVC)
- Damage estimate to the vehicle including a 1-3 severity scale and location of damage (if MVC related neck pain) (Fig. 1 and 2)
- Pre-existing injury status

Radiographs were exposed using a Siemens ISO-C C-arm fluoroscope in digital mode. The stress flexion-extension radiography technique already published

by Lin et al was utilized (11). A radiographic ruler was placed in the same plane as the C-arm to account for magnification effects. The patient's torso was stabilized by Velcro straps to a torso immobilizer constructed for the study. Overpressure was performed in flexion and extension to rule out false negatives for instability as described by Dvorak et al (8). Films were repeated until a true lateral resulted for each view (flexion and extension).

Patients with the following were excluded from the present study:

1. WAD I or WAD IV as per the Quebec Task Force Classification system (12)
 2. Pre-existing history of injury in MVC
 3. Neck pain not originating from a MVC
 4. Crash vectors in non-sagittal or coronal planes (not front-rear or side impact)
 5. Complex crash vectors in more than one plane
 6. Age less than 18
- Translation was measured by comparison to the

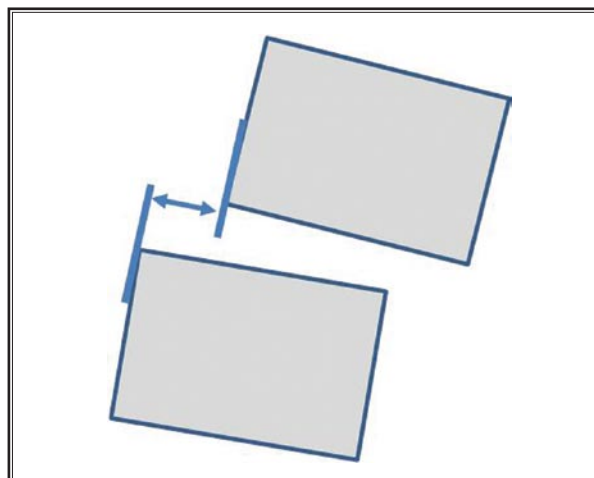


Fig. 1. Measurement of cervical instability. Translation is measured on cervical flexion-extension x-rays as the linear distance in mm from the posterior-inferior corner of the superior vertebra to the superior-posterior corner of the inferior vertebra.

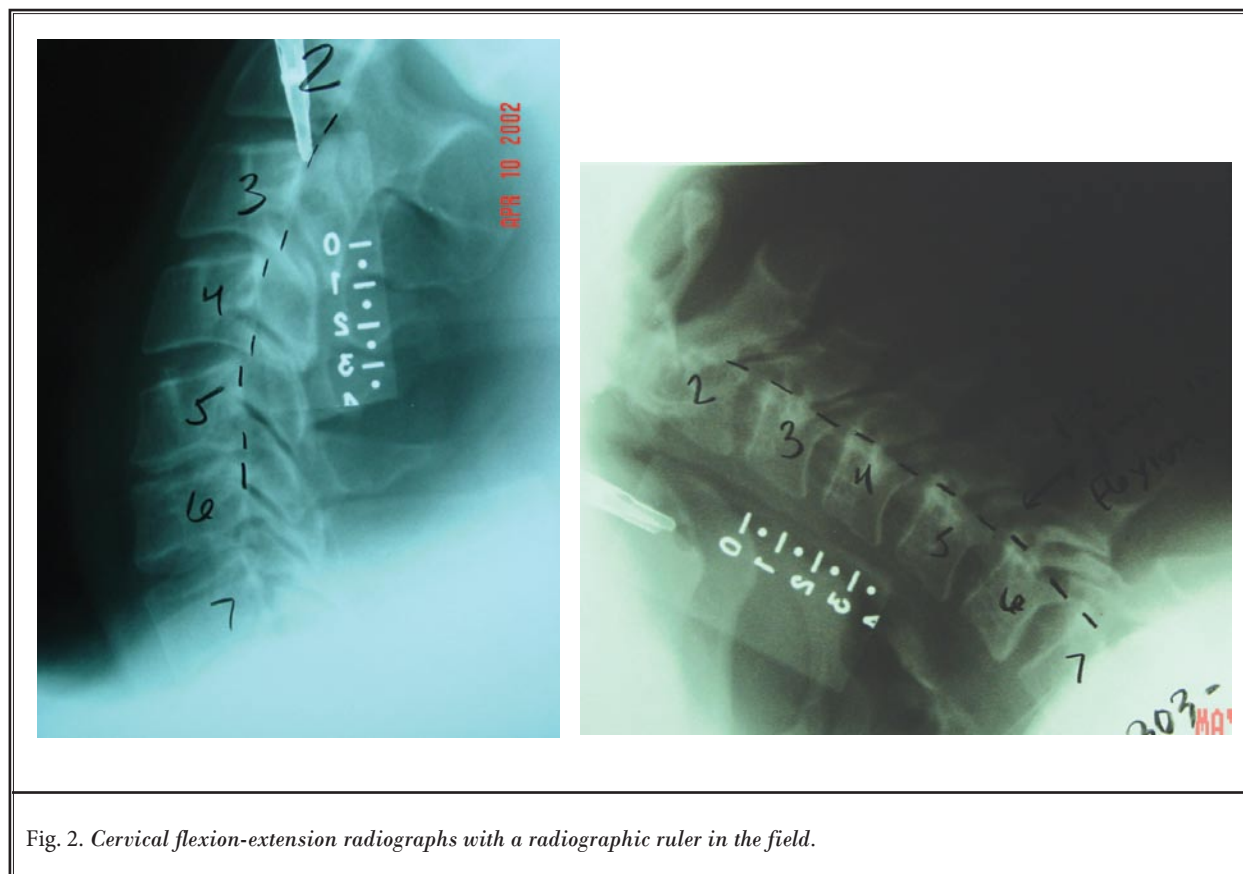


Fig. 2. Cervical flexion-extension radiographs with a radiographic ruler in the field.

radiographic ruler (Fig. 2). Translation was measured at C2-C3 through C6-C7 in millimeters as the horizontal distance between the posterior superior corner of the vertebra below and the posterior inferior corner of the vertebra above (Fig.1). This measurement was carried out both in end range flexion and extension. Total translation was calculated as the sum of all translation seen at levels C2-C3 through C6-C7.

The radiographic reader was blinded to the purpose of the study.

RESULTS

Six-hundred-ninety-two records were collected, with 432 records removed due to incomplete data capture, prior history of a MVC, crash vectors in non-sagittal or coronal planes, or complex crash vectors in more than one plane. Total records in data set were 261 radiographs from 261 unique subjects.

The mean age of the study population was 39.30 (s.d 13.02). The female population totaled 67.4 percent (n=176), while 32.6% (n=85) was male. The time since injury was 1.40 years (s.d. 1.83, range 0.20 to 22.70 years). The collision damage ranged from minimal (6.9%), to moderate (31.4%) to severe (61.7%).

Females showed significantly greater total translation in flexion-extension radiographs when involved in sagittal plane crashes (n=142) when compared to coronal plane crashes (n=34) (total translation was 4.6 mm in sagittal plane and 3.3 mm in coronal plane crashes, $P=0.04$).

Males did not significantly differ in total translation in flexion-extension radiographs when involved in sagittal plane crashes (n=75) compared to coronal plane crashes (n=10) (total translation was 3.16 mm in sagittal plane and 3.70 mm in coronal plane crashes, $P=0.45$).

In a front end collision, males (n=16) and females (n=26) did not differ in total translation in flexion-extension radiographs. In a rear end collision, females (n=103) did differ significantly in total translation in flexion-extension radiographs from their male counterparts (n=48) ($P<0.001$).

DISCUSSION

Women suffer from late whiplash at a higher rate than men and do not recover as quickly (13-18). Several reasons have been postulated. These have included a difference in muscular reaction time and amplitude (19) and greater intervertebral motions during rear impact (20). More recently, it has been postulated that

seat back stiffness in rear impact is higher in proportion to female mass, thus increasing differential acceleration in the cervical spine (21). These findings are consistent with our observations showing that males and females did not differ in total translation in frontal crash vectors, but did differ in rear crashes. In addition, the data demonstrated that while males did not have statistically significant differences in total translation between coronal and sagittal crashes, females did show more sagittal movement on flexion-extension x-rays when they had been exposed to a sagittal crash vector. It is likely that this increased segmental translation has occurred as a consequence of trauma and injury to stabilizing structures within the cervical spine. As already noted, Panjabi et al (2) have reported increases in the "neutral zone" of the cervical spine as a result of trauma, with significant increases noted in the neutral zone with experimental rear accelerations of as low as 4.5 g's. This group has also produced anterior longitudinal ligament strain and rupture in cadavers as a result of simulated whiplash trauma. These injuries produced experimentally would be expected to result in increased total translation as measured here clinically.

The limitations of this investigation include recall bias, the inability to control for all aspects of a "real world" crash, possible reader error, and lack of a normal control group. Recall bias may be a significant issue. Patients were questioned about their visible crash damage many months to years after the event. Recall of these details may be flawed. However, one would expect that with large groups, recall bias in a certain crash vector or toward more severe damage would be either random or uniform in its exaggeration. Since this study focused on comparing one crash vector to another and not in quantifying this damage, these effects likely had little impact on the final data analysis. No study that uses "real world" crash data can control for all variables. For instance, if a patient had his or her head turned at the time of a sagittal crash, a different sub-failure ligament sprain pattern may result than if the head was aligned in a sagittal plane. Again, however, one would expect this type of bias to be random, so in large groups it would likely have little impact on the data. Finally reader error may be an issue. The radiographic reader was asked to measure translation by comparing to a radiographic ruler placed in the same plane as the cervical spine. To reduce the impact of this variable we used a single blinded reader for all films. Any error in one direction or another would then

therefore be random. Lack of a normal control group may be an issue, with the presumption that women may have more total translation than men. However, if this were the case, one would expect to see more total translation in the female groups regardless of impact vector. This is contrary to the reported results, which associate more total translation with an impact vector which would be expected to cause more sagittal ligament injury.

To date many authors have hypothesized about the role of instability in whiplash. However, the presence of more vertebral translation on radiographs of late whiplash patients than in controls does not immediately lend itself to which aspect of the injury caused that instability.

CONCLUSION

This study suggests that the specific forces involved in a crash lead to particular patterns of sub-failure instability in female subjects. This may indicate that the higher degree of ligamentous stretch seen in female cadaver studies may translate to real world crash conditions. For the interventional pain community, this could be important, as only approximately half of all patients with chronic whiplash can be diagnosed as having a facet injury amenable to facet neurotomy (22). This certainly begs the question, "What's wrong with the other half?" Ligament sub-failure instability may help answer that question.

REFERENCES

- Dvorak J, Panjabi MM, Grob D, Novotny JE, Antinnes JA. Clinical validation of functional flexion/extension radiographs of the cervical spine. *Spine*. 1993; 18:120-127.
- Panjabi MM, Nibu K, Cholewicki J. Whiplash injuries and the potential for mechanical instability. *Eur Spine J*. 1998; 7:484-492.
- Ivancic PC, Pearson AM, Panjabi MM, Ito S. Injury of the anterior longitudinal ligament during whiplash simulation. *Eur Spine J* 2004; 13:61-68. Epub 2003 Nov 14.
- Kristjansson E, Leivseth G, Brinckmann P, Frobin W. Increased sagittal plane segmental motion in the lower cervical spine in women with chronic whiplash-associated disorders, grades i-ii: a case-control study using a new measurement protocol. *Spine* 2003; 28:2215-2221.
- Grob D, Dvorak J, Panjabi MM, Antinnes JA. External fixator of the cervical spine—a new diagnostic tool. *Unfallchirurg*. 1993; 96:416-421.
- Ebraheim NA, Xu R, Ahmad M, Heck B, Yeasting RA. The effect of anterior translation of the vertebra on the canal size in the lower cervical spine: a computer-assisted anatomic study. *J Spinal Disord* 1997; 10:162-166.
- Holmes A, Han ZH, Dang GT, Chen ZQ, Wang ZG, Fang J. Changes in cervical canal spinal volume during in vitro flexion-extension. *Spine* 1996; 21:1313-1319.
- Dvorak J, Froehlich D, Penning L, Baumgartner H, Panjabi MM. Functional radiographic diagnosis of the cervical spine: flexion/extension. *Spine* 1988; 13:748-755.
- White AA 3rd, Johnson RM, Panjabi MM, Southwick WO. Biomechanical analysis of clinical stability in the cervical spine. *Clin Orthop*. 1975; 109:85-96.
- Knopp R, Parker J, Tashjian J, Ganz W. Defining radiographic criteria for flexion-extension studies of the cervical spine. *Ann Emerg Med* 2001; 38:31-35.
- Lin RM, Tsai KH, Chu LP, Chang PQ. Characteristics of sagittal vertebral alignment in flexion determined by dynamic radiographs of the cervical spine. *Spine* 2001; 26:256-261.
- Spitzer WO, Skovron ML, Salmi LR, Cassidy JD, Duranceau J, Suissa S, Zeiss E. Scientific monograph of the Quebec Task Force on Whiplash-Associated Disorders: Redefining "whiplash" and its management. *Spine* 1995; (8 Suppl):1S-73S.
- Suissa S. Risk factors of poor prognosis after whiplash injury. *Pain Res Manag* 2003; 8:69-75.
- Sterner Y, Toolanen G, Gerdl B, Hildingsson C. The incidence of whiplash trauma and the effects of different factors on recovery. *J Spinal Disord Tech* 2003; 16:195-199.
- Berglund A, Alfredsson L, Jensen I, Bodin L, Nygren A. Occupant- and crash-related factors associated with the risk of whiplash injury. *Ann Epidemiol* 2003; 13:66-72.
- Suissa S, Harder S, Veilleux M. The relation between initial symptoms and signs and the prognosis of whiplash. *Eur Spine J* 2001; 10:44-49.
- Radanov BP, Sturzenegger M, Di Stefano G. Long-term outcome after whiplash injury. A 2-year follow-up considering features of injury mechanism and somatic, radiologic, and psychosocial findings. *Medicine (Baltimore)*. 1995; 74:281-297. Review.
- Squires B, Gargan MF, Bannister GC. Soft-tissue injuries of the cervical spine. 15-year follow-up. *J Bone Joint Surg Br* 1996; 78:955-957.
- Siegmund GP, Sanderson DJ, Myers BS, Inglis JT. Awareness affects the response of human subjects exposed to a single whiplash-like perturbation. *Spine* 2003; 28:671-679.
- Stemper BD, Yoganandan N, Pintar FA. Gender dependent cervical spine segmental kinematics during whiplash. *J Biomech* 2003; 36:1281-1289.
- Viano DC. Seat influences on female neck responses in rear crashes: A reason why women have higher whiplash rates. *Traffic Inj Prev*. 2003; 4:228-239.
- Barnsley L, Lord SM, Wallis BJ, Bogduk N. The prevalence of chronic cervical zygapophysial joint pain after whiplash. *Spine* 1995; 20:20-26.

