

Technical Update

## Lumbar Retrodisical Transforaminal Injection

Joseph F. Jasper, MD

From: Advanced Pain Medicine  
Physicians, Tacoma, WA.

Dr. Jasper is Medical Director,  
Advanced Pain Medicine Physicians,  
Tacoma, WA

Address Correspondence:  
Joseph F. Jasper, MD  
1628 South Mildred St., #105  
Tacoma, WA 98465-1613  
Email: apmedicine@qwest.net

Disclaimer: There was no external  
funding in preparation of this  
manuscript.  
Conflict of interest: None

Manuscript received: 9/05/2006  
Revisions accepted: 1/23/2007  
Accepted for Publication:  
4/05/2007

Free Full manuscript:  
[www.painphysicianjournal.com](http://www.painphysicianjournal.com)

**Background:** Spinal injections are commonly used to treat lumbar radiculitis and back pain. Delivery of medication to specific targeted pathology is considered important for a successful therapeutic outcome. A variety of routes of injection have been devised for epidural injection of corticosteroid.

**Objectives:** The author demonstrates a variation of the transforaminal injection technique. The radiographic spread of contrast is described using a more oblique and ventral caudad approach in the epidural space "retrodisical." It is suggested that the radiographic findings of this technique for discogenic causes of induced radiculitis and/or back pain may yield more precise targeting of putative pathologic sources of radiculopathy and back pain in selected patients.

**Methods:** In patients with disc pathology and radiculitis, the anatomy of the lumbar epidural space is reviewed for its potential effect on the flow of injectate. Contrast spread was documented for lumbar transforaminal injection using a needle placement more oblique and behind the disc rather than in the cranial portion. Comparison is made to a typical contrast spread of an infra-pedicular placed transforaminal injection.

**Results:** Retrodisical contrast injection results in reliable coverage of the retrodisical region, the exiting nerve at that foraminal level and the proximal portion of the transiting segmental neural sleeve.

**Conclusions:** The radiographic findings demonstrate a difference between classic infra-pedicular versus retrodisical transforaminal epidural contrast injection patterns, particularly at relatively low volumes. The clinical advantage of one technique versus the other should be established in randomized prospective studies.

**Key words:** Spinal, injection, corticosteroid, adhesions, disc, herniation, radiculitis, pain, lumbar, transforaminal, radicular, discogenic, retrodisical, contrast

**Pain Physician 2007; 10:501-510**

**E**pidural corticosteroid injections (ESI) may be used to treat lumbar radiculopathy or back pain due to disc pathology (1). The traditional approaches are across the interlaminar and yellow ligaments (2) or caudal (3) with or without directional catheters; transforaminal injections (4) may be used to target known irritated nerve roots with steroid injection or for diagnosis with selective neural blockade (5). Therapeutic epidural corticosteroids are thought to be most effective when the affected nerve root and its source of irritation are targeted as specifically as possible. Abdi et al (1) performed comprehensive review of the evidence utilizing Agency for Healthcare Research and Quality (AHRQ) criteria for observational studies and AHRQ and Cochrane review for criteria for randomized trials. This review showed the evidence for caudal epidural steroid injections is strong for short-term relief and moderate for long-term relief in managing chronic low back and radicular pain, and limited in managing pain of post lumbar laminectomy syndrome. The evidence for interlaminar epidural steroid injections is strong for short-term relief and limited for long-term relief in managing lumbar radiculopathy. In contrast, the evidence for lumbar transforaminal epidural steroid injections is strong for short-term and moderate for long-term improvement in managing lumbar nerve root pain.

Epidural anatomy and pathologic conditions will affect the spread of an injectate. Fluids follow the path of least resistance. The epidural space is not a simple open cylinder with negligible and even internal resistance. It is a potential space that is in part filled with varying amounts of fat, blood vessels, neural structures contained within dural sheaths, and significant connective tissues. The connective tissues consist of some organized structures and some less distinct membranous attachments. A well recognized example of organized structures includes a fold of the dura known as the plica mediana dorsalis (6,7). Bogduk described many of the epidural and spinal connective tissues (8). These included dorsal median and lateral tissues within the epidural space. Many of these may be coalescences or artifacts of displaced epidural membranous tissues. He also describes some false ligaments. There appears to be significant variation in the density of some of these connective tissue barriers, sometimes presenting significant barriers to flow and sometimes not. Common contrast patterns reveal 3 "compartments" of the epidural space: dorsal, ventral, and lateral (9,10). It has been demonstrated and commonly

observed that interlaminar injections are unilateral in 86% of patients and only reach the ventral epidural space in 36% (11). Most often lumbar interlaminar injections appear unilateral, largely due to: dorsally by the plica mediana dorsalis (6); ventrally by the median raphe between the posterior longitudinal ligament (PLL) and the disc; and another which may be present between the dura and the PLL. In pathologic conditions both induration and adhesions will further limit the flow of injectate (9,10,12). Leakage of pathologic discs contains glycoprotein (13) and antigens (14) that cause inflammatory reactions even in the absence of mechanical compression, which may also be present. Scar tissue may also form. All these factors may yield back pain and radicular symptoms.

When properly performed, transforaminal injections should result in ventro-lateral contrast spread along the segmental nerve (15-17). The target is the segmental nerve (and dorsal root ganglion) within the radicular canal. However, classic transforaminal injections are made into the third segment of the radicular canal and foramen, which does typically cover the dorsal root ganglion, yet frequently will fail to flow centrally toward the midline or reach the first segment of the radicular canal which is retrodiscal, and may fail to flow caudad across the disc below. Clearly the technique of adding a transforaminal catheter improved the mesial flow with adhesiolysis (18).

The caudal approach may reach ventral targets by high volume techniques which dilute delivered medications and impact a large swath of the epidural space (19). Caudal techniques with directional catheters (20-22) intended to reach ventral targets may meet obstruction particularly about the L5-S1 lordosis, plus add significant cost.

Frequently, a paracentral disc at one intervertebral level is affecting the nerve root exiting at a foraminal level below, while lateral disc pathology may affect the segmental nerve at the same foramen (Figs. 1-3). An optimally placed injection should cover the region of disc pathology, the disc nerve interface and the irritated segmental nerve. For example, a traditional transforaminal injection for a right L5 radiculopathy is placed with a 20 degree off the AP lateral oblique needle approach to the "safe" triangle in the ventral and cranial aspect of the L5-S1 foramen approximately 6 o'clock on the L5 pedicle in the direct AP view. Transforaminal injections, as traditionally taught, are typically made with steep angle needle approaches and low volumes of 0.5 -1.5

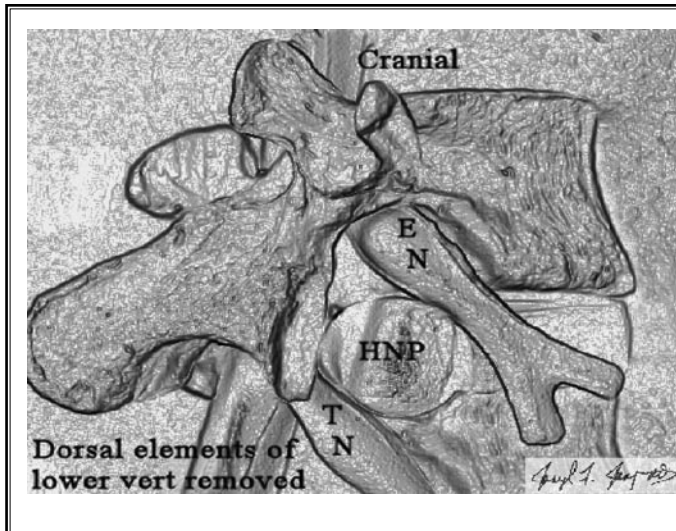


Fig. 1. Oblique view of the spine model with the dorsal elements of the lower vertebra removed and demonstrating the relationship of a herniated nucleus pulposa (HNP) at L4-5 to the L4 segmental exiting nerve (EN) at the L4-5 foramen and the L5 transiting nerve (TN) exiting a level below.

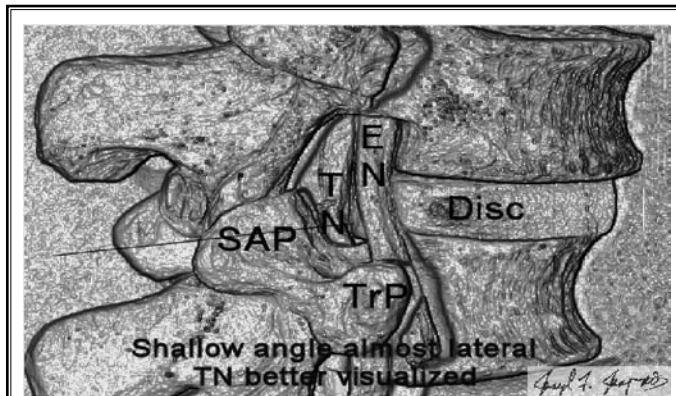


Fig. 2. Almost lateral view of the spine model demonstrating the relationship of the exiting nerve (EN), transiting nerve (TN) and the disc. Superior articular process (SAP); transverse process (TrP).

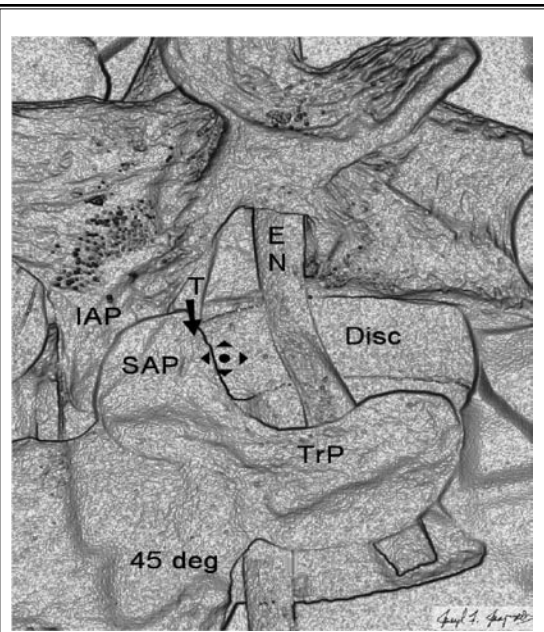


Fig. 3. The spine model in a 45-degree oblique demonstrates the landmarks commonly seen during discography and used for retrodiscal injection. Superior articular process (SAP); transverse process (TrP), disc, and inferior articular process (IAP) are in relationship to the exiting nerve (EN) and transiting nerve (T). The cross hairs mark the target for the needle placement down the x-ray beam.

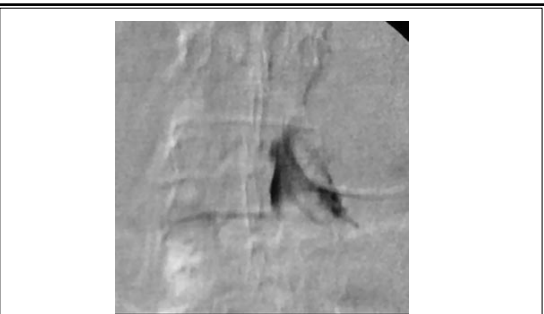


Fig. 4. Classic low volume transforaminal epidural contrast injection after washout (.75 mL each of contrast, followed by local anesthetic and corticosteroid).

mL each of contrast, local anesthetic and corticosteroid (Celestone Soluspan). Such injections frequently cover the L5 segmental nerve in the second and third portions of the radicular canal, yet often fail to cover with the steroid suspension the first segment where the L4-5 or L5-S1 disc interspaces are and the putative source pathology lies, although the marginal washout of contrast may just reach these areas (Fig. 4). While varying from the classic and specific transforaminal technique, increased volumes will sometimes

reach disc interspaces. Higher volumes decrease the specificity and thus the utility of such technique as a selective nerve root block, but may increase its utility as a therapeutic injection. Spread with the increased volume may be unpredictable, but tends to travel craniad more often than caudad. Further, the "safe" triangle is not always safe: there is a risk of

arterial injection or nerve damage particularly when stenotic or post operative conditions exist; safety is as much a function of safe practices as anatomy. Even in normal subjects the radicular arteries are bundled with the segmental nerve in the cranial portion of the foramen; however small arterioles may exist at other levels for metaphyseal branches (23); observation of contrast flow under live digital subtraction is essential to performing all transforaminal injections safely.

The author uses retrodiscal transforaminal injections with and without catheters to obtain a theoretically advantageous placement of epidural corticosteroid. The retrodiscal transforaminal approach is identical to that used for provocation discography, but stopping short of disc entry. Epidurography of such injections does demonstrate that this approach more frequently achieves coverage of both the putative disc source of nerve irritation and of the affected segmental nerve.

## **METHODS**

In this retrospective study of patients with disc pathology and radiculitis, contrast spread was documented with lumbar transforaminal injections using needle placement more oblique and posterior to the disc. Comparison is made to the typical contrast spread of infra-pedicular placed transforaminal injections. All injections were performed by the author at West Tacoma Surgery Center, following appropriate patient informed consent.

The positioning of the patient and C-arm (GE OEC 9800 with DSA) are similar to lumbar discography. The patient is placed prone on the x-ray table top padded to provide flattening of the lumbar lordosis. The back is prepped with povidone iodine and alcohol. The targeted disc's endplates are aligned as for discography with appropriate caudal or cranial tilt of the C-arm. The beam is then rotated so that the lateral surface of the superior articular process (SAP) bisects the interspace, typically 40-45 degrees off the AP axis. Skin and deep tissue anesthesia as far as the dorsal surface of the SAP is placed with buffered 0.5% lidocaine. A 7-inch Pajunk Tuohy 17g needle is advanced slowly and cautiously past the SAP lateral surface. One should avoid penetration of both the segmental nerve and the disc. The lateral radiograph should also be used while advancing past the SAP to minimize the risk of disc penetration, while the resistance to needle advancement is also used as a sign

to stop. The AP view will most often demonstrate the tip in the interpedicular line. A small amount of contrast is used to confirm ventral epidural spread on the lateral without subarachnoid, vascular, or intradiscal spread. If a discogram is apparent, one may record the result, but then pull the needle back until contrast is no longer intradiscal. Use of blunt needles should significantly reduce the risk of intradiscal injection. Large foraminally sequestered soft discs will increase the risk of disc injection. Single shot disk level transforaminal injection may be performed through the needle with 1-3 mL of contrast; if this is adequate in covering the target this is followed by 0.75-1.5 mL of local anesthetic and 1-2 mL of corticosteroid. Volumes needed may be determined by the contrast volume required to achieve the desired coverage. However, the particulate corticosteroids will remain close to the needle tip and are not likely spread as far as the contrast margins (6,9).

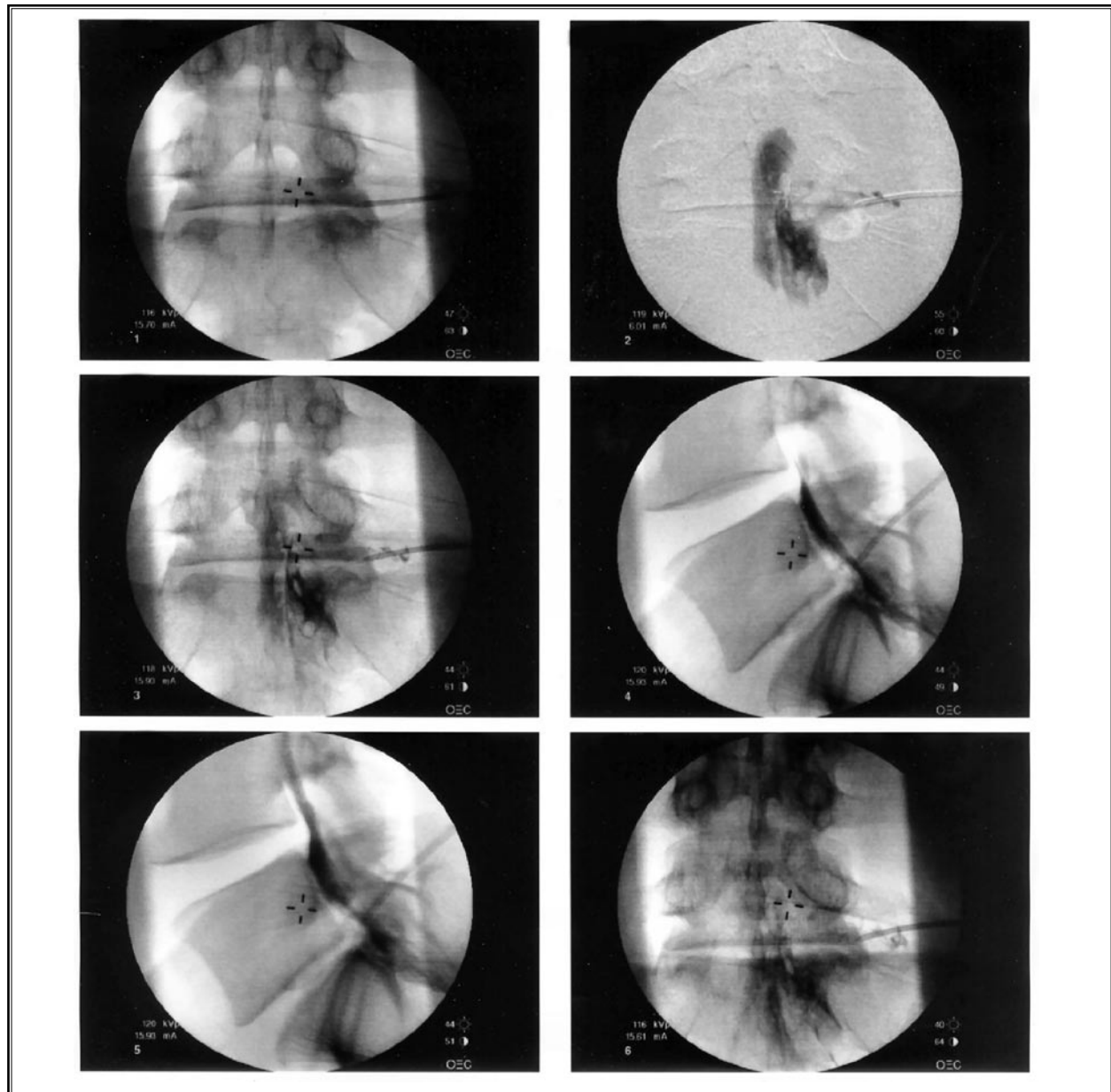
If the flow to targets is inadequate, a bent tip stylet-epidural catheter (Spinal Specialties 19g closed tip stylet catheter) may be guided across the ventral epidural disc interspace to reach a central or paracentral position. The needle may have to be slightly withdrawn dorsa-laterally in the foramen using a push-pull technique to keep the catheter ventral and to facilitate catheter introduction. When possible the catheter may be advanced mesial up to the midline. Catheter insertion may be difficult; an even shallower angle of approach may be necessary to achieve this either by approaching from 50 degrees oblique of the midline or by using a curved blunt needle. The catheter's stylet is then removed and a catheter injection adapter attached. Similar volumes of injectate and medications are used as in the single shot method.

Injection of contrast should not fill a vascular or subarachnoid pattern regardless of the epidural injection technique. Contrast should flow centrally across the disc interspace toward the midline, down around the pedicle below and then at least along the proximal segmental nerve toward its foraminal entry. Contrast is more often than not seen flowing along the segmental nerve just above the needle as well. Contrast tends to flow into the central ventral and lateral epidural compartments; the degree of such spread is dependent upon volume and or use of catheter and how centrally the catheter is advanced. Contrast should at least initially be evident in the ventral epidural space under the lateral view and may outline an extrinsic mass effect or filling defect.

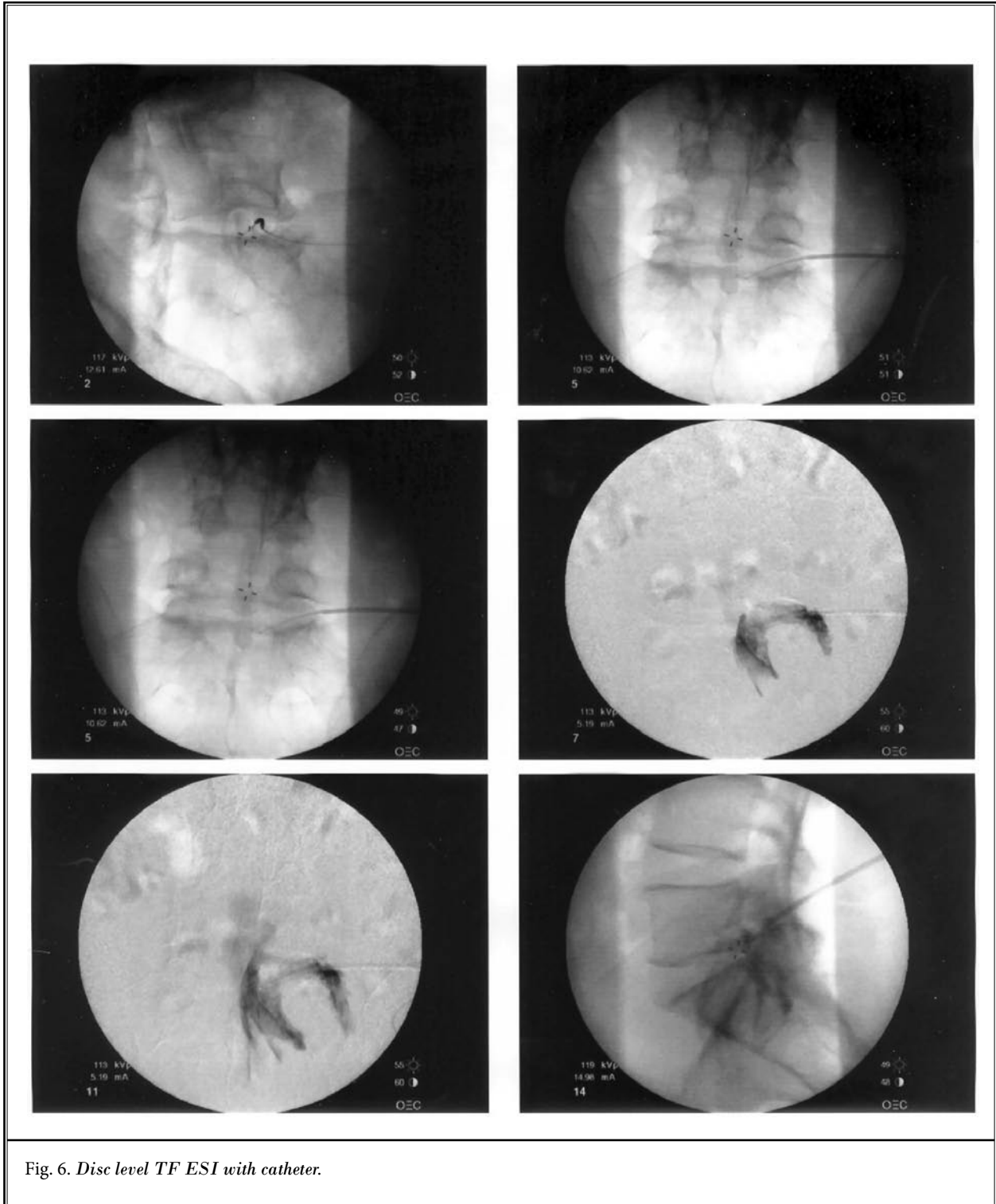
## RESULTS

Contrast studies are demonstrated below for traditional low volume selective transforaminal and for the disc level transforaminal injections. It is apparent that traditional infra-pedicular transforaminal injections (Fig. 4) cover the dorsal root ganglion in the foramen

and the parapedicular portion of the radicular canal but often not the retrodiscal portion. By comparison, the retrodiscal approach provides better coverage of the retrodiscal space and affected nerve's interface with the pathologic disc, but often less coverage of the transiting nerve's foraminal portion (Figs. 5-7). Pa-



*Fig. 5. Retrodiscal injection L5-S1. Retrodiscal injection L5-S1 right. Ventral filling is evidenced by the adherence of contrast behind the vertebral bodies of L5 and S1 and absence of filling in the dorsal two-thirds of the canal. The nodal impression upon the ventral epidural outline is typically due to disc protrusion, thickening of PLL, induration and/or scar tissue. During the procedure the needle is tactilely placed against the herniated annular wall; any further would be intradiscal. The fact that the contrast is ventral above and below the needle confirms that injectate is flowing into the ventral compartment*



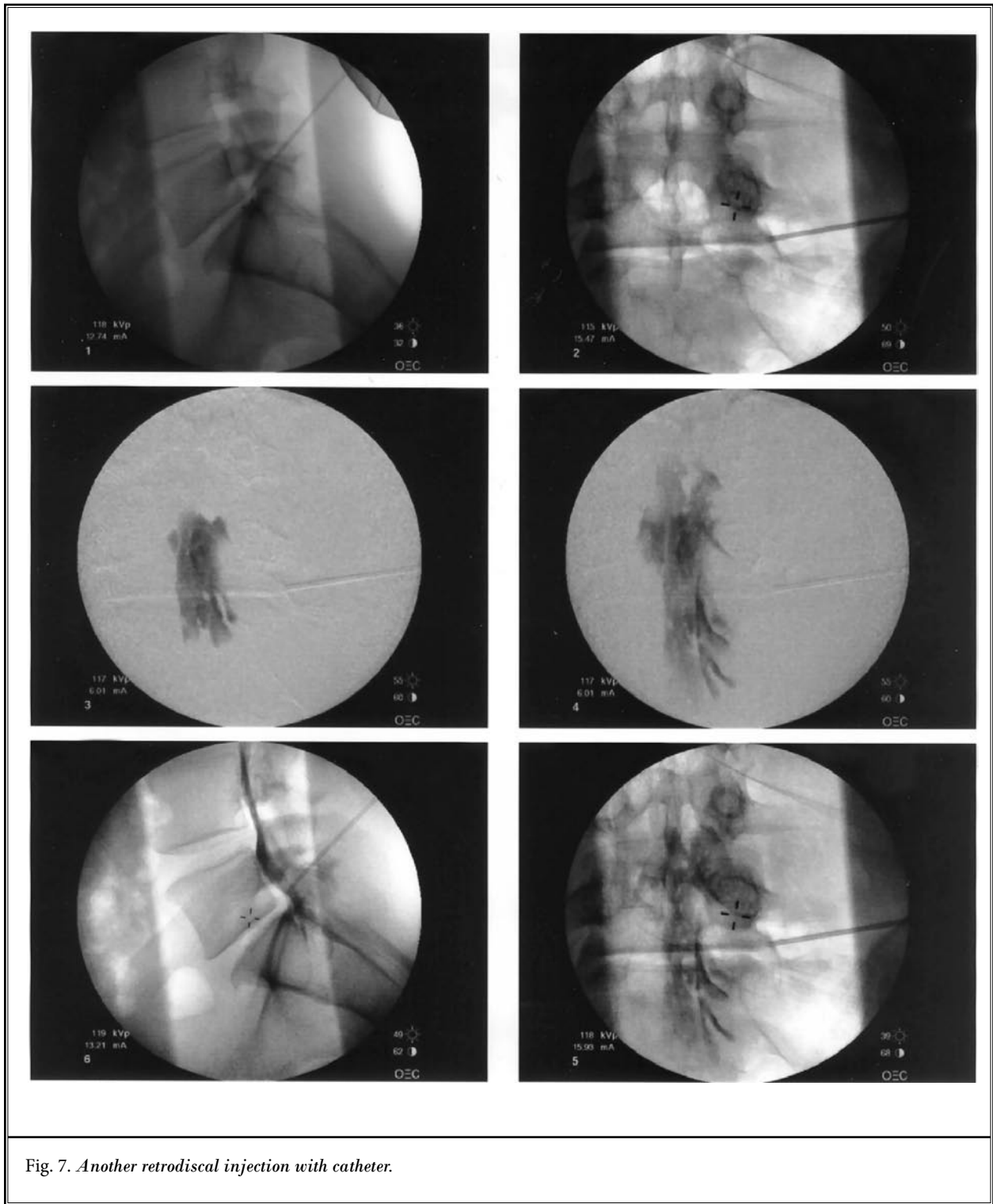


Fig. 7. Another retrodiscal injection with catheter.

tients with back pain and/or radiculitis treated with retrodiscal injections appear to achieve relief in the local anesthetic phase and corticosteroid phase, similar to other approaches. Data were not collected to determine quantity, frequency, and duration of improvement in symptoms with this technique versus other approaches. No measurement tools were applied.

One patient (Fig. 8) presented with back pain greater than sciatica and had 2 pathologic discs by MRI which might explain his lumbar pain. Provocation response with injection of 0.5 mL contrast through needles placed at each disc level was performed. This provided a distinct concordant (agrees with usual pain pattern) and discordant (produces pain but in unfamiliar location) responses that would be useful in diagnosis and future treatment planning.

## DISCUSSION

The interventional pain physician frequently seeks to deliver therapeutic epidural injections for patients suffering sciatica or lumbar pain due to disc pathology. The results noted in this paper are encouraging that superior techniques of delivery may exist.

This study does not present data of functional improvement or pain relief of the retrodiscal approach versus other. It is a simple contrast demonstration. Further comparative and controlled studies are required to establish whether this results in better success in treating radiculopathy or back pain, and if it helps reduce the need for surgery.

This is not an approach for highly selective nerve block.

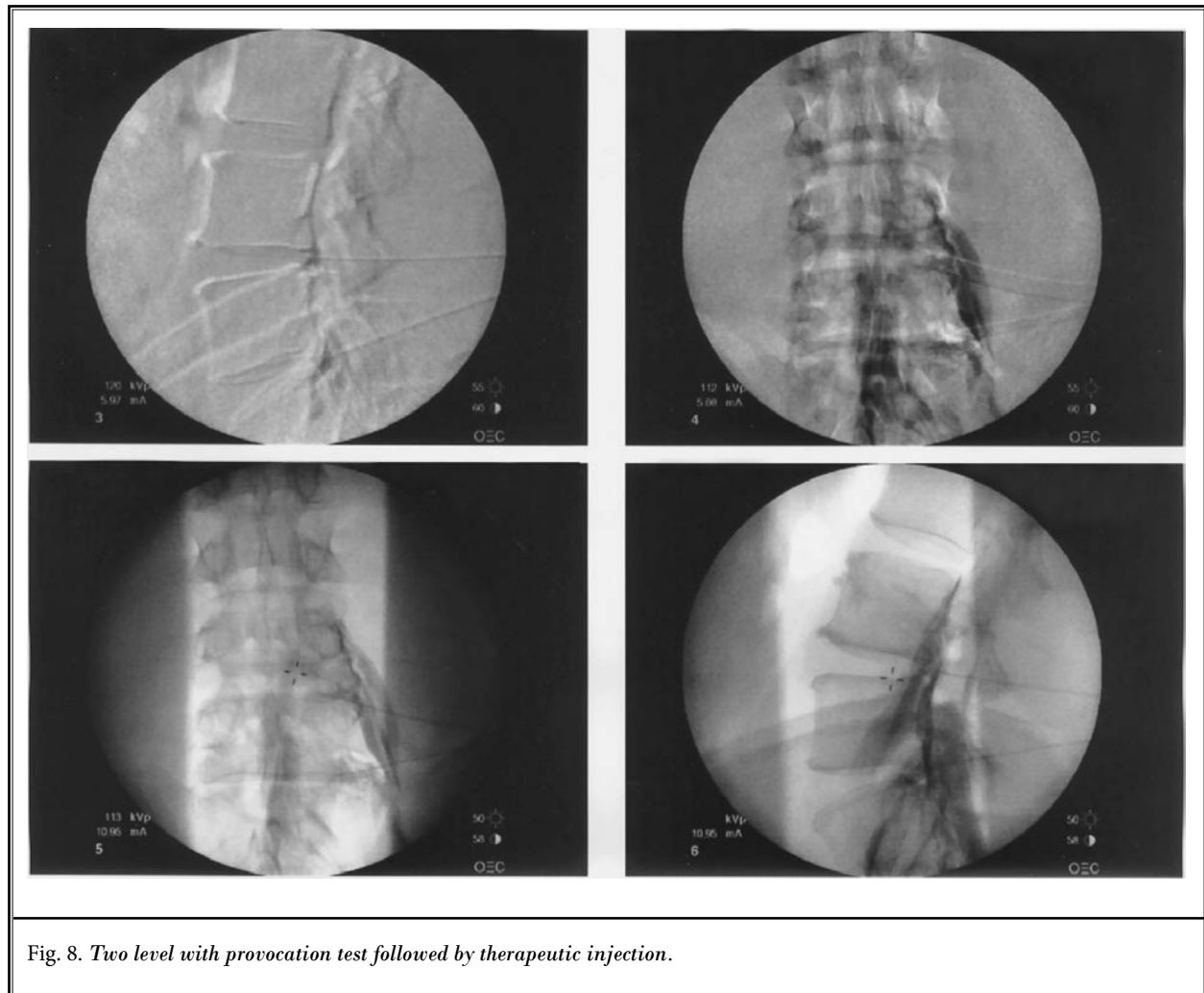


Fig. 8. Two level with provocation test followed by therapeutic injection.



There is risk of intradiscal injection which is of low morbidity and may be reduced with careful technique and the choice of a blunt tipped needle and even less with a catheter. To avoid damaging the segmental nerve, as with discography, one must be cautious to avoid anesthetizing the segmental nerve during procedural anesthesia or over-sedating the patient. Stenotic foramina present a higher risk for complications of transforaminal injections due to displacement of the nerve, arteries, osteophytes, and a loss of foramina fat; this situation may call for a safe triangle approach over a disc level approach, or a catheter placed from above or below the stenotic level.

As with other spinal injections there exists risk of infection, bleeding, dural puncture, aggravation of pain, adverse drug reactions, spinal anesthesia with its attendant risks, and failure to achieve benefit. If properly performed, devastating complications should be avoidable.

Epidural anatomy is complex with multiple potential barriers to the spread of injectates, further complicated by the presence of induration, mass effect, or scar. The importance of target specific injection of corticosteroids has been suggested but remains controversial (22). If the theory of target specific injection is correct, then there may be an advantage to deliver injections to the disc-nerve interface, rather than more distal sites.

Concern has been raised with transforaminal epidural corticosteroid injection regarding the risk of arterial injection and resultant paralysis (22). As a result, in recent ASIPP instructional workshops, Racz has suggested the use of a blunt needle slightly oblique approach glancing past the superior articular process (SAP) to the dorsal foramen below the pedicle followed by placement of a spring tip catheter along the affected segmental nerve. His theory is that the use of blunt instruments and dorsal placement will reduce or eliminate radicular arterial complications. This is a familiar technique. Hammer described the use of Tuohy

needles and catheters to perform transforaminal ventral epidural adhesiolysis in 14 post laminectomy patients (16,23). His technique utilized the classic infra-pedicular needle approach and catheter placement tracking along the segmental nerve cranial-medially and ventrally. The technique of retrodiscal injection described here respects the recommended use of blunt needles, but uses Tuohy needles rather than Racz Coude needles. Further, arterial supply tends to enter in the cranial foramen rather than inferior; thus, retrodiscal injection in the inferior foramen may have lower risk of radicular arterial injection. One should not be any less vigilant in the retrodiscal injection.

This technique is only being investigated for use in the lumbar region. Additional risk is present in the thoracic and cervical regions and is not advisable. In the thoracic region risk is increased due to the presence of the anterior spinal artery, spinal cord, and pleura. In the neck there is increased risk due to the vertebral artery, spinal cord, and increased difficulty recognizing ventral subarachnoid injection.

### **CONCLUSION**

The classic transforaminal epidural injection technique is taught with an infra-pedicular injection of relatively small volumes of medications to preserve the specificity of the nerve block.

The author has demonstrated an alternative retrodiscal approach for therapeutic transforaminal epidural injections that achieves coverage of both the intervertebral disc level and the affected segmental nerve. Thus the retrodiscal technique achieves superior placement of therapeutic injections such as corticosteroids when the target of the injection is the pathologic disc-nerve interface.

Further comparative and controlled studies are required to establish whether this results in better success in treating radiculopathy or back pain, and if it helps reduce the need for surgery.

## REFERENCES

1. Abdi S, Datta S, Trescot AM, Schulz DM, Adlaka R, Atluri SL, Smith HS, Manchikanti L. Epidural steroids in the management of chronic spinal pain: A systematic review. *Pain Physician* 2007; 10:185-212.
2. Gerest F. Treatment of sciatic neuralgia by epidural injections of hydrocortisone. *J Med Lyon* 1958; 39:261-264.
3. Lindgolm SR, Salenius P. Caudal epidural administration of anaesthetics and corticoids in the treatment of low back pain. *Acta Orthop Scand* 1964; 34:114-116.
4. DePalma MJ, Bhargava A, Slipman CW. A critical appraisal of the evidence for selective injection in the treatment of lumbosacral radiculopathy. *Arch Phys Med Rehabil* 2005; 86:1477-1483.
5. Datta S, Everett CR, Trescot AM, Schulz DM, Adlaka R, Abdi S, Atluri SL, Smith HS, Shah RV. An updated systematic review of diagnostic utility of selective nerve root blocks. *Pain Physician* 2007; 10:113-128.
6. Jasper JF. Evaluation of fluoroscopic caudal epidural injections. *Pain Physician* 2004;7:287-288.
7. Luyendijk W. The plica mediana dorsalis of the dura mater and its relation to lumbar peridurography (canalography) *Neuroradiology* 1976; 11:147-149.
8. Bogduk N. *Clinical Anatomy of the Lumbar Spine and Sacrum*. 3rd edition. Churchill Livingstone, London 1997, pp 52-53, 59-60, 131-132.
9. Songer MH, Ghosh L, Spencer DL. Effects of sodium hyaluronate on peridural fibrosis after lumbar laminectomy and discectomy. *Spine* 1990; 15:550-554.
10. Key JA, Ford LT. Experimental intervertebral disc lesions. *J Bone Joint Surg Am* 1948; 30A:621-630.
11. Botwin KP, Natalicchio J, Hann A. Fluoroscopic guided interlaminar epidural injections: A prospective evaluation of epidurography contrast patterns and anatomical review of the epidural space. *Pain Physician* 2004; 7: 77-80.
12. Kuslich SD, Ulstrom CL, Michael CJ. The tissue origin of low back pain and sciatica. *Ortho Clin North Am* 1991; 22:181-187.
13. Marshall LL, Trethewie ER. Chemical irritation of nerve root in prolapsed disc. *Lancet* 1973; 2:320.
14. Naylor A, Happey F, Turner RL, Shentall RD, West DC, Richardson C. Enzymatic and immunological activity in the intervertebral disc. *Orthop Clin North Am* 1975; 6:51-58.
15. Andrade A, Eckman E. The distribution of radiographic contrast media by lumbar translaminar and selective neural canals in normal human volunteers. In Proceedings of the Annual Meeting of the International Spinal Injection Society. Keystone, CO, January 1992.
16. Hammer M, Doleys DM, Chung OY. Transforaminal ventral epidural adhesiolysis. *Pain Physician* 2001; 4:273-279.
17. Manchikanti L, Cash KA, Pampati V, McManus CD, Damron KS. Evaluation of fluoroscopically guided caudal epidural injections. *Pain Physician* 2004; 7:81-92.
18. Racz GB, Heavner JE, Diede JH. Lysis of epidural adhesions utilizing the epidural approach. In Waldman SD, Winnie AP (eds.) *Interventional Pain Management*. Philadelphia, WB Sanders, 1996, 339-351.
19. Racz GB, Holubec JT. Lysis of adhesions in the epidural space. In Racz GB (ed.) *Techniques of Neurolysis*. Boston; Kluwer Academic Publishers. 1998, pp 57-62.
20. Dashfield AK, Taylor MB, Cleaver JS, Farrow D. Comparison of caudal steroid epidural with targeted steroid placement during spinal endoscopy for chronic sciatica: A prospective, randomized, double-blind trial. *Br J Anaesth* 2005; 94:514-519.
21. Bogduk N. *Clinical Anatomy of the Lumbar Spine and Sacrum*. 3rd edition. Churchill Livingstone, London 1997, pp 146, 147, 151.
22. Helm S, Jasper JF, Racz G. Complications of transforaminal epidural injections. *Pain Physician* 2003; 6:389-390.
23. Hammer M. Lysis of post surgical scar tissue in the anterior epidural space via a transforaminal approach. In Proceedings of the International Spinal Injection Society; Fourth Annual Meeting. Vancouver, British Columbia 1996