

Systematic Review

Accuracy of Imaging in Dynamic Spondylolisthesis: Emerging Strategies and Understanding for Pain Physicians: A Systematic Review

Mihir Jani, MD¹, Eli Dayon, DO², Nimesha Mehta, DO¹, Kunal Aggarwal, MD¹, Joseph D. Fortin, DO³, Karolina Zektser, DO⁴, Joshua Lewis MD, PhD¹, Marco Lawandy, DO¹, Ricky Ju, DO², Ugur, Yener, MD¹, Jonathan D. Krystal, MD⁵, Reza Yassari, MD⁶, Alan D. Kaye, MD, PhD⁷, and Sayed E. Wahezi, MD¹

From: ¹Dept. of Physical Medicine & Rehabilitation, Montefiore Medical Center/Albert Einstein School of Medicine, Bronx, NY; ²Dept. of Physical Medicine & Rehabilitation, Burke Rehabilitation Hospital, White Plains, NY; ³Indiana University School of Medicine/Spine Technology and Rehabilitation, Fort Wayne, IN; ⁴Dept. of Physical Medicine & Rehabilitation, Stony Brook University Hospital, Stony Brook, NY; ⁵Dept. of Orthopedics, Montefiore Medical Center/Albert Einstein School of Medicine, Bronx, NY; ⁶Dept. of Neurosurgery, Montefiore Medical Center/Albert Einstein School of Medicine, Bronx, NY; ⁷Louisiana State University Health Sciences Center Shreveport, Shreveport, LA

Address Correspondence:
Sayed E. Wahezi, MD
Dept. of Physical Medicine & Rehabilitation, Montefiore Medical Center, 1250 Waters Place, Tower #2, 8th Floor
Bronx, NY 10461
E-mail: swahezi@montefiore.org

Disclaimer: There was no external funding in the preparation of this article.

Conflict of interest: See pg. 102 for COI information.

Article received: 08-14-2024
Revised article received: 09-11-2024
Accepted for publication: 11-11-2024

Free full article:
www.painphysicianjournal.com

Background: Chronic low back pain (CLBP) is prevalent, with lumbar spondylolisthesis a common cause of the condition. Spondylolisthesis, the displacement of one vertebra over another, can have various causes. Isthmic and degenerative forms are the most common. Clinicians need to evaluate whether the condition is fixed or dynamic, since dynamic cases may cause vertebral instability and nerve compression, necessitating surgery. Traditional flexion-extension x-rays have been the standard diagnostic tool, but recent studies suggest that alternative imaging methods, such as magnetic resonance imaging or computed tomography, may offer more accurate detection.

Objective: Spondylolisthesis, often described as the slipping forward of one of the vertebrae, is a common etiology for CLBP. Generally, spondylolisthesis can be categorized as either stable or unstable. Unstable or dynamic spondylolisthesis is usually diagnosed based on the visualization of sagittal translation of the vertebral body on flexion-extension x-rays. However, it has been reported that flexion-extension x-rays may not be the most reliable method for determining the presence of an unstable spondylolisthesis. The present investigation aimed to identify the extent of the literature that discussed alternative imaging techniques for diagnosing dynamic spondylolisthesis.

Study Design: A retrospective systematic review of original research done on spondylolisthesis from 2000 to 2023.

Methods: A review protocol was followed based on PRISMA guidelines and conducted across 3 databases for relevant articles published between the years 2000 and 2023. Two reviewers screened and characterized the articles independently, and 3 additional reviewers performed full-text analysis and data extraction.

Results: The search yielded 13 articles with differences in origin, study design, sample size, and outcomes. Most of the articles were retrospective studies. Of the 13 articles, 11 showed promising results in utilizing alternative imaging to diagnose dynamic spondylolisthesis.

Limitations: The lack of a formally registered protocol and potential publication bias were the limitations for this review.

Conclusion: The present investigation analyzed the current literature and determined that alternative imaging techniques could adequately diagnose the dynamic instability of the spine. Further research is warranted to establish an in-depth analysis that elucidates the most reliable and sensitive imaging sequence for diagnosing dynamic spondylolisthesis.

Key words: Spondylolisthesis, dynamic spondylolisthesis, unstable spondylolisthesis, vertebrae

Pain Physician 2025; 28:97-103

Chronic low back pain (CLBP) is a common ailment with a lifetime prevalence of roughly 84% (1,2). Unfortunately, the constellation of symptoms involved in CLBP has many overlapping etiologies, making diagnosis difficult for even adept clinicians. One common cause of CLBP is lumbar spondylolisthesis. This pathology is defined as the displacement of one vertebral body over the vertebral body segment below it and is further classified by 6 etiologies.

The most common subtypes of spondylolisthesis are isthmic and degenerative spondylolisthesis. Isthmic spondylolisthesis, which occurs secondarily to deformities in the pars interarticularis and in community-based populations within the United States, has been demonstrated to have a prevalence of 8% (3). In contrast, degenerative spondylolisthesis has been estimated to have a prevalence of 20-31% among community-dwelling adults and is held to be secondary to progressive degeneration of the facet joints (3,4).

Regardless of its etiology, any case of spondylolisthesis must be carefully evaluated by clinicians to determine whether the condition is fixed or dynamic. Dynamic spondylolisthesis may demonstrate vertebral instability, which, under increased mechanical loads or positional changes, may lead to the compression of nerve roots, resulting in low back and leg pain. Thus, it is necessary to assess vertebral stability correctly, since doing so provides crucial information regarding the need for surgical intervention.

Flexion and extension x-rays have long been considered the gold standard for diagnosing spondylolisthesis. However, recent studies have demonstrated that these traditional imaging techniques may miss many cases of dynamic spondylolisthesis (5). This limitation prompted our investigation into alternative imaging modalities. Our intention was to determine if they could provide more accurate detection of spondylolisthesis than could flexion/extension x-rays. The present investigation, therefore, aims to compare the effectiveness of supine magnetic resonance imaging (MRI) or computed tomography (CT) to that of standing imaging modalities in diagnosing dynamic spondylolisthesis, elucidating potential alternatives to traditional flexion-extension x-rays.

METHODS

The present investigation utilized current literature comparing supine and standing imaging to gold-standard flexion and extension imaging in diagnosing

dynamic spondylolisthesis. The study was conducted with the Preferred Reporting Items for Systematic Reviews and Meta-Analyses extension for Scoping Reviews (PRISMA-ScR) protocol (Fig. 1).

No protocol was formally registered for this review. The search was conducted using MeSH terms. The search query used was "(spondylolisthesis) AND (dynamic or instability) AND (supine or MRI or CT) AND (standing or x-ray)." PubMed, Scopus, and Web of Science were the databases used in gathering the relevant articles. All articles, regardless of evidence type, were included as long as the following criteria were met: a publication date between January 2000 and December 2023, availability in English, evaluation of a diagnosis of lumbar instability, and an investigation of the reliability of an imaging modality in identifying instability. Two reviewers (MJ and ED) screened articles independently based on their titles and abstracts. Disagreement on whether to include an article was handled through a third, unbiased reviewer (NM). After the initial screening, 3 reviewers (NM, KA, KZ) were tasked with full-text read-through and data extraction.

RESULTS

The initial search query among the 3 databases resulted in 131 articles. After title analysis and the removal of duplications, 56 articles remained. A secondary screening was conducted by reading each abstract, during which process an additional 38 articles were screened out. Eighteen articles were included for full-text analysis and data extraction. Of the 18 articles, an additional 5 were screened out. Two of the 4 articles were removed, either because they did not compare an alternative imaging modality to flexion-extension imaging or because they lacked an independent analysis of each pair of imaging techniques. The remaining 3 articles were excluded as follows: 2 for being case reports and one for containing redundant data.

Among the 13 articles, 5 assessed the difference in sagittal translation among flexion-extension x-rays and supine-standing films, as depicted in Table 1 (6-10). Of those 5 articles, 3 reported a significantly greater difference in translation with supine-standing films in comparison to flexion-extension x-rays (6-8). Two of the 6 articles that assessed sagittal translation between flexion-extension and standing-supine imaging showed conflicting results (9,10). Fujimoto et al (9) showed a statistically significant difference in translation with flexion-extension x-rays. Although Fujimoto et al (9) showed results that were inconsistent with the

other 3 articles (6-8), it is notable that only 31 patients were assessed in that retrospective study. In the study conducted by Thompson et al (10), various pairings of radiographic imaging were assessed, including the flexion-extension, standing-supine, and flexion-supine varieties. Among the 3 pairs, no significant difference between the magnitude of sagittal translation in flexion-extension and that of standing-supine films was detected. However, like the project undertaken by Fujimoto et al, Thompson et al's study was also limited to a small sample size, this one comprising 25 patients (10).

The remaining 8 articles did not directly assess sagittal translation between standing flexion-extension x-rays and standing-supine films (Table 2) (5,11-17). However, those articles did investigate alternative imaging techniques for diagnosing spondylolisthesis.

Fong et al (11) showed evidence that flexion-extension films underreported unstable lumbar degenerative spondylolisthesis. A group of 225 patients were initially deemed stable according to flexion-extension radiographs. Additional pairs of dynamic images that included standing lateral radiographs and supine CT imaging found that 37% of those patients' spines showed sagittal translation of greater than 3.5 mm or angulation of more than 11 degrees, meaning that said patients had unstable lumbar spondylolisthesis.

Lee et al (5) compared the slip percentage seen in flexion-supine and neutral supine-standing imaging with that of flexion-extension x-rays and found that both of the former groups detected a statistically significant greater amount of ventral instability than did flexion-extension. Similarly, Zhou et al (12) examined differences in translation range of motion and frequency of detection of instability in flexion-extension imaging in different positions. Both teams of researchers found that the combinations of imaging techniques—flexion and supine as well as flexion and decubitus imaging—allowed larger translational ranges of motion and were better at detecting segmental instability than flexion-extension

radiographs. Those conclusions were further supported by Tarpada et al (13). In the 59 patients they assessed, supine lateral radiographs demonstrated significantly higher means of translation than did flexion-extension radiographs (7.83% +/- 4.67% vs. 5.53% +/- 4.11%; $P < 0.00133$) (13). The authors were able to conclude that

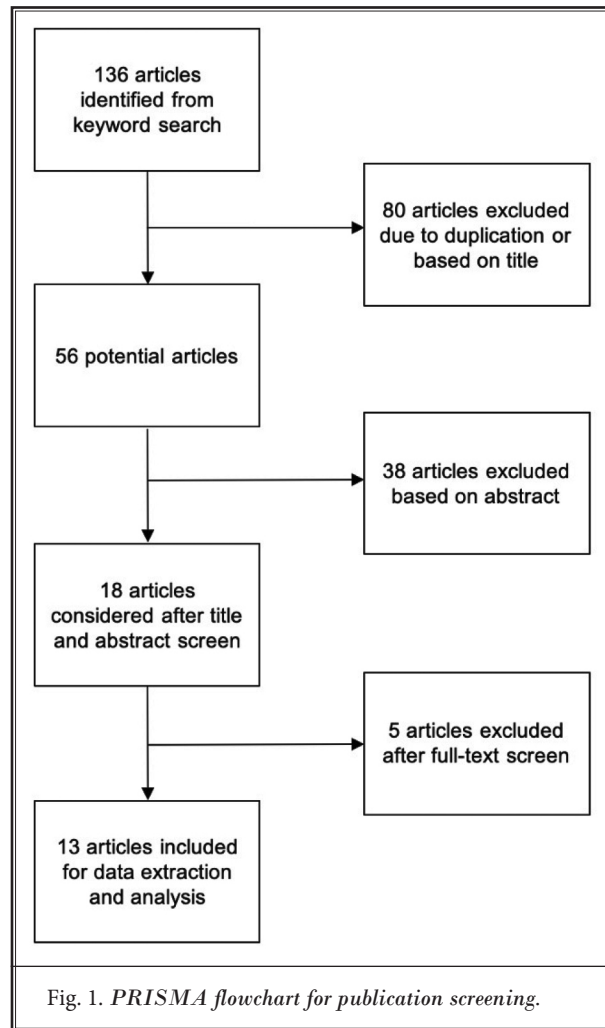


Table 1. Five articles investigating the difference in vertebral body sagittal translation in supine-standing imaging versus flexion-extension imaging.

Authors	Study Type	Number of Patients	Country of Origin	Difference in Translation in Flexion-Extension	Difference in Translation in Supine-Standing	P-Value
Cabraja et al (6)	Single-center retrospective	100	Germany	2.3mm +/- 1.5mm	4mm +/- 2mm	0.001
Chan et al (7)	Single-center retrospective	56	Canada	0.58mm +/- 2.2mm	3.77 +/- 2.95mm	0.001
Viswanthan et al (8)	Single-center prospective	51	USA	1.2mm +/- 0.9mm	5.2mm +/- 1.8mm	0.01
Fujimoto et al (9)	Single-center retrospective	92	Japan	2.2mm +/- 1.3mm	1.6 +/- 1.7mm	0.01
Thompson et al (10)	Single-center cross-sectional	25	USA	1.8 +/- 1.7mm	2.0+/-2.2mm	0.53

Table 2. Eight articles comparing alternative imaging to standard flexion-extension radiographs.

Authors	Study Type	Number of Patients	Country of Origin	Alternative Imaging More Sensitive Than Flexion-Extension (Y/N)	Imaging Modality Investigated
Fong et al (11)	Single-center cross-sectional	225	USA	Yes	Standing lateral radiographs and supine CT vs. flexion-extension radiograph
Lee et al (5)	Single-center retrospective	39	USA	Yes	Flexion + supine/neutral + supine/neutral + standing vs. flexion -extension
Zhou, Sun, Chen et al (14)	Single-center retrospective	62	China	Yes	Flexion + supine/flexion + decubitus vs. flexion-extension
Zhou, Sun, Qui, et al (12)	Single-center retrospective	154	China	Yes	Natural sitting radiograph + supine MRI vs flexion-extension
Tarpada et al (13)	Single-center retrospective	59	USA	Yes	Supine lateral + upright flexion vs. flexion extension
Krenzlin et al (16)	Single-center retrospective	113	Germany	Yes	Supine CT / supine MRI + standing inclination or reclination vs. radiograph in standing inclination + reclination
Inoue et al (17)	Prospective single-center	23	Japan	Yes	Flexion-extension X-ray imaging in different postures (standing vs. sitting vs. lateral decubitus positions)
Kashigar et al (15)	Multicenter retrospective	191	USA	Yes	Standing upright + supine MRI vs. flexion extension

both supine lateral radiographs with upright flexion images and supine lateral radiographs with upright neutral images could be more useful than flexion-extension radiographs in detecting segmental instability. The final paper by Zhou et al (14) suggested that spinal instability should be evaluated by the combination of natural sitting radiographs with supine MRI, given that this method detected translational instability in 61% of patients, whereas 19% of patients were diagnosed by flexion-extension imaging.

The study conducted by Kashigar et al (15) evaluated the additional value of obtaining flexion-extension radiographs in patients with grade 1 degenerative spondylolisthesis who had already received standing-upright radiographs and supine MRIs. The results showed that of the 191 patients in the study, only 16% had additional motion on flexion-extension radiographs that was not seen in the upright, supine imaging, and only 10% had slips of less than 7 mm on upright x-rays. Kashigar et al (15) ultimately concluded that flexion-extension radiographs had limited utility in the management of dynamic spondylolisthesis.

Although Krenzlin et al (16) did not examine flexion-extension radiographs directly, they found that comparing a single plain radiograph (in the inclination, reclination, or prone position) to a supine CT or MRI film was "sufficient and even more sensitive in detecting lumbar instability" than were functional radiographs.

One article did not utilize supine imaging in its

analysis. Inoue et al (17) demonstrated differences in the degree of spondylolisthesis in various types of flexion-extension films, including standing, sitting, and lateral decubitus. The greatest change in slip percentage and intervertebral angle was seen in flexion-extension films of patients in the lateral decubitus position.

DISCUSSION

In the present investigation, we aimed to identify the quality and characteristics of publications that compared the utility of alternative forms of imaging to that of flexion-extension x-rays in diagnosing dynamic lumbar spondylolisthesis. Our search was able to identify 5 articles that directly compared supine-to-standing imaging to flexion-extension imaging and measured the difference in sagittal translation (6-10). An additional 8 articles were identified that discussed alternative imaging but did not compare the difference in sagittal translation observed between the 2 sets of diagnostic imaging (5,11-17). Of the 13 articles, 6 (5,8,10,11,13,15) were completed within the United States while the remaining 7 (6,7,9,12,14,16,17) were split among the countries of Japan, China, Germany, and Canada. Nine of the studies (5-7,9,12-16) (comprising the majority) were of the retrospective type, and all but one of those 9 was single-center (15). Of the remaining 4 (8,10,11,17), 2 (8,17) were single-center prospective studies, and 2 (10,11) were single-center cross-sectional studies.

In our analysis, 12 of the collected articles supported the idea that alternative imaging techniques were able to identify dynamic spondylolisthesis successfully and obtain a greater degree of movement of the vertebrae than could flexion-extension imaging (5-9,11-17). Of those 12 articles, 11 incorporated some form of supine-to-standing comparison in their analysis (5-9,11-17). Only one article of the 13 screened found that the gold-standard measurement, consisting of flexion and extension imaging, was able to identify a dynamic spondylolisthesis more accurately than an alternative form (10).

The present analysis highlights the ongoing debate surrounding the diagnostic utility of traditional standing flexion/extension x-rays. Patients who experience persistent or worsening symptoms despite negative or inconclusive x-ray findings may benefit from advanced imaging modalities. In this analysis, we were able to identify alternatives to flexion-extension imaging that could impact how diagnostic testing in patients with suspected spondylolisthesis is approached, as well as the way patients are identified as potential surgical candidates. Imaging techniques such as MRI and CT can help elucidate the underlying pathology and guide further management decisions. Facet effusions on MRI scans are valuable markers of instability. Specifically, bilateral facet effusions with differences between right and left fluid volume are strong predictors for the presence of dynamic spondylolisthesis (18). Additionally, patients with complex spinal anatomy, such as those with scoliosis or prior spinal surgery, may require MRI or CT scans to accurately assess for dynamic instability while accounting for potential confounding factors. However, it is essential to balance the diagnostic yield of advanced imaging with considerations such as cost-effectiveness, patient comfort, and, in the case of CT, radiation exposure. Therefore, judicious patient selection based on clinical presentation, risk factors, and diagnostic goals is paramount for optimizing the utility and efficacy of MRI and CT imaging in the evaluation of dynamic spondylolisthesis.

Based on the evidence presented, the authors of the present analysis conclude that supine images should be paired with standing flexion/extension radiographs to determine dynamic lumbar instability most accurately. This recommendation has significant importance for pain practitioners who perform spinal canal modification procedures such as percutaneous image-guided lumbar decompression and interspinous spacer implants. Dynamic instability may limit the du-

rability and effectiveness of these procedures (19,20). Furthermore, all physicians providing spine care should know of these findings because the vertebral fusion of unstable vertebral segments is often considered the definitive treatment for spondylolisthesis. We suggest that future guidelines and research include supine and standing/flexion images to rule out a dynamic spondylolisthesis, since doing so may improve time to surgery and patient outcomes.

Though the studies reviewed are compelling enough for us to recommend that both supine and stand/flexion imaging be performed instead of flexion/extension alone, we also advise caution in interpreting any comparative flexion or standing radiographs in the setting of a lumbar scoliotic deformity. In patients with rotational and/or sagittal scoliosis, the vertebral bodies may artificially appear translational on lateral projection. This possibility is related to the relatively larger width-to-depth ratio of lumbar vertebral bodies, which, upon rotation around their central axis during flexion, will appear as if they were translated anteriorly (21).

The authors surmise that supine positioning relaxes the paraspinal musculature, creating an image that is not influenced by muscular contraction and depends only on gravity. Nonetheless, standing and flexion radiographs both create paraspinal contracture. Therefore, the net contractile change of paravertebral forces between the supine and the standing position is greater than the one between the flexion and the extension position (22).

Limitations

Despite the limitations of the review process, including the lack of a formally registered protocol and potential publication bias, the findings suggest that alternative imaging modalities may offer advantages in detecting segmental instability. However, the heterogeneity of study designs and the small sample sizes across the literature underscore the need for further research to elucidate the most effective diagnostic approach.

CONCLUSION

The results of this analysis suggest that supine and flexion imaging may offer better demonstrations of dynamic lumbar instability than can flexion and extension imaging. Although the literature comparing the techniques is limited, what we identified was compelling enough for the authors of the present analysis to

subscribe to the aforementioned conclusion. We do suggest more in-depth analysis to validate our claim. Further research may be needed to elucidate the most effective diagnostic approach for accurately identifying patients who have dynamic spondylolisthesis. Spine and pain physicians should include supine and standing comparative imaging in their algorithms for patient procedure selection instead of flexion versus extension radiographs.

Conflicts of Interest

Dr. Sayed Emal Wahezi receives research funding from Boston Scientific, Abbott, and Vertos and also serves as a consultant for Boston Scientific. All other authors report no conflicts of interest. All other authors certify that he or she, or a member of his or her immediate family, has no commercial association (i.e., consultancies, stock ownership, equity interest, patent/licensing arrangements, etc.) that might pose a conflict of interest in connection with the submitted article.

Contributorship Statement

Dr. Sayed Emal Wahezi, MD is responsible for the overall content as guarantor and accepts full responsibility for the finished work and/or the conduct of the study. He had access to the data and controlled the decision to publish. All the authors' contributions are listed below.

MJ: Design and data collection, methodology, writing (original draft preparation)

ED: Design and data collection, methodology, analysis

NM, KA, KZ: Writing (results, analysis, and interpretation)

JL, ML, RJ: Writing (introduction, discussion, review, and editing)

UY, JF, JK, RY, AK: Writing (review and editing)

SW: Conceptualization, writing, editing, supervision

Additional Disclaimer

Availability of Data and Material Data sharing is not applicable to this article, since no datasets were generated or analyzed during the current study. Ethical approval is not needed for this scoping review, and peer-reviewed articles were included in it. This article is based on previously conducted studies and does not contain any new studies with human patients or animals performed by any of the authors. Informed consent was waived, since this paper was a review of publications in the literature. This study is an original work by the authors, not previously published, and is not undergoing consideration for publication elsewhere currently. All sources utilized are duly acknowledged through accurate citation. It is imperative to properly cite and enclose any literal copies of text with quotation marks to indicate their sources. Every author has contributed significantly to the paper through personal and active involvement, and they shall accept public liability for its content.

REFERENCES

- Balagué F, Mannion AF, Pellisé F, Cedraschi C. Non-specific low back pain. *Lancet* 2012; 379:482-491.
- Maher C, Underwood M, Buchbinder R. Non-specific low back pain. *Lancet* 2017; 736-747.
- Kalichman L, Kim DH, Li L, Guermazi A, Berkin V, Hunter DJ. Spondylolysis and spondylolisthesis: Prevalence and association with low back pain in the adult community-based population. *Spine (Phila Pa 1976)* 2009; 34:199-205.
- Denard PJ, Holton KF, Miller J, et al; Osteoporotic Fractures in Men (MrOS) Study Group. Lumbar spondylolisthesis among elderly men: Prevalence, correlates, and progression. *Spine (Phila Pa 1976)* 2010; 35:1072-1078.
- Lee NJ, Mathew J, Kim JS, et al. Flexion-extension standing radiographs underestimate instability in patients with single-level lumbar spondylolisthesis: Comparing flexion-supine imaging may be more appropriate. *J Spine Surg* 2021; 7:48-54.
- Cabraja M, Mohamed E, Koeppe D, Kroppenstedt S. The analysis of segmental mobility with different lumbar radiographs in symptomatic patients with a spondylolisthesis. *Eur Spine J* 2012; 21:256-261.
- Chan V, Marro A, Rempel J, Nataraj A. Determination of dynamic instability in lumbar spondylolisthesis using flexion and extension standing radiographs versus neutral standing radiograph and supine MRI. *J Neurosurg Spine* 2019; 31:229-235.
- Viswanathan VK, Hatef J, Aghili-Mehrizi S, Minnema AJ, Farhadi HF. Comparative utility of dynamic and static imaging in the management of lumbar spondylolisthesis. *World Neurosurg* 2018; 117:e507-e513.
- Fujimoto S, Teramoto A, Morita T, et al. Evaluation of segmental mobility in patients with lumbar spondylolisthesis: A comparison of images from standing flexion-extension and standing/supine slippage. *J Med Invest* 2023; 70:135-139.
- Thompson AR, Montgomery TP, Gillis

- C, et al. How do standing neutral, supine lateral, standing flexion, and standing extension radiographs compare in detecting the presence and magnitude of stable and dynamic spondylolisthesis? *Clin Orthop Relat Res* 2023; 481:2459-2468.
11. Fong AM, Duculan R, Endo Y, et al. Instability missed by flexion-extension radiographs subsequently identified by alternate imaging in L4-L5 lumbar Degenerative Spondylolisthesis. *Spine (Phila Pa 1976)* 2023; 48:E33-E39.
 12. Zhou Q, Sun X, Qiu Y, et al. Utility of the decubitus or the supine rather than the extension lateral radiograph in evaluating lumbar segmental instability. *Eur Spine J* 2022; 31:851-857.
 13. Tarpada SP, Cho W, Chen F, Amorosa LF. Utility of supine lateral radiographs for assessment of lumbar segmental instability in degenerative lumbar spondylolisthesis. *Spine (Phila Pa 1976)* 2018; 43:1275-1280.
 14. Zhou QS, Sun X, Chen X, et al. Utility of natural sitting lateral radiograph in the diagnosis of segmental instability for patients with degenerative lumbar spondylolisthesis. *Clin Orthop Relat Res* 2021; 479:817-825.
 15. Kashigar A, Laratta JL, Carreon LY, et al. Is there additional value to flexion-extension radiographs for degenerative spondylolisthesis? *Spine* 2021; 46:E458-E462.
 16. Krenzlin H, Keric N, Ringel F, Kantelhardt SR. Intermodal detection of lumbar instability in degenerative spondylolisthesis is superior to functional radiographs. *Front Surg* 2022; 9:860865.
 17. Inoue D, Shigematsu H, Nakagawa Y, Takeshima T, Tanaka Y. The influence of posture on instability evaluation using flexion-extension X-ray imaging in lumbar spondylolisthesis. *Asian Spine J* 2021; 15:308-316.
 18. Lattig F, Fekete TF, Grob D, Kleinstück FS, Jeszenszky D, Mannion AF. Lumbar facet joint effusion in MRI: A sign of instability in degenerative spondylolisthesis? *Eur Spine J* 2012; 21:276-281.
 19. Deer TR, Grider JS, Pope JE, et al. The MIST Guidelines: The Lumbar Spinal Stenosis Consensus Group guidelines for minimally invasive spine treatment. *Pain Pract* 2019; 19:250-274.
 20. Deer TR, Grider JS, Pope JE, et al. Best practices for Minimally Invasive Lumbar Spinal Stenosis Treatment 2.0 (MIST): Consensus guidance from the American Society of Pain and Neuroscience (ASPN). *J Pain Res* 2022; 15:1325-1354.
 21. Ploumis A, Transfeldt EE, Gilbert TJ Jr, Mehbod AA, Dykes DC, Perra JE. Degenerative lumbar scoliosis: Radiographic correlation of lateral rotatoryolisthesis with neural canal dimensions. *Spine (Phila Pa 1976)* 2006; 31:2353-2358.
 22. Gouteron A, Tabard-Fougère A, Moissenet F, et al. Sensitivity and specificity of the flexion and extension relaxation ratios to identify altered paraspinal muscles' flexion relaxation phenomenon in nonspecific chronic low back pain patients. *J Electromyogr Kinesiol* 2023; 68:102740.

