

Randomized Controlled Trial

# Comparison of Selective Nerve Root Pulsed Radiofrequency Vs Paramedian Interlaminar Epidural Steroid Injection for the Treatment of Painful Cervical Radiculopathy

Gokhan Yildiz, MD, Gevher Rabia Genc Perdecioğlu, MD, Omer Taylan Akkaya, MD, Ezgi Can, MD, and Damla Yuruk, MD

From: Ankara Etlik City Hospital,  
Department of Algology, Ankara,  
Turkey

Address Correspondence:  
Gokhan Yildiz, MD  
Department of Algology  
Ankara Etlik City Hospital  
Varlık Mahallesi, Halil Sezai Erkut  
Caddesi, Yenimahalle  
Ankara, Turkey  
E-mail: gkoildz@gmail.com

Disclaimer: There was no external  
funding in the preparation of this  
manuscript.

Conflict of interest: Each author  
certifies that he or she, or a  
member of his or her immediate  
family, has no commercial  
association (i.e., consultancies,  
stock ownership, equity interest,  
patent/licensing arrangements,  
etc.) that might pose a conflict of  
interest in connection with the  
submitted manuscript.

Manuscript received: 09-19-2023  
Revised manuscript received:  
11-15-2023  
Accepted for publication:  
11-27-2023

Free full manuscript:  
[www.painphysicianjournal.com](http://www.painphysicianjournal.com)

**Background:** Although there are studies evaluating ultrasound-guided selective nerve root pulsed radiofrequency (ULSD-SNRPRF) and fluoroscopy-guided paramedian cervical interlaminar epidural steroid injection (FL-CIESI) for the treatment of chronic cervical radicular pain, no study has compared the efficacy of these 2 methods.

**Objectives:** This study aimed to compare the efficacy of these 2 methods, their superiority to each other, and the incidence of adverse events.

**Study Design:** A prospective, randomized controlled trial

**Setting:** Outpatient department of a single-center pain clinic.

**Methods:** Sixty patients who did not respond to conservative treatments for lower cervical radicular pain were randomly divided into 2 groups. One group underwent ULSD-SNRPRF (Group U), and the other underwent paramedian FL-CIESI (Group F). Patients were evaluated pretreatment, and 3 and 6 months posttreatment. The Numeric Rating Scale (NRS-11) was used to assess clinical improvement, The Neck Disability Index (NDI) to assess improvement in functional disability, and the Self-Leeds Assessment of Neuropathic Symptoms and Signs Pain Score (S-LANSS) to assess the treatment's effect on neuropathic pain. Clinically significant pain relief was defined as a 50% or more pain reduction in the NRS-11. The posttreatment reduction in medication consumption was assessed using the Medication Quantification Scale Version III (MQS III). We also evaluated whether there was a difference in treatment-related characteristics, such as procedure time and adverse events.

**Results:** The procedure time was significantly longer in Group U. Blood aspiration was observed in 2 patients in Group U and vascular spread in one patient in Group F, with no significant difference. At 3 and 6 months posttreatment, NRS-11 and NDI scores showed a significant decrease compared to the pretreatment scores in both groups; there was no difference between the groups. Both treatments effectively improved neuropathic pain, with no significant difference between the S-LANSS scores. There was no difference in the reduction of medication consumption between the groups.

**Limitations:** There was no sham or control group, and the follow-up period was limited to 6 months.

**Conclusions:** Pain relief, functional improvement, and safety were similar between groups. ULSD-SNRPRF and paramedian FL-CIESI are 2 different effective techniques for chronic cervical radicular pain. The choice of method should depend on various factors, such as patient preference, operator experience, and availability of resources. An advantage of ULSD over fluoroscopy is that patients and physicians are not exposed to radiation.

**Key words:** Pulsed radiofrequency treatment, epidural injections, steroids, radiculopathy, neck pain, fluoroscopy, ligamentum flavum, ultrasonography

**Pain Physician 2024; 27:E221-E229**

**R**adicular pain in the lower cervical spine is a common condition that affects a patient's quality of life and function. According to a systematic analysis of the 2017 Global Burden of Disease Study, the global age-standardized prevalence and incidence rate of radicular neck pain in the general population were 3,551 per 100,000 and neck pain was the fourth leading cause of disability worldwide (1). Neck pain is caused by compression or inflammation of the nerve roots that exit the spinal cord through the intervertebral foramina (2).

Epidural steroid injections involve injecting a corticosteroid and a local anesthetic into the epidural space, the space between the dura mater and the vertebrae. Epidural steroid injections aim to reduce inflammation and edema around the nerve roots, thus relieving pain and improving function (3).

Fluoroscopy-guided cervical interlaminar epidural steroid injections (FL-CIESI) can be performed via a midline or paramedian approach (4). The midline interlaminar approach involves inserting a needle into the epidural space through the interlaminar space, which is the gap between the 2 adjacent vertebrae. However, it has some limitations, such as difficulty reaching the anterior epidural space, where most nerve root compressions are located. Drugs administered into the epidural space may have difficulty reaching the spinal nerve root in the anterior epidural space. In addition, a cadaveric study reported the incidence of a midline ligamentum flavum defect and a gap between 87% and 100% between C3 and T2 (5). Midline ligamentum flavum defect was detected between C7-T1 in 93% of cases. This midline ligamentum flavum defect may also increase the risk of spinal cord injury during an epidural injection. Therefore, the paramedian approach may provide a safer, easier, and more effective access to the anterior epidural space, where the main compression and inflammation are located (4).

Ultrasound-guided selective nerve root pulsed radiofrequency (ULSD-SNRPRF) is a technique in which PRF energy is delivered to cervical nerve roots under ULSD guidance (6). ULSD guidance allows direct visualization of the nerve root and surrounding structures (such as vascular structures) that cannot be observed with fluoroscopy; it also provides real-time feedback on needle placement and PRF delivery.

Both techniques aim to reduce pain transmission from the affected nerve root. However, there is limited evidence on the comparative effectiveness and safety of these 2 techniques for chronic cervical radicular pain.

The primary aim of our study was to compare the efficacy of these 2 methods in treating cervical radicular pain. The secondary aims were to compare the procedures' duration, complications, and adverse events.

## METHODS

### Study Design and Patients

Our study was designed as a prospective, randomized controlled trial. Approval for this prospective study was obtained from the local ethics committee (approval number AEŞH-EK1-125). The study was registered at ClinicalTrials.gov (registration number NCT05950321). Written informed consent was obtained from all patients for interventional procedures and participation in the study. A computerized randomization program was used to allocate the patients to the groups.

The inclusion criteria for this study were: 1) age between 18 and 75 years; 2) radicular pain radiating only to the neck and one arm for more than 12 weeks; 3) pain of a neuropathic character (Self-Administered Leeds Assessment of Neuropathic Symptoms and Signs [S-LANSS] >12) and evidence of radiculopathy by electroneuromyography; 4) unresponsiveness to conservative treatments (including analgesics and physiotherapy modalities); 5) only protruding (not extruded or migrated) disc herniation at C5-C6, C6-C7, and C7-T1 levels determined through clinical examination and/or radiological imaging; 6) no surgical operation for cervical disc herniation; and 7) an absence of motor deficits in the arm and hand.

The exclusion criteria were as follows: 1) possible shoulder or arm pathology detected by orthopedic assessment; 2) detection of possible inflammatory or rheumatological disease by a rheumatologist; 3) dominant axial cervical pain; 4) grade 2 (severe) foraminal stenosis (7); 5) presence of cervical myelopathy; 6) motor deficit associated with radiculopathy; 7) coagulopathy or use of antiplatelets or anticoagulants; 8) an implanted pacemaker; 9) any comorbidity (such as diabetes mellitus or hypertension); 10) renal-hepatic insufficiency; 11) a diagnosis of psychiatric illness; and 12) injection site or systemic infection.

All ULSD- and FL-guided procedures were performed by an interventional pain physician who had at least 5 years of experience. Patients were monitored and vascular access was established prior to all procedures. The patients were not sedated, and the interventions were performed under local anesthesia.

### Ultrasound-guided Selective Nerve Root Diagnostic Blockade and Pulsed Radiofrequency Procedure (Group U)

A 5-12 MHz linear ULSD probe (LOGIQ P9, GE Ultrasound) was wrapped in a sterile transparent drape. The patient was placed in the lateral decubitus position, with the intervention site on the upper side. The area was cleaned with povidone-iodine. The vertebral levels C5, C6, and C7 were determined according to the morphology of the tubercle of the transverse process (Fig. 1). The C7 vertebra has a more prominent posterior tubercle and rudimentary anterior tubercle. The C5 and C6 vertebrae have more uniform anterior and posterior tubercles. The anterior tubercle of C6 is more prominent (carotid tubercle) (8). After identifying the hypoechoic nerve root and surrounding vascular structures between the tubercles of the transverse process, a 22G spinal needle was inserted in the same plane as the ULSD probe and directed from posterior to anterior. Approaching from the dorsal side of the relevant nerve root while avoiding the vascular structures, 1.5 mL of 1% lidocaine was injected for each affected root after negative aspiration.

Patients who reported a 50% or greater reduction in radicular pain for at least 2 hours underwent ULSD-SNRPRF the next day using the same procedure and 5 mm active type, 60 mm RF cannulas (TOP Nuropole Needle, TOP Corporation) and an RF generator (TOP Lesion Generator, TOP Corporation). After approaching the hypoechoic nerve root, a current of 0.4 – 0.5 V at a frequency of 50 Hz was applied for sensory stimulation, and a paresthesia response was obtained in the corresponding dermatome. PRF was applied to each nerve root at 42°C for 4 minutes after a contraction response

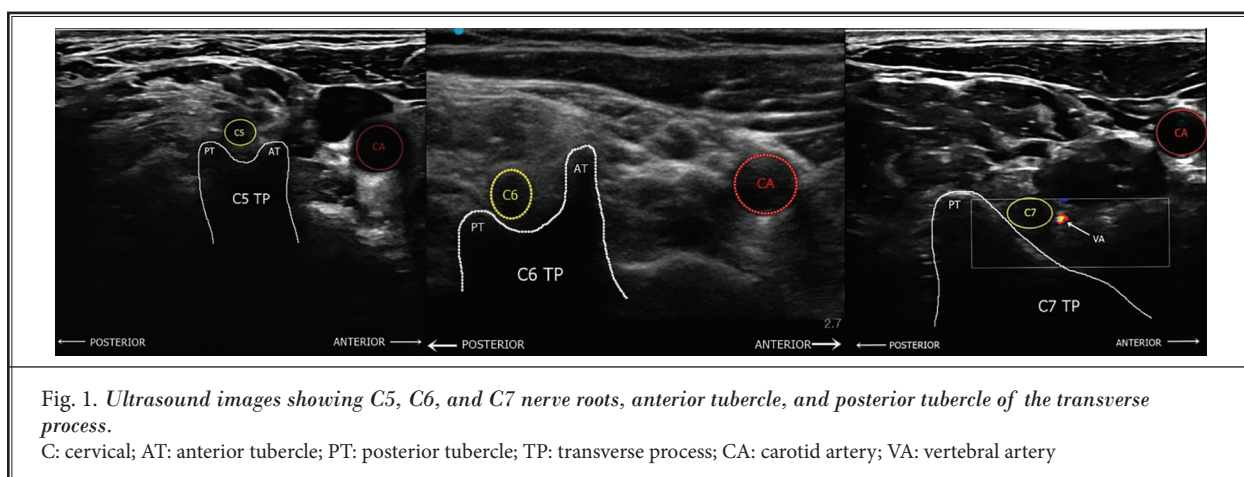
was observed in the relevant myotome at a 1.0 – 1.2 V current at a frequency of 2 Hz. No medication was administered after the PRF.

### Fluoroscopy-guided Cervical Interlaminar Epidural Steroid Injection Procedure (Group F)

Each patient was positioned prone with a pillow under the chest to open the interlaminar space by flexing the spine. The posterior neck area was cleaned with povidone-iodine. The interlaminar space to be entered was determined with fluoroscopy. The C7-T1 level was the access point to the epidural space (Fig. 2). Aiming for a paramedian approach, 1 mL of 1% lidocaine was applied to the skin with a 27G needle 1.5 – 2 cm lateral to the midline, and then a 20G Tuohy needle was inserted. The needle was guided in the anteroposterior fluoroscopic view, and the needle depth was checked in the lateral view. When the needle tip approached the spinolaminar line, the epidural space was entered using a loss-of-resistance injector. To visualize the appropriate spread in the epidural space and to rule out nonepidural (such as intravascular) spread, one mL of contrast medium (iohexol, 300 mg iodine/mL, GE Healthcare) was administered by taking real-time images. Posterior or anterior spread of contrast medium within the epidural space was noted. Dexamethasone (10 mg) and 0.5% lidocaine (20 mg) were injected slowly into the epidural space at a total volume of 4 mL. All patients were monitored in the recovery room for at least one hour for any possible adverse events.

### Assessment

Demographic data, analgesic medications, pain duration, and affected nerve roots were recorded before



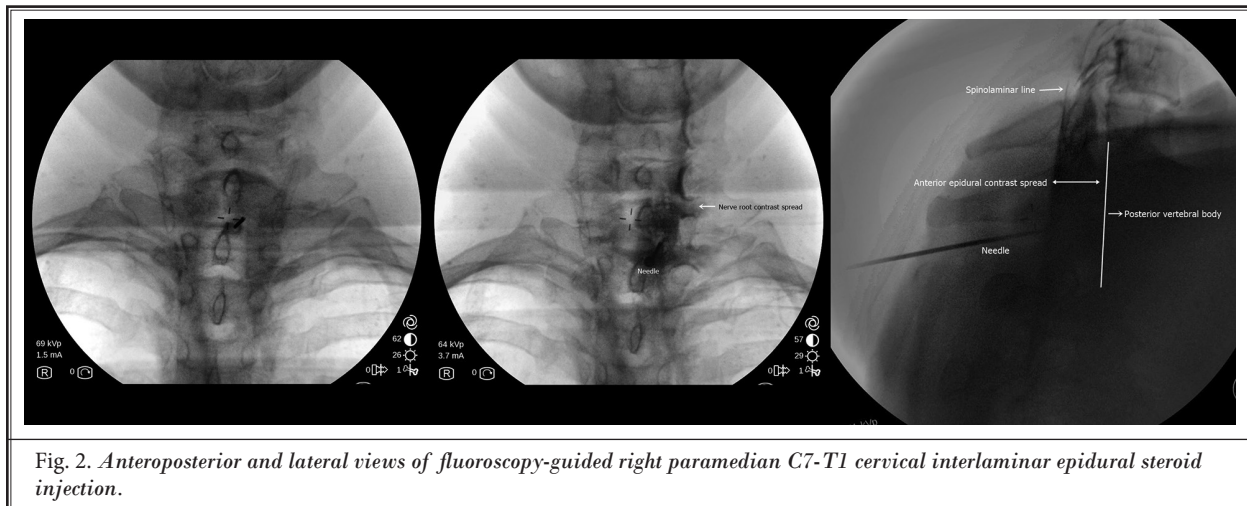


Fig. 2. Anteroposterior and lateral views of fluoroscopy-guided right paramedian C7-T1 cervical interlaminar epidural steroid injection.

the procedure. Contrast medium spread to the anterior and posterior epidural space in Group F, adverse events such as vascular spread, and procedure duration were recorded during the procedure in both groups. A clinician who had never seen the patients performed the posttreatment assessments.

The efficacy of the treatments was assessed using the Numeric Rating Scale (NRS-11), Neck Disability Index (NDI), and S-LANSS. The NRS-11 and NDI scores were assessed at pretreatment and 3 and 6 months posttreatment. The effect of the treatments on drug consumption was assessed using the Medication Quantification Scale Version III (MQS III).

For the NRS-11, 0 is defined as no pain and 10 is defined as the highest pain intensity. Significant pain relief was defined as a 50% or greater decrease in the NRS-11.

The NDI is a self-report questionnaire that measures the effect of neck pain on a patient's activities of daily living and quality of life. It consists of 10 items assessing pain intensity, personal care, lifting, reading, headaches, concentration, work, driving, sleep, and leisure. Each item is scored from 0 to 5, with higher scores indicating greater disability (9).

The S-LANSS is a 7 item self-report scale that aims to identify pain of predominantly neuropathic origin based on a patient's current symptoms and signs. It has a cut-off score of 12 or more, which indicates neuropathic pain with high sensitivity and specificity (10). The S-LANSS was assessed at pretreatment and 6 months posttreatment.

The MQS III is a tool that quantifies medication use in patients with chronic pain by considering 3 aspects: drug class, dosage, and detriment (risk). The MQS III as-

signs a numerical value to each medication class based on its potential negative impact, as rated by American Pain Society member physicians. The MQS III can be used as a clinical and research tool to monitor and compare the medication profiles of patients with pain over time or across different treatments (11). The MQS was assessed at pretreatment and 6 months posttreatment.

The primary outcome in our study was treatment response, with a change in the NRS-11 at 3 and 6 months posttreatment. The secondary outcomes were changes in the NDI, S-LANSS, MQS III scores, unexpected adverse event rate, and procedure duration. For procedure duration, the procedure was started with the first insertion of the ULSD probe or the first image taken with fluoroscopy and ended with needle removal.

### Sample Size and Statistical Analysis

The sample size was calculated using G\*Power 3.1.9.4 software (Heinrich Heine University). With an effect size of 1.018,  $\alpha = 0.05$ , and power  $(1-\beta) = 0.95$ , a minimum of 27 patients in each group was planned; the study was completed with 30 patients in each group. For this analysis, the statistically significant NRS-11 data at month 3 ( $2.8 \pm 2.7$  for Group U,  $5.5 \pm 2.6$  for Group F) was used (12).

All analyses were performed using jamovi Version 2.3, (The jamovi Project). The results of this study are expressed as frequencies, percentages, and medians (minimum-maximum). Categorical variables were compared using the  $\chi^2$  test. Numerical dependent variables were compared between the groups using an independent sample t test and Mann-Whitney U test. The NRS-11 and NDI scores were analyzed using the

Friedman test and the S-LANSS scores were analyzed using the Wilcoxon test. Statistical significance was set as  $P < 0.05$ .

## RESULTS

Seventy-two patients who met the inclusion criteria were included in this study. Before ULSD-SNRPRF in Group U, 2 patients who did not respond to the diagnostic block were excluded from the study. A vasovagal reaction developed in one patient in Group U and 2 patients in Group F, so the interventions were stopped, the patients were excluded from the study, and their hypotension and bradycardia were treated appropriately. After excluding patients who were lost to follow-up, 30 patients from each group were included in the study. A patient selection flowchart is shown in Fig. 3.

The demographic and clinical characteristics of the patients are shown in Table 1. Age, gender, body mass index, pain duration, analgesic medication, affected nerve root, and pain side were similar between the groups. The duration of the procedures, complications, and posttreatment pain and functionality scores are shown in Table 2.

The procedure duration was  $12.73 \pm 2.74$  minutes in Group U and  $6.07 \pm 0.99$  mins in Group F. The shorter duration time in Group F was statistically significant ( $P < 0.001$ ).

While bleeding was observed in 2 patients in Group U, vascular contrast medium spread was observed in one patient in Group F. After controlling the bleeding in all 3 patients, the needle direction was changed and vascular adverse events were not observed again. No dural puncture was observed in any patient. There were no significant differences in the adverse events between the groups. In Group F, contrast medium spread was observed in the anterior epidural space in 76.7% of the patients, while in 23.3% of the patients, contrast medium spread was observed in the posterior epidural space, with significantly more anterior spread.

The NRS-11, NDI, and S-LANSS scores were similar between the groups at baseline. The NRS-11 and NDI scores showed a significant decrease at 3 and 6 months posttreatment in both groups compared with baseline; there was no significant difference between the groups. The S-LANSS and MQS III scores were only evaluated

at 6 months posttreatment. There was a significant decrease in both groups compared to baseline; there was no significant difference between the groups.

## DISCUSSION

In our study, paramedian FL-CIESI and ULSD-SNRPRF treatment effectively reduced chronic cervical radicular pain at 3 and 6 months compared to pretreatment and significantly improved NRS-11, S-LANSS, and NDI scores. The NRS score reduction of 50% or more at 6 months was 60% in Group U and 63.3% in Group F. Lee, et al (6) reported a success rate of 63.3% at 6 months post-ULSD-SNRPRF. Choi, et al (4) reported a clinical improvement of up to 77.4% at 3 months post modified paramedian CIESI.

Since cervical radicular pain usually originates from an intervertebral disc, interventions targeting the anterior epidural space may be more effective than those targeting the posterior epidural space. Paramedian CIESI is more effective than transforaminal epidural injection (TFEI) in spreading the contrast medium into the anterior epidural space where the main root compression occurs (4). In the study by Choi, et al (4), a 90% rate of spread to the anterior epidural space was observed with a modified paramedian CIESI, while this rate was 83.9% in the TFEI group. However, no significant difference in clinical improvement was observed between the 2 groups (4). In our study, spread to the anterior epidural space was observed at 76.7% in Group F. Transition to the anterior epidural space with midline CIESI has been reported at a rate of 28% – 44% (4).

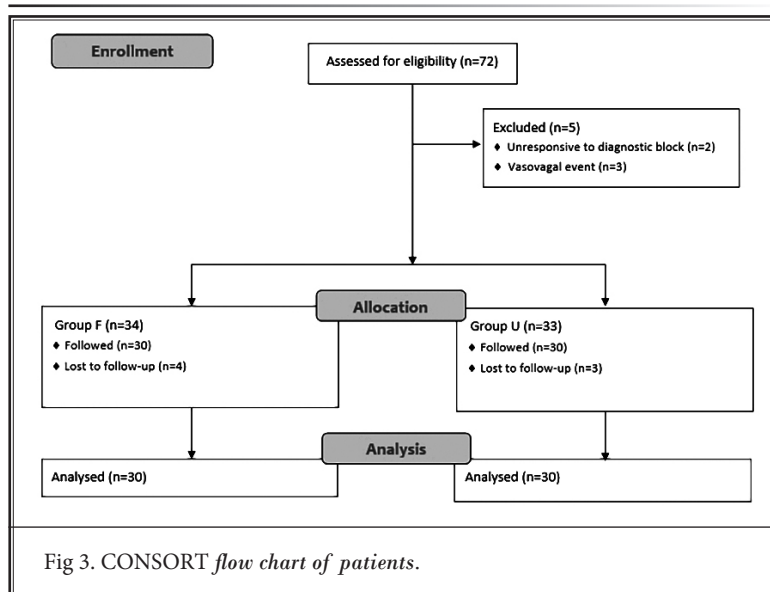


Fig 3. CONSORT flow chart of patients.

Table 1. Baseline demographic and clinical characteristics of patients.

		Group U		Group F		P
		Mean	Median	Mean	Median	
Age(yrs)		52.17 ± 12.43	52.50 (32 - 75)	52.62 ± 11.12	52 (33 - 75)	0.904 <sup>a</sup>
Gender n(%)	Women	22 (73.3)		19 (63.3)		0.579 <sup>b</sup>
	Men	8 (26.7)		11 (36.7)		
BMI (kg/m <sup>2</sup> )		22.38 ± 2.04	22.30 (19 - 26)	22.39 ± 2.00	22.90 (18.7 - 25.1)	0.880 <sup>a</sup>
Affected nerve root	C6	2 (6.7)		4 (13.3)		0.402 <sup>b</sup>
	C7	0		2 (6.7)		
	C5-C6	12 (40)		13 (43.3)		
	C6-C7	12 (40)		8 (26.7)		
	C5-C6-C7	4 (13.3)		3 (10)		
Side n(%)	Left	15 (50)		13 (43.3)		0.796 <sup>b</sup>
	Right	15 (50)		17 (56.7)		
Duration of pain (mos)		10.10 ± 2.49	9.50 (6-15)	10.90 ± 2.71	11 (7 - 15)	0.216 <sup>c</sup>
Analgesic baseline	None	2 (6.7)		0		0.634 <sup>d</sup>
	NSAID	1 (3.3)		3 (10)		
	Tramadol	7 (23.3)		11 (36.7)		
	Pregabalin	4 (13.3)		3(10)		
	Gabapentin	5 (16.7)		4 (13.3)		
	Duloxetine	1 (3.3)		0		
	Amitriptyline	2 (6.7)		2 (6.7)		
	Combined	8 (26.7)		7 (23.3)		

Group U: Ultrasound-guided selective nerve root pulsed radiofrequency group; Group F: Fluoroscopy-guided paramedian cervical interlaminar epidural steroid injection group; BMI: Body mass index; C: Cervical nerve root; NSAID: Nonsteroidal anti-inflammatory drugs; a: Independent Samples t test; b: Continuity Correction; c: Mann Whitney U test; d:Pearson's  $\chi^2$  test

Table 2. Intervention-related and posttreatment clinical features.

	Group U		Group F		P
	Mean	Median	Mean	Median	
Procedure duration (mins)	12.73±2.74	13(8-18)/45.30	6.07±0.99	6(5-8)/15.70	<0.001 <sup>c</sup>
NRS-11-baseline	7.53 ± 0.97	8(6-9)/28.50	7.79 ± 0.94	8(6-9)/32.50	0.353 <sup>c</sup>
NRS-11-3 months	4.00 ± 2.10*	3.50(11-8)/33.75*	3.45 ± 2.70*	2(1-9)/27.25*	0.142 <sup>c</sup>
NRS-11-6 months	4.53 ± 1.83*	4(2-8)/34.53*	3.76 ± 1.83*	4(2-8)/26.47*	0.070 <sup>c</sup>
NDI-baseline	23.53 ± 2.81	23.50(19-29)/28.12	24.17 ± 2.35	24(20-28)/32.88	0.286 <sup>c</sup>
NDI-3 months	13.83 ± 6.44*	12(5-24)/34.13*	11.66 ± 6.13*	8(5-23)/26.87*	0.105 <sup>c</sup>
NDI-6 months	14.80 ± 6.46*	13(6-26)/34.37*	12.40 ± 6.45*	10(5-24)/26.63*	0.085 <sup>c</sup>
S-LANNS-baseline		16(13-18)/32.73		16(13-18)/28.20	0.344 <sup>a</sup>
S-LANNS-6 months		4(1-17)/28.42**		3(1-17)/32.58**	0.313 <sup>a</sup>
MQS III-6 months		2.10(0-5.2)/28.75*		1.95(0-5)/32.25	0.421 <sup>c</sup>
Vascular adverse events n(%)	2(6.7)		1(3.3)		0.097 <sup>b</sup>
Dural puncture	0		0		

Group U: Ultrasound-guided selective nerve root pulsed radiofrequency group; Group F: Fluoroscopy-guided paramedian cervical interlaminar epidural steroid injection group; NRS-11: Numeric rating scale; NDI: Neck Disability Index; S-LANNS: Self-Leeds Assessment of Neuropathic Symptoms and Signs Pain Score; MQS III: Medication Quantification Scale Version III a: Mann Whitney U test; b: Fisher's exact test; c: Pearson's  $\chi^2$  test; \*:  $P < 0.001$  compared with baseline values in each group with Friedman test; \*\*:  $P < 0.001$  compared with baseline values in each group with Wilcoxon test.

Although previous studies have shown no difference in the clinical efficacy between midline and paramedian epidural injections (3), another important issue is safety. No comprehensive study has compared complications, such as dural puncture, between the midline and paramedian approaches. It is possible for CIESIs to have catastrophic results. The complication rate varies between 2.4% and 5.4% (3). Most of these complications are minor and self-limited, and include increased pain, pain at the injection site, numbness, and vasovagal reactions. However, some rare but serious complications may occur, such as spinal cord injury, infection, epidural hematoma, and intracranial hypotension.

According to a study by Amrhein, et al (13), the incidence of accidental dural puncture during fluoroscopy-guided midline cervical epidural injection was reported to be 1.4%. The highest rate of dural puncture occurred at the C5-C6 level. The incidence of midline gaps in the ligamentum flavum ranges from 71.4% to 100% in different studies (5,14). This rate is 93% between C7-T1, where cervical epidural steroid injection is most commonly applied as in our study, and 93% between C6-C7.

In our study, a paramedian approach was used in Group F, and dural puncture was not observed in any patient. A paramedian approach may prevent the catastrophic consequences of a midline ligamentum flavum defect. In addition, the Anesthesia Patient Safety Foundation has stated that cervical epidural steroid injections should be administered at the C7-T1 level and, if necessary, at the uppermost C6-C7 level to reduce neurological complications (15). In our study, all epidural steroid injections were performed at the C7-T1 level.

Choi, et al (4) also evaluated vascular adverse events in their study by comparing paramedian CIESI and TFEI. In this study, no contrast medium vascular spread was observed with paramedian CIESI, whereas vascular spread was observed in 38.7% of the patients in the FL-guided TFEI group. In our study, vascular events were observed in only 2 patients in Group U, while vascular spread was observed in only one patient in Group F. Interventional procedures on cervical nerve roots can be risky because of vascular structures close to the cervical nerve roots. TFEI under FL guidance can have a high vascular risk because vascular structures are not visible on fluoroscopy. The position of the needle tip is critical to avoid intravascular injection and potential complications, such as stroke or spinal cord infarction. During cervical TFEI, an ascending or deep cervical artery within 2 mm of the needle tip in the needle end

position has been demonstrated with a rate of 20% (16).

ULSD effectively prevents vascular complications and allows the direct visualization and imaging of various soft tissues, including blood vessels, without radiation exposure. Although we were unable to visualize vascular structures in 2 cases in Group U, blood aspiration suggested that we were unable to detect some vascular structures. In such cases, nonparticulate steroids are crucial to prevent vascular occlusion (17). Particulate steroids pose a risk of neurological complications due to vascular infarction if inadvertently injected into the arterial system. This may result in spinal cord ischemia, brainstem or cerebellar stroke, or even death. In our study, no additional medication was given after PRF application in Group U, but it is important to use nonparticulate steroids such as dexamethasone if preferred. The use of blunt needles to prevent vascular injuries during TFEI also contributes to reducing vascular complications.

The anatomical structure targeted by ULSD-SNRPRF is the distal neuroforamen. Epidural spread has been demonstrated in 30% of cases with a ULSD-SNR block (18). This suggests that there may be inadequate drug delivery to the anterior epidural space and dorsal root ganglion. However, it has been suggested that the drug is delivered to the lesion site via diffusion through neuronal cell membranes (19). Another hypothesis is that the transforaminal passage is reduced due to the high viscosity of contrast media, whereas drugs pass more easily into the epidural space because of their low viscosity. There was also no difference between the ULSD-SNR block and TFEI in terms of clinical improvement (20). It is thought that PRF treatment causes neuromodulation via micromolecular changes. PRF may also alter the expression of ion channels and neurotransmitters in the nerve, leading to long-term changes in neuronal excitability and synaptic transmission (6).

It has been suggested that the electromagnetic field generated by short currents of 20 milliseconds with a PRF cannula placed near nerve tissue has neuromodulatory effects (21). The clinical efficacy of ULSD-SNRPRF suggests that this neuromodulatory effect is transmitted to the dorsal root ganglion and higher neuronal structures. PRF reduces microglial activation, cytokines, and mediators that may be involved in the pathogenesis of chronic neuropathic pain (22). Similar to the efficacy of PRF in the treatment of neuropathic pain, CIESI has also been shown

to be effective in the treatment of neuropathic pain. Toprak, et al (23) achieved significant clinical improvement in both cervical neuropathic and nociceptive pain with CIESI.

In our study, the S-LANSS neuropathic pain score at 6 months was significantly lower in both groups compared to baseline. There was no difference between the 2 groups. In addition, there were no differences between the 2 groups regarding the decrease in drug consumption at 6 months posttreatment as calculated by the MQS III. Despite the efficacy of both methods in neuropathic and nociceptive pain, ULSD-SNRPRF was performed for 4 minutes per level, which is a longer procedure time than paramedian FL-CIESI.

Our study had several limitations. First, there was no sham stimulation or a control group. Another

limitation was that the follow-up period was limited to 6 months, thus we could not evaluate longer-term results.

## CONCLUSIONS

ULSD-SNRPRF and paramedian FL-CIESI are 2 different techniques used for managing chronic radicular pain. Both methods have their advantages and limitations. The choice of technique should be based on the patient's condition, preference, and availability of resources. Although our study is not a cost-effectiveness study, the high cost of a radiofrequency generator and cannula used for ULSD-SNRPRF should also be considered. Further studies are needed to compare the long-term outcomes and cost-effectiveness of these 2 techniques.

## REFERENCES

- Safiri S, Kolahi AA, Hoy D, et al. Global, regional, and national burden of neck pain in the general population, 1990-2017: Systematic analysis of the Global Burden of Disease Study 2017. *BMJ* 2020; 368:m791.
- Jang JH, Lee WY, Kim JW, Cho KR, Nam SH, Park Y. Ultrasound-guided selective nerve root block versus fluoroscopy-guided interlaminar epidural block versus fluoroscopy-guided transforaminal epidural block for the treatment of radicular pain in the lower cervical spine: A retrospective comparative study. *Pain Res Manag* 2020; 2020:9103421.
- Yoon JY, Kwon JW, Yoon YC, Lee J. Cervical interlaminar epidural steroid injection for unilateral cervical radiculopathy: comparison of midline and paramedian approaches for efficacy. *Korean J Radiol* 2015; 16:604-612.
- Choi E, Nahm FS, Lee PB. Comparison of contrast flow and clinical effectiveness between a modified paramedian interlaminar approach and transforaminal approach in cervical epidural steroid injection. *Br J Anaesth* 2015; 115:768-774.
- Yoon SP, Kim HJ, Choi YS. Anatomic variations of cervical and high thoracic ligamentum flavum. *Korean J Pain* 2014; 27:321-325.
- Lee SH, Choi HH, Roh EY, Chang MC. Effectiveness of ultrasound-guided pulsed radiofrequency treatment in patients with refractory chronic cervical radicular pain. *Pain Physician* 2020; 23:E265-E272.
- Kim S, Lee JW, Chai JW, et al. A new MRI grading system for cervical foraminal stenosis based on axial T2-weighted images. *Korean J Radiol* 2015; 16:1294-1302.
- Karmakar MK, Pakpirom J, Songthamwat B, Areeruk P. High definition ultrasound imaging of the individual elements of the brachial plexus above the clavicle. *Reg Anesth Pain Med* 2020; 45:344-350.
- Jones C, Sterling M. Clinimetrics: Neck Disability Index. *J Physiother* 2021; 67:144.
- Koc R, Erdemoglu AK. Validity and reliability of the Turkish Self-administered Leeds Assessment of Neuropathic Symptoms and Signs (S-LANSS) questionnaire. *Pain Med* 2010; 11:1107-1114.
- Gallizzi M, Gagnon C, Harden RN, Stanos S, Khan A. Medication Quantification Scale Version III: internal validation of detriment weights using a chronic pain population. *Pain Pract* 2008; 8:1-4.
- Chalermkitpanit P, Pannangpetch P, Kositworakitkun Y, et al. Ultrasound-guided pulsed radiofrequency of cervical nerve root for cervical radicular pain: A prospective randomized controlled trial. *Spine J* 2023; 23:651-655.
- Amrhein TJ, Parivash SN, Gray L, Kranz PG. Incidence of inadvertent dural puncture during CT fluoroscopy-guided interlaminar epidural corticosteroid injections in the cervical spine: An analysis of 974 cases. *AJR Am J Roentgenol* 2017; 209:656-661.
- Joshi J, Roytman M, Aiyer R, Mauer E, Chazen JL. Cervical spine ligamentum flavum gaps: MR characterisation and implications for interlaminar epidural injection therapy. *Reg Anesth Pain Med* 2022; 47:459-463.
- Manchikanti L, Malla Y, Cash KA, Pampati V. Do the gaps in the ligamentum flavum in the cervical spine translate into dural punctures? An analysis of 4,396 fluoroscopic interlaminar epidural injections. *Pain Physician* 2015; 18:259-266.
- Stewart ZE. Safety of local anesthetics in cervical nerve root injections: A narrative review. *Skeletal Radiol* 2023; 52:1893-1900.
- Makkar JK, Singh PM, Jain D, Goudra B. Particulate vs non-particulate steroids for transforaminal epidural steroid injections: Systematic review and meta-analysis of the current literature. *Pain Physician* 2016; 19:327-340.
- Park Y, Ahn JK, Sohn Y, et al. Treatment effects of ultrasound guide selective nerve root block for lower cervical radicular pain: A retrospective study of 1-year follow-up. *Ann Rehabil Med* 2013; 37:658-667.
- Kang S, Yang SN, Kim SH, Byun CW, Yoon JS. Ultrasound-guided cervical nerve root block: Does volume affect the spreading pattern? *Pain Med* 2016;



- 17:1978-1984.
20. Jee H, Lee JH, Kim J, Park KD, Lee WY, Park Y. Ultrasound-guided selective nerve root block versus fluoroscopy-guided transforaminal block for the treatment of radicular pain in the lower cervical spine: A randomized, blinded, controlled study. *Skeletal Radiol* 2013; 42:69-78.
21. Vigneri S, Sindaco G, Gallo G, et al. Effectiveness of pulsed radiofrequency with multifunctional epidural electrode in chronic lumbosacral radicular pain with neuropathic features. *Pain Physician* 2014; 17:477-486.
22. Cho HK, Cho YW, Kim EH, Sluijter ME, Hwang SJ, Ahn SH. Changes in pain behavior and glial activation in the spinal dorsal horn after pulsed radiofrequency current administration to the dorsal root ganglion in a rat model of lumbar disc herniation: Laboratory investigation. *J Neurosurg Spine* 2013; 19:256-263.
23. Sanal-Toprak C, Ozturk EC, Yucel FN, Sencan S, Gunduz OH. Does the presence of neuropathic pain affect the outcomes of the interlaminar epidural steroid injection for cervical disc herniation?: A prospective clinical study. *Medicine (Baltimore)* 2021; 100:e25012.

