

Feasibility Study

Implantation of Surgical Paddle Electrodes Using Percutaneous Biportal-Endoscopic Technique for Spinal Cord Stimulation: An Anatomical Feasibility Study in Human Cadavers

Chen Li, MD¹, Ye Jiang, MD², Tengfei Liu, MD¹, Lutao Yuan, MD², Cong Luo, MD², and Yong Yu, MD, PhD¹

From: ¹Department of Neurosurgery, Zhongshan Hospital, Fudan University, Shanghai, China; ²Department of Neurosurgery, Minhang Hospital, Fudan University, Shanghai, China

Address Correspondence:
Yong Yu, MD, PhD
Department of Neurosurgery
Zhongshan Hospital
Fudan University
180 Fenglin Rd
Shanghai, 200032, China
E-mail: yuyongziming@163.com

Disclaimer: Chen Li and Ye Jiang contributed equally to this work.
Funding was received from Shanghai Municipal Commission of Health (202240290).

Conflict of interest: Each author certifies that he or she, or a member of his or her immediate family, has no commercial association (i.e., consultancies, stock ownership, equity interest, patent/licensing arrangements, etc.) that might pose a conflict of interest in connection with the submitted manuscript.

Manuscript received: 05-12-2023
Revised manuscript received: 07-02-2023
Accepted for publication: 08-19-2023

Free full manuscript:
www.painphysicianjournal.com

Background: Spinal cord stimulation is a technique in which different types of electrodes are placed in the spinal epidural space for neuromodulation. Surgical paddle electrodes (SEs) are usually implanted by a surgeon by performing open surgery with laminectomy. Recent advances in endoscopic spine surgery provide another option for minimally invasive SE implantation.

Objectives: This anatomical study aims to examine the feasibility of implanting SEs in thoracic and cervical spine segments, discussing the specific advantages and disadvantages compared with previously reported methods.

Study Design: Laboratory study with Institutional Review Board No B2023-056.

Methods: Four fresh adult cadavers (2 women, 2 men) were operated on in this study. The posterior unilateral biportal endoscopic surgical approach, the accessibility to the intraspinal epidural space, and the technical possibilities and limitations of implantation of SEs were evaluated, as well as the surgical duration and complications.

Results: All the planned steps of the operation were successfully accomplished in all 4 cadavers. A total of 8 electrodes were successfully implanted through the working portal. Among them, 4 were located in the cervical segment and 4 in the thoracic segment. The proper position of the electrodes was also verified by fluoroscopy. No rupture of dura occurred during the operation. Except for the first cadaver, the duration of surgery did not exceed 1 hour.

Limitations: Anatomical study on human cadavers, the quantity of cadavers, and the steep learning curve.

Conclusions: The results of this anatomical study show that the SEs can be satisfactorily implanted in cervical and thoracic segments using the unilateral biportal endoscopic technique.

Key words: Surgical paddle electrodes, spinal cord stimulation, unilateral biportal endoscopic technique, anatomical feasibility, anatomical study, cadavers, cervical, thoracic

Pain Physician 2023; 26:E805-E813

Spinal cord stimulation (SCS) is a technique in which different types of electrodes are placed in the spinal epidural space for neuromodulation. Significant progress has been made in SCS technology since Shealy et al (1) first implanted an electrode in the

spinal cord in 1967. As a result, the indications of SCS have expanded with the development of novel neural targets, innovations in waveforms, intelligent devices, the evolution of programming, and the comprehensive understanding of novel mechanisms of action (2-4).

The indications encompassed the previously called failed back surgery syndrome and complex regional pain syndrome have expanded to peripheral vascular disease, refractory angina, phantom limb pain, chronic head and neck pain, etc. Furthermore, new applications are being proposed and researched worldwide (5-6).

At present, 2 types of electrodes are available commercially: surgical paddle electrodes (SEs) and percutaneous puncture cylindrical electrodes (PEs), each of which features its own advantages and shortcomings (7-8). PEs have the advantages of the possibility of being implanted under local anesthesia by interventionists, which are less invasive and much more commonly used, reducing the risks of exposure to various types of anesthesia or surgical intervention. The risk of initial adverse events is lower. Advantages of SEs include having higher energy efficiency, requiring less battery usage and impedance, and having a lower likelihood of migration (2,9-12). However, implantation of SEs is more invasive and requires surgical implantation via laminotomy or hemilaminotomy by a surgeon. Longer skin incisions, wider paravertebral muscle detachment, and greater bone trauma cannot be ignored. Implantation of SEs is associated with higher initial postoperative complications (13). In order to minimize the shortcomings of SEs and reduce iatrogenic damage, many surgeons have explored alternative surgical methods (14-17).

Endoscopic spine surgery has been widely accepted in recent years due to its minimally invasive nature and high-definition (HD) visual field. The indications of endoscopic spine surgery have expanded with the rapid development of endoscopic armamentaria and technological innovations (18-19). The biportal endoscopic technique (UBE) is used in endoscopic spine surgery (20) and has shown encouraging clinical results in decompressive laminectomy for the treatment of spinal stenosis (21-24). The concept of a biportal endoscopic system is different from the uniportal technique as it uses endoscopes with intraendoscopic working channels. Two skin portals are made: one portal is used for the endoscope and the other permits entry of the working instruments. In fact, the separation of the working channel from the endoscopy portal allows for greater maneuverability of the working instruments (23-24). Moreover, it provides a new method for exploring the minimally invasive placement of SEs by using the working channel for SE implantation. In particular, spinal endoscopy surgery can be performed without general anesthesia (19), allowing communication between sur-

geons and patients during surgery to confirm the range of electrode coverage.

Based on the descriptions of the biportal endoscopic technique used in spinal surgery, this anatomical study (Fig. 1) aims to examine the feasibility of implanting SEs in thoracic and cervical segments, considering the specific advantages and disadvantages compared with previously reported methods. To the best of our knowledge, this is the first study to place SEs using the biportal endoscopic technique.

METHODS

Four fresh adult cadavers (2 women, 2 men) were operated on in this study. The research protocol for this study was reviewed and approved by the Institutional Review Board. The posterior unilateral biportal endoscopic surgical approach, the accessibility to the intraspinal epidural space, and the technical possibilities and limitations of implantation of SEs were evaluated.

Equipment Used in the Percutaneous Biportal Endoscopic Procedure and the Surgical Paddle Electrodes

The procedures were performed using an HD autoclavable 4-mm, 30° arthroscope (CONMED Linvatec, Largo, FL), an arthroscopic tissue shaver (Ergo Shaver handpiece; CONMED Linvatec, Largo, FL), a 3.5-mm high-speed spinal bur (LJM45DRS, Xishan Science & Technology Co., Ltd, China), and standard arthroscopic facilities and conventional spine instruments (Backbone Science & Technology Co., Ltd, China), such as serial dilators, a specially designed dissector, pituitary forceps, and Kerrison punches. The surgical region was irrigated with an isotonic saline solution, which was drained from the endoscopic portal to the working portal. A pressure pump irrigation system was used to control the flow rate and limit irrigation pressure under 30 mmHg (10K Fluid System, CONMED Linvatec, Largo, FL).

Two types of SEs were implanted: specify SureScan magnetic resonance imaging (MRI) 2X8 977C265 (56.4X7.6mm) for cervical segments and specify SureScan MRI 5-6-5 977C165 (64.2X10mm) for thoracic segments (Intellis; Medtronic, Minneapolis, MN).

Surgical Approach

The patients were placed in the prone position on a radiolucent table to enable the use of C-arm fluoroscopy. The procedure was approached from the left side because the senior doctor is a right-handed operator, allowing the left hand to hold the endoscope and the

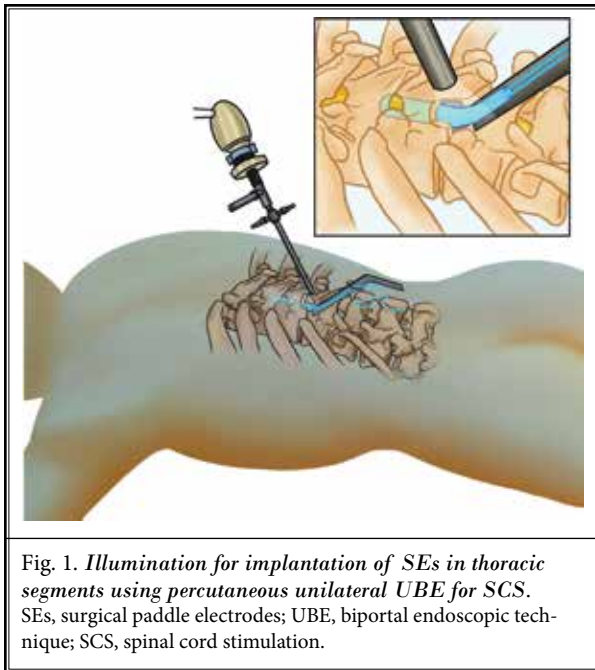


Fig. 1. Illumination for implantation of SEs in thoracic segments using percutaneous unilateral UBE for SCS. SEs, surgical paddle electrodes; UBE, biportal endoscopic technique; SCS, spinal cord stimulation.

right hand to operate and place electrodes. Another important reason for this choice is that the working channel is inclined toward the cranial side, which is usually consistent with the electrode placement direction. The T10-T11 segment and the C6-C7 segment were selected for the entry of thoracic and cervical spinal cord electrodes, respectively, meeting the common needs in clinical practice.

Thoracic Electrodes Implantation

The target level (T10-T11) and the puncture sites on the skin for the portals were verified by anteroposterior fluoroscopy before the operation. The observative portal (A point) was located at the lateral edge of the left pedicle of T10 and the operative portal (B point) was located at the medial margin of the left pedicle of T12. This selection allowed for a greater incline angle to the cephalic side and closer to the median of the operating channel, which is beneficial for electrode placement.

Two spinal puncture needles were inserted at sites A and B targeting the left facet joint of T10-T11 (Fig. 2A). A 1.2 cm skin incision (B point) was made along with the puncture needle, and a K-wire was introduced through the needle and followed by serial dilator insertion after removing the needle. A specially designed dissector was used to strip the muscle overlying the lamina to create a space sufficient for observation and operation. Next, a 0.5 cm skin incision (A point) was

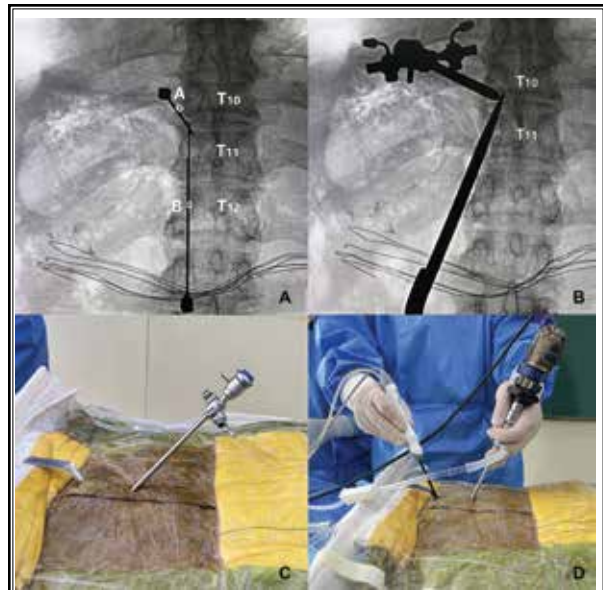


Fig. 2. Puncture positioning and placement of the biportal endoscope. A: Anteroposterior fluoroscopy showing 2 puncture needles punctured at sites A and B, targeting the left facet joint of T10-T11. Point A was located at the lateral edge of the left pedicle of T10 and point B was located at the medial margin of the left pedicle of T12. Needle B was inclined at about 45° to the cephalic side. B: Anteroposterior fluoroscopy demonstrating the outer sheath of the endoscope and the dissector to strip paravertebral muscles and create a working space. C: Photograph showing the endoscope and the semi-open tube (working portal). D: Photograph showing the unilateral biportal endoscopic spine surgery for implantation of SEs. SEs, surgical paddle electrodes.

made to insert the endoscope (Fig. 2B). Finally, the dissector was withdrawn and a semi-open tube was inserted for working device access (Fig. 2C). A saline irrigation pump was connected to the endoscope, providing a continuous flow of saline solution irrigation, and all the subsequent steps were performed under HD endoscopic visualization (Fig. 2D).

The bipolar radiofrequency probe was used to clear soft tissue to expose the left lamina and spinous process of T10 and T11 (Fig. 3A). Then, a high-speed bur was applied to remove part of the base of the spinous process of T10. The lower half of the T10 lamina was removed with Kerrison punches to expose the attachment of the ligamentum flavum. Subsequently, the base of the T11 spinous process and the upper half of the lamina were removed until the attachment of the ligamentum flavum was exposed. Finally, a 1.5 cm (width)* 3 cm (length) bone window was shaped between T10 and T11 (Fig. 3B).

After removing the ligamentum flavum, the dura mater was visualized.

The semi-open tube (working portal) was then adjusted closer to the midline, with an average angle of about 45°, suspending above the bone window (Fig. 3C). After insertion of the phantom lead (Fig. 3D), the paddle lead was smoothly implanted into the epidural space along the angle of the semi-open tube and ascended to the T8-T9 level (Fig. 3E). The position was verified by x-ray (Fig. 4A-4C). Strain-relief loops of conducting wire were made within the body (Fig. 3F). The lead was secured to the supraspinous ligament with anchoring sleeves, and the rest of the SCS procedure was performed as usual.

Cervical Electrodes Implantation

The cervical electrodes were placed using a similar biportal endoscopy technique as the thoracic electrodes described above. However, some key notes regarding

the characteristics of cervical anatomy and cervical electrodes are outlined below. 1) C6-C7 was selected as the target level for electrode insertion. The presence of cervical lordosis favored the placement of the electrodes in the cephalad direction. 2) The interlaminar window between C6 and C7 was relatively wide. The puncture needle should not converge to the midline to prevent entry into the spinal canal. 3) A smaller bone window (about 1.2 cm* 2 cm) was required due to the smaller size of the cervical electrode. 4) The upper end of the electrode is usually placed below the atlas due to the posterior arch of the atlas. Therefore, this placement is not suitable for cervicomedullary SCS. Figures 5-7 illustrate the placement process of cervical electrodes.

RESULTS

All the planned steps of the operation were successfully performed in all 4 cadavers. The operator

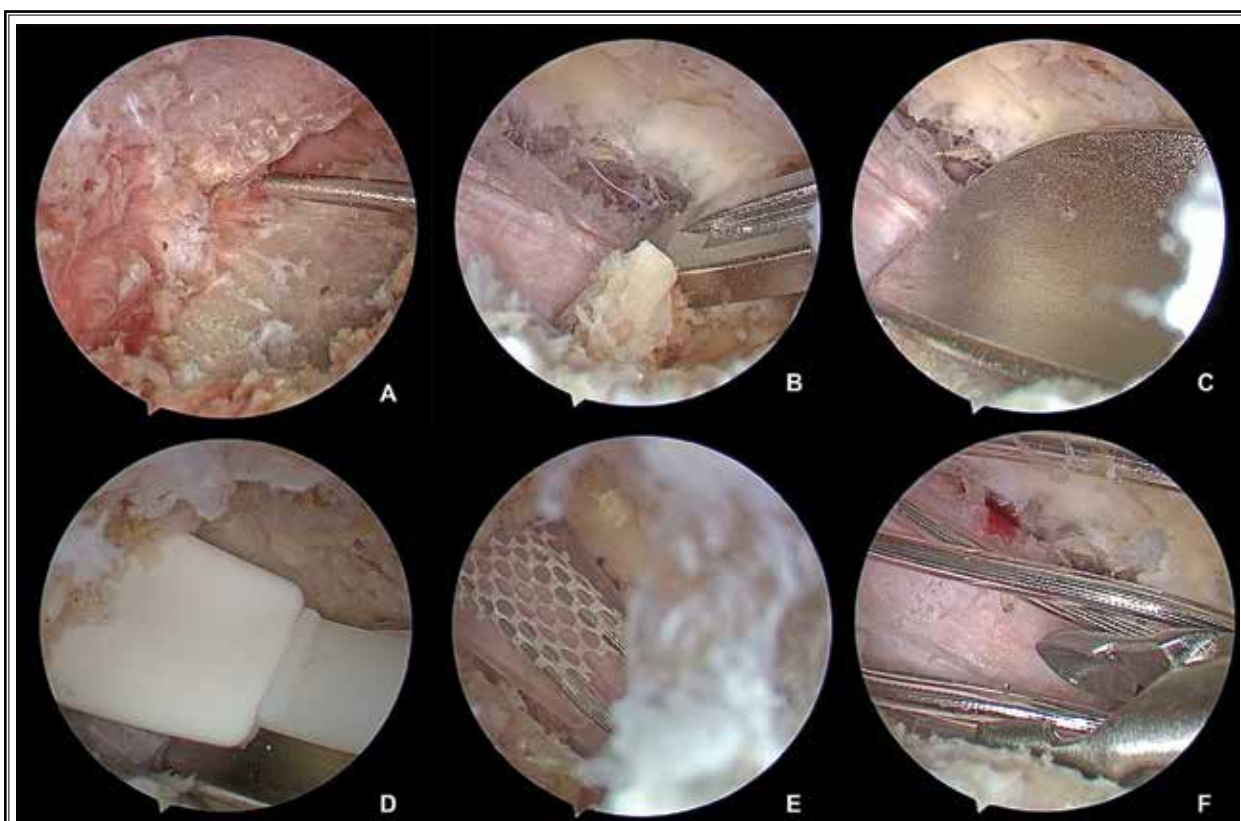


Fig. 3. Endoscopic photograph showing the steps of biportal endoscopic spine surgery for implantation of surgical paddle electrode in the thoracic segment. A: The left lamina and spinous process of T10 and T11. B: The bone window was shaped with Kerrison punches to expose the dura mater. C: The position of the semi-open tube (working portal) was adjusted, suspending above the bone window. D: Insertion of the phantom electrode. E: The paddle electrode was implanted into the epidural space. F: The strain-relief loops of conducting wire were made.

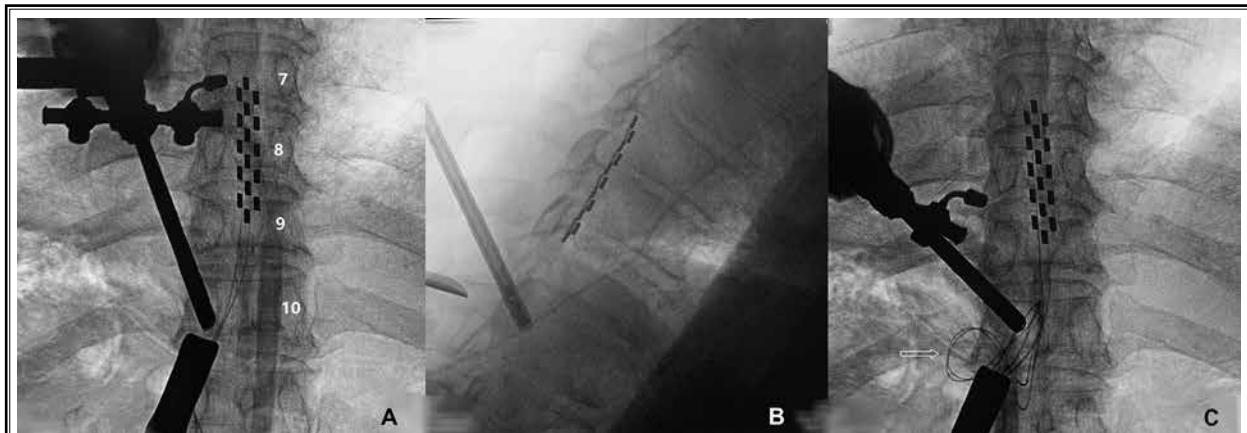

Fig. 4. The position of the thoracic paddle electrode was verified by fluoroscopy. A: Anteroposterior fluoroscopy showing that the electrode was implanted in the median position from T7 to T9; B: Lateral fluoroscopy demonstrating the position of the electrode. C: Anteroposterior fluoroscopy demonstrating the strain-relief loops of conducting wire within the body.

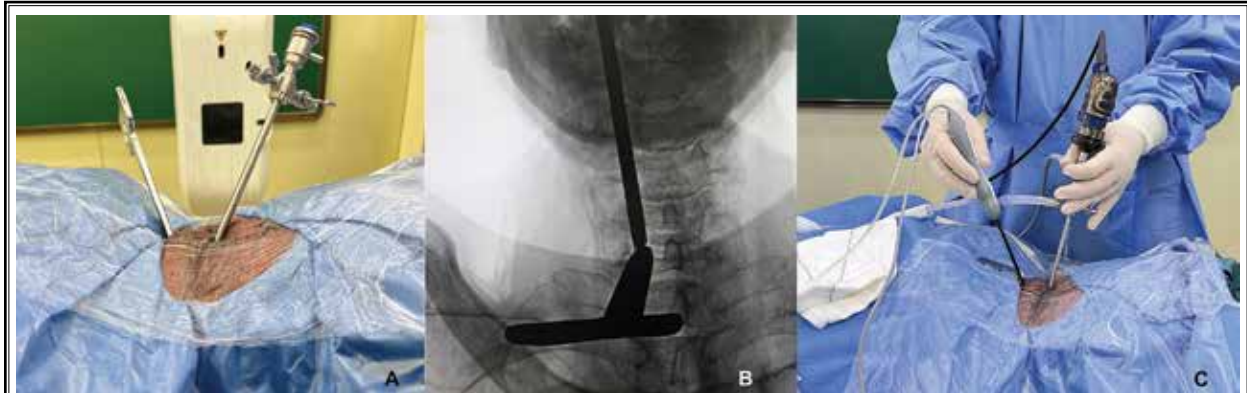


Fig. 5. Placement of the cervical biportal endoscope portal. A: Photograph showing the outer sheath of the endoscope and the dissector. B: Anteroposterior fluoroscopy demonstrating the position of the outer sheath of the endoscope and the dissector at the intersection of the left C6-C7 zygapophysial joint. C: Photograph showing unilateral biportal endoscopic spine surgery for implantation of SEs. SEs, surgical paddle electrodes.

has experience in over 500 cases of cervical, thoracic, and lumbar spine endoscopic surgeries, so puncture orientation, portal establishment, bone window formation, and epidural exposure were technically easy to achieve. A total of 8 electrodes were successfully implanted through the working portal. Among them, 4 were located in the cervical segment and 4 in the thoracic segment. Strain-relief loops of lead wiring were made within the body through the working portal, and extending wiring was sutured to the paraspinal ligaments for anchoring. No rupture of dura occurred during the operation. The proper position of the electrodes was also verified by fluoroscopy.

The duration of each of the 8 operations was

recorded (Fig. 8). The first surgery was the thoracic electrode implantation, which took 105 minutes due to the exploratory nature of the process. The second one was the cervical electrode implantation, which was shortened to 68 minutes. The remaining surgeries were performed within 60 minutes.

DISCUSSION

SCS is well established as a safe, effective, reversible, and minimally invasive method for treating chronic pain syndromes of neuropathic origin derived from a wide variety of etiologies (25). Currently, SEs and PEs are the 2 mainstream types of electrodes. There is no consensus about the superiority of one type of lead

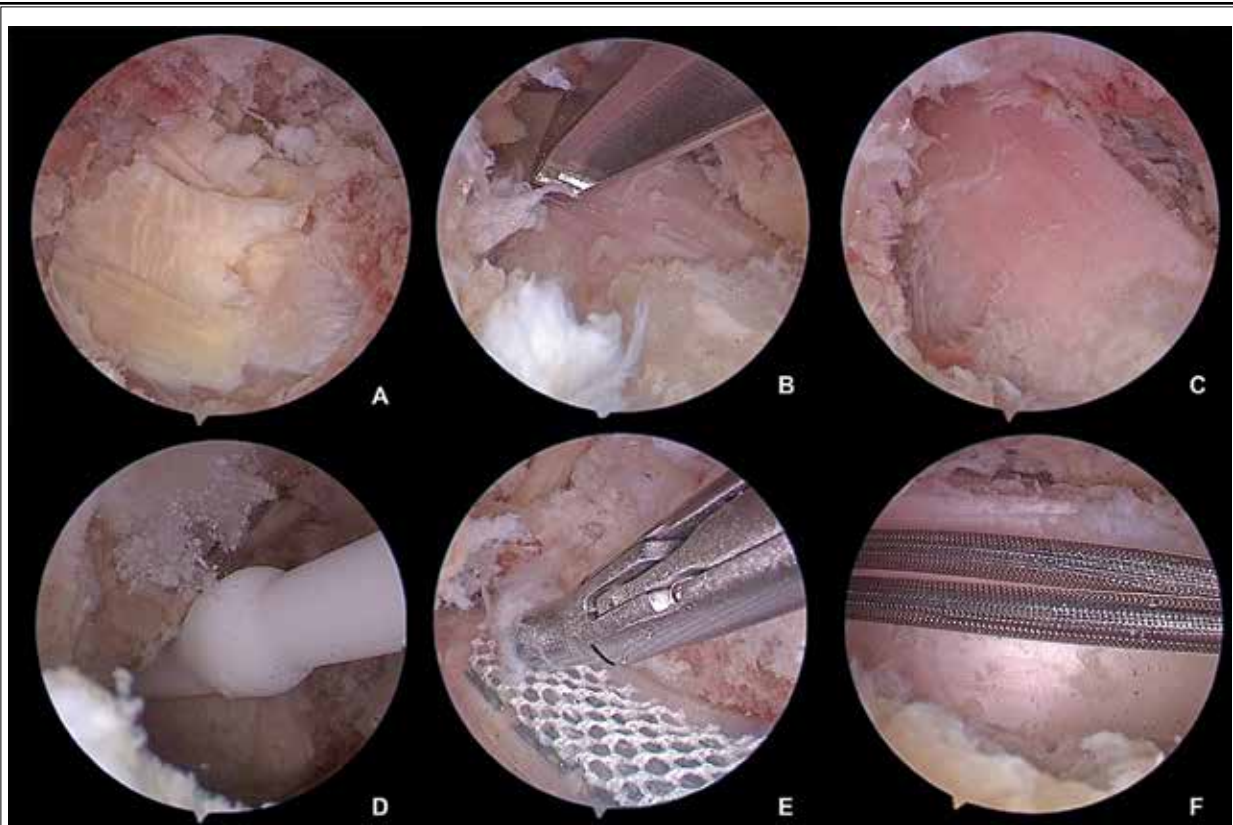


Fig. 6. Endoscopic photograph showing the steps of biportal endoscopic spine surgery for implantation of SEs in the cervical segment. A: The bone window was created between C6 and C7 to expose the ligamentum flavum. B: Sublamina decompression of the C6 segment to the cephalic side, facilitating electrode ascension. C: The bone window was shaped, clearly exposing the dura mater. D: Insertion of the phantom electrode. E: The paddle electrode was adjusted into the epidural space. F: The paddle electrode being placed above C6 and the electrode wire in the endoscopic field of view. SEs, surgical paddle electrodes.

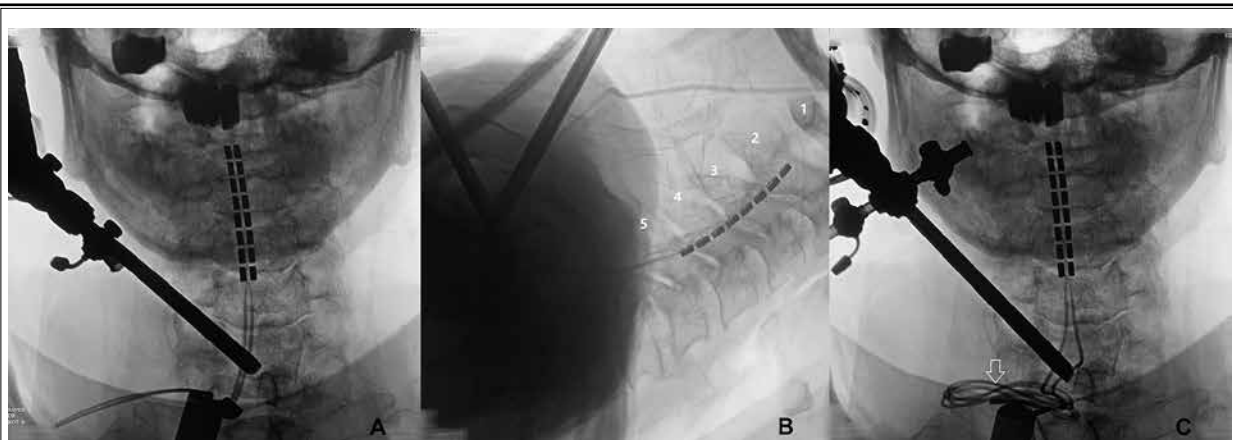


Fig. 7. The position of the cervical paddle electrode was verified by fluoroscopy. A: Anteroposterior fluoroscopy demonstrating the electrode was implanted in the median position from C2 to C5; B: Lateral fluoroscopy demonstrating the position of the electrode. C: Anteroposterior fluoroscopy demonstrating the strain-relief loops of conducting wire.

over the other, and the selection largely depends on the patient, the surgeon's professional training, technical preferences, and experience (7-8). PEs are usually placed under local anesthesia with the aid of fluoroscopic guidance in many centers worldwide. It is a minimally invasive procedure and allows the patient to provide timely feedback to stimulation, thus confirming the correct electrode coverage (26). However, PEs produce a spherical electric field, of which only the part facing the dura surface is effective. On the contrary, SEs have all the contacts facing the dura and the electric field is oriented toward the spinal cord, which allows for more efficient energy delivery (10). Moreover, although similar rates of lead migration have been reported between SEs and PEs (27), migration tends

to be less extreme for SEs (11,28). Lead migration can result in significant loss of SCS efficacy. In this regard, SEs offer an advantage due to the steady contact with the dura surface and negligible tilting or dislodgement in the long term. However, the drawbacks of SEs also need to be faced seriously. Implantation of SEs usually requires a more invasive open surgery with laminotomy due to the size of SEs, with higher risks of adverse events related to the procedure. Hence, new minimally invasive approaches for SE implantation are being developed.

In 2013, Rigoard et al (15) introduced a novel method for SE implantation using an optic transligamentally minimally invasive technique. The surgical approach was performed on both sides of the supraspinous process. After dissection of the paravertebral muscles, an expandable minimal access spinal technology (MAST) tubular retraction system (METRx; Medtronic Inc, Minneapolis, MN) was inserted midline, pushing bilateral paravertebral muscles aside. A cold light optic fiber was attached to the retractor blade to illuminate the deep surgical area. After resection of the supraspinous and interspinous ligaments and the ligamentum flavum, the SEs were successfully implanted. This minimally invasive surgery can also be performed without general anesthesia, providing superior SCS lead performance and clinical outcomes (16).

In the past 2 decades, endoscopic spinal technology has developed rapidly and has been accepted in many fields of spinal surgery. The minimally invasive nature and incomparable HD vision of spinal endos-

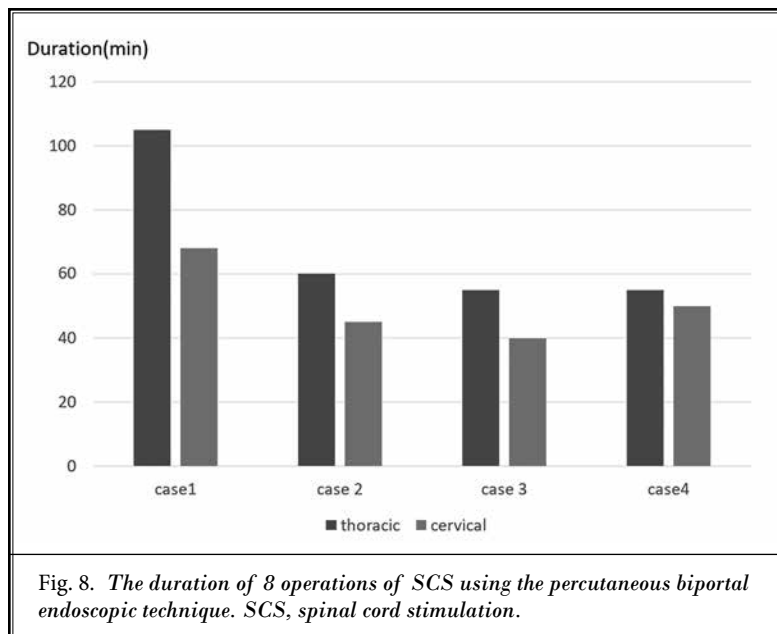


Fig. 8. The duration of 8 operations of SCS using the percutaneous biportal endoscopic technique. SCS, spinal cord stimulation.

copy (18,29) promote the use of this technique for SE implantation. The present study in human cadavers demonstrated the feasibility of implanting SEs using the percutaneous biportal endoscopic technique. A skin incision of about 1.2 cm was made for the working portal, which was suitable for the electrode width. The semi-open tube kept the working channel unobstructed and also served as a channel for inserting the surgical electrodes into the epidural space. Moreover, the direction and angle of the semi-open tube could be adjusted to facilitate the placement of the surgical electrodes to the cephalic side in the median. In the present study, anteroposterior and lateral fluoroscopy was performed to verify the proper placement of the SEs.

This UBE technique has some advantages compared to the previously reported MAST technique. 1) Only 2 small skin incisions are required: one of 0.5 cm for endoscopic observation, and the other 1.2 cm for working device and insertion of SEs. 2) Only one side of the paravertebral muscle needs to be stripped off, sparing the contralateral paraspinal muscles. 3) The supraspinous and interspinous ligaments were preserved and did not need to be excised. 4) Endoscopic close observation and irrigation provided better surgical vision. 5) Continuous flushing would be beneficial for reducing bleeding, subsequent adhesions, and scars. Except for the first surgery, the remaining surgeries were all completed within 1 hour, which was similar to the MAST technique (16).

In this study, no dural tear occurred in the 8 operations. Previous literature (30) has reported that the incidence of dural tears in lumbar spinal stenosis surgery using the UBE technique was approximately 2.23%. It can be inferred that the narrow spinal canal and adhesion of the dura mater have a higher probability of causing tearing. The current study only investigated the placement of SEs in the thoracic and cervical segments. However, we believe that this technique is also suitable for placement in lumbar segments. The interlaminar window and spinal canal of the lumbar segments are larger, allowing easier SE placement.

Limitations

The limitations of this anatomical study on human cadavers are obvious: 1) It doesn't reflect the actual surgical procedure on live patients. Some other influencing factors, such as intraoperative bleeding control and patient cooperation during surgery, need to be further evaluated in practical applications. 2)

The quantity of cadavers in this study is limited due to various constraints. However, the main objective of this cadaver study is to demonstrate the feasibility that the UBE can be used for the placement of SEs. The results of this study can serve as a foundation for further clinical applications. Moreover, another disadvantage of endoscopic procedures is the steep learning curve. This endoscopic-assisted SE implantation is a minimally invasive procedure with an excellent field of vision and can reduce surgery-induced trauma, but the procedure may feel unfamiliar at first for the operator. Sufficient training is necessary to accomplish the surgery smoothly and quickly.

CONCLUSIONS

The results of this anatomical study demonstrate that SEs can be satisfactorily implanted in cervical and thoracic segments using the UBE technique. The endoscopic-assisted implantation of SEs provides another option with some advantages.

REFERENCES

1. Shealy CN, Mortimer JT, Reswick JB. Electrical inhibition of pain by stimulation of the dorsal columns: Preliminary clinical report. *Anesth Analg* 1967; 46:489-491.
2. Dones I, Levi V. Spinal cord stimulation for neuropathic pain: Current trends and future applications. *Brain Sci* 2018; 8:138.
3. Atkinson L, Sundaraj SR, Brooker C, et al. Recommendations for patient selection in spinal cord stimulation. *J Clin Neurosci* 2011; 18:1295-1302.
4. Moriyama K, Murakawa K, Uno T, et al. A prospective, open-label, multicenter study to assess the efficacy of spinal cord stimulation and identify patients who would benefit. *Neuromodulation* 2012; 15:7-11.
5. Isagulyan E, Slavin K, Konovalov N, et al. Spinal cord stimulation in chronic pain: Technical advances. *Korean J Pain* 2020; 33:99-107.
6. Strand N, Maloney J, Tieppo Francio V, et al. Advances in pain medicine: A review of new technologies. *Curr Pain Headache Rep* 2022; 26:605-616.
7. Kirkpatrick AF. Percutaneous electrodes versus electrodes placed by laminotomy for spinal cord stimulation. *Neurosurgery* 1991; 28:932-933.
8. Hatzis A, Stranjalis G, Megapanos C, Sdrolias PG, Panourias IG, Sakas DE. The current range of neuromodulatory devices and related technologies. *Acta Neurochir Suppl* 2007; 97(pt 1):21-29.
9. North RB, Lanning A, Hessels R, Cutchis PN. Spinal cord stimulation with percutaneous and plate electrodes: Side effects and quantitative comparisons. *Neurosurg Focus* 1997; 2:13.
10. North RB, Kidd DH, Olin JC, Sieracki JM. Spinal cord stimulation electrode design: Prospective, randomized, controlled trial comparing percutaneous and laminectomy electrodes—part I: Technical outcomes. *Neurosurgery* 2002; 51:381-389.
11. Witkam RL, Buijse ML, Arnts IJJ, et al. Surgical paddle electrode implantation as a rescue therapy to failed percutaneous leads in failed back surgery syndrome patients. *Neuromodulation* 2022; 25:745-752.
12. Bendersky D, Yampolsky C. Is spinal cord stimulation safe? A review of its complications. *World Neurosurg* 2014; 82:1359-1368.
13. Babu R, Hazzard MA, Huang KT, et al. Outcomes of percutaneous and paddle lead implantation for spinal cord stimulation: A comparative analysis of complications, reoperation rates, and health-care costs. *Neuromodulation* 2013; 16:418-426; discussion 426-427.
14. Vangeneugden J. Implantation of surgical electrodes for spinal cord stimulation: Classical midline laminotomy technique versus minimal invasive unilateral technique combined with spinal anaesthesia. *Acta Neurochir Suppl* 2007; 97(pt 1):111-114.
15. Rigoard P, Luong AT, Delmotte A, et al. Multicolumn spinal cord stimulation lead implantation using an optic transligamentar minimally invasive technique. *Neurosurgery* 2013; 73:550-553.
16. Monlezun O, Voirin J, Roulaud M, et al. "MAST" prospective study: Value of minimal access spine technologies technique for multicolumn spinal cord stimulation surgical lead implantation in the context of a French multicentre randomized controlled trial (ESTIMET study). *Neurochirurgie* 2015; 61(suppl 1):S125-S130.
17. Rigoard P, Ounajim A, Goudman L, et al. Combining awake anesthesia with minimal invasive surgery optimizes intraoperative surgical spinal cord stimulation lead placement. *J Clin Med* 2022; 11:5575.
18. Yu Y, Li ZZ, Nishimura Y. Editorial: Endoscopic spine surgery. *Front Surg* 2023; 9:1127851.
19. Chung AS, McKnight B, Wang JC. Scientific view on endoscopic spine surgery: Can spinal endoscopy become

- a mainstream surgical tool? *World Neurosurg* 2021; 145:708-711.
20. Ahn Y. Current techniques of endoscopic decompression in spine surgery. *Ann Transl Med* 2019; 7(suppl 5):S169.
 21. Hwa Eum J, Hwa Heo D, Son SK, Park CK. Percutaneous biportal endoscopic decompression for lumbar spinal stenosis: A technical note and preliminary clinical results. *J Neurosurg Spine* 2016; 24:602-607.
 22. Park SM, Park J, Jang HS, et al. Biportal endoscopic versus microscopic lumbar decompressive laminectomy in patients with spinal stenosis: A randomized controlled trial. *Spine J* 2020; 20:156-165.
 23. Park HJ, Park SM, Song KS, et al. Evaluation of the efficacy and safety of conventional and biportal endoscopic decompressive laminectomy in patients with lumbar spinal stenosis (ENDO-B trial): A protocol for a prospective, randomized, assessor-blind, multicenter trial. *BMC Musculoskelet Disord* 2021; 22:1056.
 24. Kang MS, You KH, Han SY, Park SM, Choi JY, Park HJ. Percutaneous full-endoscopic versus biportal endoscopic posterior cervical foraminotomy for unilateral cervical foraminal disc disease. *Clin Orthop Surg* 2022; 14:539-547.
 25. Rock AK, Truong H, Park YL, Pilitsis JG. Spinal cord stimulation. *Neurosurg Clin N Am* 2019; 30:169-194.
 26. Nagel SJ, Lempka SF, Machado AG. Percutaneous spinal cord stimulation for chronic pain: Indications and patient selection. *Neurosurg Clin N Am* 2014; 25:723-733.
 27. Kim DD, Vakharyia R, Kroll HR, Shuster A. Rates of lead migration and stimulation loss in spinal cord stimulation: A retrospective comparison of laminotomy versus percutaneous implantation. *Pain Physician* 2011; 14:513-524.
 28. Veizi E, Hayek SM, North J, et al. Spinal cord stimulation (SCS) with anatomically guided (3D) neural targeting shows superior chronic axial low back pain relief compared to traditional SCS-LUMINA study. *Pain Med* 2017; 18:1534-1548.
 29. Gokaslan ZL, Telfeian AE, Wang MY. Introduction: Endoscopic spine surgery. *Neurosurg Focus* 2016; 40:E1.
 30. Park DY, Upfill-Brown A, Curtin N, et al. Clinical outcomes and complications after biportal endoscopic spine surgery: A comprehensive systematic review and meta-analysis of 3673 cases. *Eur Spine J* 2023; 32:2637-2646.

