

Retrospective Study

A Modified Unilateral Extrapedicular Approach Applied to Percutaneous Kyphoplasty to Treat Lumbar Osteoporotic Vertebral Compression Fracture: A Retrospective Analysis

Di Zhu, MD¹, Jun-Nan Hu, MB¹, Lei Wang, MB¹, Wei Cui, MD¹, Ji-Chao Zhu, MD¹, Song Ma, MD¹, Bao-Peng Tian, MD², and Bao-Ge Liu, MD, PhD¹

From: ¹Department of Orthopedic Surgery, Beijing Tiantan Hospital, Capital Medical University, Fengtai District, Beijing, China; ²Beijing HuiLongGuan Hospital, Peking University HuiLongGuan Clinical Medical School, Beijing, China

Address Correspondence:
Bao-Ge Liu, MD, PhD
Department of Orthopedic Surgery, Beijing Tiantan Hospital
Capital Medical University, No.119
South 4th Ring West Road
Fengtai District
Beijing, 100070, China
E-mail: baogeliu@hotmail.com

Disclaimer: Di Zhu and Junnan Hu equal contribution as first author. This work was supported by the funding from the National Key Research and Development Program of China (Grant No. 2018YFF0301103) and the Key Subject Construction Project of Fengtai District of Beijing (Grant No. 2-2-2-006-12-06).

Conflict of interest: Each author certifies that he or she, or a member of his or her immediate family, has no commercial association (i.e., consultancies, stock ownership, equity interest, patent/licensing arrangements, etc.) that might pose a conflict of interest in connection with the submitted manuscript.

Manuscript received: 10-08-2022
Revised manuscript received: 12-20-2022
Accepted for publication: 01-04-2022

Free full manuscript:
www.painphysicianjournal.com

Background: In recent years, many extrapedicular puncture methods have been applied to percutaneous kyphoplasty (PKP) in the treatment of osteoporotic vertebral compression fractures (OVCFs). However, these techniques were generally complex and had the risk of some puncture-related complications, which greatly limited the wide applications in PKP. Finding a safer and more feasible extrapedicular puncture method was rather important.

Objectives: To evaluate the treatment effect of modified unilateral extrapedicular PKP in patients with lumbar OVCFs clinically and radiologically.

Study Design: Retrospective study.

Setting: Department of Orthopedic Surgery, an affiliated hospital of a medical university.

Methods: Patients who were treated by modified unilateral extrapedicular PKP in our institution, from January 2020 to March 2021, were retrospectively enrolled. The degree of pain relief and functional recovery were evaluated by the Visual Analog Scale (VAS) and the Oswestry Disability Index (ODI), respectively. Radiologic results were assessed including anterior vertebral height (AVH) and kyphotic angle. In addition, volumetric analysis was performed to evaluate bone cement distribution. And the intraoperative data and complications were also recorded.

Results: A total of 48 patients with lumbar OVCFs were successfully treated by modified unilateral extrapedicular PKP. All patients experienced a significant decrease in VAS and ODI scores after surgery ($P < 0.01$) and maintained the statistical significance until the last follow-up ($P < 0.01$), as well as significant AVH restoration ($P < 0.01$) and kyphotic angle correction ($P < 0.01$) compared with preoperative corresponding values. Volumetric analysis showed that all cases of bone cement diffused across the midline of the vertebral body (VB), in which 43 patients (89.6%) presented optimal contralateral distribution with good or excellent bone cement spread. In addition, 8 patients (16.7%) experienced asymptomatic cement leakage, and no other severe complications, such as injuries to segmental lumbar arteries and nerve roots, were found.

Limitations: A noncontrol study with a small patient population and short follow-up duration.

Conclusions: Modified unilateral extrapedicular PKP, in which the puncture trajectory was advanced through the bottom of Kambin's triangle to or across the midline of VB for proper bilateral cement distribution, greatly alleviated back pain and restored the morphology of fractured vertebrae. It seemed to be a safe and effective alternative applied to treat lumbar OVCFs with appropriate patient selection.

Key words: Lumbar, osteoporotic vertebral compression fractures, extrapedicular, percutaneous kyphoplasty

Pain Physician 2023; 26:E191-E201

With the advent of population aging, osteoporotic vertebral compression fractures (OVCFs) have become serious public health issues, resulting in severe back pain, immobility, and spinal deformity (1). As a minimally invasive surgical treatment, percutaneous kyphoplasty (PKP) was widely used to treat OVCFs and reported to provide excellent improvement of clinical symptoms and restoration of the morphology of the fractured vertebra (2). Although the bilateral transpedicular approach was the typical puncture method in PKP, unipedicular PKP has been gaining popularity in recent years. Compared with the bilateral puncture, the unipedicular PKP could reduce the operation time, fluoroscopy radiation, and the presence of complications, such as cement leakage (3). However, it may be difficult to achieve proper bilateral distribution of bone cement in unipedicular PKP due to the limitation of pedicle width, in which bone cement was mainly restricted to the puncture side (4). And what is more, the vertebral pedicle puncture may also increase the risks of pedicle fracture and facet joint violation, which might cause spinal cord and nerve root injury and residue back pain after PKP (5). Another more effective and safer puncture technique might be required, as a result, the extrapedicular technique was proposed in unilateral PKP to avoid the aforementioned disadvantages (6). Initially, it was used in the mid- and high thoracic OVCFs by Boszczyk et al (8), in 2005, and was later applied to the lumbar vertebrae (7,8). The skin puncture point in this approach totally depended on the anatomical landmarks of the costovertebral joint and transverse process under fluoroscopy, which may be not clearly demonstrated in advanced osteoporotic patients during surgery. In recent years, some extrapedicular puncture methods have been applied to PKP; however, these techniques were generally complex and required a long learning curve, which limited the wide applications of extrapedicular PKP in the treatment of lumbar OVCFs (9-11).

In this article, our institution summarized and proposed a modified unilateral extrapedicular approach applied to treat lumbar OVCFs according to previous studies. In this newly designed puncture method, the trajectory was advanced from predetermined points of skin toward the superolateral part of the junction between the pedicle and vertebral body (VB) through the bottom of Kambin's triangle. We will demonstrate the procedures of this modified unilateral extrapedicular approach and show its therapeutic effect, radiologic results, and safety.

METHODS

Patient Population

This retrospective study was approved by the Institutional Review Board of Beijing Tiantan Hospital (KYSQ 2018-252-01). All patients involved in the study were given full explanations of the procedures and purpose, and informed consent was obtained. Totally 48 patients were enrolled with single-level lumbar OVCFs treated by the modified unilateral extrapedicular approach between January 2020 and March 2021. The inclusion criteria were as follows: (1) a painful single-level lumbar OVCF caused by lower energy force, with no more than 50% loss of vertebral height; (2) patients who did not respond to conventional treatment, including bed rest, bracing, and medical therapy (Visual Analog Scale [VAS] score > 5); (3) bone mineral density examined by dual-energy x-ray examination (T-score < -2.5); and (4) the fractured vertebrae were confirmed by magnetic resonance imaging (MRI), with the hypointense signal on T1-weighted images and hyperintense signal on T2-weighted images. The exclusion criteria were as follows: (1) vertebral fracture secondary to the vertebral tumor or infection; (2) burst fracture with the displacement of the fractured bony fragment into the spinal canal, or even complaint of neurological deficits; (3) multiple vertebral fractures with 2 or more levels; and (4) uncorrected coagulopathy or other severe comorbidities, which were contraindicated to surgical therapy.

Surgical Techniques

The procedures of PKP were all performed by the same well-experienced spine surgeon of our institution. Before surgery, we took the individual measurement of anatomical parameters based on preoperative MRI or computed tomography (CT) scans, including puncture distance and puncture angle. On axial MRI (Fig. 1), Point O was the center point of VB and Point A was the bone entry point, which was located in the superolateral junction between VB and the pedicle. Line OA was the puncture trajectory of modified unilateral extrapedicular PKP and the skin puncture point (Point B) was the intersection between Line OA and the surface of the skin. Then the puncture distance (x cm) and puncture angle in the coronal plane were recorded.

During surgery, all patients were placed in a prone position on a radiolucent table with local anesthesia. The C-arm was used for viewing anteroposterior (AP) and lateral projections of the spine to locate the center point of VB (Point O) and the bone entry point (Point A). A line connecting 2 points was drawn on the skin (Line

OA), and the skin puncture point (Point B) was marked along the line at the distance of x cm measured before surgery (Figs. 2a-2c). After making a 5-mm skin incision, a puncture needle was aimed at Point A, the bone entry point. When arriving at the cortex of the vertebrae, the end of the needle should be located at the superolateral part of VB, not beyond the medial margin of the ipsilateral pedicle on AP view, and the posterosuperior corner of VB on lateral view (Fig. 2d). Meantime, patients should be also asked to report any adverse events, such as radicular pain, hypesthesia, or numbness in the lower limbs. A minor adjustment of angle and direction might be required to make the needle tip point to the anterior-inferior corner of VB on lateral view. Then, the working cannula was established after the removal of the guide wire. A bone drill was inserted through the working cannula to create the place for the balloon catheter, and finally reached or exceeded the midline of VB on AP view and anterior one-third of VB on lateral view (Figs. 2e-2g). The remaining kyphoplasty procedures were almost identical to those in the standard balloon kyphoplasty (12). Then the polymethylmethacrylate (PMMA) bone cement was injected slowly into VB at low pressure (Figs. 2h-2j). Under fluoroscopic monitoring, the injection was continued until the cement reached the posterior one-fourth of VB or the cement leakage was observed.

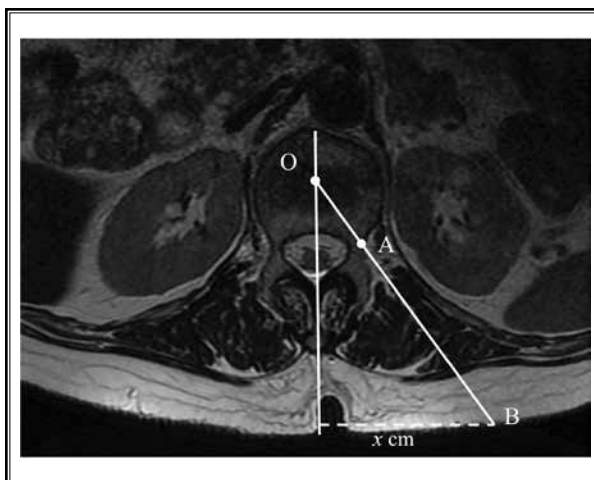


Fig. 1. The puncture trajectory and skin puncture point of modified unilateral extrapedicular PKP were determined from preoperative axial MRI or CT. Point O was the center point of VB, and Point A was the center point of VB, located in the superolateral junction between the pedicle and VB. The intersection of Line OA and the surface of skin was Point B. Line BO was the puncture trajectory and Point B was skin puncture point. Then, the distance of Point B to midline (x cm) and the angle between Line BO and midline were measured. PKP, percutaneous kyphoplasty; MRI, magnetic resonance imaging; CT, computed tomography; VB, vertebral body.

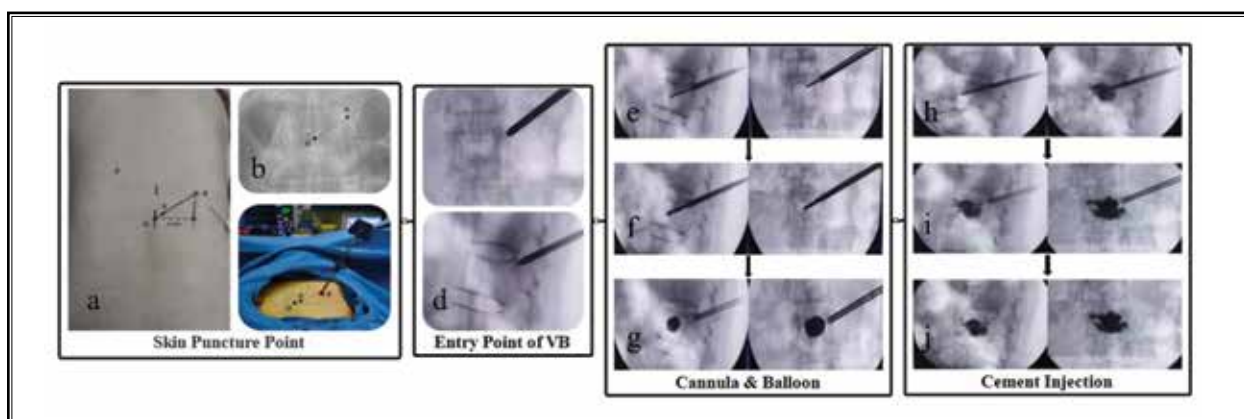


Fig. 2. The instruction of procedures of modified unilateral extrapedicular PKP in detail. (a-c) The establishment of skin puncture point during surgery. Point O was the projection of center point of VB, and Point A was the projection of entry point of VB. The skin puncture point, Point B, was determined along Line OA at the distance of x cm measured preoperatively. (d) The entry point of VB was located at the superolateral part of the pedicle on AP view, and the slightly superior part of the junction between the pedicle and VB on lateral view under fluoroscopy. (e-g) The tip of the working cannula was advanced to anterior part of VB across the midline. Then the balloon was inserted and expanded to restore AVH. (h, i) The bone cement was slowly injected into VB until cement reached posterior one-fourth of VB or cement leakage was observed under fluoroscopic monitoring. Ensuring that no cement following the bone filler when pulling it out. (j) AP and lateral radiographs showed the proper bilateral cement distribution during surgery. PKP, percutaneous kyphoplasty; VB, vertebral body; AVH, anterior vertebral height; AP, anteroposterior.

The working cannula was not removed until the bone cement hardened.

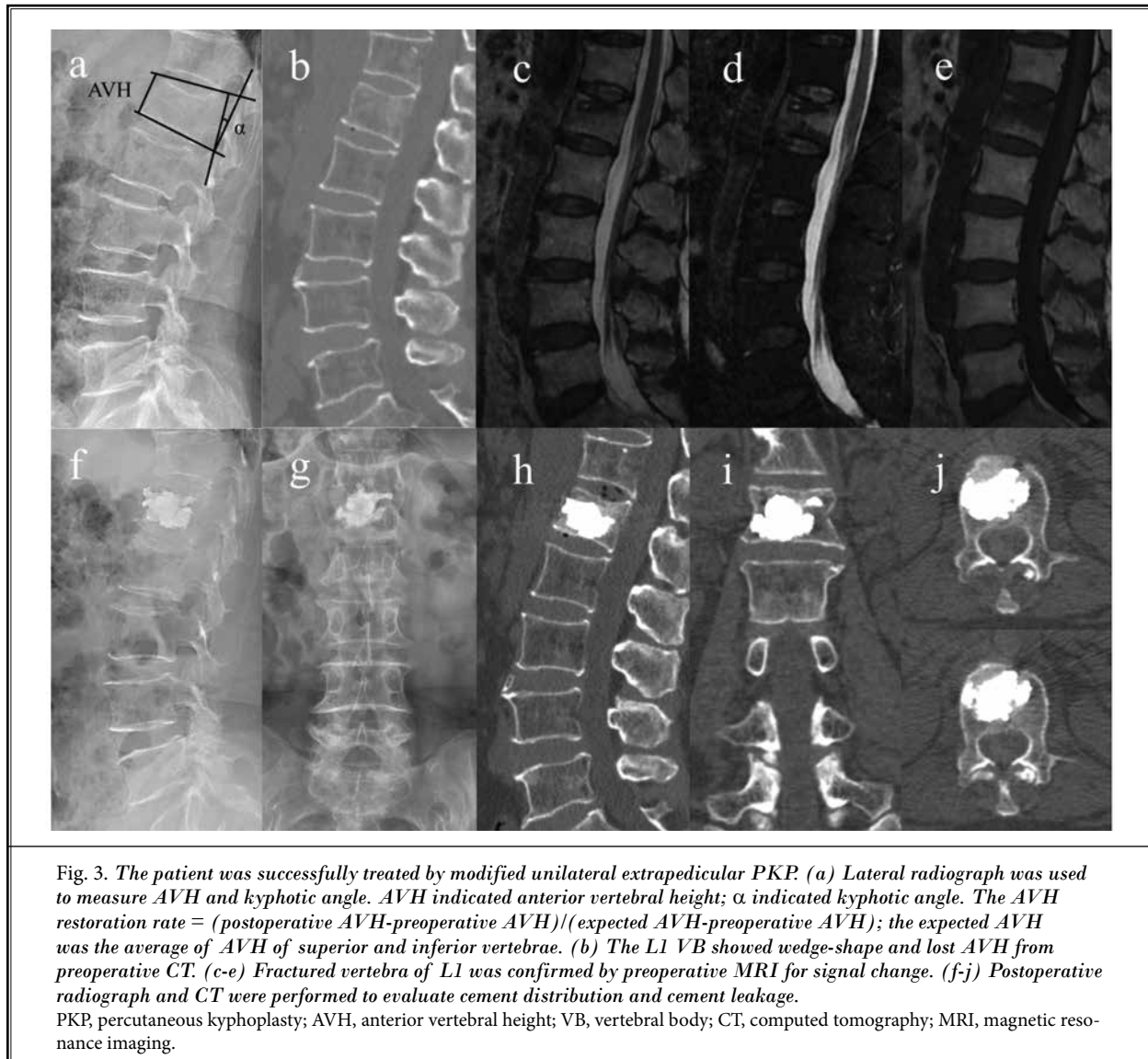
After surgery, all patients were encouraged to mobilize after a 2-hour flat in bed and were discharged 1 day later. Regular antiosteoporosis therapy was recommended to improve the quality of bone and prevent the presence of refracture.

Outcome Measurements

Clinical and radiologic assessments were performed preoperatively, one day postoperatively, and one year postoperatively. As for clinical results, the severity of back pain was evaluated by using the VAS score, and the Oswestry Disability Index (ODI) was used to evalu-

ate the functional outcome. For radiologic results, preoperative and postoperative x-rays were observed to analyze the degree of anterior vertebral height restoration (AVH) and kyphotic deformity improvement. The AVH was defined as the distance between the anterior points of superior and inferior endplates of VB. The calculation of the AVH restoration rate was as follows: $(\text{postoperative AVH} - \text{preoperative AVH}) / (\text{expected AVH} - \text{preoperative AVH})$, and the expected AVH was the average AVH of superior and inferior vertebrae (13). The measurement of the kyphotic angle was taken from the superior endplate of the fractured vertebra to the inferior endplate of the fractured vertebra.

The postoperative CT scan was taken to evalu-



ate bone cement distribution (Fig. 3). The volumetric analysis of cement distribution involved the volume fraction of bone cement and contralateral cement diffusion grade, which was performed by using 3D Slicer software (www.slicer.org), an open-source 3D visualization software (14). The models were reconstructed in the range of threshold (226-3071) for the fractured VB and threshold (1000-3071) for bone cement (15,16). The volume fraction was defined as follows: (cement distribution volume/fractured VB volume) * 100% (17). Then the model of cement was separated into 2 parts along the midline of VB, including the puncture side and the contralateral side (Fig. 4a). The contralateral cement diffusion grade was calculated as follows: contralateral cement diffusion ratio = (cement volume of contralateral side/cement volume of puncture side) * 100%. Grade 1 (< 50%) indicated fair PMMA spread, grade 2 (50% to 75%) indicated good PMMA spread, and grade 3 (> 75%) indicated excellent PMMA spread (Figs. 4b and 4c).

Additionally, cement leakage was also confirmed by axial CT scans and then recorded the location of leakage, including paraspinal leakage, intervertebral leakage, and intraspinal leakage. And other procedure-related complications were recorded, such as pulmonary embolism, injury to lumbar arteries (LAs) and nerve roots during surgery, and retroperitoneal hematoma, adjacent vertebral fracture after surgery.

Statistical Analysis

Statistical analyses were performed by SPSS Version 23.0 software (IBM Corporation, Armonk,

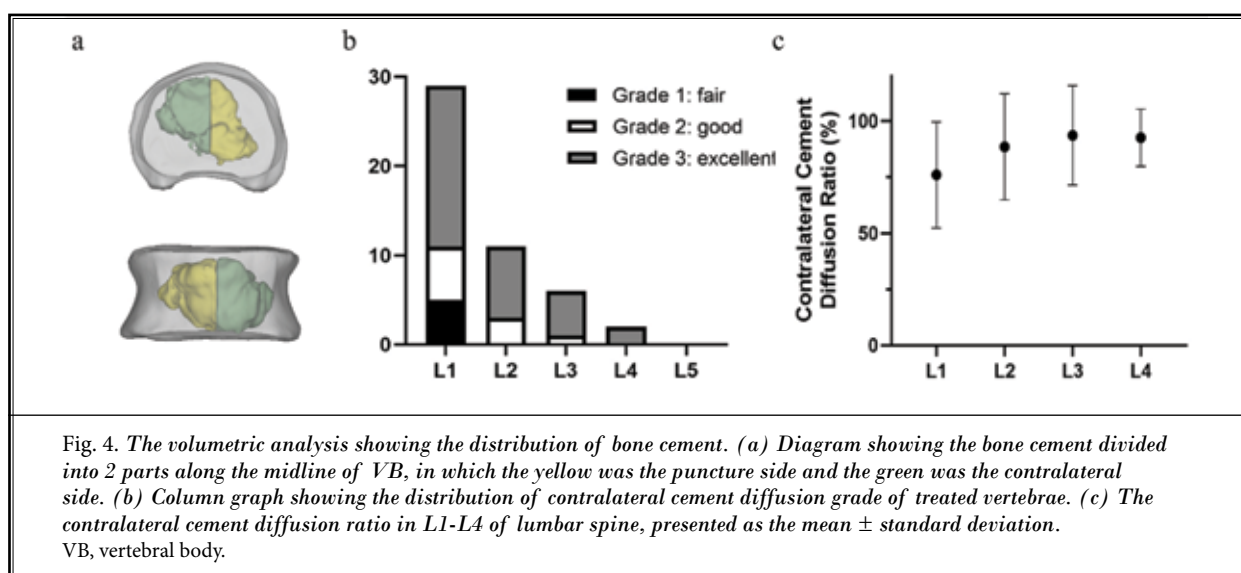
NY). The quantitative data were presented as the mean \pm standard deviation and the categorical data were presented as numbers and percentage values. The paired t test was performed when comparing the differences between preoperative and postoperative outcomes. The $P < 0.01$ indicated statistical significance.

RESULTS

Patient Characteristics

A total of 48 consecutive patients (42 women and 6 men; age range 55-85 years, the mean of 70.9 years) were enrolled in this study, with a mean follow-up duration of 14.3 months (range 12-24 months). The mean body mass index (BMI) was 25.1 ± 3.0 kg/m² and the mean T-score was -3.1 ± 0.6 . The fractured vertebrae were from L1 to L4 (L1 in 29, L2 in 11, L3 in 6, and L4 in 2) and the mean symptom duration was 6.3 days (range 1-30 days) (Table 1).

All patients were successfully treated by modified unilateral extrapedicular PKP, and no case of operation failure related to difficulties in the surgical technique was found. During surgery, the average puncture angle in the coronal plane was $42.2 \pm 6.1^\circ$ and the average volume of injected bone cement was 4.3 ± 0.7 mL (volume fraction of $17.4 \pm 4.5\%$). The mean frequency of fluoroscopy was 21.7 ± 3.1 and the mean operation time was 38.5 ± 7.1 min. Table 1 summarized detailed general data of patients enrolled in this study.



Clinical and Radiologic Results

The clinical assessments and radiologic measurements were shown in Table 2. The mean preoperative VAS score was 7.9 ± 0.9 and improved significantly to 2.9 ± 0.7 after surgery ($P < 0.01$) and maintained 2.0 ± 0.8 until the last follow-up ($P < 0.01$). The mean ODI scores showed a statistically significant decrease from preoperative 73.3 ± 8.1 to 33.7 ± 5.4 after surgery ($P < 0.01$) and to 22.8 ± 4.0 at last follow-up ($P < 0.01$).

The mean preoperative AVH and kyphotic angle, which were 21.5 ± 2.9 mm and $13.0 \pm 3.9^\circ$, were significantly restored to 24.5 ± 2.1 mm ($P < 0.01$) and $6.5 \pm$

2.6° ($P < 0.01$) after surgery, respectively, with the AVH restoration rate of $60.6 \pm 9.5\%$. Until the last follow-up, the mean AVH and kyphotic angle were maintained at 24.0 ± 2.2 mm and $8.0 \pm 2.8^\circ$, showing the statistical significance from preoperative corresponding values ($P < 0.01$), and the AVH restoration rate was $51.5 \pm 10.1\%$.

Volumetric Analysis

The graph of bone cement distribution was shown in Figs. 4b-4c. All treated vertebrae of bone cement were dispersed to the contralateral side and located in the anterior-middle part of VB. And the situation of contralateral cement diffusion grade was as follows: grade 1 in 5 cases (10.4%) showing fair PMMA spread, grade 2 in 10 cases (20.8%), and grade 3 in 33 cases (68.8%) showing good or excellent PMMA spread, with the mean contralateral cement diffusion ratio of $81.7 \pm 23.7\%$ in total population.

Complications

Among 48 treated vertebrae, bone cement leakage was found in 8 patients (16.7%), in which cement leakage occurred into the epidural space in one case (2.1%), the adjacent disc in 3 cases (6.3%), and the paraspinal muscles in 4 cases (8.3%), without obvious clinical symptoms (Table 1). No other severe adverse events were found, such as segmental LAs injury, spinal canal or nerve roots injury, and retroperitoneal hematoma. The adjacent vertebral refracture occurred in one case within one year follow-up, accepting another PKP.

DISCUSSION

Since the first proposal of PKP by Garfin et al (18) in 1998, it has been widely used in the treatment of OVCFs for the last 20 years, and various puncture techniques were developed and applied to PKP in clinical practice. The early puncture methods were bilateral and unilateral transpedicular approaches (20). Although the unipedicular reduced the operation time and radiation exposure compared with bipedicular PKP, it cannot easily achieve proper bilateral distribution of bone cement due to the constraint of pedicles. Additionally, a vertebral pedicle puncture may be the risk of damage to the posterior structure of the vertebrae, including the cortex of the pedicles and facet joints. Therefore, the extrapedicular approach was proposed in unilateral PKP for better cement distribution and lower puncture-related complications (21). However, no standardization for the procedures of extrapedicular PKP in the application of lumbar OVCF was made,

Table 1. *The general data of patients.*

Patients (n)	48
Age	70.9 (55 to 85)
Gender (women n [%])	42 (87.5)
BMI (kg/m ²)	25.1 \pm 3.0
BMD (T-score)	-3.1 \pm 0.6
Symptom Duration (d)	6.3 (1 to 30)
Follow-up Duration (mo)	14.3 (12 to 24)
Injected Cement Volume (mL)	4.3 \pm 0.7
Volume Fraction of Cement (%)	17.4 \pm 4.5
Puncture Angle ($^\circ$)	42.2 \pm 6.1
Operation Time (min)	38.5 \pm 7.1
Fluoroscopy Times	21.7 \pm 3.1
Cement Leakage (n [%])	
Total Leakage	8 (16.7)
Intraspinal Leakage	1 (2.1)
Paraspinal Leakage	4 (8.3)
Intervertebral Leakage	3 (6.3)

Abbreviations: BMI, body mass index; BMD, bone mineral density.

Table 2. *The clinical and radiologic results of patients.*

	Preoperative	Postoperative 1 day	Postoperative 1 year
VAS Score	7.9 \pm 0.9	2.9 \pm 0.7*	2.0 \pm 0.8†
ODI Score	73.3 \pm 8.1	33.7 \pm 5.4*	22.8 \pm 4.0†
AVH (mm)	21.5 \pm 2.9	24.5 \pm 2.1*	24.0 \pm 2.2†
AVH Restoration (%)	/	60.6 \pm 9.5	51.5 \pm 10.1
Kyphotic Angle ($^\circ$)	13.0 \pm 3.9	6.5 \pm 2.6*	8.0 \pm 2.8†

Abbreviations: VAS, Visual Analog Scale; ODI, Oswestry Disability Index; AVH, anterior vertebral height.

* Postoperative 1 day vs preoperative, $P < 0.01$.

† Postoperative 1 year vs preoperative, $P < 0.01$.

including the establishment of the skin puncture points and entry points of VB (Table 3). Ryu et al (22) introduced the far-lateral extrapedicular approach, in which the needle was advanced from 1 cm lateral to the lateral one-third of the transverse process on AP view and along the direction of the pedicle on lateral view, penetrating the cortex of the transverse process and

access to VB. Mishra et al (23) reported another extrapedicular approach that the skin puncture points were located on the line bisecting the affected VB horizontally on AP view, and then the needle entered VB via the lateral wall. These techniques were quite complex and surgeons who were not well-skilled would require repeated adjustment of puncture needle and intraop-

Table 3. *The summarization of technical points of various extrapedicular approach in the lumbar vertebrae.*

Author	Time	Approach	Skin Puncture Point	Puncture Angle	Entry Point of Vertebrae
Beall et al (7)	2007	Parapedicular approach	A line was drawn from the contralateral inferior vb corner to the ipsilateral superior vb corner and extended out of vb for a distance equal to the width of the mid portion of vb, which was the skin puncture point	45°	Junction between the superior portion of the pedicle and the posterior portion of VB
Ryu et al (22)	2007	Far-lateral extrapedicular approach	1 cm lateral to the lateral one-third of the left transverse process on AP view	45° to 50°	The lateral wall of the junction between the pedicle and VB, through the transverse process
Ryu et al (6)	2009	Far-lateral extrapedicular approach	Line B was drawn along the contralateral border of VB; line C was drawn along the outmost border of the ipsilateral pedicle; line A was drawn parallel to line B, and apart from line C by 2.5 times of distance between line B and line C; then the intersection of line A and the line connecting contralateral lower corner and ipsilateral upper corner of VB was the skin puncture point	45° to 50°	The lateral wall of the junction between the pedicle and VB, through the transverse process
Cho et al (12)	2011	Unilateral extrapedicular approach	1-3 cm lateral to the tip of the left transverse process on AP view	Measured before surgery	Superolateral junction between the pedicle and VB, over the transverse process
Ringer et al (21)	2013	Lumbar extrapedicular approach	Connecting the center points of bilateral pedicle and drawing its midline; 8 cm, 9 cm, 10 cm, 11 cm lateral to the midline in L1, L2, L3, L4, respectively	Approximately 60°	The lateral wall of the junction between the pedicle and VB, through the transverse process
Wang et al (10)	2019	Kambin's triangle approach	5-7 cm lateral to the midline on the horizontal line of the inferior endplate of the upper VB on AP view	Measured before surgery	The superolateral area of VB on AP view, and the posterosuperior side of VB on the lateral view
Mishra et al (23)	2020	Single balloon extrapedicular approach	A line was drawn perpendicular to the midline of VB and bisecting the affected level on AP view, the skin puncture point was established along the line at the preoperatively measured distance	45°	The lateral wall of VB
Wang et al (9)	2020	Modified extrapedicular approach	A line was drawn connecting the upper edge of the ipsilateral pedicle and the lower edge of the contralateral pedicle, the skin puncture point was established along the line at the preoperatively measured distance	Measured before surgery	Outer upper edge of the pedicle on AP view and upper edge of the pedicle in lateral view
Zhuo et al (11)	2021	Modified transverse process-pedicle approach	Measured/planned before surgery (without clear explanation of location during the surgery)	Measured before surgery	The superolateral junction between the pedicle and the vertebral transitional location, through the transverse process

Abbreviations: VB, vertebral body; AP, anteroposterior.

erative fluoroscopy, which might increase the patient's pain and radiation exposure. In addition, subsequent clinical studies (24-26) reported the complications of the injury to segmental LAs and nerve roots. Consequently, a safer and more feasible puncture method was needed to be applied in unilateral extrapedicular PKP to treat lumbar OVCFs.

According to previous studies (4,11,12,20) of extrapedicular PKP, the puncture method used in our institution was the modified unilateral extrapedicular approach, that the working channel passed through the bottom of Kambin's triangle to the center point of the fractured VB. The entry point of VB was the superolateral junction between the pedicle and VB, which was free of LAs and nerve roots. Furthermore, the procedures of this approach were quite simplified and controllable. The projections of the superolateral corner of the pedicle on AP view and the posterosuperior corner of VB on lateral view under fluoroscopy were remarkable, which facilitated the location of the bone entry point and the puncture process. Once reaching the cortex of VB safely, due to paraspinal soft tissues, the puncture angle and direction of the instrument could be easily adjusted toward the anterior-inferior corner of VB. It was simple for spine surgeons to perform this PKP with clear bone landmarks and standardized puncture processes, avoiding repeated adjustment and intraoperative fluoroscopy.

One of the main advantages of extrapedicular PKP was that it could provide proper bilateral distribution of bone cement by the unilateral puncture. In unipedicular PKP, bone cement was mostly located in the puncture side inside the augmented VB due to the limited puncture angle, which might result in recompression and progressing kyphosis (25). Lien et al (26) reported that the pedicle angles in the coronal plane were 8.3° to 14.1° in the L1-L3 vertebrae. However, our results indicated that the puncture angle in modified unilateral extrapedicular PKP was 42.2° . The trajectory could easily reach or exceed the midline of VB at a larger extraversion angle during surgery. What is more, it was free of the constraints of the pedicle, which made it possible to adjust the direction and depth of the cannula flexibly to the optimal position for cement injection and dispersion under intraoperative fluoroscopy. Therefore, this approach could obtain a better contralateral disperse of bone cement compared with other puncture techniques.

Some clinical and biomechanical studies (27,28) have pointed that cement distribution had correla-

tions with curative effects of OVCFs by PKP. Liebschner et al (29) reported that only a small amount of bone cement with symmetric distribution was needed to recover vertebral stiffness to its intact value. He et al (30) proposed that proper distribution facilitated the clinical and radiologic improvements. Patients in our study experienced great pain relief and function recovery, with significant pre- to postoperative AVH restoration and kyphotic angle correction. The pattern of bone cement distribution might account for it. In our volumetric analysis, all vertebrae of cement diffused across the midline and presented optimal bilateral distribution, and the cement was mainly located at the anterior-middle part of VB, filling the fractured areas. Appropriate cement distribution inside the augmented VB, the biomechanical properties recovery, and stability reconstruction of the fractured VB greatly ensured the therapy effects.

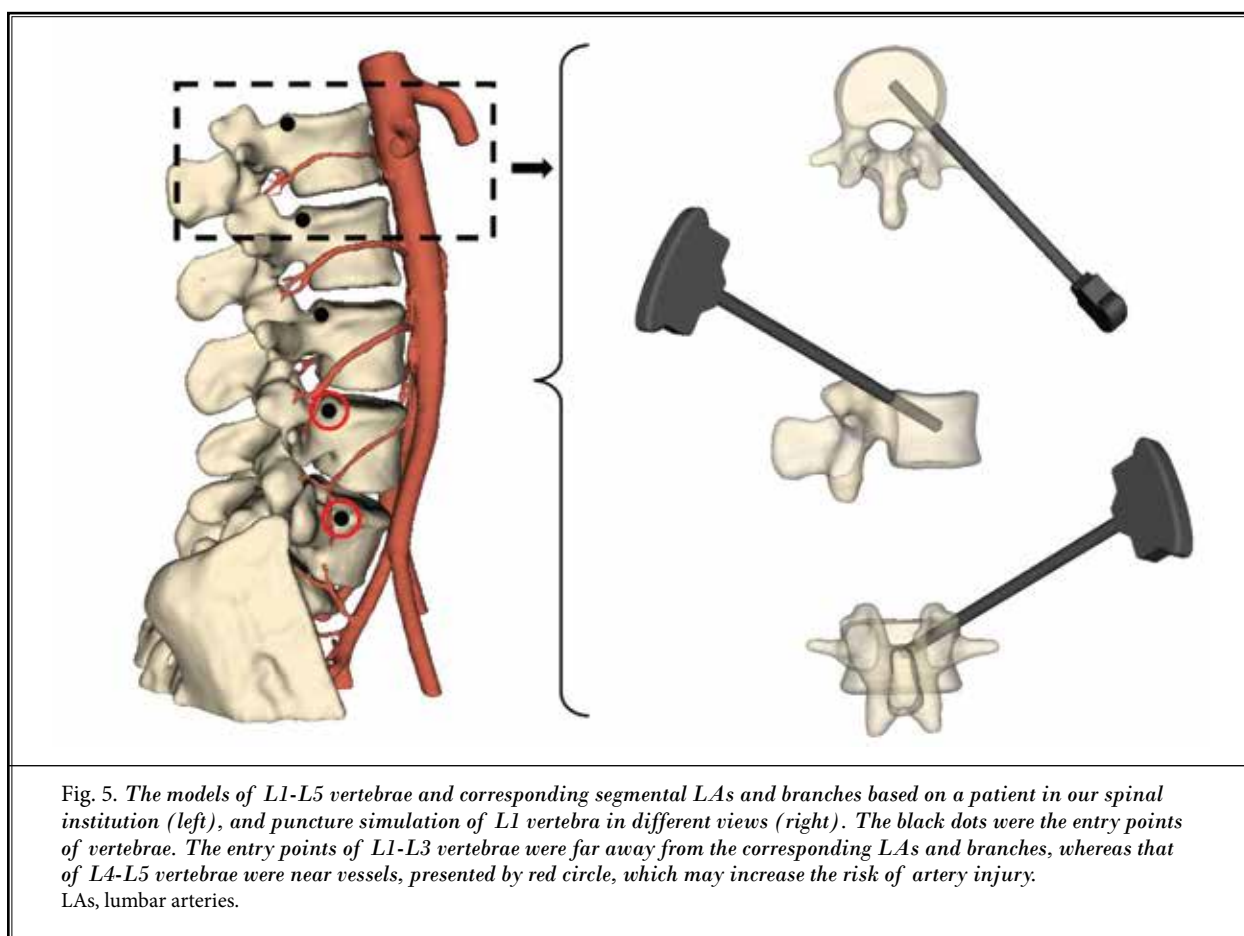
As to cement leakage, the incidences in different puncture methods varied a lot, and for transpedicular PKP, the incidences have been reported to range from 9.3% to 30.6% (31). In our results, a total of 8 cases (16.7%) experienced asymptomatic cement leakage, showing a low and comparable incidence (Table 1). Previous studies (30,34) have reported that a large amount of cement was the risk factor for cement leakage. The average volume of cement in the modified unilateral extrapedicular PKP was only 4.3 mL. The small amount of cement with central distribution inside VB further reduced cement leakage. In addition, the extrapedicular puncture maintained the integrity of the pedicle and avoided the iatrogenic damage to the inner wall, decreasing the incidence of intraspinal leakage. However, we noticed that several early patients in our spinal institution presented paraspinal leakage into soft tissues near the foraminal area via the bone entry point of VB. Such leakage, although unlikely to cause serious neurological symptoms, was undesirable. We tried to clear the instrument of any residual PMMA before removal from VB to avoid leakage into the surrounding soft tissues.

Another severe complication of extrapedicular PKP was the damage to segmental LAs and nerve roots, which has been reported (33). Heo et al (34) reported a case of segmental LA injury following extrapedicular PKP. They punctured the cortex of the lateral wall of VB, where existed the path of the segmental LA, and the forming retroperitoneal hematoma irritated the nearby nerve root, causing severe radiated leg pain and numbness. Then, some researchers began to draw

attention to the anatomical relationships among the LAs, pedicle, and VB (35,36). Xu et al (37) suggested that the safe puncture point should be located at the posterosuperior corner of the L1-L3 vertebrae for no vessels passing. In the current study, the entry point of VB in modified unilateral extrapedicular PKP was just located at the safe puncture zone, the superolateral junction of the pedicle and VB, without LAs passing by. In addition, it passed through the bottom of Kambin's triangle and kept away from exiting nerve roots. The aforementioned features reduced the risk of LAs and nerve injuries, ensuring the safety of procedures. However, it had some limitations in L4 or L5 levels because the corresponding segmental LA and its lateral branches were mostly passed near the entry point of VB (Fig. 5), resulting in damage to vessels.

Meantime, in our experience, we found that some other patients with lumbar OVCFs may not be definitely suitable for modified unilateral extrapedicular approach applied to PKP. 1) Unlike an instrument ad-

vanced through the pedicle in transpedicular PKP, very little bony purchase was obtained at the bone entry point (Point A) in modified unilateral extrapedicular PKP, providing the poor "anchor effect." Care was taken to avoid dislodging the puncture needle or cannula from VB, especially in patients with a higher BMI and thick paraspinal soft tissues. 2) Before reaching the cortex of VB, the puncture needle would pass through a long distance of soft tissues in this puncture technique. For those patients who were taking anticoagulant therapy or suffering from coagulopathy disorders, it may increase the risk of paraspinal muscle injury and hematoma, causing postoperative residual dorsal pain. 3) The bone entry point (Point A) was located near the intervertebral foramen region. For those with the collapse of intervertebral space or spinal scoliosis resulting in severe lumbar foraminal stenosis, puncture through the Kambin's triangle may cause injury to exiting nerve roots of the superior vertebra. 4) Patients with severe compression fracture (i.e., vertebral height loss of more



than 50%) should be cautiously treated because the entry point of VB of this technique was higher than that in transpedicular PKP. It may be difficult to penetrate the anterior part of VB to restore AVH and correct kyphosis.

Limitations

The limitations of our study were the small sample size, short follow durations, and its retrospective design. The long-term prognosis and complications of modified unilateral extrapedicular remained extrapedicular PKP remained uncertain. In addition, the lack of a control group failed to clearly show if the modified unilateral extrapedicular PKP had superiority over traditional puncture methods in clinical and radiologic results. In the future, we will focus on the long-term

follow-up comparison study of different puncture techniques in a larger patient population to verify the treatment effects of modified unilateral extrapedicular PKP in lumbar OVCFs.

CONCLUSIONS

The modified unilateral extrapedicular PKP, in which the puncture trajectory was advanced through the bottom of Kambin triangle to or across the midline of VB for proper bilateral cement distribution, greatly alleviated back pain and restored the morphology of fractured vertebrae. It seemed to be a safe and effective alternative applied to treat lumbar OVCFs with appropriate patient selection.

REFERENCES

- Long Y, Yi W, Yang D. Advances in vertebral augmentation systems for osteoporotic vertebral compression fractures. *Pain Res Manag* 2020; 2020:3947368.
- Hardouin P, Fayada P, Leclot H, et al. Kyphoplasty. *Joint Bone Spine* 2002; 69:256-261.
- Chen C, Chen L, Gu Y, et al. Kyphoplasty for chronic painful osteoporotic vertebral compression fractures via unipedicular versus bipedicular approachment: A comparative study in early stage. *Injury* 2010; 41:356-359.
- Lin J, Qian L, Jiang C, et al. Bone cement distribution is a potential predictor to the reconstructive effects of unilateral percutaneous kyphoplasty in OVCFs: A retrospective study. *J Orthop Surg Res* 2018; 13:140.
- Schmidt R, Cakir B, Mattes T, et al. Cement leakage during vertebroplasty: An underestimated problem? *Eur Spine J* 2005; 14:466-473.
- Ryu KS, Huh HY, Jun SC, et al. Single-Balloon kyphoplasty in osteoporotic vertebral compression fractures: Far-Lateral extrapedicular approach. *J Korean Neurosurg Soc* 2009; 45:122-126.
- Beall DP, Braswell JJ, Martin HD, et al. Technical strategies and anatomic considerations for parapedicular access to thoracic and lumbar vertebral bodies. *Skeletal Radiol* 2007; 36:47-52.
- Boszczyk BM, Bierschneider M, Hauck S, et al. Transcostovertebral kyphoplasty of the mid and high thoracic spine. *Eur Spine J* 2005; 14:992-999.
- Wang LM, Liu FY, Lu K, et al. Modified extrapedicular kyphoplasty for the treatment of lumbar compression fracture: Case report and technical note. *Medicine (Baltimore)* 2020; 99:e19053.
- Wang YF, Shen J, Li SY, et al. Kambin triangle approach in percutaneous vertebroplasty for the treatment of osteoporotic vertebral compression fractures. *Medicine (Baltimore)* 2019; 98:e17857.
- Zhuo Y, Liu L, Wang H, et al. A modified transverse process-pedicle approach applied to unilateral extrapedicular percutaneous vertebroplasty. *Pain Res Manag* 2021; 2021:6493712.
- Cho SM, Nam YS, Cho BM, et al. Unilateral extrapedicular vertebroplasty and kyphoplasty in lumbar compression fractures: Technique, anatomy and preliminary results. *J Korean Neurosurg Soc* 2011; 49:273-277.
- Lieberman IH, Dudeney S, Reinhardt MK, et al. Initial outcome and efficacy of "kyphoplasty" in the treatment of painful osteoporotic vertebral compression fractures. *Spine (Phila Pa 1976)* 2001; 26:1631-1638.
- Fedorov A, Beichel R, Kalpathy-Cramer J, et al. 3D Slicer as an image computing platform for the Quantitative Imaging Network. *Magnetic Resonance Imaging* 2012; 30:1323-1341.
- Jin YJ, Yoon SH, Park KW, et al. The volumetric analysis of cement in vertebroplasty: Relationship with clinical outcome and complications. *Spine (Phila Pa 1976)* 2011; 36:E761-E772.
- Limthongkul W, Karaikovic EE, Savage JW, et al. Volumetric analysis of thoracic and lumbar vertebral bodies. *Spine J* 2010; 10:153-158.
- Nieuwenhuijse MJ, Bollen L, van Erkel AR, et al. Optimal intravertebral cement volume in percutaneous vertebroplasty for painful osteoporotic vertebral compression fractures. *Spine (Phila Pa 1976)* 2012; 37:1747-1755.
- Garfin SR, Yuan HA, Reiley MA. New technologies in spine: kyphoplasty and vertebroplasty for the treatment of painful osteoporotic compression fractures. *Spine (Phila Pa 1976)* 2001; 26:1511-1515.
- Rousing R, Andersen MO, Jespersen SM, et al. Percutaneous vertebroplasty compared to conservative treatment in patients with painful acute or subacute osteoporotic vertebral fractures: Three-Months follow-up in a clinical randomized study. *Spine (Phila Pa 1976)* 2009; 34:1349-1354.
- Zhang H, Zhao B, Luo L, et al. The puncture methods of extrapedicular PVP (PKP): A narrative review. *Interdisciplinary Neurosurgery* 2021; 25:101250.
- Ringer AJ, Bhamidipaty SV. Percutaneous access to the vertebral bodies: A video and fluoroscopic overview of access techniques for trans-, extra-, and infrapedicular approaches. *World Neurosurg* 2013; 80:428-435.
- Ryu KS, Park CK, Kim MK, et al. Single balloon kyphoplasty using far-lateral extrapedicular approach: Technical note and preliminary results. *J Spinal Disord Tech* 2007; 20:392-398.
- Mishra PK, Dwivedi R, Dhillon CS.

- Osteoporotic vertebral compression fracture and single balloon extrapedicular kyphoplasty: Findings and technical considerations. *Bull Emerg Trauma* 2020; 8:34-40.
24. Biafora SJ, Mardjetko SM, Butler JP, et al. Arterial injury following percutaneous vertebral augmentation: A case report. *Spine (Phila Pa 1976)* 2006; 31:E84-E87.
 25. Lee JH, Lee DO, Lee JH, et al. Comparison of radiological and clinical results of balloon kyphoplasty according to anterior height loss in the osteoporotic vertebral fracture. *Spine J* 2014; 14:2281-2289.
 26. Lien SB, Liou NH, Wu SS. Analysis of anatomic morphometry of the pedicles and the safe zone for through-pedicle procedures in the thoracic and lumbar spine. *Eur Spine J* 2007; 16:1215-1222.
 27. Chen B, Li Y, Xie D, et al. Comparison of unipedicular and bipedicular kyphoplasty on the stiffness and biomechanical balance of compression fractured vertebrae. *Eur Spine J* 2011; 20:1272-1280.
 28. Sun HB, Jing XS, Liu YZ, et al. The optimal volume fraction in percutaneous vertebroplasty evaluated by pain relief, cement dispersion, and cement leakage: A prospective cohort study of 130 patients with painful osteoporotic vertebral compression fracture in the thoracolumbar vertebra. *World Neurosurg* 2018; 114:e677-e688.
 29. Liebschner MA, Rosenberg WS, Keaveny TM. Effects of bone cement volume and distribution on vertebral stiffness after vertebroplasty. *Spine (Phila Pa 1976)* 2001; 26:1547-1554.
 30. He X, Li H, Meng Y, et al. Percutaneous kyphoplasty evaluated by cement volume and distribution: An analysis of clinical data. *Pain Physician* 2016; 19:495-506.
 31. Chen WC, Tsai SHL, Goyal A, et al. Comparison between vertebroplasty with high or low viscosity cement augmentation or kyphoplasty in cement leakage rate for patients with vertebral compression fracture: A systematic review and network meta-analysis. *Eur Spine J* 2021; 30:2680-2690.
 32. Chen C, Fan P, Xie X, et al. Risk factors for cement leakage and adjacent vertebral fractures in kyphoplasty for osteoporotic vertebral fractures. *Clin Spine Surg* 2020; 33:E251-E255.
 33. Liu L, Li N, Wang Q, et al. Iatrogenic lumbar artery injury in spine surgery: A literature review. *World Neurosurg* 2019; 122:266-271.
 34. Heo DH, Cho YJ. Segmental artery injury following percutaneous vertebroplasty using extrapedicular approach. *J Korean Neurosurg Soc* 2011; 49:131-133.
 35. Ma R, Zheng Z, Zhou X, et al. An anatomical study of the origins courses and distributions of the transverse branches of lumbar arteries at the L1-L4 levels. *Eur Spine J* 2022; 31:678-684.
 36. Seker M, Cicekcibasi AE, Salbacak A, et al. A morphometric study and variations on the lumbar arteries of human fetuses. *Ann Anat* 2005; 187:135-140.
 37. Xu J, Fan S, Ni Y, et al. An anatomical feasibility study using CTA reconstruction for modified percutaneous lumbar vertebroplasty. *BMC Musculoskeletal Disorders* 2022; 23:693.

