

Prospective Study

Comparison of Unilateral and Bilateral Percutaneous Kyphoplasty for Bone Cement Distribution and Clinical Efficacy: An Analysis Using Three-Dimensional Computed Tomography Images

Yuting Zhang, MS¹, Xiujin Chen, MS², Jiachen Ji, BS³, Zhengwei Xu, MD², Honghui Sun, MD², Liang Dong, MD², and Dingjun Hao, MD²

From: ¹The Department of Radiology, Hong-Hui Hospital, Xi'an Jiaotong University College of Medicine, Xi'an, Shannxi, China; ²The Department of Orthopedic, Hong-Hui Hospital, Xi'an Jiaotong University College of Medicine, Xi'an, Shannxi, China; ³Xi'an Medical University, Xi'an, Shannxi, China

Address Correspondence:
Liang Dong, MD
The Department of Radiology
Hong-Hui Hospital
Xi'an Jiaotong University
College of Medicine
Xi'an, Shannxi, China
E-mail: dongliang-526@163.com

Disclaimer: Yuting Zhang, Xiujin Chen, and Jiachen Ji contributed equally to this study. There was no external funding in the preparation of this manuscript.

Conflict of interest: Each author certifies that he or she, or a member of his or her immediate family, has no commercial association (i.e., consultancies, stock ownership, equity interest, patent/licensing arrangements, etc.) that might pose a conflict of interest in connection with the submitted manuscript.

Manuscript received: 01-03-2022
Revised manuscript received:
03-24-2022
Accepted for publication:
04-11-2022

Free full manuscript:
www.painphysicianjournal.com

Background: Percutaneous kyphoplasty (PKP) is an effective treatment for osteoporotic vertebral compression fractures (OVCF). Comparisons of different approaches have previously focused primarily on x-rays. Three-dimensional (3D) computed tomography (CT) enables better imaging evaluation of bone cement distribution.

Objectives: To compare the CT imaging parameters and clinical efficacies of unilateral and bilateral PKP.

Study Design: This was a prospective, nonrandomized controlled study.

Setting: Department of Orthopedics from an affiliated hospital.

Methods: Seventy-two single-level OVCF patients who underwent 3D CT between 2018 and 2020 were evaluated prospectively. All patients underwent PKP and were assigned to 2 groups: unilateral PKP and bilateral PKP. Imaging outcomes were assessed by determining the cement volume, leakage, dispersion index, vertebral height (VH) and the cement volume of the noninjected and injected sides. Clinical outcomes were evaluated using the Visual Analog Scale (VAS). The correlations between the bone cement volume or dispersion index and the VAS, VH improvement rate (VHIR), or bone cement leakage were also evaluated.

Results: The mean follow-up time was 17.1 months. The postoperative VH and VAS in both groups were significantly improved ($P < 0.05$). However, there were no statistically significant differences in the cement volume, leakage or dispersion index, VH, or VAS between the 2 groups. No statistically significant differences in the cement volume or VH were found between the noninjected and injected sides within the unilateral group. The operative time was significantly shorter in the patients who underwent unilateral PKP. Unilateral PKP in which the bone cement did not cross the midline had a higher VAS compared with bilateral PKP. Both the bone cement volume and dispersion index displayed a positive correlation with the VHIR, but no correlation with the VAS or bone cement leakage.

Limitations: This study was limited by the nonrandomized design, small sample size, and short follow-up period.

Conclusions: While unilateral PKP was as effective as bilateral PKP, it had a shorter operation time. However, the bilateral PKP approach might be followed when bone cement is distributed in only one side following the unilateral PKP procedure.

Key words: Osteoporotic vertebral compression fracture, percutaneous kyphoplasty, bone cement distribution

Pain Physician 2022; 25:E805-813

Osteoporotic vertebral compression fractures (OVCF) usually occur in elderly osteoporosis patients. Severe dynamic pain caused by OVCF seriously affects the patients' quality of life, even leading to long-term bed rest among these patients, which can increase the risk for pneumonia, thrombosis, and bedsores. Some patients were even admitted with Kümmell disease, which further led to vertebral collapse, thereby increasing the difficulty of treatment (1,2). Percutaneous kyphoplasty (PKP) is a safe and effective minimally invasive surgical treatment for OVCF (3,4). In a multicenter, randomized clinical trial from The Lancet (5), PKP alleviated patients' pain and significantly improve their quality of life compared with nonsurgical treatment.

Bilateral PKP has been considered the standard approach for OVCF, providing a safe and effective treatment. Some studies (6,7) additionally showed that unilateral PKP provided numerous benefits, including shorter operative times, less radiation exposure, and lower surgery-related costs. However, the advantages of the 2 surgical procedures in different perspectives remain greatly debated, including the vertebral height (VH) improvement rate (VHIR), cement leakage, and Visual Analog Scale (VAS) improvement rate (VASIR). Moreover, the effects of the bone cement volume and dispersion index on clinical efficacy are greatly debated. In recent years, increasing research has investigated the differences between the unilateral and bilateral procedures (28); however, nearly all these studies have been conducted with x-rays to analyze the radiographic and clinical outcomes. To our knowledge, 3-dimensional (3D) computed tomography (CT) imaging could perform a more precise assessment of bone cement distribution and an accurate measurement of the bone cement volume, cement leakage, and VH. In this paper, we aimed to compare the CT imaging parameters and clinical efficacies of unilateral and bilateral PKP.

METHODS

Patient Population

In this prospective, nonrandomized controlled study, patients with single-level OVCF who underwent PKP and 3D CT were enrolled between January 2018 and January 2020. Inclusion criteria were as follows: (1) 3D CT was performed before and after surgery; (2) single-level OVCF was diagnosed by magnetic resonance imaging and bone density (T score < -2.5); (3) severe

back pain associated with OVCF was unresponsive to analgesic medication for a minimum of 2 weeks; and (4) the occurrence of $\geq 15\%$ height losses of the fractured vertebra (6). Exclusion criteria were: (1) compression of the spinal cord and nerve roots; (2) lack of cooperation (such as Alzheimer's disease and other forms of dementia); and (3) pathological fractures (such as vertebral metastatic cancer or osteomyelitis). All 72 patients obtained written informed consent and underwent PKP, 32 patients were included in the unilateral PKP group and 40 patients in the bilateral PKP group. The study was approved by the human research ethics committees at Honghui Hospital (201904001).

Surgical Procedure

All surgeries were performed by 2 senior surgeons (Hao DJ and Xu ZW) together specialized in PKP. All patients were maintained in the prone position under local anesthesia. In the bilateral group, the puncture points were located in the lateral margin of the pedicle at the 3 o'clock and 9 o'clock positions on intraoperative fluoroscopy. In the unilateral group, the puncture point was located at approximately 5 mm from the lateral margin of the pedicle where it intersected with the midportion of the transverse process. The needle puncture through the pedicle and into the anterior one-third of the vertebral body was performed under fluoroscopy. Subsequently, a balloon was inserted into the vertebral body and expanded. Finally, bone cement was injected into the vertebral body under lateral fluoroscopy guidance. All patients were discharged at 1 or 2 days postoperation and were advised to avoid extreme physical strain for 2 months.

Outcome Evaluation

The 256-line multi-slice CT-Scanner (Siemens SOMATOM Definition Flash, Siemens Healthcare, Forchheim, Germany) preoperatively and at 6 months postoperatively from all patients, the CT scans providing 1-mm thick axial helical with coronal and sagittal reconstructions. The 3D CT images were imported into the processing workstation (Philips CT workstation, EBW 4.5, The Netherlands) and the following parameters were determined: volume of bone cement within the vertebral body; the bone cement dispersion index, with the measurement as illustrated in Fig. 1; and the VH as the mean of 3 different points (Fig. 2). The vertebral body was divided into 2 halves from the midline, and the bone cement volume of each side was determined. All the measurements were performed 3 times

independently at the Honghui Hospital by 2 surgeons (Dong L and Zhang YT).

The VAS (0-10) evaluated preoperatively and at 6 months after surgery was used to assess the clinical efficacy. The above clinical parameters were compared between unilateral PKP and bilateral PKP (Figs. 3 and 4). Unilateral PKP in which the bone cement did not cross the midline was also compared to bilateral PKP (Fig. 5). The correlations between the volume of bone cement or bone cement dispersion index and the VASIR, VHIR, or bone cement leakage volume were also evaluated.

$$\text{VASIR} = \frac{(\text{postoperative VAS} - \text{preoperative VAS})}{(\text{0-preoperative VAS})} \times 100\%$$

is defined as the VAS score at 6 months after surgery)

$$\text{VHIR} = \frac{(\text{postoperative VH} - \text{preoperative VH})}{(\text{normal VH-preoperative VH})} \times 100\%$$

Normal VH (cm) =

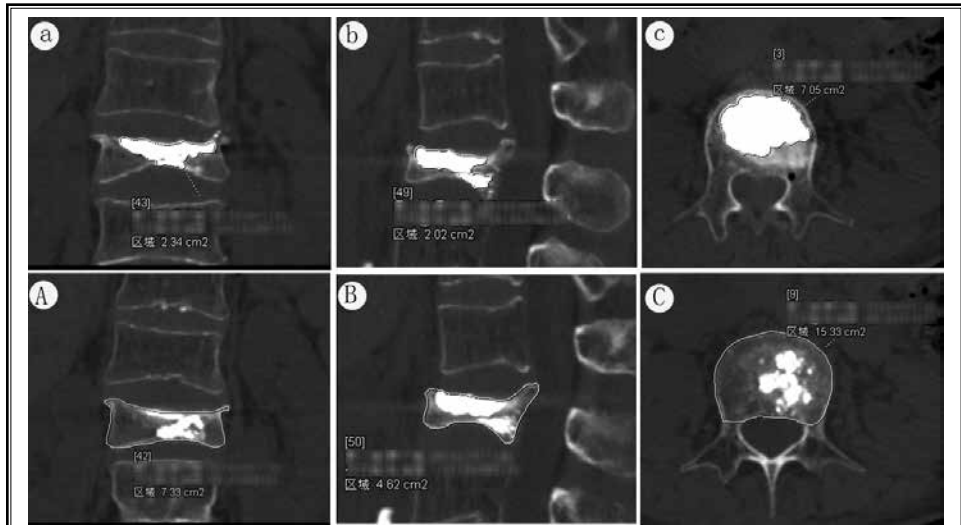


Fig. 1. Measurement of bone cement dispersion on 3D CT scans. We measured the largest area of bone cement (a, b, c) and the largest area of vertebral body (A, B, C) in the axial, coronal, and sagittal planes, respectively. The bone cement dispersion was equal to the sum of the largest area of bone cement in the axial, coronal, and sagittal planes divided by the sum of the largest area of the vertebral body in the axial, coronal, and sagittal planes. 3D, 3-dimensional; CT, computed tomography.

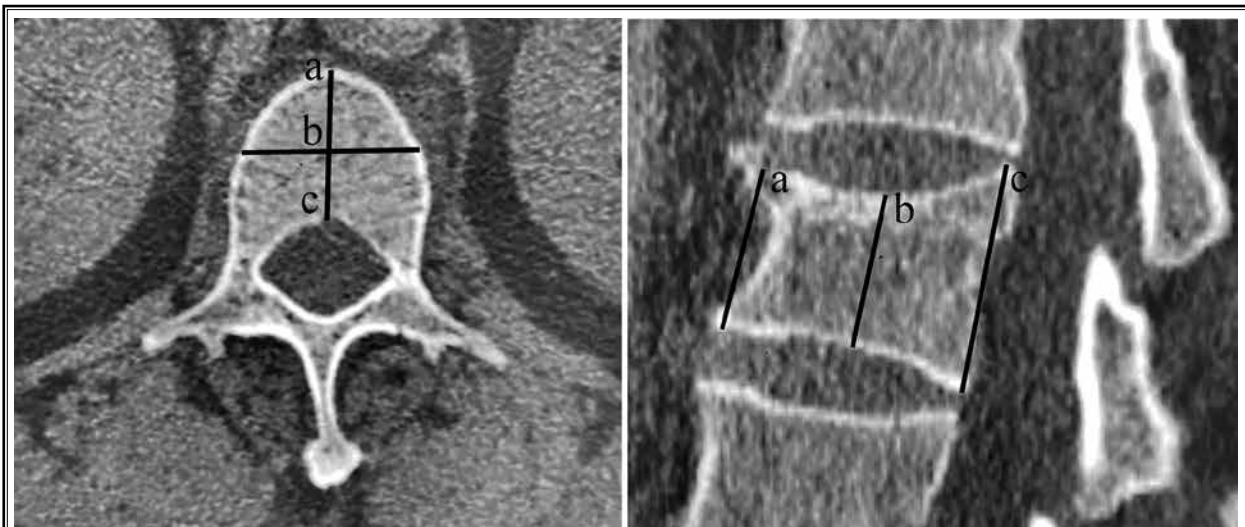


Fig. 2. Measurement of VH on 3D CT scans. We drew 2 bisectors on the axial vertebral body view, and the anterior (a), middle (b), and posterior (c) points were constructed. The VH was equal to (a + b + c)/3. VH, vertebral height; 3D, 3-dimensional; CT, computed tomography.

$$\frac{(\text{VH of upper adjacent segment} + \text{VH of lower adjacent segment})}{2}$$

Statistical Analysis

SPSS statistical software, version 19.0 (IBM Corporation, Armonk, NY) was used. The paired t test was applied to compare pre- and postoperative data. Two

different groups were compared by the 2-sample t test. $P < 0.05$ was considered statistically significantly different. Pearson's correlation analysis was used to analyze the correlation between bone cement and clinical outcomes. The receiver operating characteristic (ROC) curve and the area under the curve were calculated to determine whether the bone cement volume or dispersion index was better in the VASIR (Fig. 6).

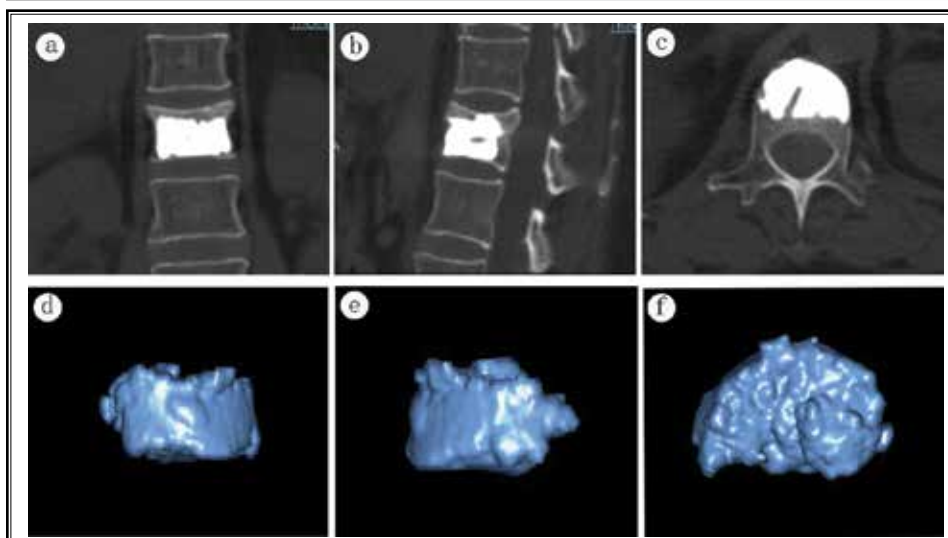


Fig. 3. Unilateral group: a-c: coronal, sagittal, and axial reconstructed images of the spine segment, including cement and bone; d-e: coronal, sagittal, and axial reconstructed model of intravertebral bone cement.

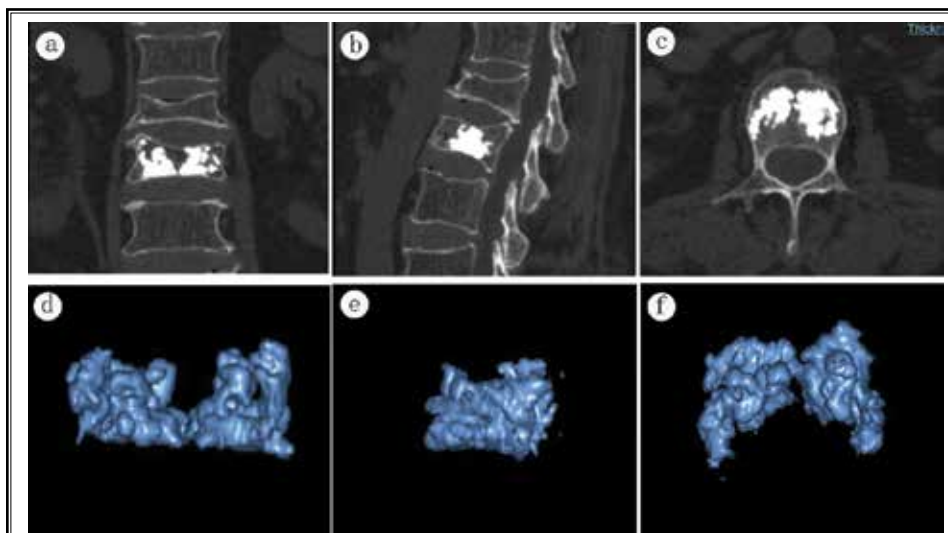


Fig. 4. Bilateral group: a-c: coronal, sagittal, and axial reconstructed images of the spine segment, including cement and bone; d-e: coronal, sagittal, and axial reconstructed model of intravertebral bone cement.

RESULTS

Demographic Characteristics

All 72 patients underwent efficient PKP, with no intraoperative spinal cord injury or mortality. The mean follow-up was 17.1 months (range, 14–27 months). Five patients were lost to the final follow-up because of the loss of patient contact (phone number no longer valid, 3 cases) and mortality from other disease (2 cases). Clinical and radiographic follow-up data could not be obtained for these 5 patients. There were no significant differences in the patient demographic data between the 2 groups. Demographic data of the patients are presented in Table 1.

Imaging Results

The following radiological outcomes are listed in Tables 1 and 2. All patients in the 2 groups displayed an increased VH after surgery ($P < 0.01$); whereas, no significant difference was found in VH

between the unilateral and bilateral groups ($P > 0.05$). Additionally, there were no statistically significant differences between the unilateral and bilateral groups in the bone cement volume (4.3 ± 1.1 mL vs 4.1 ± 1.3 mL, $P > 0.05$), dispersion index ($47.1 \pm 15.4\%$ vs $47.3 \pm 13.7\%$, $P > 0.05$), or cement leakage rate. Within the unilateral PKP group comparison, no statistically significant difference in the bone cement volume was found between the noninjected and injected sides of the vertebral body.

The bone cement dispersion index ($R^2 = 0.532$, $P < 0.01$) displayed a strong positive correlation and the bone cement volume ($R^2 = 0.303$, $P < 0.05$) a moderate positive correlation with the VHIR. However, the bone cement volume and dispersion index showed no significant correlation with the bone cement leakage volume (Fig. 7).

Clinical Outcomes

The mean operative time in unilateral and bilateral PKP was 34.3 ± 5.7 and 48.1 ± 6.6 minutes, respectively, being significantly shorter in the unilateral group ($P < 0.01$). The following clinical outcomes are listed in Table 3. The mean preoperative VAS for the patients who underwent unilateral PKP was 7.3 ± 1.0 , which decreased to 1.8 ± 1.1 at 6 months after surgery ($P < 0.01$). For the patients who underwent bilateral PKP, the mean preoperative VAS of 7.1 ± 1.0 decreased to 1.7 ± 1.3 at 6 months after surgery ($P < 0.01$). However, no significant difference was found between the 2 groups regarding the VAS ($P > 0.05$). In 6 patients who underwent unilateral PKP, the bone cement did not cross the midline, being limited to the injected side of the vertebral body. These 6 patients had a higher VAS compared with the bilateral PKP patients ($P < 0.05$).

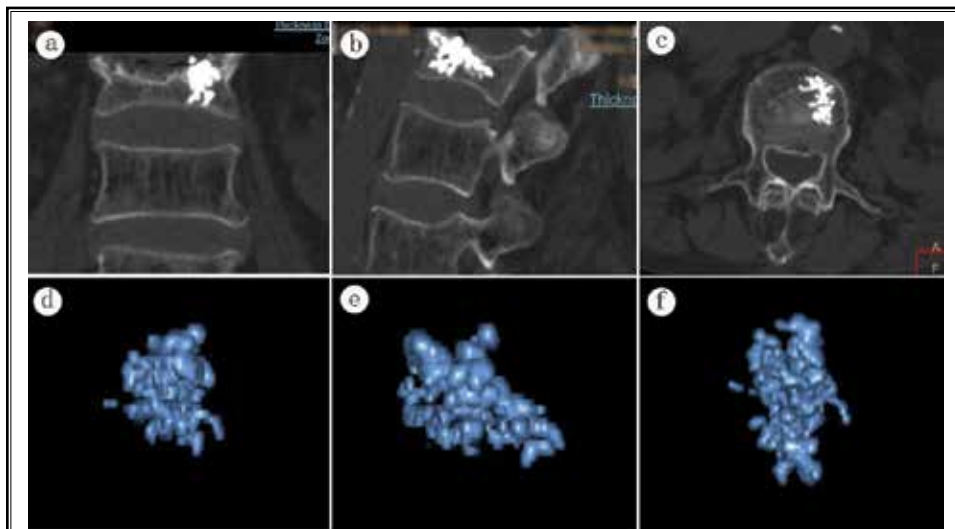


Fig. 5. Unilateral PKP showing that bone cement did not cross the midline. a-c: coronal, sagittal, and axial reconstructed images of the spine segment, including cement and bone; d-e: coronal, sagittal, and axial reconstructed model of intravertebral bone cement. PKP, percutaneous kyphoplasty.

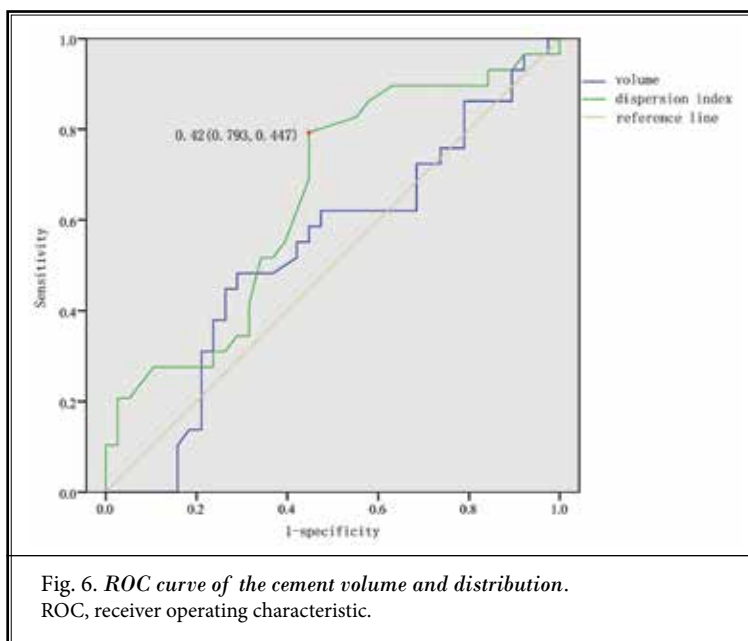


Fig. 6. ROC curve of the cement volume and distribution. ROC, receiver operating characteristic.

The bone cement volume and dispersion index displayed no significant correlation with the VASIR (Fig. 7). Even when controlling for the bone cement volume, the cement dispersion index displayed no significant correlation with the VASIR, and the bone cement volume also showed no significant correlation with the VASIR when controlling for the cement dispersion index. Patients were assigned to 2 groups based

Table 1. Characteristic of the study population, radiographic data, and operative time ($X \pm S$).

Parameters	Unilateral Group	Bilateral Group	P value
Number of cases	29	38	
Average age, y	73.6 \pm 5.7	74.1 \pm 4.9	0.417
Gender, men:women	10:19	12:26	0.802
T score	-3.1 \pm 0.7	-3.2 \pm 0.6	0.160
BC volume (cm ³)	4.3 \pm 1.1	4.1 \pm 1.3	0.231
BC dispersion index (%)	47.1 \pm 15.4	47.3 \pm 13.7	0.957
Operative time (min)	34.3 \pm 5.7	48.1 \pm 6.6	0.000*

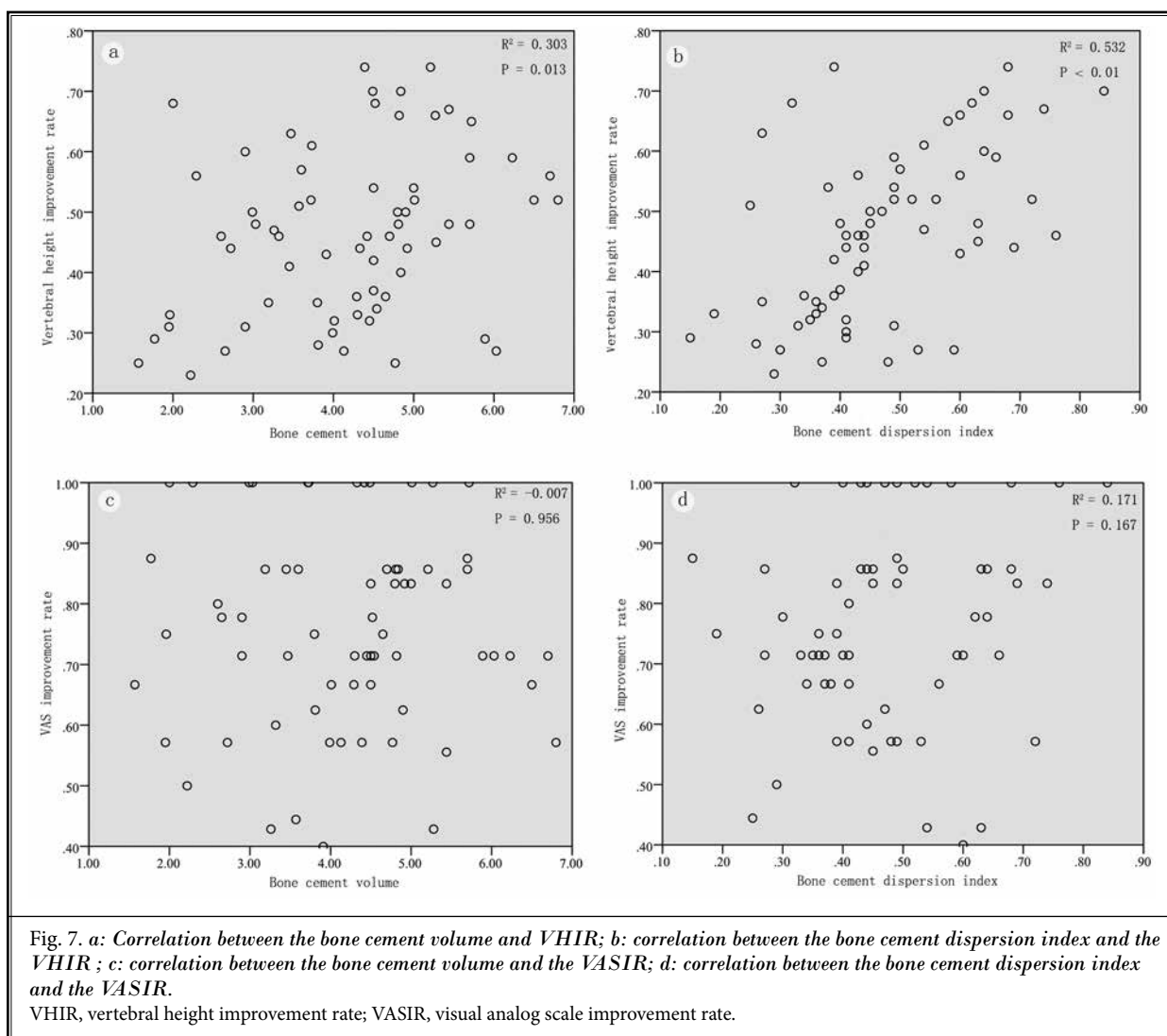
* Statistical difference between unilateral group and bilateral group.

on the VASIR; group A was $\geq 80\%$ (29 patients); group B was $< 80\%$ (38 patients); and a ROC curve was constructed. The area under the ROC curve of the cement dispersion index of 0.648 (95% confidence interval (CI): 0.514-0.782, $P < 0.05$) was greater than that for the cement volume of 0.532 (95% CI: 0.390-0.674, $P = 0.653$). The "optimal" cutoff value was defined by the highest

Table 2. The change of VH.

Group	n	Pre-op	6-month	VHIR (%)
Unilateral Group	29	16.2 \pm 2.4	19.2 \pm 2.7*	44.9 \pm 14.2
Bilateral Group	38	16.2 \pm 1.9	19.7 \pm 2.2*	47.7 \pm 13.6

* Statistical difference between preoperative and 6-month follow-up. Abbreviations: VH, vertebral height; Pre-op, preoperative; VHIR, vertebral height improvement rate.



Youden index value, and the cement dispersion index at 0.42 had a sensitivity of 0.793 and a specificity of 0.553 (Fig. 6).

DISCUSSION

As an effective and common treatment, PKP provides rapid and long-lasting pain relief for OVCF (8). In our study, both unilateral and bilateral procedures markedly relieved pain, with a mean VASIR of 76%. However, several studies showed that these 2 surgical procedures led to different clinical and radiographic outcomes. Therefore, our study aimed to accurately assess the differences of the 2 procedures and evaluate the correlation among the cement volume, cement distribution, and clinical outcomes by 3D CT scans.

Some studies showed bilateral PKP to be more effective than unilateral PKP in restoring VH (9,10); whereas, others demonstrated the reverse (11). Nevertheless, the VH restoration of the 2 approaches in some published meta-analyses remained inconclusive. A meta-analysis including 12 randomized controlled trials by Feng et al (12) demonstrated that bilateral PKP produced better VH restoration; whereas, a meta-analysis by Tan et al (13) summarizing the findings from all systematic reviews and meta-analyses showed no such significant difference between the 2 approaches. In our study, the VHIR determined by 3D CT, as one of the more reliable indicators to predict VH restoration, also showed no significant difference between the 2 groups, as in other studies (14,15).

The bone cement distribution is difficult to define exactly and harder still to measure. In Lin et al's study (16), the bone cement distribution was defined such that if cement could pass the midline of the vertebra on lateral radiographs, and they showed that the bone cement distribution had a positive correlation with the VH restoration. He et al (17) determined the bone cement distribution by calculating the percentage of the area occupied by cement on anteroposterior and lateral radiographs, coming to the same conclusion. In our study, the bone cement distribution was represented by the bone cement dispersion index, which was defined as the percentage of the area occupied by cement in the vertebral body on 3D CT. We concluded that bone cement dispersion index ($R^2 = 0.532$, $P < 0.01$) displayed a strong positive correlation with the VHIR. Because our results showed that the 2 approaches had no significant difference in the bone cement dispersion index, this may explain why there was also no significant difference in the VH restoration between the 2 groups.

Table 3. *The change of VAS.*

Group	n	Pre-op	6-month	VASIR (%)
Unilateral Group	29	7.3 ± 1.0	1.8 ± 1.1*	75.7 ± 14.8
Bilateral Group	38	7.1 ± 1.0	1.7 ± 1.3*	75.9 ± 17.7
Unilateral Group	6	7.8 ± 1.0	3.0 ± 0.9*#	60.9 ± 13.2

* Statistical difference between preoperative and 6-month follow-up.

Significant difference between bilateral group and unilateral group (N).

Abbreviations: VAS, visual analog scale; Pre-op; preoperative; VASIR, visual analog scale improvement rate; Unilateral Group (N), unilateral group that bone cement didn't cross the midline.

Similarly, cement leakage remains under debate with respect to the 2 approaches. In Tan et al's meta-analysis (13), unilateral PKP produced a lower risk for cement leakage than bilateral PKP. Yan et al (11) reported a similar result in a prospective comparative study, suggesting that this may be associated with the more lateral puncture point, such that bone cement was mainly distributed in the anterior and middle of the vertebra body in the unilateral PKP group. In contrast, in a meta-analysis by Feng et al (12), there was no difference in cement leakage between the 2 procedures. Because cement leakage in most of the above studies was confirmed by x-rays, it was possible that minute leakage could not be observed. Our study introduced 3D CT to assess cement leakage from different planes, which increased the sensitivity and accuracy, also concluding that there was no significant difference between the 2 methods. Several studies (18-20) confirmed that bone cement leakage displayed a closer relationship with the basal vertebral vein, fracture severity, and cement viscosity if the puncture position was correct.

There is very limited investigation of the relationship between the cement volume or distribution and cement leakage. Some studies (21,22) indirectly confirmed that an increase in the cement volume may increase the risk for cement leakage. However, in a biomechanical cadaveric study (23), no relationship was found between the maximum pressures during injection in vertebrae and the cement leakage rate. He et al (17) found that the cement distribution and volume were not risk factors for cement leakage, which we similarly demonstrated.

However, the bone cement volume was not the more the better. An excessive volume of bone cement may result in its asymmetric distribution and excessive vertebral stiffness (24). He et al (17) found that an extensive cement volume increased the incidence of adjacent vertebral fractures, and that there was no correlation between the cement volume and pain relief,

a similar conclusion to that in our study. Belkoff et al (25) suggested that an approximate 2 mL injection of bone cement can restore the strength of the diseased vertebral body, while regaining the stiffness requires a minimum of 4 mL. According to the ROC curve, He et al (17) found that the cement volume was a predictor for pain relief, with a volume of 3.80 mL displaying the highest Youden index. However, the cement volume in that study was considered as the injection volume of the bone cement, which was inconsistent with the actual volume in the vertebral body. In our study, pain relief was innovatively represented by the VASIR. Our study showed with 3D CT scans that the cement volume of the vertebral body was not a predictor for the VASIR through the ROC curve.

In ROC curve analyses, He et al (17) showed that the cement distribution was a better predictor than the cement volume for pain relief, the cement distribution having the highest Youden index when it was 0.49, with an extensive cement distribution contributing to pain relief. Chen et al (26) showed that the spongy cement was superior to the blocky cement in terms of pain relief and functional recovery. However, Yuan et al (21) reported that pain relief with the fracture area injected accurately with a small dose of bone cement was comparable with that of a conventional dose of bone cement. Zhang et al (27) showed that a different distribution of the bone cement produced no statistically significant difference in the VAS between the 2 different approaches. In our study, the cement dispersion index also had no significant correlation with the VASIR; whereas, it was a predictive factor for pain relief. The highest Youden index of the cement distribution was at 0.42.

The meta-analysis by Feng et al (12) revealed that unilateral PKP had a better effect on pain relief; whereas, other studies reported no significant difference between the 2 approaches. In the meta-analysis of Chen et al (28), unilateral PKP produced a higher degree of pain relief at short-term follow-up after surgery, but no significant differences in clinical outcomes with

long-term follow-up. A meta-analysis by Cheng et al (6) showed no significant difference in the VAS scores in the short-term or long-term follow-up, as also reported by Yan et al (11). We also concluded that there was no significant difference regarding the VAS. In our study, unilateral PKP in which the bone cement did not cross the midline had a higher VAS score compared with bilateral PKP. As in the study by Chen et al (15), if the bone cement distributed in only one side, the stiffness of the other side was less than the augmented side. Many surgeons perform the bilateral PKP approach as a potential remedy when the bone cement distributes in only one side with the unilateral PKP procedure, but few articles have previously mentioned this condition. Consequently, it cannot be excluded that the bilateral PKP procedure can be mistaken for unilateral PKP during data analyses, even if surgeons have indicated using the bilateral procedure, which may result in a statistical bias.

There were some limitations in this study. First, the nonrandomized design and small sample size might lead to patient selection bias. Therefore, prospective, randomized controlled trials with a larger patient population are required. Second, potential bias may be introduced by the loss to follow-up, which might reduce the statistical power. Third, the follow-up period was relatively short, thus a longer follow-up might allow the assessment of adjacent fractures and further VH changes.

CONCLUSIONS

Our study revealed that the unilateral PKP procedure was as effective as the bilateral PKP procedure for pain alleviation, VH restoration, and the reduction of cement leakage. It also demonstrated that the unilateral PKP procedure required a shorter operative time. However, for unilateral PKP where the bone cement does not cross the midline, this procedure might be extended to a bilateral PKP. Given the small sample size and the nonrandomized design, the results of study should be accepted with caution.

REFERENCES

1. Li H, Liang CZ, Chen QX. Kummell's disease, an uncommon and complicated spinal disorder: A review. *J Int Med Res* 2012; 40:406-414.
2. Muratore M, Ferrera A, Masse A, et al. Osteoporotic vertebral fractures: Predictive factors for conservative treatment failure. A systematic review. *Eur Spine J* 2018; 27:2565-2576.
3. Wu AM, Lin ZK, Ni WF, et al. The existence of intravertebral cleft impact on outcomes of nonacute osteoporotic vertebral compression fractures patients treated by percutaneous kyphoplasty: A comparative study. *J Spinal Disord Tech* 2014; 27:E88-E93.
4. Nakamae T, Yamada K, Tsuchida Y, et al. Risk factors for cement loosening after vertebroplasty for osteoporotic vertebral fracture with intravertebral cleft: A retrospective analysis. *Asian Spine J*

- 2018; 12:935-942.
5. Wardlaw D, Cummings SR, Van Meirhaeghe J, et al. Efficacy and safety of balloon kyphoplasty compared with non-surgical care for vertebral compression fracture (FREE): A randomised controlled trial. *Lancet* 2009; 373:1016-1024.
 6. Cheng X, Long HQ, Xu JH, et al. Comparison of unilateral versus bilateral percutaneous kyphoplasty for the treatment of patients with osteoporosis vertebral compression fracture (OVCF): A systematic review and meta-analysis. *Eur Spine J* 2016; 25:3439-3449.
 7. Yin P, Ji Q, Wang Y, et al. Percutaneous kyphoplasty for osteoporotic vertebral compression fractures via unilateral versus bilateral approach: A meta-analysis. *J Clin Neurosci* 2019; 59:146-154.
 8. Georgy BA. Clinical experience with high-viscosity cements for percutaneous vertebral body augmentation: Occurrence, degree, and location of cement leakage compared with kyphoplasty. *AJNR Am J Neuroradiol* 2010; 31:504-508.
 9. Chen C, Chen L, Gu Y, et al. Kyphoplasty for chronic painful osteoporotic vertebral compression fractures via unipedicular versus bipedicular approach: A comparative study in early stage. *Injury* 2010; 41:356-359.
 10. Chen C, Wei H, Zhang W, et al. Comparative study of kyphoplasty for chronic painful osteoporotic vertebral compression fractures via unipedicular versus bipedicular approach. *J Spinal Disord Tech* 2011; 24:E62-E65.
 11. Yan L, He B, Guo H, et al. The prospective self-controlled study of unilateral transverse process-pedicle and bilateral puncture techniques in percutaneous kyphoplasty. *Osteoporos Int* 2016; 27:1849-1855.
 12. Feng H, Huang P, Zhang X, et al. Unilateral versus bilateral percutaneous kyphoplasty for osteoporotic vertebral compression fractures: A systematic review and meta-analysis of RCTs. *J Orthop Res* 2015; 33:1713-1723.
 13. Tan G, Li F, Zhou D, et al. Unilateral versus bilateral percutaneous balloon kyphoplasty for osteoporotic vertebral compression fractures: A systematic review of overlapping meta-analyses. *Medicine (Baltimore)* 2018; 97:e11968.
 14. Steinmann J, Tingey CT, Cruz G, et al. Biomechanical comparison of unipedicular versus bipedicular kyphoplasty. *Spine (Phila Pa 1976)* 2005; 30:201-205.
 15. Chen B, Li Y, Xie D, et al. Comparison of unipedicular and bipedicular kyphoplasty on the stiffness and biomechanical balance of compression fractured vertebrae. *Eur Spine J* 2011; 20:1272-1280.
 16. Lin J, Qian L, Jiang C, et al. Bone cement distribution is a potential predictor to the reconstructive effects of unilateral percutaneous kyphoplasty in OVCFs: A retrospective study. *J Orthop Surg Res* 2018; 13:140.
 17. He X, Li H, Meng Y, et al. Percutaneous kyphoplasty evaluated by cement volume and distribution: An analysis of clinical data. *Pain Physician* 2016; 19:495-506.
 18. Nieuwenhuijse MJ, Muijs SP, Van Erkel AR, et al. A clinical comparative study on low versus medium viscosity polymethylmetacrylate bone cement in percutaneous vertebroplasty: Viscosity associated with cement leakage. *Spine (Phila Pa 1976)* 2010; 35:E1037-E1044.
 19. Wang C, Fan S, Liu J, et al. Basivertebral foramen could be connected with intravertebral cleft: A potential risk factor of cement leakage in percutaneous kyphoplasty. *Spine J* 2014; 14:1551-1558.
 20. Nieuwenhuijse MJ, Van Erkel AR, Dijkstra PD. Cement leakage in percutaneous vertebroplasty for osteoporotic vertebral compression fractures: Identification of risk factors. *Spine J* 2011; 11:839-848.
 21. Yuan L, Bai J, Geng C, et al. Comparison of targeted percutaneous vertebroplasty and traditional percutaneous vertebroplasty for the treatment of osteoporotic vertebral compression fractures in the elderly. *J Orthop Surg Res* 2020; 15:359.
 22. Zhang H, Xuan J, Chen TH, et al. Projection of the most anterior line of the spinal canal on lateral radiograph: An anatomic study for percutaneous kyphoplasty and percutaneous vertebroplasty. *J Invest Surg* 2020; 33:134-140.
 23. Reidy D, Ahn H, Mousavi P, et al. A biomechanical analysis of intravertebral pressures during vertebroplasty of cadaveric spines with and without simulated metastases. *Spine (Phila Pa 1976)* 2003; 28:1534-1539.
 24. Liebschner MA, Rosenberg WS, Keaveny TM. Effects of bone cement volume and distribution on vertebral stiffness after vertebroplasty. *Spine (Phila Pa 1976)* 2001; 26:1547-1554.
 25. Belkoff SM, Mathis JM, Erbe EM, et al. Biomechanical evaluation of a new bone cement for use in vertebroplasty. *Spine (Phila Pa 1976)* 2000; 25:1061-1064.
 26. Chen JB, Xiao YP, Chen D, et al. Clinical observation of two bone cement distribution modes of percutaneous vertebroplasty in the treatment of thoracolumbar Kummell's disease. *J Orthop Surg Res* 2020; 15:250.
 27. Zhang W, Liu S, Liu X, et al. Unilateral percutaneous vertebroplasty for osteoporotic lumbar compression fractures: A comparative study between transverse process root-pedicle approach and conventional transpedicular approach. *J Orthop Surg Res* 2021; 16:73.
 28. Chen X, Guo W, Li Q, et al. Is unilateral percutaneous kyphoplasty superior to bilateral percutaneous kyphoplasty for osteoporotic vertebral compression fractures? Evidence from a systematic review of discordant meta-analyses. *Pain Physician* 2018; 21:327-336.

