

## Observational Study

# e Postoperative Upper-limb Palsy After Posterior Percutaneous Endoscopic Cervical Foraminotomy and Discectomy

Weiheng Wang, MD<sup>1</sup>, Liang Tang, MD<sup>2</sup>, Gonghao Zhang, MD<sup>2</sup>, Bing Xiao, MD<sup>1</sup>, Yanhai Xi, MD<sup>1</sup>, Xin Gu, MD<sup>2</sup>, and Xiaojian Ye, MD<sup>2</sup>

From: <sup>1</sup>Department of Orthopaedics, Second Affiliated Hospital of Naval Medical University, NO.415 Fengyang Road, Shanghai, China; <sup>2</sup>Department of Orthopaedics, Tongren Hospital, Shanghai Jiaotong University, No. 1111, Xianxia Road, Shanghai, China

Address Correspondence: Xin Gu, MD  
Department of Orthopaedics, Tongren Hospital, Shanghai Jiaotong University, No. 1111, Xianxia Road, Shanghai, China  
E-mail: guxin2004ty@qq.com;

Disclaimer: Weiheng Wang and Liang Tang contributed equally to this work. This work was sponsored by the National Key R and D Program of China (2020YFC2008404), the National Natural Science Foundation of China (No. 82102605), and Shanghai Sailing Program (19YF1448400).

Conflict of interest: Each author certifies that he or she, or a member of his or her immediate family, has no commercial association (i.e., consultancies, stock ownership, equity interest, patent/licensing arrangements, etc.) that might pose a conflict of interest in connection with the submitted manuscript.

Manuscript received: 06-10-2022  
Revised manuscript received: 08-16-2022  
Accepted for publication: 09-19-2022

Free full manuscript:  
www.painphysicianjournal.com

**Background:** Postoperative upper-limb palsy (ULP) is a serious complication after cervical spine surgery. ULP after posterior percutaneous endoscopic cervical foraminotomy and discectomy (PPCED) has not yet been reported.

**Objective:** To introduce cases of postoperative ULP after PPCED and associated risk factors.

**Study Design:** A single-center, retrospective, observational study.

**Setting:** Shanghai Changzheng Hospital, Naval Medical University, Shanghai, China.

**Methods:** From January 2016 through January 2022, PPCED involving a total of 663 segments was performed in 610 patients with radiculopathy who were diagnosed with cervical radiculopathy or mixed cervical spondylosis caused by foraminal stenosis or posterolateral disc herniation.

**Results:** PPCED was successfully completed in 610 patients, 6 of whom (0.98%) developed ULP. Two patients were diagnosed with double-segment cervical nerve root canal stenosis (C4/5/6, C5/6/7) and 2 with migrated cervical disc soft herniation (a magnetic resonance image of one showed a migrated disc herniation downward from C4/5 in the sagittal plane; another showed this upward from C5/6); one patient was diagnosed with C5/6 intervertebral foraminal stenosis, and one had simple C4/5 lateral disc herniation. Postoperative ULP rates for C4/5 (2/30, 6.67%) and C5/6 (2/177, 1.13%) were much higher than those for the other levels. Anatomically, the width of the intervertebral foramen on computed tomography was  $2.3 \pm 1.12$  mm in ULP cases, which was significantly lower than that in non-ULP cases ( $3.4 \pm 1.83$ ,  $P < 0.05$ ). This suggests that preoperative foramen width correlates highly negatively with postoperative ULP incidence.

**Limitations:** This was a single-center, retrospective, nonrandomized study with a low level of evidence.

**Conclusions:** PPCED is a good treatment for cervical radiculopathy. The rate of postoperative ULP after PPCED is much lower than that after posterior cervical foraminotomy. Perturbation to the C5 (or C6) nerve root, thermal injury due to burr use or the radiofrequency applied, and marked foraminal stenosis are possible relevant factors associated with postoperative ULP.

**Key words:** Postoperative upper limb palsy, complications, posterior percutaneous endoscopic cervical foraminotomy and discectomy, preoperative foramen width

**Pain Physician 2022; 25:E1291-E1298**

**C**ervical radiculopathy is a common spinal disorder presenting with radiating pain and numbness from the neck to the upper limb and is usually caused by compression of the nerve root by a herniated disc or stenosis of the intervertebral foramen (1). Surgical treatment should be considered when conservative management fails, even though it is effective for most cases of cervical radiculopathy. Posterior cervical foraminotomy is a classic surgical method for treating cervical nerve root compression, first described by Spurling in 1944 (2). In 2001, the application of microendoscopy in posterior cervical foraminotomy was introduced after the development of minimally invasive techniques (3). Moreover, the development of full endoscopic techniques led to posterior percutaneous cervical endoscopic foraminotomy and discectomy (PPCED), as reported in 2007 by Ruetten (4). In general, PPCED is increasingly being used widely because of its minimal invasiveness, excellent postoperative efficacy, short hospitalization time and fast recovery (5). Although complications of PPCED are rare (6), upper-limb palsy (ULP) is a serious possible complication.

ULP, also known as C5 palsy, is a common complication after anterior and posterior cervical spine surgery. Despite the relatively low incidence and good prognosis, patients with ULP are generally dissatisfied with their surgery (7). In posterior cervical open surgery, prophylactic foraminal enlargement can be applied to prevent postoperative ULP (8). However, many recent studies have found that postoperative ULP can still occur after foraminoplasty (9), and in some cases, foraminoplasty is an independent risk factor for ULP after cervical spine surgery (10,11). Postoperative ULP followed by microendoscopic foraminal decompression at the C5/6/7 levels has been reported (12), but no study has reported postoperative ULP after PPCED. Therefore, we retrospectively analyzed the incidence of ULP after PPCED within 5 years at our center and possible related risk factors. To the best of our knowledge, this is the first report about ULP after PPCED.

## METHODS

### Patients

From January 2016 through January 2022, PPCED, with 663 segments, was performed on 610 patients diagnosed with cervical radiculopathy or mixed cervical spondylosis caused by foraminal stenosis or posterolateral disc herniation. The exclusion criteria included 1)

a history of cervical spine surgery; 2) decreased muscle strength, deltoid, biceps or other upper-limb muscle strength before PPCED; 3) postoperative follow-up less than half a year; and 4) dural tear or other significant damage to nerves occurring during surgery.

All 610 patients were enrolled, including 270 men and 340 women, with an average age of 62.6 years (Table 1). Cervical disc herniation (soft, lateral herniation) was diagnosed in 401 patients, and 209 were diagnosed with cervical foraminal stenosis (no obvious soft herniation). The preoperative diagnosis was based on clinical symptoms combined with imaging. Cervical nerve root block was conducted when necessary. All operations were performed by the same chief surgeon. A total of 557 patients underwent single-segment PPCED, and 53 underwent double-segment (C4/5/6, C5/6/7) PPCED.

### Surgical Procedure

After administration of general anesthesia, the patient was placed prone on a special plaster bed. The shoulders were pulled and fixed with tape to maintain the natural flexion of the cervical spine. The patient was placed in a 30° reverse Trendelenburg position to elevate the surgical site above the heart to reduce venous bleeding. TESSYSTEM Endoscopic System (Joimax GmbH), a surgical drill (Shrill, Joimax GmbH) and a radiofrequency coagulator (DTF-40, Trigger-Flex® Bipolar System, Elliquence LLC) were used during the PPCED procedure.

Under fluoroscopic guidance, the appropriate level was localized on lateral imaging, and a longitudinal 0.8 cm incision was made approximately 1.5 cm lateral to the midline on the side of the pathology. The paraspinous muscles were bluntly divided with a blunt dilator (6.5 mm), which was advanced gently toward the lamino-facet junction of the lateral mass (point V) (Fig. 1a); the working sheath (7.5 mm) was placed via the dilator.

Fluoroscopy was used to verify the placement and trajectory of the working sheath. The residual soft tissue was ablated using bipolar radiofrequency, and the “V-point” was clearly exposed under endoscopy. A high-speed burr was utilized to resect the medial third of the inferior articular process of the cephalad vertebra until the superior articular process of the caudad vertebra was visualized. The medial third of the exposed superior articular process was resected with the burr and Kerrison rongeur (1 mm) in the same way.

After partial resection of the ligamentum flavum, the epidural venous plexus was coagulated to maintain a clear visual field and to accurately identify nerve

roots. The nerve root was exposed from its origin at the thecal sac laterally across the cephalad aspect of the pedicle. Decompression was performed until the proximal and distal pedicles were confirmed longitudinally, and a probe was then easily inserted through the foramen to confirm adequate neural decompression.

In cases of ruptured discs, free-moving ruptured discs were removed when exploring the axillary and shoulder of the nerve root. After the nerve root had been decompressed satisfactorily, all instruments were removed, and direct skin closure was performed. Because of the small incision involved with PPCED, a drainage tube was not necessary; a silicone sheet was placed for drainage in some cases, which was removed within 24 hours after the operation. On the second day after surgery, a cervical brace was provided to be worn for 3 weeks. All patients were routinely provided with cervical health education.

### Retrospective Data Collection

The general information of the patients; the visual analog scale (VAS) score of neck, shoulder and upper limb pain; and the neck disability index (NDI) score were recorded before the operation. The narrowest intervertebral foramen width was measured by preoperative computed tomography (CT) at the narrowest point of the corresponding segment (Fig. 1b).

Additionally, surgical outcome data were recorded, including blood loss, operation time, length of hospital stay, back to work/ full activity, and complications. The sensory and motor conditions of the upper limbs were closely observed after PPCED. VAS scores of neck, shoulder and upper limb pain; sensation and muscle strength of the upper limb; and NDI scores were assessed at one day, 2 weeks, 3 months, and 6 months post-PPCED.

### Postoperative ULP Definition and Treatment

Postoperative ULP was defined as deterioration in muscle power of the deltoid (or deltoid and biceps brachii) by 2 grades in the manual muscle test, with or without paresthesia (numbness, hyperesthesia, pain, etc.) in the corresponding nerve root distribution within 2 weeks after PPCED. Patients experiencing ULP after surgery were examined by both magnetic resonance imaging and CT to exclude hematoma and infection. Treatment of postoperative ULP included the use of methylprednisolone, hyperbaric oxygen therapy, and rehabilitation exercises. Regular outpatient follow-up was conducted for all patients.

Table 1. Demographic characteristics of 610 patients with PPCED.

Characteristics	Value
Mean age, years, $\pm$ SD	63.21 $\pm$ 17.6
Men, n (%)	356 (58.36)
Clinical diagnosis, n (%)	
posterolateral disc herniation	324 (53.11)
foraminal stenosis	286 (46.88)
VAS score (preoperative), $\pm$ SD	6.32 $\pm$ 2.56
VAS score (postoperative), $\pm$ SD	2.34 $\pm$ 1.86
NDI score (preoperative), $\pm$ SD	32.64 $\pm$ 16.21
NDI score (postoperative), $\pm$ SD	6.85 $\pm$ 6.13
Levels of PPCED, n (%)	
C4/5	30 (4.92)
C5/6	177 (29.02)
C6/7	310 (50.82)
C7/T1	40 (6.56)
C4/5/6	18 (2.95)
C5/6/7	35 (5.74)
Postoperative ULP, n (%)	6 (0.98)

### Statistical Analysis

Statistical analysis was performed using SPSS 21.0 software (IBM Corp.). The results are reported as the mean  $\pm$  SD. Student's t-test was used to compare averages of continuous variables. The Pearson  $\chi^2$  test and Fisher's exact test were used to compare proportions of categorical variables between groups.  $P < 0.05$  was considered statistically significant.

### RESULTS

A total of 610 patients underwent PPCED surgery. The average age of the patients was 62.21  $\pm$  17.6 years, and 58.36% were men. Diagnoses were classified into 2 categories: posterolateral disc herniation (324 patients, 53.11%) and foraminal stenosis (286 patients, 46.88%). The mean preoperative VAS and NDI scores of the patients were 6.32  $\pm$  2.56 and 32.64  $\pm$  16.21, respectively.

The surgical segment of PPCED was C4-T1. Single-segment surgery was performed in 557 cases (30 cases of C4/5, 177 cases of C5/6, 310 cases of C6/7, 40 cases of C7/T1) and 2-segment surgery in 53 cases (18 cases of C4/5/6 and 35 cases of C5/6/7).

The mean operative time was 96.87  $\pm$  30.70 minutes. The mean blood loss was 28.39  $\pm$  20.83 mL. The average length of hospital stay was 2.74  $\pm$  1.39 days. The average back to work/ full activity was 2.16  $\pm$  1.39 weeks. The overall complication rate was 3.11% (19/610). Five patients (0.82%) still had pain after the

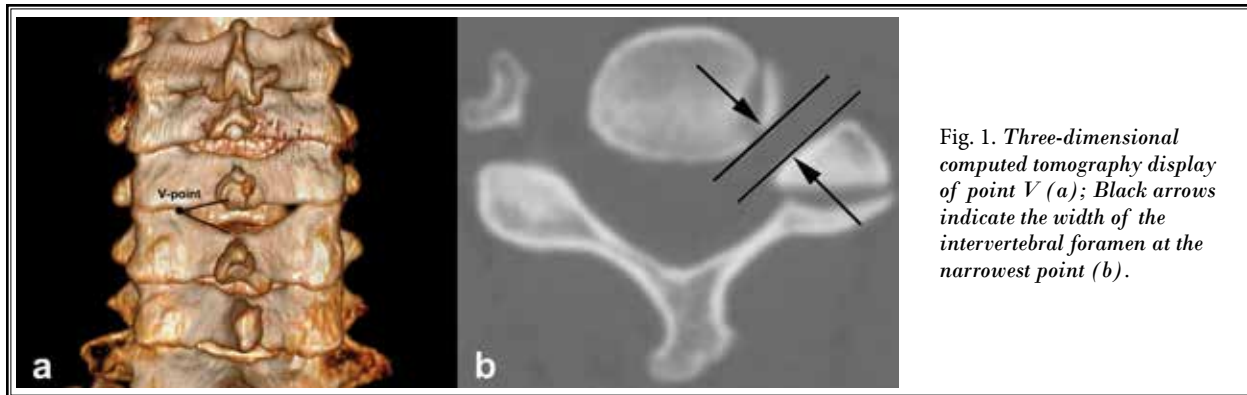


Fig. 1. Three-dimensional computed tomography display of point V (a); Black arrows indicate the width of the intervertebral foramen at the narrowest point (b).

operation: 3 underwent anterior cervical discectomy and fusion surgery and 2 conservative treatments.

Two patients (0.33%) developed superficial wound infections after the operation and recovered after antibiotic treatment. Six patients (0.98%) had a dural tear during the operation. The dural tear was not repaired during the operation, and the wound was tightly sutured. There was no cerebrospinal fluid leakage and no other discomfort symptoms after the operation. Six patients (0.98%) had postoperative ULP. However, postoperative VAS ( $2.34 \pm 1.86$ ) and NDI ( $6.85 \pm 6.13$ ) scores were significantly improved compared to those before surgery ( $P < 0.05$ ) (Table 1).

PPCED was performed on a total of 663 segments in 610 patients. Among them, 6 patients had postoperative ULP (6/610, 0.98%). No patients experienced a significant decrease in postoperative wrist and hand muscle strength to below grade 3 in the manual muscle test. Six patients recovered their motor strength more or less within 3 months. In 2 cases, the deltoid muscle strength that had declined significantly to grade 0-1 after PPCED recovered to grade 4 at 3 months after the operation and returned to grade 5 after 6 months of follow-up. In the remaining patients, muscle strength recovered to grade 5 within 3 months after PPCED. During the 3-month follow-up, VAS and NDI scores in 6 patients were significantly improved compared to those preoperatively ( $P < 0.05$ , Table 2).

The mean age of the 6 patients diagnosed with ULP was  $57.33 \pm 13.125$  years. Three were diagnosed with cervical disc herniation preoperatively, and 3 were diagnosed with cervical foraminal stenosis preoperatively. Among them, 2 cases involved segment C4/5, 2 cases involved segment C5/6, one case involved segment C4/5/6, and one case involved segment C5/6/7. Comparisons of the patients in the ULP and non-ULP groups are shown in Table 2, with no significant dif-

ference between them in terms of age, gender, preoperative diagnosis, preoperative VAS/NDI score, or mean operating time ( $P > 0.05$ , Table 2).

Among the 610 patients, the rate of single-segment PPCED was 0.72% (4/557), and that of two-segment PPCED was 3.77% (2/53). In terms of surgical segments, there was a statistically significant difference between the ULP and non-ULP groups ( $P = 0.0886$ , Table 3). Table 4 shows the number of patients and incidences of ULP according to level of PPCED. In descending order, the incidences of ULP were as follows: C4/5 (2/30, 6.67%); C4/5/6 (1/18, 5.56%); C5/6/7 (1/35, 2.86%); and C5/6 (2/177, 1.13%). Overall, there was a significant trend between the incidence of ULP and the various levels of PPCED ( $P < 0.001$ , Table 4).

The width of the intervertebral foramen on CT was  $2.3 \pm 1.12$  mm in ULP cases, significantly lower than that in non-ULP cases ( $3.4 \pm 1.83$ ); the difference was significant ( $P = 0.0295$ , Table 5). Cervical nerve root canal stenosis was defined as an intervertebral foramen width  $< 3$  mm. The incidence rate of intervertebral foramen width  $< 3$  mm in ULP cases was 66.67% (4/6); in non-ULP cases it was 20.86% (126/604), a significant difference ( $P < 0.05$ , Table 5).

## DISCUSSION

ULP, also known as C5 palsy, is a common complication after anterior and posterior cervical spine surgery. ULP is defined as deterioration in muscle strength in the deltoid by 2 or more grades (determined by manual muscle testing on the deltoid muscle, with or without involvement of the biceps muscle) but no loss of strength in other muscles. According to the literature, the incidence of ULP after cervical spine surgery ranges from 0.58% to 15.8% (13,14). One multicenter retrospective analysis found an incidence of ULP in cervical spine surgery of 0.58% (88/15097), which is lower than

Table 2. Clinical data of patients with and without ULP

Characteristics	ULP (n = 6)	Non-ULP (n = 604)	P value
Mean age, years, ± SD	57.33 ± 13.125	64.36 ± 18.186	0.4788
Men, n (%)	3 (50)	353 (58.44)	0.6971
Clinical diagnosis, n (%)			
posterolateral disc herniation	3 (50)	321 (53.15)	1
foraminal stenosis	3 (50)	283 (46.85)	1
VAS score (preoperative), ± SD	6.167 ± 1.753	6.41 ± 2.73	0.319
NDI score (postoperative), ± SD	35.833 ± 13.656	31.63 ± 15.24	0.9044
Mean operating time, mins, ± SD	75.32 ± 32.16	70.54 ± 28.16	0.5207
Levels of PPCED, n (%)			< 0.0001
C4/5	2 (33.33)	28 (4.64)	
C5/6	2 (33.33)	175 (28.97)	
C6/7	0	310 (51.32)	
C7/T1	0	40 (6.62)	
C4/5/6	1 (16.67)	17 (2.81)	
C5/6/7	1 (16.67)	34 (5.63)	

in previous reports. This reduction may be related to advances in cervical spine surgery techniques and the use of microscopes (15).

It is currently believed that the cause of ULP is mainly related to traction of the C5 nerve root. Due to the drift of the spinal cord after posterior cervical surgery and the change in intervertebral height after anterior cervical surgery, the C5 nerve root or nerve root artery becomes taut after ischemia, which leads to ULP (16). Some scholars believe that ULP is the manifestation of spinal cord nerve ischemia-reperfusion injury (17). Risk factors associated with ULP include intraoperative nerve injury (18), the angle of the posterior opening of the laminae (19), and the presence of preoperative spinal cord hyperintensity (20).

Whether prophylactic C4/5 foraminotomy can prevent the occurrence of ULP remains controversial. In a retrospective clinical study, Ohashi (8) found that prophylactic foraminoplasty can reduce the incidence of ULP from 7% to 1.7% at 2 years postsurgery. Nonetheless, several recent studies have shown that prophylactic C4/5 foraminoplasty does not prevent the occurrence of postoperative ULP; the authors did not recommend it as a preventive surgery (9,21). Moreover, a comprehensive case study of 27 clinical centers reported that

Table 3. Number of PPCED segments and incidences of ULP

Number of PPCED Segments	ULP (n = 6)	Non-ULP (n = 604)	Incidence (%)
1 segment	4	553	0.72
2 segments	2	51	3.77
Total	6	604	0.98

P = 0.0886, Fisher's exact test

Table 4. Levels of PPCED and incidences of ULP

Levels of PPCED	ULP (n = 6)	ULP (n = 604)	Incidence (%)
C4/5	2	28	6.67
C5/6	2	175	1.13
C6/7	0	310	0
C7/T1	0	40	0
C4/5/6	1	17	5.56
C5/6/7	1	34	2.86
Total	6	604	0.98

P = 0.002747 < 0.001, Fisher's exact test

Table 5. Width of intervertebral foramen and incidences of ULP

Characteristics	ULP (n = 6)	Non-ULP palsy (n = 604)	P value
Width of intervertebral foramen on computed tomography mm ± SD	2.3 ± 1.12	3.4 ± 1.23	0.0295
Width < 3 mm, n (%)	4 (66.67)	126 (20.86)	0.0208

posterior cervical laminoplasty combined with foraminoplasty was more likely to result in postoperative ULP than posterior cervical laminoplasty alone (15.1% vs 3.1%). The authors believe that heat from the drill may lead to damage to the sensitive nerve root (22).

PPCED was developed from open posterior cervical foraminal decompression, which is essentially a cervical foraminal enlargement surgery performed completely endoscopically. To avoid postoperative axial pain and segmental instability caused by posterior muscle dissection, minimally invasive posterior cervical foraminotomy, also known as posterior cervical key-hole surgery, is performed using a channel under a microscope or a microendoscope. In 2007, Ruetten (4) first reported the application of full endoscopic discectomy by the posterior cervical key-hole approach, while Kim et al (23) reported a minimally invasive approach to the cervical spine with less trauma and faster recovery. In general, PPCED is being widely performed for cervical



radiculopathy caused by lateral cervical disc herniation and foraminal stenosis.

ULP is a serious condition, but complications of PPCED are rare (6). Wu's meta-analysis (5) of PPCED complications found that the most frequent complication was transient root palsy (4.5%), which clinically manifested as hypoesthesia or numbness in the newly developed nerve root innervation area after surgery, with or without a decrease in muscle strength. Although the definition of nerve root palsy reported in the literature mainly manifests as sensory disturbance, some patients primarily experience decreased muscle strength (deltoid and biceps) after PPCED. As ULP in the literature involves the same concept as C5 palsy, which not only occurs in the C4/5 segment but also in the C5/6 segment after PPCED (24), we defined it herein as postoperative ULP after PPCED.

The incidence of postoperative ULP in this study was 0.98%, which was lower than that of conventional cervical spine surgery (6%) (13) and of temporary nerve palsy after PPCED (4.5%) (5). The patients' condition was complex, including foraminal stenosis and a highly migrated disc herniation. Our study found that the incidence of postoperative ULP was associated with case selection and learning curves. In the early stage of the PPCED operation in this study, ULP was rare due to the relatively simple case selection (soft lateral protrusion). However, with the accumulation of clinical cases, the surgical indications became expanded, the difficulty of the operation increased, and the incidence of ULP, mainly manifesting as decreased muscle strength, gradually increased.

Different from conventional open cervical surgery, the core of the PPCED technique is to expand the intervertebral foramen and decompress the nerve root canal (25). PPCED has no significant effect on spinal cord drift or intervertebral height increase, and as a result, there is no traction or ischemic damage to nerve roots. By analyzing the data of this case series and the previous literature (9,21,22), we consider that the causes of postoperative ULP after PPCED include the following: 1) advancement and disturbance of the C5 or C6 nerve root; 2) nerve root damage caused by the heat generated by the application of a power drill and bipolar radiofrequency during the operation; and 3) aggravation of the already damaged nerve root in the severely narrowed nerve root canal via intraoperative decompression.

Anatomy is an important factor affecting postoperative ULP after PPCED. Anatomical studies have

found that ULP is mainly caused by C5 nerve root injury, but because the adjacent C5 and C6 nerve root innervation areas overlap each other, C6 nerve root palsy can also lead to ULP (26). In our study, cases of endoscopic dural tears and neurological injuries with obvious manipulation errors were excluded. Our results showed that in single-segment PPCED, the C4/5 segment was associated with the highest rate of ULP (6.67%), followed by C5/6 (1.13%); there was no ULP below the C6/7 segment, which is similar to the results of conventional open cervical spinal surgery.

The high incidence of ULP in the C4/5 and C5/6 segments is closely related to the morphometric characteristics of the nerve roots. The C5 nerve root travels a shorter distance in the spinal canal and has a more horizontal direction and greater tension than other segmental nerve roots (9). Adjacency between nerve roots and corresponding cervical discs is important in PPCED. A study by Nobuhiro (27) found that as the cervical spine descends, the nerve roots are positioned higher relative to the intervertebral discs. Most C5/6 discs are ventral to the C5 nerve roots, whereas most discs below C6/7 are in the axillary region of the nerve roots. Therefore, a greater degree of retraction on the C5 nerve root is needed for discectomy, which results in potential damage to the nerve root.

As the C7 and C8 nerve roots are located below the level of the intervertebral disc, the possibility of intraoperative C7 and C8 nerve root injury is less likely. C7 and lower nerve roots innervate the forearm and hand muscles. Myung (28) reported a case of postoperative decreases in finger grip strength (C7 palsy) due to intraoperative C7 root retraction, which resolved completely by 6 months after surgery. In the present study, no muscle weakness was found after PPCED in segments below C6/7. One of the possible reasons is that there is more overlap in the innervation of the nerve roots in the hand, which contributes to muscle strength, and that the injury of a single C7 or T1 nerve root does not lead to obvious muscle strength abnormalities.

Previous studies have suggested that ULP during foraminoplasty occurs owing to nerve root injury caused by the high temperatures generated by a high-speed power drill (22). In animal experiments, it was found that diamond grinding heads and stainless steel grinding heads can generate high temperatures of 174°C and 77°C, respectively (29). Studies by Tamai K et al (30) and Takenaka (31) suggest that the use of chilled saline to lower the temperature in cervical foraminoplasty under open or minimally invasive access

can reduce the occurrence of ULP. In PPCED surgery, a drill is also used to decompress the bone structure; thus, a high-temperature drill head in a saline environment of normal temperature may be one of the causes of nerve root injury. In PPCED, a radiofrequency bipolar coagulator is required for hemostasis or intervertebral disc ablation. The temperature of the head end of a radiofrequency cutter head can reach 70°C (32), and repeated hemostasis around the nerve root may also cause damage to the nerve root. Therefore, the application of ice saline lavage, the reduced use of grinding heads and radiofrequency involved may help to prevent ULP.

Our study excluded patients with preoperative cervical radiculopathy with decreased muscle strength. However, the cervical intervertebral foramen is significantly narrowed in some patients; the course of the disease may also be longer, and underlying radiculopathy may already exist. Previous reports support that cervical radiculopathy confirmed by preoperative electromyography is an important factor in postoperative ULP (33). In this study, postoperative ULP occurred in 3/98 cases (3.06%) with an intervertebral foramen width < 3 mm, much higher than that with a width  $\geq$  3 mm (3/162, 1.8%). Hence, preoperative foramen width correlates highly negatively with postoperative ULP incidence. This suggests that after long-term compression caused by intervertebral foraminal stenosis, underlying radiculopathy may be present, which becomes aggravated during foraminotomy and leads to the occurrence of ULP.

Different from ULP after open surgery, all 6 patients in this study experienced a definite decrease in shoulder and elbow muscle strength on the first postoperative day, without delay. Postoperatively, patients have fewer symptoms and faster recovery after PPCED

than after open surgery foraminoplasty (22). Therefore, PPCED is less invasive than open surgery.

### Limitations

There are some limitations in this study. First, due to the low incidence of ULP after PPCED, the number of cases was insufficient, the statistics were biased, and multiple regression analysis could not be performed to clarify factors relevant to ULP. The possible etiology can only be speculated on the basis of the literature and relevant clinical experience, which is not sufficiently convincing. Second, as this was a clinical retrospective study, evidentiary support was low. Therefore, prospective controlled studies with more cases and more clinical centers are needed to further clarify the symptoms, etiology, and outcome of postoperative ULP after PPCED.

### CONCLUSIONS

PPCED is a good treatment for cervical radiculopathy. The rate of postoperative ULP after PPCED is much lower than that after posterior cervical foraminotomy. Perturbation to the C5 (or C6) nerve root, thermal injury from the burr or radiofrequency used, and marked foraminal stenosis are possible relevant factors for postoperative ULP. Postoperative ULP after PPCED has a good prognosis with a short recovery time.

### Author Contributions

XG and XJY designed the study. WHW and XG wrote the manuscript. LT and GZ collected the data. BX and YHX performed the data analysis. All authors read and approved the final manuscript. XG is responsible for this article.

### REFERENCES

1. Corey DL, Comeau D. Cervical radiculopathy. *Med Clin North Am* 2014; 98:791-799, xii.
2. Spurling RG, Scoville W. Lateral rupture of cervical intervertebral disc. A common cause of shoulder and arm pain. *Surg Gynecol Obstet* 1944; 78:350-358.
3. Adamson TE. Microendoscopic posterior cervical laminoforaminotomy for unilateral radiculopathy: Results of a new technique in 100 cases. *J Neurosurg* 2001; 95:51-57.
4. Ruetten S, Komp M, Merk H, et al. A new full-endoscopic technique for cervical posterior foraminotomy in the treatment of lateral disc herniations using 6.9-mm endoscopes: Prospective 2-year results of 87 patients. *Minim Invasive Neurosurg* 2007; 50:219-226.
5. Wu PF, Liu BH, Wang B, et al. Complications of full-endoscopic versus microendoscopic foraminotomy for cervical radiculopathy: A systematic review and meta-analysis. *World Neurosurg* 2018; 114:217-227.
6. Zheng C, Huang X, Yu J, et al. Posterior percutaneous endoscopic cervical discectomy: A single-center experience of 252 Cases. *World Neurosurg* 2018; 120:e63-e67.
7. Miller JA, Lubelski D, Alvin MD, et al. C5 palsy after posterior cervical decompression and fusion: Cost and quality-of-life implications. *Spine J* 2014; 14:2854-2860.
8. Ohashi M, Yamazaki A, Watanabe K, et al. Two-year clinical and radiological outcomes of open-door cervical laminoplasty with prophylactic bilateral C4-C5 foraminotomy in a prospective study. *Spine (Phila Pa 1976)* 2014;

- 39:721-727.
9. Liu G, Reyes MR, Riew KD. Why does C5 palsy occur after prophylactic bilateral C4-5 foraminotomy in open-door cervical laminoplasty? A risk factor analysis. *Global Spine J* 2017; 7:696-702.
  10. Takenaka S, Kashii M, Iwasaki M, et al. Risk factor analysis of surgery-related complications in primary cervical spine surgery for degenerative diseases using a surgeon-maintained database. *Bone Joint J* 2021; 103-b:157-163.
  11. Pennington Z, Lubelski D, D'Sa A, et al. Preoperative clinical and radiographic variables predict postoperative C5 palsy. *World Neurosurg* 2019; 127:e585-e592.
  12. Oshina M, Segawa T, Oshima Y, et al. C5 palsy after C5/6/7 posterior foraminotomy decompression: A case report. *Medicine (Baltimore)* 2020; 99:e18817.
  13. Lubelski D, Derakhshan A, Nowacki AS, et al. Predicting C5 palsy via the use of preoperative anatomic measurements. *Spine J* 2014; 14:1895-1901.
  14. Nassr A, Eck JC, Ponnappan RK, et al. The incidence of C5 palsy after multilevel cervical decompression procedures: A review of 750 consecutive cases. *Spine (Phila Pa 1976)* 2012; 37:174-178.
  15. Oh JK, Hong JT, Kang DH, et al. Epidemiology of C5 palsy after cervical spine surgery: A 21-center study. *Neurospine* 2019; 16:558-562.
  16. Anand SK, Macki M. What have we learned from C5 palsy - A short communication. *J Clin Neurosci* 2020; 81:111-112.
  17. Hasegawa K, Homma T, Chiba Y. Upper extremity palsy following cervical decompression surgery results from a transient spinal cord lesion. *Spine (Phila Pa 1976)* 2007; 32:E197-E202.
  18. Hirabayashi K, Toyama Y, Chiba K. Expansive laminoplasty for myelopathy in ossification of the longitudinal ligament. *Clin Orthop Relat Res* 1999; 359:35-48.
  19. Uematsu Y, Tokuhashi Y, Matsuzaki H. Radiculopathy after laminoplasty of the cervical spine. *Spine (Phila Pa 1976)* 1998; 23:2057-2062.
  20. Kaneko K, Hashiguchi A, Kato Y, et al. Investigation of motor dominant C5 paralysis after laminoplasty from the results of evoked spinal cord responses. *J Spinal Disord Tech* 2006; 19:358-361.
  21. Takeuchi K, Yokoyama T, Wada K, et al. Critical points and effectiveness of prophylactic C4/5 foraminotomy to prevent C5 palsy after posterior cervical spine surgery. *Acta Orthop Traumatol Turc* 2021; 55:527-534.
  22. Ishiguro H, Takenaka S, Kashii M, et al. Direct involvement of concomitant foraminotomy for radiculomyelopathy in postoperative upper limb palsy in cervical laminoplasty. *World Neurosurg* 2021; 146:e14-e21.
  23. Kim CH, Kim KT, Chung CK, et al. Minimally invasive cervical foraminotomy and discectomy for laterally located soft disk herniation. *Eur Spine J* 2015; 24:3005-3012.
  24. Takenaka S, Nagamoto Y, Aono H, et al. Differences in the time of onset of postoperative upper limb palsy among surgical procedures: A meta-analysis. *Spine J* 2016; 16:1486-1499.
  25. Ahn Y. Current techniques of endoscopic decompression in spine surgery. *Ann Transl Med* 2019; 7:S169.
  26. Guday E, Bekele A, Mucbe A. Anatomical study of prefixed versus postfixed brachial plexuses in adult human cadaver. *ANZ J Surg* 2017; 87:399-403.
  27. Tanaka N, Fujimoto Y, An HS, et al. The anatomic relation among the nerve roots, intervertebral foramina, and intervertebral discs of the cervical spine. *Spine (Phila Pa 1976)* 2000; 25:286-291.
  28. Youn MS, Shon MH, Seong YJ, et al. Clinical and radiological outcomes of two-level endoscopic posterior cervical foraminotomy. *Eur Spine J* 2017; 26:2450-2458.
  29. Hosono N, Miwa T, Mukai Y, et al. Potential risk of thermal damage to cervical nerve roots by a high-speed drill. *J Bone Joint Surg Br* 2009; 91:1541-1544.
  30. Tamai K, Suzuki A, Takahashi S, et al. The incidence of nerve root injury by high-speed drill can be reduced by chilled saline irrigation in a rabbit model. *Bone Joint J* 2017; 99-B:554-560.
  31. Takenaka S, Hosono N, Mukai Y, et al. The use of cooled saline during bone drilling to reduce the incidence of upper-limb palsy after cervical laminoplasty: Clinical article. *J Neurosurg Spine* 2013; 19:420-427.
  32. Ru N, Su C, Li J, et al. Varied low back pain induced by different spinal tissues in percutaneous endoscopic lumbar discectomy: A retrospective study. *Pain Physician* 2022; 25:E331-E339.
  33. Sasai K, Saito T, Akagi S, et al. Preventing C5 palsy after laminoplasty. *Spine (Phila Pa 1976)* 2003; 28:1972-1977.