

Retrospective Study

e Analysis of Risk Factors and Prediction Model for Recurrence of Hemifacial Spasm After Radiofrequency Ablation

Yong Fei, MD¹, Enming Zhang, MD², Yi Wu, MD³, Jianmei Xia, MD¹, Bing Huang, MD¹, and Ming Yao, PhD¹

From: ¹Department of Anesthesiology and Pain, The Affiliated Hospital of Jiaxing University, Jiaxing, P.R. China; ²Jiaxing University Master Degree Cultivation Base, Zhejiang Chinese Medical University, P. R. China; ³Department of Scientific Research and Discipline Development, The Affiliated Hospital of Jiaxing University, Jiaxing, P.R. China

Address Correspondence: Bing Huang, MD
Department of Anesthesiology and Pain
The Affiliated Hospital of Jiaxing University 1882 Zhong-Huan-South Road Jiaxing 314000, P.R. China. E-mail: jxhb999@sina.com

Disclaimer: Yong Fei, MD, and Enming Zhang, MD, contributed equally to this work. Key Discipline Established by Zhejiang Province and Jiaxing City Jointly-Pain Medicine (2019-ss-ttx); Zhejiang Provincial Natural Science Foundation of Social welfare projects (LGF20H090021); Medical and Health Science and Technology Research Program of Zhejiang Province (2022KY1239); and Jiaxing Key Laboratory of Neurology and Pain Medicine.

Conflict of interest: Each author certifies that he or she, or a member of his or her immediate family, has no commercial association (i.e., consultancies, stock ownership, equity interest, patent/licensing arrangements, etc.) that might pose a conflict of interest in connection with the submitted manuscript.

Manuscript received: 04-23-2022
Revised manuscript received: 06-22-2022
Accepted for publication: 07-29-2022

Free full manuscript:
www.painphysicianjournal.com

Background: Computed tomography (CT)-guided percutaneous stylomastoid foramen puncture radiofrequency ablation for the treatment of hemifacial spasm has a significant clinical effect; however, related risk factors for recurrence have not been studied.

Objective: To investigate the risk factors for the recurrence of hemifacial spasm after radiofrequency ablation and construct a model for predicting recurrence.

Study Design: This is a single-center retrospective observational study.

Setting: The study was conducted at the Pain Department of the Affiliated Hospital of Jiaxing College in Jiaxing, China.

Methods: A retrospective analysis was performed on 99 patients diagnosed with primary hemifacial spasm (HFS) admitted to the Affiliated Hospital of Jiaxing University between August 2018 and December 2021. All patients underwent CT-guided percutaneous stylomastoid foramen radiofrequency ablation. Kaplan-Meier survival analysis, log-rank test, and Cox proportional risk regression model were used to analyze the clinical factors that affect the recurrence of patients with HFS after radiofrequency ablation, and a recurrence prediction model was established.

Results: Follow-up was 3-12 months; recurrence rates were 20.2%, 36.4%, and 71.9% at 3, 6, and 12 months postoperatively, respectively. Univariate analysis showed that puncture approach, operation time, and facial paralysis level were factors influencing recurrence in patients with HFS after radiofrequency ablation ($P < 0.05$). The multivariate Cox proportional risk regression model showed that the operative time and facial paralysis grade were independent factors for recurrence after radiofrequency ablation in patients with facial spasms. The recurrence risk function model of patients with facial spasms after radiofrequency ablation was expressed as $h(t) = h_0 \exp(-0.619X_1 - 2.589X_2)$, where X_1 and X_2 represent the operation time and facial paralysis grade, respectively. The likelihood ratio of the model was statistically significant ($\chi^2 = 55.769$, $P < 0.001$).

Limitations: We look forward to increasing the sample size in follow-up studies and exploring relevant conclusions in randomized controlled trials.

Conclusion: Long operation times and high-grade facial paralysis can reduce the risk of recurrence in patients with facial spasms. The constructed recurrence prediction model could serve as a reference for clinical diagnosis and treatment.

Key words: Hemifacial spasm, radiofrequency ablation, recurrence, risk-factors, prediction model

Pain Physician 2022; 25:E1249-E1255

Hemifacial spasm (HFS), also known as facial spasm, is an involuntary spasm of one side of the face. Convulsions are paroxysmal and irregular, varying in degree, and can be aggravated by fatigue, mental tension, and voluntary movement. The disease usually begins with the orbicularis oculi muscle and affects the entire face (1-2). As for the mechanism of primary hemifacial spasm, most scholars accept the theory of microvascular compression of the facial nerve root in the pontine section. The responsibility of the compression of blood vessels leads to facial nerve demyelination changes, causes ectopic action potential "interactive mixing" from the face of the side of the nerve abnormal discharge, and causes facial muscle involuntary convulsion, that is, facial muscle spasm (3). The disease occurs mostly after middle age and is common in females, seriously affecting the patient's life, studies, and work; at the same time, some patients may also experience some headache and tinnitus symptoms, which result in patient upset and some anxiety symptoms. However, there are few treatments for HFS, and facial Botox subcutaneous injection has a short efficacy and is easily tolerated (4-5). Microvascular decompression (MVD) is a classic treatment technique for HFS (6); however, the high risk and cost of this operation are the main reasons why patients are reluctant to choose this surgical method. Computed tomography (CT)-guided percutaneous stylomastoid foramen radiofrequency ablation to treat HFS has achieved significant therapeutic effects, and the facial muscles of the patients stopped twitching immediately after surgery with high satisfaction (7). Radiofrequency ablation for HFS involves partial destruction of the facial nerve to eliminate HFS without causing severe facial paralysis. CT-guided percutaneous stem-milk foramina radiofrequency ablation is effective in the treatment of facial spasm, and the symptoms of facial muscle convulsion can disappear. Moreover, CT-guided puncture has the advantages of safety, effectiveness, and accuracy (8). As there have been no reports on recurrence after facial nerve radiofrequency ablation, this study retrospectively analyzed the clinical data of 99 patients diagnosed with HFS, discussed risk factors for recurrence, and constructed a recurrence prediction model to provide a reference to control recurrence of HFS after radiofrequency ablation.

METHODS

Inclusion and Exclusion Criteria

This study was approved by the Ethics Committee

of the Affiliated Hospital of Jiaxing University in Jiaxing, China, and 99 patients who underwent CT-guided percutaneous stylomastoid foramen puncture and radiofrequency ablation of the facial nerve for the treatment of HFS in our hospital from August 2018 to December 2021 were included in this retrospective study.

Inclusion criteria: 1) meeting the diagnostic criteria for HFS and affecting the quality of life of the patients (9); 2) refusal to undergo MVD surgery or cannot tolerate general anesthesia; 3) refusal to undergo Botox treatment; 4) agreed to accept CT-guided radiofrequency thermocoagulation and signed informed consent.

Exclusion criteria were as follows: 1) preoperative thrombocytopenia or coagulation dysfunction; 2) infection or tumor at the puncture site; 3) preoperative head CT and craniocerebral MRI examination ruled out pontine cerebellar angle occupying lesions; 4) lost to follow-up or absence of medical records.

Surgical Procedure

This research team was the first to use CT-guided percutaneous stylomastoid foramen radiofrequency ablation to treat HFS in the awake state (7). The specific surgical procedures were as follows: after entering the room, the patient lay on the CT bed with the affected side on the upper side, the venous access was opened, oxygen saturation (SpO₂), noninvasive blood pressure (BP), and electrocardiogram (ECG) were monitored, and oxygen was administered through a nasal catheter. A CT positioning grid was placed in front of and behind the earlobe (Fig. 1). Cephalic localization images were taken using the paranasal sinus model, and axial scanning of the mastoid region with a thickness of 3 mm was performed. The puncture approach was designed with the nipple hole of the affected stem as the target (Fig. 2). Local anesthesia was performed at the puncture site, and a No. 7 radiofrequency needle (Model 240100, Normande Medical Technology Co., Ltd.) with a length of 5 cm, a diameter of 0.9 cm, and an exposed end of 5 mm was used to puncture the target site under the guidance of CT (Fig. 3), and the observation of 3D reconstruction was confirmed by CT scan (Fig. 4). Another approach is the posterior mastoid approach (Fig. 5). Pain radiofrequency temperature-controlled thermal coagulator (R-2000B type, Beijing Beiqi Medical Technology Co., LTD.) and low-frequency (2 Hz) current was used for motor nerve stimulation test. If an electric current below 0.5 mA induced the twitch of the

affected side facial muscle with the same frequency as electric stimulation, then the standard radiofrequency was administered, starting at 65°C for 30 s. Simultaneously, the patients were asked to bulge their cheeks, close their eyes; radiofrequency was stopped immediately after the cheeks leaked. If there was no change in the patient's cheek and eye closure after 65°C for 30 s, the temperature of the radio frequency parameters was increased by 5°C, and then the next 30 s of radiofrequency was performed until the patient had a slight air leakage in the drum on the affected side and a slight difficulty in the lower eyelid when the eye was closed. The surgery was terminated immediately. If current stimulation above 0.5 mA induced the same frequency twitch of facial muscles, the electrical stimulation test and radiofrequency should be performed after adjusting the position of the needle tip. Termination temperature, operation time, termination time, and grade of facial paralysis were recorded, and the therapeutic effect of hemifacial spasm was observed in outpatient or WeChat video follow-ups.

Follow-Up

Follow-up was conducted by referring to inpatient medical records, outpatient follow-up or phone calls, and WeChat videos to obtain information on HFS patients after radiofrequency ablation, such as grade

of facial paralysis, recurrence, and recurrence time. Follow-up began on the day of radiofrequency ablation of the hemifacial spasm and ended on March 31, 2022. The diagnostic criterion for the recurrence of HFS is the onset of involuntary twitching of the facial muscles. The degree of facial paralysis was recorded

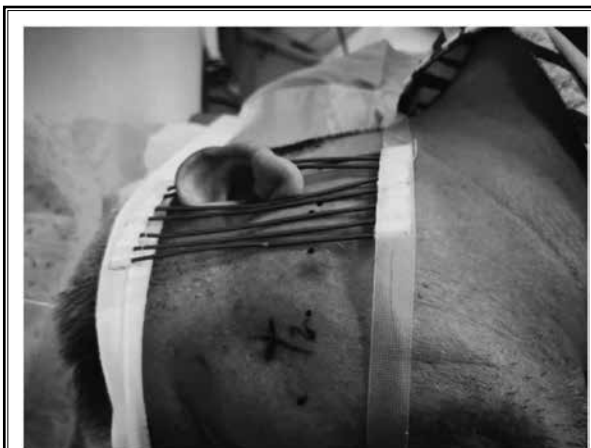

Fig. 1. Positioning grids were placed before CT scanning (positioning grids were made by the interventional catheter and placed longitudinally before and after the earlobe so as to determine the puncture point in combination with the development of positioning grids on the skin on CT scanning images).

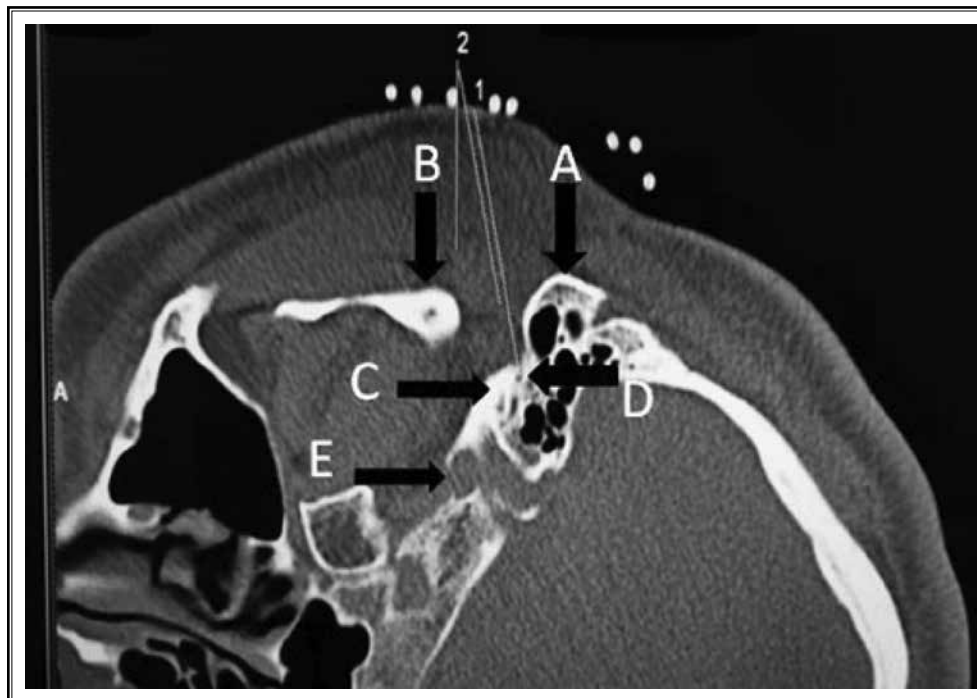
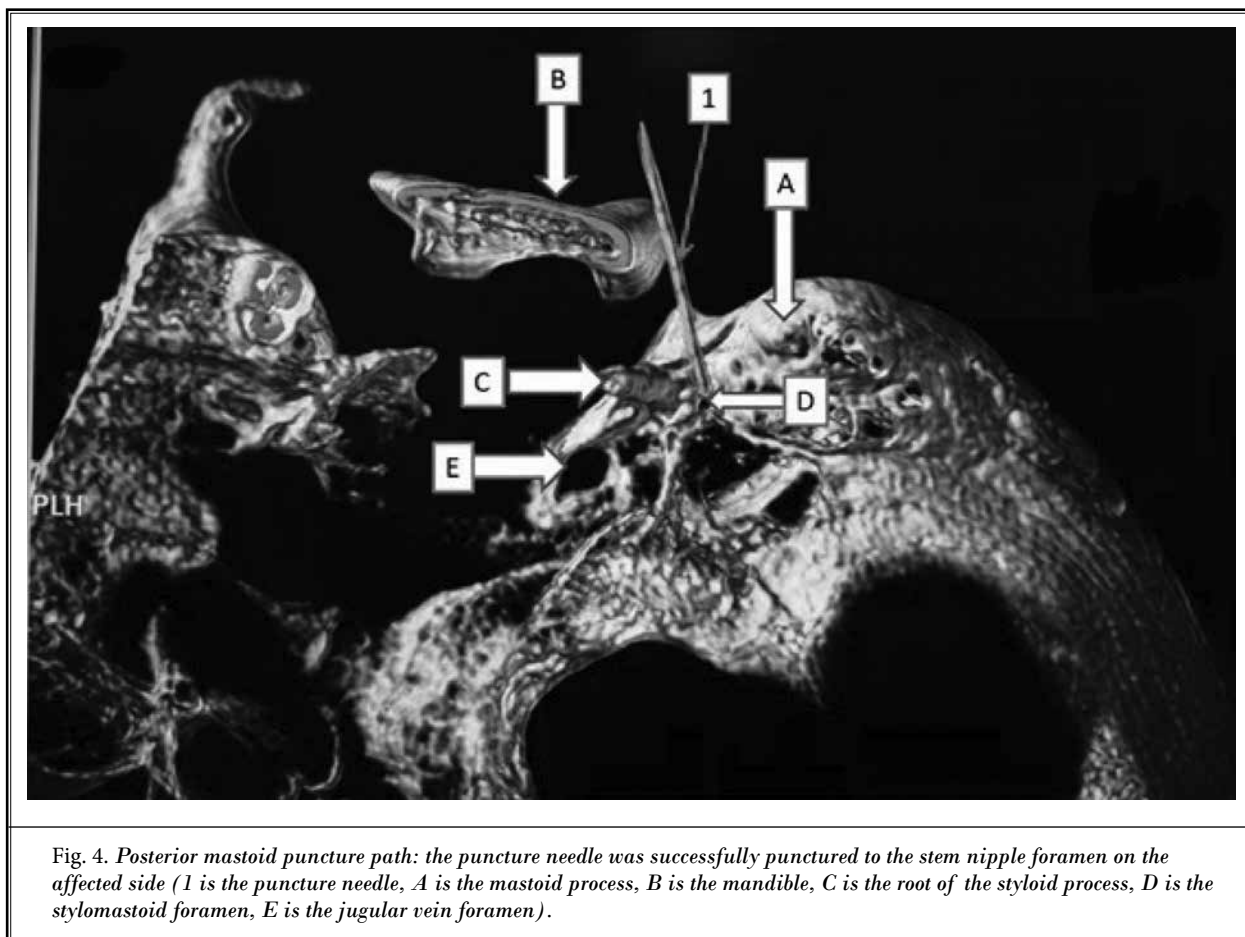
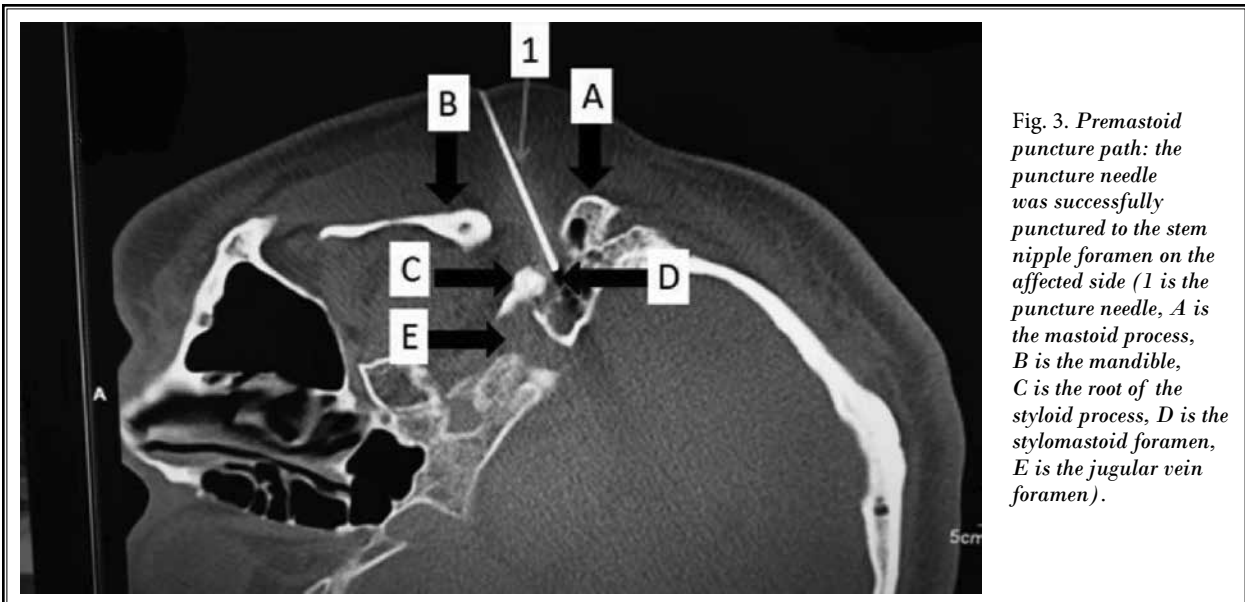


Fig. 2. Premastoid puncture path design: 1: puncture depth 4.18cm; 2 is the puncture angle (included with the sagittal plane) of 13 degrees, A is the mastoid process, B is the mandible, C is the root of the styloid process, D is the stylomastoid foramen, and E is the jugular vein foramen. The white points close to the skin in the figure are developed as positioning bars so as to mark the skin puncture points.



according to the House-Brackmann classification standard (10): Class I, normal without facial paralysis; class II, mild paralysis; class III, moderate paralysis; class IV, moderate-severe paralysis; class V, severe paralysis; and class VI, total paralysis.

Statistical Analysis

SPSS software version 21.0 (IBM Corporation, Armonk, NY) was used for the statistical analysis. The Kaplan-Meier method and log-rank test were used for survival analysis. A Cox proportional risk regression model was used for multivariate analysis, and a recurrence prediction model was established. The test level was $\alpha = 0.05$.

RESULTS

Demographic Data

A total of 102 patients with HFS who underwent radiofrequency ablation were included, of which one case was excluded from the data analysis due to incomplete data, 2 cases were lost to follow-up due to repeated telephone contacts, and a total of 99 eligible patients with HFS were finally included. Basic information of the patients is shown in Table 1.

Follow-Up Data

The patients were followed for 3-12 months, with a median follow-up of 12 months. Recurrence rates at 3, 6, and 12 months postoperatively were 20.2%, 36.4%, and 71.9%, respectively.

Univariate Analysis

The puncture approach, operation time, and grade of facial paralysis were related to recurrence after radiofrequency ablation of facial spasm ($P < 0.05$). Gender, age, affected side, medical history, botox treatment history, termination time, and termination temperature were not associated with recurrence after radiofrequency ablation in patients with hemifacial spasm ($P > 0.05$), as shown in Table 1.

Multivariate Step-by-Step Cox Proportional Risk Regression Model

Postoperative recurrence was the survival outcome, and multivariate stepwise Cox proportional risk regression model was used to analyze the covariates with statistically significant factors in the univariate test (variable filtering method forward: $LR, \alpha_{\lambda} = 0.05, \alpha_{\text{出}} = 0.10$). The results showed that short operative time

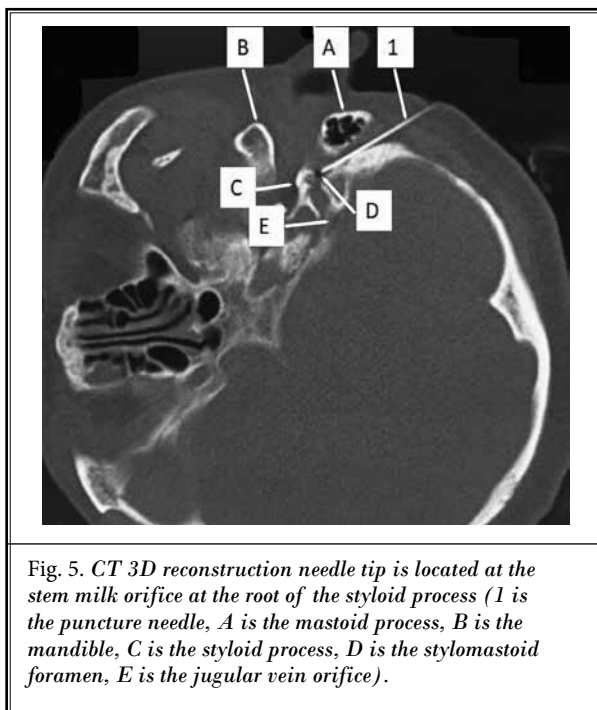


Fig. 5. CT 3D reconstruction needle tip is located at the stem milk orifice at the root of the styloid process (1 is the puncture needle, A is the mastoid process, B is the mandible, C is the styloid process, D is the stylomastoid foramen, E is the jugular vein orifice).

and low-grade facial paralysis were independent risk factors for recurrence after radiofrequency ablation in patients with facial spasms, as shown in Table 2.

Multifactor Prediction Model

According to the analysis results of the multivariate Cox proportional risk regression model, the recurrence risk function model expression of patients with facial spasm after radiofrequency ablation was fitted as $h(t) = h_0 \exp(-0.619X_1 - 2.589X_2)$, Prognostic index = $-0.619X_1 - 2.589X_2$, where X_1 and X_2 represent operation time and facial paralysis grade, respectively. The likelihood ratio of the model was statistically significant ($\chi^2 = 55.769, P < 0.001$).

DISCUSSION

In 2005, Jannetta et al proposed that the pathogenesis of primary HFS and primary trigeminal neuralgia was the same as the theory of microvascular compression theory (3). MVD has become the standard treatment for HFS. However, MVD surgery is associated with many serious and dangerous complications, such as facial paralysis, hearing impairment, cerebrospinal fluid leakage, intracranial infection, intracranial hemorrhage, cerebellar infarction, and even death (11-13). Relatively safe local injection of carnitine is effective for primary HFS for only approximately 3 months (14).

Table 1. *Univariate analysis of recurrence after radiofrequency ablation in 99 patients with hemifacial spasm.*

Variable	Cases	Median to recurrence	95% CI	P
Gender				0.672
Male	34	7	5.099-8.901	
Female	65	9	7.719-10.281	
Age				
≤ 60	42	9	6.701-11.299	0.421
> 60	57	9	7.786-10.214	
Affected side				
Left	54	9	7.609-10.391	0.972
Right	45	8	6.360-9.640	
Medical history (M)				0.134
≤ 24	35	7	5.377-8.623	
> 24	64	9	8.222-9.778	
BTX				0.613
Yes	37	9	7.819-10.181	
No	62	7	5.638-8.362	
Surgical approach				0.000
Anterior	69	7	5.934-8.066	
Posterior	30	-	-	-
Final temperature (°)				0.156
≤ 75	44	9	8.087-9.913	
> 75	55	7	5.183-8.817	
Terminal time (S)				0.719
≤ 25	41	9	8.235-9.765	
> 25	58	7	5.135-8.865	
Operation time (min)				0.001
≤ 30	60	7	5.937-8.063	
> 30	39	12	8.358-15.642	
Facial paralysis				0.000
Grade II and below	67	6	4.932-7.068	
Class II above	32	-	-	

Table 2. *Analysis of 99 patients with postoperative hemifacial spasm by multivariate step-cox proportional risk. Regression Model*

Risk factors	β	SE	Wald	P	OR	95% CI
Operation time	-0.619	0.268	5.338	0.021	0.538	0.318-0.910
Facial paralysis level	-2.589	0.449	33.253	0.000	0.075	0.031-0.181

This research team took the lead in using CT-guided percutaneous stylomastoid foramen radiofrequency ablation in the awake state to treat HFS and achieved a good therapeutic effect, which has the advantages of precision, minimally invasive, safety, and effectiveness (7). This technique, like extracranial radiofrequency therapy for primary trigeminal neuralgia, requires the sacrifice of part of the patient's nerve function (15-17). Radiofrequency treatment of facial spasms inevitably causes functional dysfunction of facial expression muscles. The related complications of this technique were only mild or moderate facial palsy on the affected side, which also shows that the CT-guided percutaneous stylomastoid foramen radiofrequency ablation method can effectively treat primary HFS. Although the facial nerve is a mixed nerve, in addition to movement of the facial muscle, it also innervates the taste and secretion of the lacrimal gland in the anterior 2/3 region of the tongue, and the radiofrequency thermal coagulation of the facial nerve in this treatment is not completely destroyed, but partially inactivated, manifested as partial loss of motor function (cheeks bulging leakage and eye closing fatigue). The degree of facial paralysis is controlled in the House-Brackmann classification standard between I-III to avoid complete loss of taste function and gland points (7).

Although CT-guided percutaneous stylomastoid foramen radiofrequency ablation for HFS has a definite therapeutic effect, radiofrequency thermal coagulation of the opposite nerve in this treatment is not completely destroyed, and the injured nerve may still recrudescence after repair. In this study, a single factor combined with multiple factors was used to analyze the factors influencing recurrence in patients with HFS after radiofrequency ablation, and a recurrence prediction model and an individual prognostic index equation were established. In this study, the recurrence rates of HFS at 3, 6, and 12 months after radiofrequency ablation were 20.2%, 36.4%, and 71.9%, respectively. A possible reason for this is that the facial nerve self-repairs after injury over time. Short operative time and low-grade facial paralysis are independent risk factors for recurrence after radiofrequency ablation in patients with facial spasms, which is consistent with the treatment principle of this technique.

Facial paralysis is the main complication associated with this procedure. Adequate communication with patients before surgery guarantees an improvement in patient satisfaction. Although radiofrequency treatment of primary HFS via the stylomastoid foramen is

safer and saves more medical and health resources than MVD, radiofrequency thermal coagulation treatment of primary HFS will inevitably lead to different degrees of facial paralysis on the affected side. This requires not only the operator to master the puncture technology but also to grasp the best time to end the treatment; once there is a gill leak, immediately terminate the radiofrequency treatment to retain facial nerve function to the maximum extent to obtain the best treatment effect. To this end, it is necessary to fully communicate with the patient. Radiofrequency therapy can be implemented only when patients with primary HFS are aware of alternatives, such as MVD and Botox injection, fully understand and accept postoperative facial paralysis, and sign the informed consent. Health care providers should inform the patient of possible postoperative facial paralysis (in the House-Brackmann classification standard III level, static appearance and no obvious angle not oblique), which can be restored in a few months without intervention treatment, and that the effective time of radiofrequency treatment of primary

HFS will be proportional to the degree of postoperative facial paralysis. This is to help patients understand and have realistic expectations of the results of surgery, which include mild facial paralysis so that the patients are not dissatisfied with radiofrequency therapy.

Limitations

This was a single-center retrospective observational study, and the reliability of the conclusions may need to be confirmed in a multicenter, randomized controlled trial. Second, the follow-up period was short. Furthermore, the sample size was small.

CONCLUSION

In conclusion, this study confirmed that surgical duration and facial paralysis grade in patients with HFS are factors related to recurrence of radiofrequency ablation. For patients with the risk factors mentioned above, preventive measures must be taken to improve their prognosis.

REFERENCES

1. Abbruzzese G, Berardelli A, Defazio G. Hemifacial spasm. *Handb Clin Neurol* 2011; 100:675-680.
2. Lefaucheur JP, Ben Daamer N, Sangla S, Le Guerinel C. Diagnosis of primary hemifacial spasm. *Neurochirurgie* 2018; 64:82-86.
3. Jannetta PJ, McLaughlin MR, Casey KF. Technique of microvascular decompression. Technical note. *Neurosurg Focus* 2005; 18:E5.
4. Duarte GS, Rodrigues FB, Castelão M, et al. Botulinum toxin type A therapy for hemifacial spasm. *Cochrane Database Syst Rev* 2020; 11:CD004899.
5. Tambasco N, Filidei M, Nigro P, Parnetti L, Simoni S. Botulinum toxin for the treatment of hemifacial spasm: An update on clinical studies. *Toxins (Basel)* 2021; 13:881.
6. Lee S, Joo KM, Park K. Challenging microvascular decompression surgery for hemifacial spasm. *World Neurosurg* 2021; 151:e94-e99.
7. Huang B, Yao M, Chen Q, et al. Awake CT-guided percutaneous stylomastoid foramen puncture and radiofrequency ablation of facial nerve for treatment of hemifacial spasm. *J Neurosurg* 2021; 1-7.
8. Huang B, Lin H, Du X, et al. Treatment of primary hemifacial spasm with CT-guided percutaneous radiofrequency thermocoagulation in stem and milk forceps. *Chinese Journal of Neuromedicine* 2019; 09:933-938.
9. Tambasco N, Simoni S, Sacchini E, et al. Validation of the Hemifacial Spasm Grading Scale: A clinical tool for hemifacial spasm. *Neurol Sci* 2019; 40:1887-1892.
10. Jannetta PJ, McLaughlin MR, Casey KF. Technique of microvascular decompression. Technical note. *Neurosurg Focus* 2005; 18:E5.
11. Bigder MG, Kaufmann AM. Failed microvascular decompression surgery for hemifacial spasm due to persistent neurovascular compression: An analysis of reoperations. *J Neurosurg* 2016; 124:90-95.
12. Miller LE, Miller VM. Safety and effectiveness of microvascular decompression for treatment of hemifacial spasm: A systematic review. *Br J Neurosurg* 2012; 26:438-444.
13. Lee MH, Jee TK, Lee JA, Park K. Postoperative complications of microvascular decompression for hemifacial spasm: Lessons from experience of 2040 cases. *Neurosurg Rev* 2016; 39:151-158.
14. Gunes A, Demirci S, Koyuncuoglu HR, Tok L, Tok O. Corneal and tear film changes after botulinum toxin-A in blepharospasm or hemifacial spasm. *Cornea* 2015; 34:906-910.
15. Huidan Lin, Gang Cao, Guanjun Jin, et al. Extracranial non-Gasserian ganglion application of radiofrequency thermocoagulation on the mandibular branch of the trigeminal through the foramen ovale for trigeminal neuralgia. *Pain Physician* 2021; 24:E425-E432.
16. Huang B, Yao M, Feng Z, et al. CT-guided percutaneous infrazygomatic radiofrequency neurolysis through foramen rotundum to treat V2 trigeminal neuralgia. *Pain Med* 2014; 15:1418-1428.
17. Xie K, Liu S, Huang B, Yao M. Effects of supraorbital foramen variations on the treatment efficacy of radiofrequency therapy for V1 trigeminal neuralgia: A retrospective study. *Pain Res Manag* 2020; 2020:8142489.

