

Artificial Intelligence

Deep Learning Algorithm Trained on Lumbar Magnetic Resonance Imaging to Predict Outcomes of Transforaminal Epidural Steroid Injection for Chronic Lumbosacral Radicular Pain

Jeoung Kun Kim, PhD¹, Ming Xing Wang, MS¹, and Min Cheol Chang, MD²

From: ¹Department of Business Administration, School of Business, Yeungnam University, Gyeongsan-si, Republic of Korea; ²Department of Rehabilitation Medicine, College of Medicine, Yeungnam University, Daegu, Republic of Korea

Address Correspondence: Min Cheol Chang, MD
Department of Physical Medicine and Rehabilitation, College of Medicine, Yeungnam University 317-1 Daemyungdong, Namku, Taegu 705-717, Republic of Korea
E-mail: wheel633@ynu.ac.kr

Disclaimer: This study was supported by the National Research Foundation of Korea Grant funded by the Korean government (No. NRF2021R1A2C1013073).

Conflict of interest: Each author certifies that he or she, or a member of his or her immediate family, has no commercial association (i.e., consultancies, stock ownership, equity interest, patent/licensing arrangements, etc.) that might pose a conflict of interest in connection with the submitted manuscript.

Manuscript received: 05-20-2022
Revised manuscript received: 06-28-2022
Accepted for publication: 08-16-2022

Free full manuscript: www.painphysicianjournal.com

Background: Transforaminal epidural steroid injections (TFESI) are widely used to alleviate lumbosacral radicular pain. Knowledge of the therapeutic outcomes of TFESI allows clinicians to elucidate therapeutic plans for managing lumbosacral radicular pain. Deep learning (DL) can outperform traditional machine learning techniques and learn from unstructured and perceptual data. A convolutional neural network (CNN) is a representative DL model.

Objectives: We developed and investigated the accuracy of a CNN model for predicting therapeutic outcomes after TFESI for controlling chronic lumbosacral radicular pain using T2-weighted sagittal lumbar spine magnetic resonance (MR) images as input data.

Study Design: Imaging study using DL.

Setting: At the spine center of a university hospital.

Methods: We collected whole T2-weighted sagittal lumbar spine MR images from 503 patients with chronic lumbosacral radicular pain due to a herniated lumbar disc (HLD) and spinal stenosis. A “good outcome” was defined as a $\geq 50\%$ reduction in the numeric rating scale (NRS-11) score at 2 months after TFESI vs the pretreatment NRS-11 score. A “poor outcome” was defined as a $< 50\%$ decrease in the NRS-11 score at 2 months after TFESI vs pretreatment.

Results: In the prediction of therapeutic outcomes after TFESI on the validation dataset, the area under the curve was 0.827.

Limitations: Our study was limited in that we used a small amount of lumbar spine MR imaging data to train the CNN model.

Conclusions: We demonstrated that a CNN model trained, using whole lumbar spine sagittal T2-weighted MR images, could help determine outcomes after TFESI in patients with chronic lumbosacral radicular pain due to an HLD or spinal stenosis.

Key words: Deep learning, convolutional neural network, radicular pain, spinal stenosis, herniated disc, magnetic resonance image, chronic pain, lumbar spine

Pain Physician 2022; 25:587-592

Lumbosacral radicular pain, the most common neuropathic pain (affecting 10% to 25% of the general population), radiates along the lower extremities in the area innervated by the affected nerve root and features a sharp, stabbing,

and shooting quality (1,2). The most common causes of lumbosacral radicular pain are a herniated lumbar disc (HLD) and spinal stenosis (3). Lumbosacral radicular pain reduces an individual's functional ability and quality of life (4). Acute lumbosacral

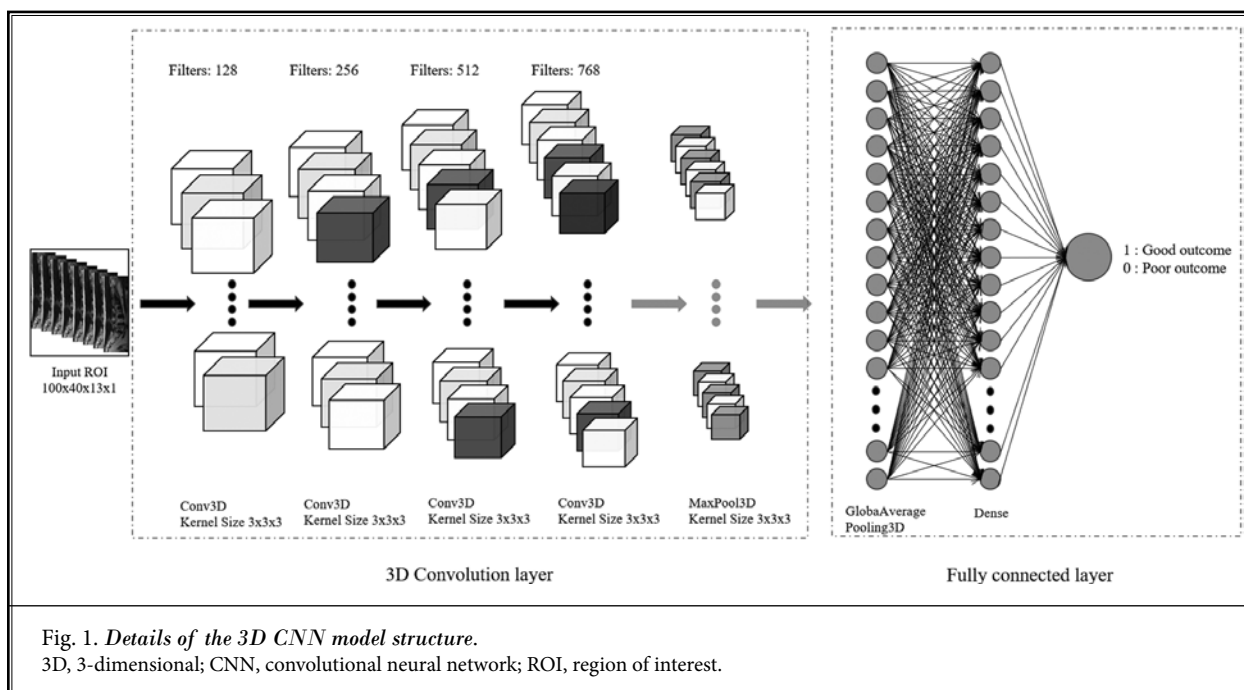
radicular pain that persists for longer than 3 months is considered chronic pain (5). The prognosis of chronic lumbosacral radicular pain is unfavorable (5). Various conservative therapeutic methods, such as oral medications (e.g., pregabalin, gabapentin, tramadol, duloxetine, and amitriptyline), physical therapies, and interventions, are used to treat chronic lumbosacral radicular pain (5). Transforaminal epidural steroid injections (TFESI) are one of the most effective and frequently used methods of alleviating such pain (6-8). Corticosteroids reduce inflammation in the area near the HLD and nerve root inflammation induced by mechanical compression from the spinal stenosis (7). Corticosteroids reduce production and release of various cytokines and inflammation-mediated cells, which is one of the main causes of radicular pain (9). In addition, decreased inflammation can reduce the edema caused by inflammation on the nerve root or tissues surrounding the nerve root. Reduced edema can create space between the bony exit and the nerve root, reducing nerve root compression, venous engorgement, and arterial insufficiency (9). Also, corticosteroids can inhibit neural transmission of pain signal within the nociceptive C-fiber (10,11).

The ability to predict therapeutic outcomes is important to the development of treatment plans for chronic lumbosacral radicular pain. Several studies

(7,12-14) have attempted to determine the therapeutic outcome of TFESI based on clinical features and imaging findings in patients with chronic lumbosacral radicular pain. Many previous studies (7,12-14) reported that lumbar magnetic resonance imaging (MRI) findings, such as HLD size or type, or lumbar spinal stenosis severity, can affect therapeutic outcomes of TFESI. However, the accuracy of predicting therapeutic outcomes of TFESI is currently insufficient.

Machine learning (ML) (15) is a computer algorithm that can automatically learn from data without requiring explicit programming. ML can overcome the limitations of existing analysis techniques and enable breakthroughs in the field of image analysis. Deep learning (DL) (16) is an advanced ML approach that involves the construction of artificial neural networks with structures and functions similar to those of the human brain using a large number of hidden layers. The DL technique outperforms traditional ML techniques and learns from unstructured and perceptual image data. A convolutional neural network (CNN) (17) is a representative DL model that is highly advantageous for imaging recognition and classification.

In this study, we developed a CNN model using lumbar MRI as input data to predict therapeutic outcomes after lumbar TFESI in patients with chronic lumbosacral radicular pain (Fig. 1).



METHODS

Patients

A total of 503 consecutive patients who visited the spine center of a university hospital for lumbosacral radicular pain and underwent lumbar TFESI between January 2013 and December 2021 (mean age = 59.2 ± 14.4, M:W = 226:277, injection levels L2:L3:L4:L5:S1 = 4:18:65:324:92, HLD:lumbar spinal stenosis = 240:263) were retrospectively recruited for this study (Table 1). The inclusion criteria for this study were as follows: (1) age 20-79 years; (2) received single-level lumbar TFESI for segmental pain that radiated to the lower extremity due to an HLD or lumbar spinal stenosis; (3) presentation with a ≥ 3-month history of a symptomatic lumbar radicular pain score of > 3 on a numerical rating scale (NRS-11; 0 = no pain; 10 = the worst pain) prior to TFESI; (4) ≥ 50% temporary pain relief following a diagnostic nerve block with 1 mL of 2% lidocaine; and (5) MRI and electrophysiological findings corresponding to the clinical manifestations. The data of patients who had a history of spinal surgery, such as lumbar fusion or laminectomy, prior to TFESI were excluded. The study protocol was approved by the institutional review board of the university hospital, which waived the requirement for written informed consent owing to the retrospective nature of this study.

TFESI Procedures

TFESI was conducted using the standard method described in a previous study (7). All injections were performed by a single interventional physiatrist specializing in spinal injections. A strict aseptic technique was utilized to perform the TFESI procedures. Patients were placed prone, and C-arm fluoroscopy (Siemens, Erlangen, Germany) was used to aid level identification and needle placement. Lidocaine 1% was administered at the needle insertion site, and the tip of a 25-gauge 90-mm spinal needle with a bend at the tip to allow for guidance was positioned between the lateral vertebral body and the 6 o'clock position below the pedicle. Lateral fluoroscopic imaging demonstrated the presence of the needle tip between the

spinal laminar margin and posterior vertebral body. Under anteroposterior fluoroscopy, 0.3 mL of nonionic contrast material was injected to confirm the absence of vascular uptake and spread of contrast into the foramen. Subsequently, another injection of the contrast medium was performed under real-time fluoroscopic monitoring. Subsequently, 20 mg (0.5 mL) of triamcinolone with 0.5 mL of bupivacaine hydrochloride and 1 mL of normal saline was injected.

Outcome Measurement After TFESI

Pain severity, at pretreatment and 2-month follow-up after TFESI, was assessed on the NRS-11 (0 = no pain; 10 = worst pain). The NRS-11 data were collected via chart review. A "good outcome" was defined as a ≥ 50% reduction in the NRS-11 score at 2 months post-TFESI vs the pretreatment NRS-11 score. A "poor outcome" was defined as a < 50% reduction in the NRS-11 score at 2 months post-TFESI vs the pretreatment score. To validate the change in pain reduction, NRS-11 scores were evaluated by assessing the difference between the pretreatment NRS-11 scores and the 2-month post-treatment scores (change in NRS-11 [%] = [pretreatment score – 2 months post-TFESI score]/pretreatment score × 100).

Images Used for the DL Algorithm (Input Data)

MRI was performed using a sensitivity-encoding head coil on a 1.5-T Philips Gyroscan Intera (Magnetom Vision; Siemens, Erlangen, Germany) with a spine array coil. Spin-echo sequences, axial, and sagittal T1-weighted (repetition time = 583 milliseconds, echo time = 12 milliseconds) and turbo T2-weighted (repetition time = 3,800 milliseconds, echo time = 128 milliseconds) images were

Table 1. Three-dimensional CNN model performance for determining the therapeutic outcomes of TFESI for chronic lumbosacral radicular pain.

Sample Size (patients)	402 (79.9%) for training; 101 (20.1 %) for validation, total 503
Sample Ratio (patients)	Good outcome (1): 219 (43.5%); poor outcome (0): 284 (56.5%) Good outcome (1): 175 (43.5%); poor outcome (0): 227 (56.5%) for training Good outcome (1): 44 (43.6%); poor outcome (0): 57 (56.4%) for validation
Model Performance	- Custom 3D CNN model with 13 dimensions - Adam optimizer, ReLU activation - Learning rate 1e-04, batch size 4 - Data augmentation using random angle rotation [-20, -10, -5, 5, 10, 20] - Dropout 0.1 for regularization - ROI 3D image resized to 100 (H) × 40 (W) × 13 (D) × 1 (C) - Training accuracy: 75.9%; AUC 0.839 with 95% CI (0.800-0.878) - Validation accuracy: 76.2%; AUC 0.827 with 95% CI (0.744-0.909)

Abbreviations: 3D, 3-dimensional; Adam, adaptive moment estimation; AUC, area under the curve; C, channel; CI, confidence interval; CNN, convolutional neural network; D, dimension; H, height; ReLU, rectified linear unit; ROI, region of interest; TFESI, transforaminal epidural steroid injection; W, width.

obtained. All T2-sagittal consecutive lumbar spine magnetic resonance (MR) images of each included patient were used for the development of the DL algorithm. MR images obtained prior to the TFESI were used to develop the DL algorithm. Thirteen T2-weighted sagittal lumbar spine MR slices for each included patient were used to develop the DL algorithm.

DL Algorithms

Python 3.8.8, SciKit-Learn 0.24.1, and TensorFlow 2.8.0 with Keras were used to develop the 3-dimensional (3D) CNN model for diagnosing the TFESI outcomes (Fig. 1). The 3D CNN model consists of 4 layers and uses a 3D array consisting of 13 slices of 100 × 40 resolution MRI as the input data. The region of interest was marked in the lumbar, sacral, and paraspinal muscles. Figure 2 outlines the DL model development process. The details of the 3D CNN model structure are shown in Fig. 1. The diagnostic model uses a 3D array with 13 T2-weighted sagittal MR slices per patient and shows good (1) or poor (0) outcomes.

Statistical Analysis

The statistical analyses were performed using Python 3.8.8 and Scikit-Learn version 0.24.1. Receiver operating characteristic curve analysis was performed, and the area under the curve (AUC) was calculated (Fig. 3). The 95% confidence interval (CI) for the AUC was calculated as described by DeLong et al (18).

RESULTS

The developed 3D CNN model performance was

evaluated using a validation dataset. The validation accuracy was 76.2%, and the AUC was 0.827 (95% CI, 0.774-0.909). The training accuracy was 75.9%, and the AUC was 0.839 (95% CI, 0.800-0.878). Table 1 lists the details and performance of the developed 3D CNN model. The 95% CI for the AUC was calculated using the DeLong et al (18) formula. Scikit-Learn was used to calculate the receiver operating characteristic curve and AUC (Fig. 3).

DISCUSSION

In this study, we developed a CNN model to predict therapeutic outcomes of lumbar TFESI in patients with chronic lumbosacral radicular pain due to an HLD or lumbar spinal stenosis using 13 T2-weighted sagittal lumbar spine MR slices from each of the 503 included patients.

In our study, the AUC of our developed model, evaluated using the validation dataset for predicting the therapeutic outcome 2 months after lumbar TFESI, was 0.827 (Table 1). Considering that an AUC of 0.8-0.9 is generally considered excellent, our CNN model, trained with 13 T2-weighted sagittal lumbar spine MR slices, can help clinicians predict therapeutic outcomes after lumbar TFESI in patients with chronic lumbosacral radicular pain.

A deep neural network (DNN) (19) has a multilayer perceptron architecture with multiple hidden layers, which has a greater ability to analyze input data than a traditional shallow neural network. A CNN, a representative DNN model that specializes in image data analysis, receives multiple channels of 2-dimensional data as

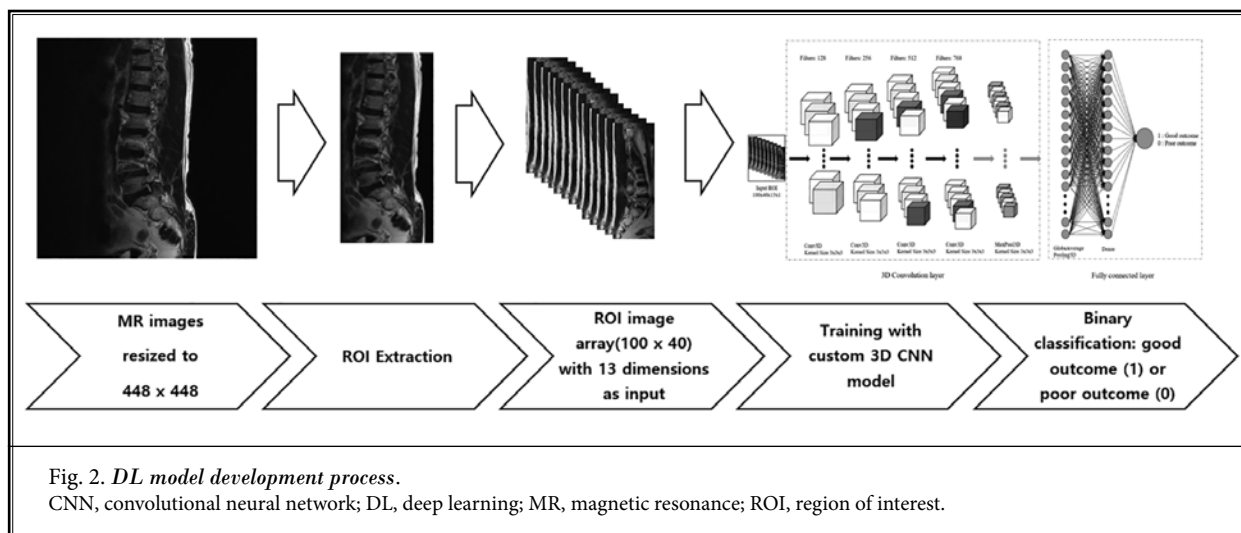
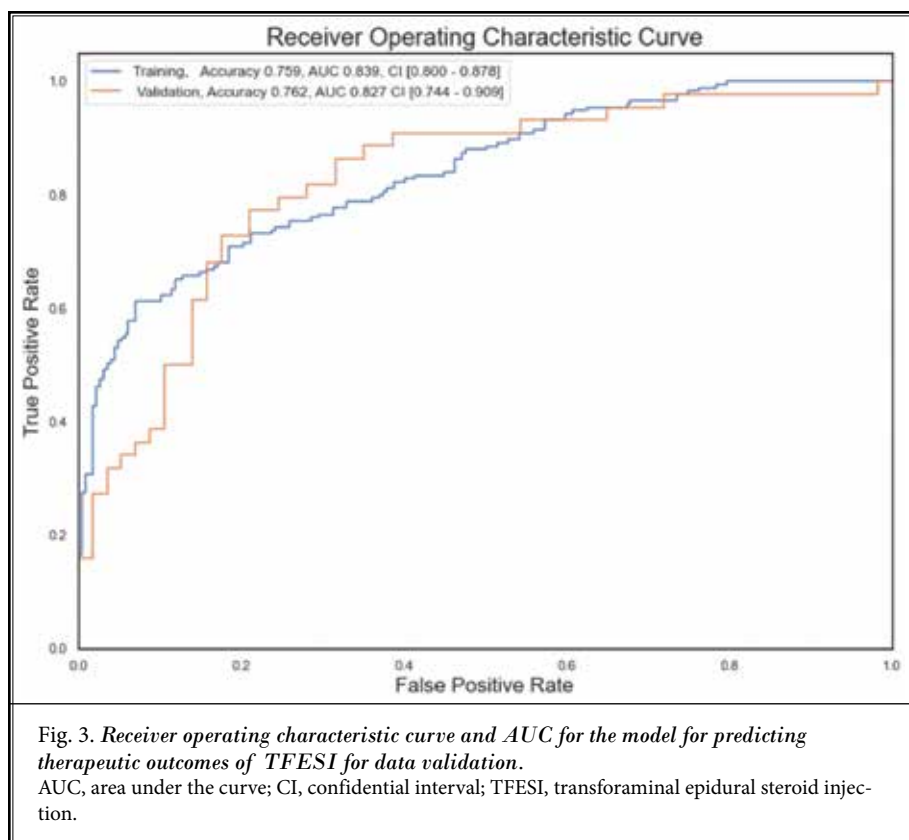


Fig. 2. DL model development process.

CNN, convolutional neural network; DL, deep learning; MR, magnetic resonance; ROI, region of interest.

input and transforms them repeatedly using convolution and pooling operations (17). Through these CNN processes, valuable features are extracted from the input data. Various features of lumbar spine MRI that can affect the therapeutic outcome, such as HLD type and size and spinal stenosis severity, would have been weighted and reflected in the development of the CNN model to determine the prognosis after TFESI (7,12-14,20). However, because of the nature of DNN, we cannot know which features of lumbar MRI were actually considered by the model for predicting the therapeutic outcome of TFESI in patients with chronic lumbosacral radicular pain.

Some previous studies (7,12-14,20) evaluated prognostic factors based on lumbar spine MRI to predict TFESI outcomes for lumbosacral radicular pain due to an HLD or spinal stenosis. Lechmann et al (13) recruited 156 patients with lumbosacral radiculopathy due to an HLD and spinal stenosis, and reported that pain reduction one month after TFESI was greater in patients with osteophyte degeneration, foraminal nerve root compression, or foraminal or extraforaminal HLD. Lee et al (14) evaluated 149 patients who received TFESI due to an HLD, and reported that foraminal or extraforaminal HLD showed good TFESI outcomes. Kwak et al (12) reported that patients with extruded HLD demonstrated a worse response to TFESI than those with protruded HLD. Do et al (20) reported that epidural steroid injections had a limited effect on moderate or severe lumbar central spinal stenosis. Additionally, Chang et al (7) performed TFESI in 31 patients with mild-to-moderate lumbar foraminal stenosis and in 26 patients with severe lumbar foraminal stenosis. Successful pain relief ($\geq 50\%$ at 3 months after TFESI) was observed in 87.1% and 42.3% of cases of mild-to-moderate and severe lumbar foraminal stenosis, respectively. These previous studies (7,12-14,20) classified patients according to



lumbar spine MRI findings and performed intergroup comparisons using traditional statistical analysis. To our knowledge, our study is the first to show the possibility of using DL algorithms trained using MR images to predict therapeutic outcomes of TFESI for chronic lumbosacral radicular pain.

CONCLUSIONS

We showed that a CNN model trained, using T2-weighted lumbar spinal sagittal MR images, could be helpful for determining therapeutic outcomes after TFESI for chronic lumbosacral radicular pain. Our study was limited in that we used a small amount of lumbar spine MRI data to train the CNN model. We believe that if a larger amount of input MRI data were used, the accuracy of the model would be further increased. In addition, if a CNN model was developed using learning of sagittal and axial MR images, its accuracy in predicting outcomes of TFESI in patients with chronic lumbosacral radicular pain would be enhanced. We also believe that developing a CNN model that integrates lumbar spine MR images, and patients' clinical data would further increase its accuracy.

REFERENCES

1. Lee DG, Cho YW, Ahn SH, Chang MC. The effect of bipolar pulsed radiofrequency treatment on chronic lumbosacral radicular pain refractory to monopolar pulsed radiofrequency treatment. *Pain Physician* 2018; 21:E97-E103.
2. Van Boxem K, Cheng J, Patijn J, et al. 11. Lumbosacral radicular pain. *Pain Pract* 2010; 10:339-358.
3. Govind J. Lumbar radicular pain. *Aust Fam Physician* 2004; 33:409-412.
4. Hadi MA, McHugh GA, Closs SJ. Impact of chronic pain on patients' quality of life: A comparative mixed-methods study. *J Patient Exp* 2019; 6:133-141.
5. Chang MC. Conservative treatments frequently used for chronic pain patients in clinical practice: A literature review. *Cureus* 2020; 12:e9934.
6. Celenlioglu AE, Sencan S, Bilim S, Sancar M, Gunduz OH. Comparison of caudal versus transforaminal epidural steroid injection in post lumbar surgery syndrome after single-level discectomy: A prospective, randomized trial. *Pain Physician* 2022; 25:161-169.
7. Chang MC, Lee DG. Outcome of transforaminal epidural steroid injection according to the severity of lumbar foraminal spinal stenosis. *Pain Physician* 2018; 21:67-72.
8. Lipetz J, Zelinger P, Kline M, Chahine N, Bloom O. Lumbar radicular pain response to first injection with non-particulate steroid. *Cureus* 2020; 12:e7104.
9. Akuthota V, Lento P, Sowa G. Pathogenesis of lumbar spinal stenosis pain: Why does an asymptomatic stenotic patient flare? *Phys Med Rehabil Clin N Am* 2003; 14:17-28.
10. Johansson A, Hao J, Sjölund B. Local corticosteroid application blocks transmission in normal nociceptive C-fibres. *Acta Anaesthesiol Scand* 1990; 34:335-338.
11. Li JY, Xie W, Strong JA, Guo QL, Zhang JM. Mechanical hypersensitivity, sympathetic sprouting, and glial activation are attenuated by local injection of corticosteroid near the lumbar ganglion in a rat model of neuropathic pain. *Reg Anesth Pain Med* 2011; 36:56-62.
12. Kwak S, Jang SH, Chang MC. Long-Term outcomes of transforaminal epidural steroid injection in patients with lumbosacral radicular pain according to the location, type, and size of herniated lumbar disc. *Pain Pract* 2021; 21:836-842.
13. Lechmann M, Roskopf A, Ehrmann C, Sutter R, Pfirrmann CWA, Peterson CK. Relationship of specific MRI findings to treatment outcomes in patients receiving transforaminal epidural steroid injections. *Skeletal Radiol* 2016; 45:1677-1685.
14. Lee JW, Choi SW, Park SH, Lee GY, Kang HS. MR-Based outcome predictors of lumbar transforaminal epidural steroid injection for lumbar radiculopathy caused by herniated intervertebral disc. *Eur Radiol* 2013; 23:205-211.
15. Deo RC. Machine learning in medicine. *Circulation* 2015; 132:1920-1930.
16. Kim JK, Choo YJ, Shin H, Choi GS, Chang MC. Prediction of ambulatory outcome in patients with corona radiata infarction using deep learning. *Sci Rep* 2021; 11:7989.
17. Yamashita R, Nishio M, Do RKG, Togashi K. Convolutional neural networks: An overview and application in radiology. *Insights Imaging* 2018; 9:611-629.
18. DeLong ER, DeLong DM, Clarke-Pearson DL. Comparing the areas under two or more correlated receiver operating characteristic curves: A nonparametric approach. *Biometrics* 1988; 44:837-845.
19. Abiodun OI, Jantan A, Omolara AE, Dada KV, Mohamed NA, Arshad H. State-Of-The-Art in artificial neural network applications: A survey. *Heliyon* 2018; 4:e00938.
20. Do KH, Kim TH, Chang MC. Effects of interlaminar epidural steroid injection in patients with moderate to severe lumbar central spinal stenosis: A prospective study. *Ann Palliat Med* 2020; 9:163-168.