

Randomized Controlled Trial

Transforaminal Versus Interlaminar Approach of Full-Endoscopic Lumbar Discectomy Under Local Anesthesia for L5/S1 Disc Herniation: A Randomized Controlled Trial

Zhiheng Chen, MD¹, Xin Wang, MD¹, Xiaoyan Cui, RN, BN², Guowang Zhang, MD¹, Jianguang Xu, MD¹, and Xiaofeng Lian, MD¹

From: ¹The Department of Orthopedics, Shanghai Jiao Tong University Affiliated Sixth People's Hospital, Shanghai, China; ²The Department of Operating Nursing, Shanghai Jiao Tong University Affiliated Sixth People's Hospital, Shanghai, China

Address Correspondence: Xiaofeng Lian, MD
Department of Orthopedics
Shanghai Jiao Tong University
Affiliated Sixth People's Hospital
Shanghai, China
E-mail: xf909@126.com

Disclaimer: This study was funded by Clinical Trial Project of Shanghai Sixth People's Hospital (yhg202003).

Conflict of interest: Each author certifies that he or she, or a member of his or her immediate family, has no commercial association (i.e., consultancies, stock ownership, equity interest, patent/licensing arrangements, etc.) that might pose a conflict of interest in connection with the submitted manuscript.

Manuscript received: 05-08-2022
Revised manuscript received: 08-04-2022
Accepted for publication: 08-29-2022

Free full manuscript:
www.painphysicianjournal.com

Background: Local anesthesia is feasible for both transforaminal and interlaminar approaches in percutaneous endoscopic lumbar discectomy (PELD). However, the optimal approach for PELD has not yet been established at the L5/S1 segment under local anesthesia with 1% lidocaine.

Objectives: In this study, we compared the transforaminal approach with the interlaminar approach of PELD under local anesthesia for L5/S1 disc herniation (DH).

Study Design: This was a prospective randomized clinical trial.

Methods: From January 2019 to March 2020, 91 consecutive patients with L5/S1 DH who planned to undergo PELD in our unit were randomized to the transforaminal endoscopic lumbar discectomy (TELD, n = 46) or interlaminar endoscopic lumbar discectomy (IELD, n = 45). Both procedures were performed under local anesthesia with 1% lidocaine. The clinical outcomes were assessed as the Visual Analog Scale (VAS) score, Oswestry Disability Index (ODI) score, and modified MacNab criteria. Patient satisfaction surveys and surgical complications were also recorded and analyzed.

Results: Compared to the IELD group, the TELD group had a shorter operative time and postoperative bed rest time ($P < 0.001$) but a longer radiation time ($P < 0.001$) and lower VAS scores for intraoperative back pain ($P < 0.001$) and leg pain ($P < 0.001$). At the postoperative follow-up, there were no significant differences between the 2 groups in the VAS scores, ODI scores, or modified MacNab criteria. The surveys showed a significantly higher satisfaction rate in the TELD group than in the IELD group ($P = 0.014$). Six patients in the IELD group (13.3%) needed extra intravenous injections of sufentanil because of intense pain during the procedure. In the IELD group, there were 2 cases of neuropathic pain after surgery.

Limitations: Due to the study was included in a single spine center with a relatively small population and its relatively short-term follow-up, the study is not generalizable.

Conclusions: Both TELD and IELD can provide good clinical outcomes for L5/S1 DH under local anesthesia with 1% lidocaine. TELD was superior to IELD in terms of surgical-related experience and complications.

Key words: Lumbar disc herniation, L5/S1, transforaminal endoscopic lumbar discectomy, interlaminar endoscopic lumbar discectomy, local anesthesia, 1% lidocaine, low concentration, endoscopic spinal surgery, percutaneous endoscopic lumbar discectomy, intraoperative pain

Pain Physician 2022; 25:E1191-E1198

Percutaneous endoscopic lumbar discectomy (PELD), which includes transforaminal endoscopic lumbar discectomy (TELD) and interlaminar endoscopic lumbar discectomy (IELD), has been widely used in the surgical treatment of lumbar disc herniation (LDH) (1-3). For the L5/S1 segment, IELD is preferred due to anatomic characteristics, such as a wider interlaminar space (4-6). However, in a meta-analysis (7), the authors found that TELD had comparable clinical outcomes and safety compared with IELD. However, IELD was superior to TELD regarding radiation times and operative time. Therefore, the authors stated that IELD might be a better surgical procedure for L5/S1 DH (7).

General anesthesia is routinely recommended for the IELD procedure because of the intraoperative pain resulting from cutting the ligamentum flavum and manipulating the disc annulus fibrosus or posterior longitudinal ligament (10 and Fig. 1g). In previous comparison studies (4-6), general anesthesia was used in the IELD procedure, but local anesthesia was used in the TELD procedure, which might have resulted in an imbalance and bias of the 2 procedures. In another study (8), the same general anesthesia was adopted in both procedures for the L5/S1 segment, and the authors stated that IELD required a shorter operative time and suffered less radiation exposure than TELD.

Recently, local anesthesia has been explored and proven to be effective and safe for IELD (9,10). In a retrospective study (11), local anesthesia with sedation were both used in TELD and IELD, and 2 groups achieved similar pain relief in a one-year follow-up. In our recent clinical practice, we found that local anesthesia using 1% lidocaine was effective and safe for IELD at the L5/S1 segment. However, to our knowledge, there is little literature comparing TELD and IELD under 1% lidocaine local anesthesia for the L5/S1 segment. Therefore, the purpose of this study was to compare these 2 procedures in a prospective and randomized manner in terms of surgical-related parameters, clinical outcomes, and complications.

METHODS

Study Design and Patients

We conducted a prospective, randomized controlled study in the Sixth People's Hospital of Shanghai Jiao Tong University from January 2019 to March 2020. The study was carried out with the approval of the ethics committee of the hospital and registration to the academic board, the approval number is 2021-KY-

51(K). This study was funded by Clinical Trial Project of Shanghai Sixth People's Hospital (ynhg202003).

Patients aged 18-70 years with L5/S1 DH who planned to undergo PELD were enrolled in this study. The follow-up period will last at least 24 months. The inclusion criteria were as follows: 1) L5/S1 DH confirmed by magnetic resonance imaging (MRI) and computed tomography (CT) scans, and only one side nerve root was compressed (Figs. 1a and 1b); 2) symptoms corresponding to the L5/S1 segment, including low back or single-side lower extremity pain, sensory changes, or motor weakness; 3) failure of conservative treatment for at least 2 months; and 4) American Society of Anesthesiologists fitness grade I or II. The exclusion criteria included: 1) multiple segments of LDH in addition to L5/S1 requiring surgical treatment; 2) LDH combined with spondylolysis or instability; 3) previous spinal surgery or postoperative recurrence; 4) CT scan showing broad calcification or ossification; 5) infection of the lumbar spine; 6) foraminal or extraforaminal DH; and 7) basic diseases or comorbid conditions that precluded surgery.

Written consent to participate in this study was obtained from all patients and the recruitment of patients was completed by an independent researcher. And then every patient was given a serial number by another researcher according to the consecutive sequence of recruitment. Then, they were randomly assigned to the TELD or IELD group using computer-generated randomized codes according to the serial number. The final collection of all patients' data were done by another independent researcher and then the data were handed over to another blinded researcher for data analysis. Although patients and physicians knew which arm was assigned, outcome assessors and data analysts were ignorant of them.

Surgical Procedure

The patient was placed in the prone position on a radiolucent table for C-arm fluoroscopic guidance with genu flexion and hip flexion. Under the guidance of C-arm fluoroscopy, the skin entry point of the puncture needle was marked. Lidocaine (1%) was used for local anesthesia in both groups (Figs. 1c and 1d).

IELD

The surgical area was prepped and draped in a regular sterile fashion. Local anesthesia was performed as follows: 1% lidocaine was injected layer-by-layer into the skin, subcutaneous tissue, fasciae, muscle, upper lamina, lower lamina, and ligamentum flavum. Then,

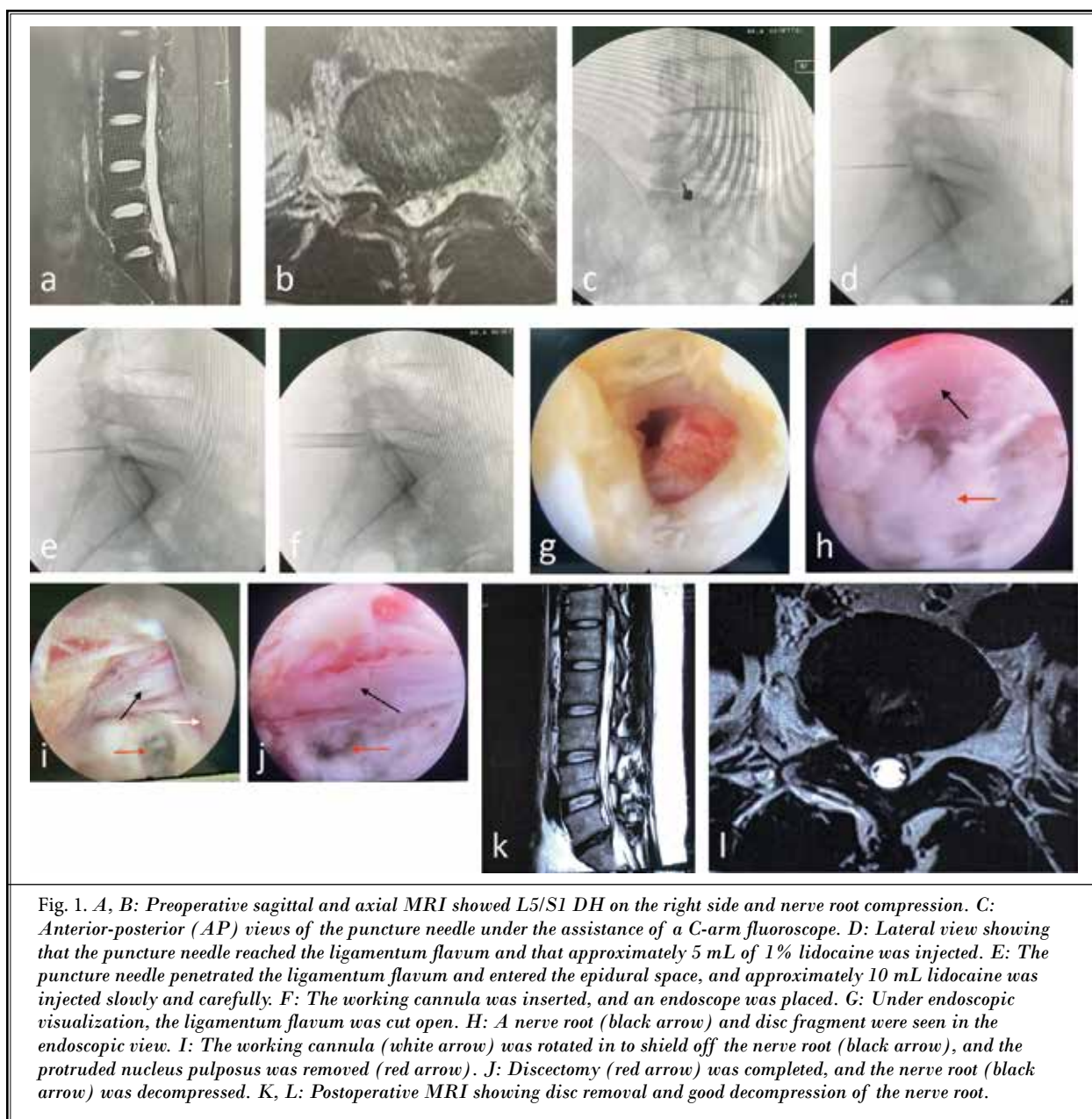


Fig. 1. *A, B: Preoperative sagittal and axial MRI showed L5/S1 DH on the right side and nerve root compression. C: Anterior-posterior (AP) views of the puncture needle under the assistance of a C-arm fluoroscope. D: Lateral view showing that the puncture needle reached the ligamentum flavum and that approximately 5 mL of 1% lidocaine was injected. E: The puncture needle penetrated the ligamentum flavum and entered the epidural space, and approximately 10 mL lidocaine was injected slowly and carefully. F: The working cannula was inserted, and an endoscope was placed. G: Under endoscopic visualization, the ligamentum flavum was cut open. H: A nerve root (black arrow) and disc fragment were seen in the endoscopic view. I: The working cannula (white arrow) was rotated in to shield off the nerve root (black arrow), and the protruded nucleus pulposus was removed (red arrow). J: Discectomy (red arrow) was completed, and the nerve root (black arrow) was decompressed. K, L: Postoperative MRI showing disc removal and good decompression of the nerve root.*

under C-arm fluoroscopy guidance, a puncture needle was used to penetrate the ligamentum flavum and enter the epidural space (Fig. 1e). At this point, approximately 10 mL of lidocaine was injected slowly and carefully. Then, routine IELD was performed. Briefly, the working cannula was inserted into the interlaminar space (Fig. 1f). Under endoscopic visualization, the lateral part of the ligamentum flavum was cut open to expose the nerve root (Fig. 1g). In the case of a narrow interlaminar window space, a portion of the upper and lower lamina

was cut using a high-speed drill. The working cannula was pushed down gently and rotated slowly to shield off the nerve root (Fig. 1i), the protruded nucleus pulposus was exposed (Fig. 1h), and routine discectomy was performed under endoscopic visualization (Fig. 1j).

TELD

Generally, the puncture needle was introduced toward the DH at 10 cm to 12 cm from the midline with an angle of approximately 30° to 45° with the horizon-

tal surface. Lidocaine (1%) was injected layer-by-layer from the skin to the extraforamen. The foramen, extraforamen, and facet joint were injected with 5 mL 1% lidocaine, respectively. Then, routine foraminotomy and discectomy were performed under endoscopic visualization (Fig. 2).

Outcome Measurements

Surgical-related parameters, such as operation time (from skin injection of lidocaine to incision closure), intraoperative radiation time, length of hospitalization, postoperative bed rest time (from the end of the surgery to the first time get up) and intraoperative pain (using the Visual Analog Scale (VAS)), were recorded (Table 1). Clinical outcome was evaluated pre- and postoperatively using the VAS, Oswestry Disability Index (ODI), and modified MacNab criteria (Tables 2 and

3). Patient satisfaction surveys recorded 3 levels as to whether they were "very satisfied," "satisfied," or "not satisfied." The rate of satisfaction was calculated as follows: (no of "very satisfied" patients + no of "satisfied" patients)/total no of patients. Patients were followed-up on day 1, 3 months, 6 months, 1 year, and 2 years after surgery. All surgical complications were recorded.

Statistical Analysis

According to Cook et al (12), we calculated that a sample population with 41 patients per group would be required to obtain 90% power to detect differences in the pain score using VAS, with a standard deviation (SD) of 2.0 ($\alpha = 0.05$ and $\beta = 0.20$). To compensate for possible loss, 120 patients were enrolled. SPSS Version 19.0 (IBM Corporation, Armonk, NY) was used for the statistical analysis. Classic t tests and chi-square tests

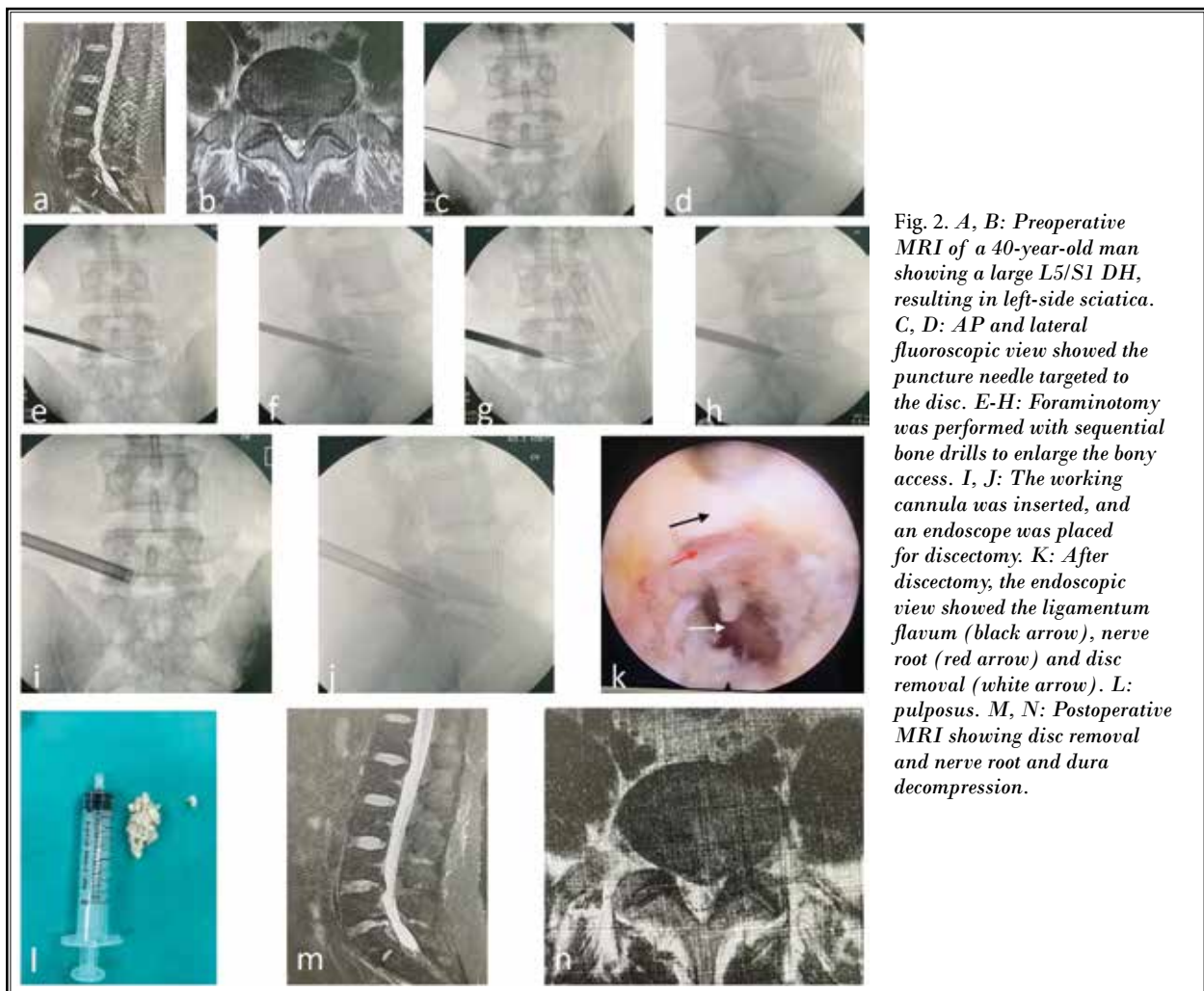


Fig. 2. A, B: Preoperative MRI of a 40-year-old man showing a large L5/S1 DH, resulting in left-side sciatica. C, D: AP and lateral fluoroscopic view showed the puncture needle targeted to the disc. E-H: Foraminotomy was performed with sequential bone drills to enlarge the bony access. I, J: The working cannula was inserted, and an endoscope was placed for discectomy. K: After discectomy, the endoscopic view showed the ligamentum flavum (black arrow), nerve root (red arrow) and disc removal (white arrow). L: pulposus. M, N: Postoperative MRI showing disc removal and nerve root and dura decompression.

were used to compare the groups. *P* values < 0.05 were considered statistically significant.

RESULTS

From January 2019 to March 2020, a total of 120 patients met the inclusion criteria. Among them, 14 patients declined participation in the study, and 3 patients had other significant health problems. Therefore, 103 patients were included in this study, of whom 53 were assigned to the TELD group and 50 to the IELD group. At the 2-year follow-up, 46 patients in the TELD group and 45 patients in the IELD group were available for complete data analysis (Fig. 3). All 91 patients were followed up for 24-38 months (mean 28.5 months). The baseline characteristics of both groups were similar (Table 1).

As shown in Table 1, the mean operative time and bed rest time in the TELD group were significantly shorter than those in the IELD group (*P* < 0.001). The intraoperative radiation time in the TELD group was significantly longer than that in the IELD group (*P* < 0.001).

All patients in both groups completed the procedure as expected. The intraoperative VAS scores of both back and leg pain in the TELD group were significantly lower than those in the IELD group (Table 1). In the IELD group, extra intravenously injected sufentanil was required in 6 patients (13.3%) because of intense intraoperative pain. In the TELD group, no intense pain or extra injection was required during surgery.

Both groups showed a significant improvement in VAS and ODI scores after surgery (Table 2). For each data collection time, the differences in VAS and ODI scores between the 2 groups were not significant (Table 2). According to the modified MacNab criteria, in the TELD group, 32 patients (69.6%) were rated excellent, 12 patients (26.1%) were rated good, and 2 patients (4.3%) were rated fine. In the IELD group, 33 patients (73.3%) were excellent, 9 patients (20.0%) were good, and 3 patients (6.7%) were fine. No cases in either group were rated as bad at the final follow-up. There was no significant difference (*P* = 0.763) between the 2 groups in the modified MacNab criteria (Table 3). For the questionnaire, in the TELD group, the rate of satisfaction was 91.3%, which was significantly higher than that in the IELD group, which was 71.1% (*P* = 0.014). There were no surgery-related complications, such as dural tears, nerve root injuries, or wound infections. Postoperative neuropathic pain occurred in 2 patients in the IELD group (4.4%) and resolved with conserva-

Table 1. Patient demographics at baseline and intraoperative parameter.

	TELD	IELD	<i>P</i> value
Total Patients	46	45	
Men/Women (no)	25/21	24/21	NS
Mean Age (y)	34.8 ± 9.1	36.2 ± 8.6	NS
Side (no)			
Left/Right	27/19	25/20	NS
DH Type			
Shoulder/Axillar	26/20	26/19	NS
Operative Time (min)	51.4 ± 15.2	62.6 ± 18.1	< 0.001
Radiation Time (s)	6.2 ± 1.8	4.7 ± 1.1	< 0.001
Hospitalization Time (d)	2.4 ± 0.8	2.5 ± 0.7	NS
Bed Rest Time (h)	3.2 ± 2.1	6.1 ± 3.4	< 0.001
VAS Score	6.8 ± 2.1	6.5 ± 2.3	NS
Intraop VAS of back	3.6 ± 1.8	4.6 ± 2.1	< 0.001
Intraop VAS of leg	3.5 ± 1.7	4.8 ± 2.2	< 0.001
ODI Score	58.7 ± 14.6	56.5 ± 15.7	NS

Data are presented as mean ± SD.

Abbreviations: TELD, transforaminal endoscopic lumbar discectomy; IELD, interlaminar endoscopic lumbar discectomy; DH, disc herniation; VAS, visual analog scale; ODI, Oswestry Disability Index; NS, not significant; SD, standard deviation.

Table 2. VAS and ODI of the 2 groups.

		TELD Group	IELD Group	<i>P</i> value
VAS	Pre-op	6.8 ± 2.1	6.5 ± 2.3	NS
	1 d post-op	2.9 ± 1.7	3.1 ± 1.6	NS
	3 mo post-op	2.0 ± 1.2	1.9 ± 1.3	NS
	Final follow-up	0.7 ± 0.7	0.8 ± 0.7	NS
ODI	Pre-op	58.7 ± 14.6	56.5 ± 15.7	NS
	1 d post-op	37.4 ± 10.8	36.9 ± 11.5	NS
	3 mo post-op	22.5 ± 8.6	23.8 ± 8.2	NS
	Final follow-up	7.2 ± 3.8	7.8 ± 3.6	NS

Values are mean ± SD

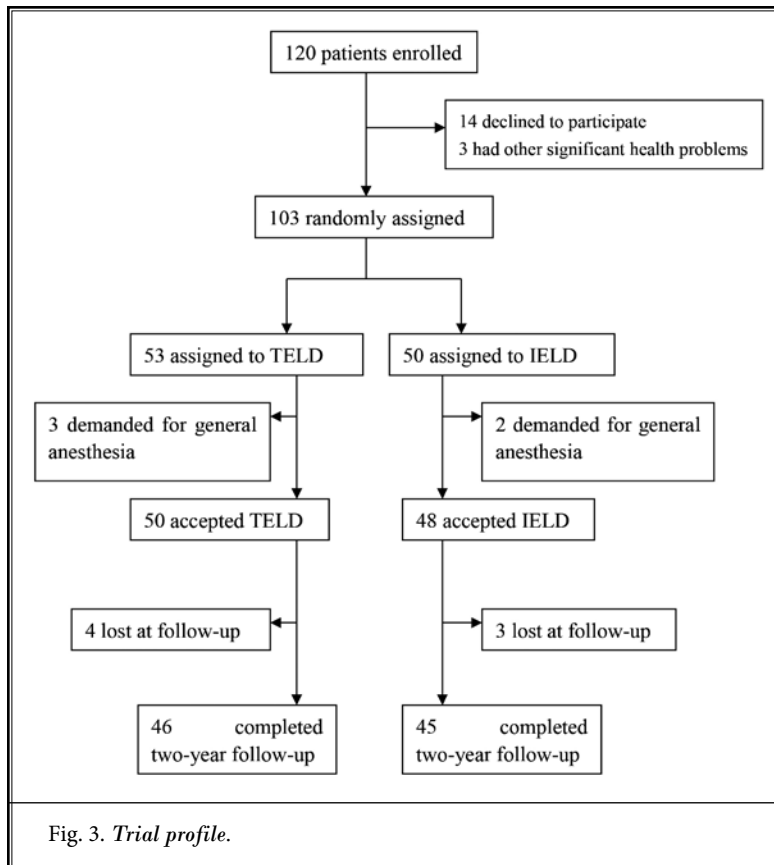
Abbreviations: VAS, visual analog scale; ODI, Oswestry Disability Index; NS, not significant; SD, standard deviation.

Table 3. Modified MacNab criteria of 2 groups.

	TELD	IELD
Excellent	32	33
Good	12	9
Fine	2	3
Excellent/Good Rate	95.7%	93.3%*

**P* = 0.763, compared with TELD group.

Abbreviations: TELD, transforaminal endoscopic lumbar discectomy; IELD, interlaminar endoscopic lumbar discectomy.



tive treatment. No recurrence of DH occurred in the 2 groups at the final follow-up.

DISCUSSION

From the results of the present study, we found that, under local anesthesia with 1% lidocaine, both TELD and IELD could yield good clinical outcomes for L5/S1 DH. However, in terms of operative time and postoperative bed time, TELD was superior to IELD. Intraoperative experience, as seen through the intraoperative VAS scores of the back and leg pain, was more comfortable in the TELD group than in the IELD group. Moreover, the rate of satisfaction was better in TELD than in IELD. Therefore, under local anesthesia, TELD was preferentially recommended for L5/S1 DH (Table 1).

In previous studies (5,6,8), IELD had a shorter operative time than TELD, which was contrary to our present study. Hua et al (8) utilized general anesthesia for both the IELD and TELD procedures. However, IELD was performed in the lateral position, while TELD was performed in the prone position. In the other 2 studies (5,6), general anesthesia was used for IELD in the prone

position, and local anesthesia was used for TELD in the prone position. None of the authors (5,6,8) specified how to calculate the operation time. In the present study, both the IELD and TELD procedures were performed in the prone position under local anesthesia. The operative time was specified from the first injection of lidocaine to the completion of incision closure. The probable reasons for the longer operative time in IELD were as follows: first, some patients required a slow and cautious cut of the ligamentum flavum to avoid intense pain. Moreover, some patients needed extra intravenously injected sufentanil due to intense intraoperative pain, which would take more time. Second, in some patients with a small interlaminar window (13), the median part of both the L5 and S1 lamina needed to be cut off with a high-speed drill, which also takes extra time.

During the interlaminar process, intolerable back and leg pain could be induced by shearing the ligamentum flavum, rotating and pushing down the working channel, and manipulating the annulus fibrosis. Therefore, in the

IELD procedure, general anesthesia is recommended and preferred by most surgeons (14,15). However, local anesthesia has recently been shown to be effective and safe for IELD (9,10,16). With local anesthesia, the patient's status could be monitored by surgeons, thus avoiding nerve root injury during surgery. In the present study, all 45 patients in the IELD group were successfully operated on as expected under local anesthesia with 1% lidocaine. In the case of intolerable pain arising intraoperatively, the procedure could be performed smoothly with extra intravenously injected sufentanil, as shown in 6 (13.3%) patients in the present study. However, intraoperative pain, depicted as the VAS score of the back and leg, was more severe in the IELD group than in the TELD group. This could be a reason for the lower satisfaction rate in the IELD group. However, more intraoperative pain did not affect the clinical outcomes in terms of the VAS score, ODI score, or modified MacNab criteria.

Due to the special anatomy at the L5/S1 segment, such as the high iliac crest, narrow intervertebral foramen, or larger facet joints, the transforaminal approach

would be challenging for endoscopic discectomy (17). With some modified techniques and well-done foraminotomy, DH at the L5/S1 segment could be accessible and removed effectively (18-21). In the present study, the skin puncture point was made more median to the midline in challenging cases, such as high iliac, and foraminotomy was performed with a reamer (Fig. 4). As a result, repeated fluoroscopy must be used to check the trajectory of the approach and increase radiation exposure to the surgeon and patient (22). As shown in the present study, the intraoperative radiation time in TELD was significantly longer than that in the IELD group.

In the present study, the foraminal and extraforaminal DH were excluded because the transforaminal approach was preferred for these types of DH; whereas, the interlaminar approach was technically challenging. For IELD, there were 2 approaches to access the herniated disc: the shoulder approach and axillar approach (23). According to the position of the protrusive disc with a compressed nerve root on axial MRI, L5/S1 DH can be divided into 3 types: axilla, shoulder, and ventral (24,25). Typically, we chose shoulder approach for shoulder type and axillar approach for axillar type. For central and ventral types of DH, we used the com-

bination of both axillar and shoulder approaches to ensure complete removal of disc fragments (Figs. 1k and 1l). As this surgical strategy was used for IELD in the present study, safe and effective clinical outcomes were achieved in the case of L5/S1 intervertebral disc resection.

CONCLUSIONS

From the present study, we concluded that, under local anesthesia with 1% lidocaine, both TELD and IELD were effective and safe for L5/S1 DH. Compared with IELD, TELD was preferred due to less operative time, postoperative bed rest time, and complications. Moreover, TELD showed less intraoperative pain and a higher postoperative satisfaction rate. The main limitation of our study is that a single spine center was included with a relatively small population and the results of the study are greatly affected by the operation of the surgeon. Therefore, the study is not generalizable. Another limitation of our study is its relatively short-term follow-up. Multicenter prospective randomized trials with more patients and long-term follow-up are required in future studies so that the result can be more generalized.

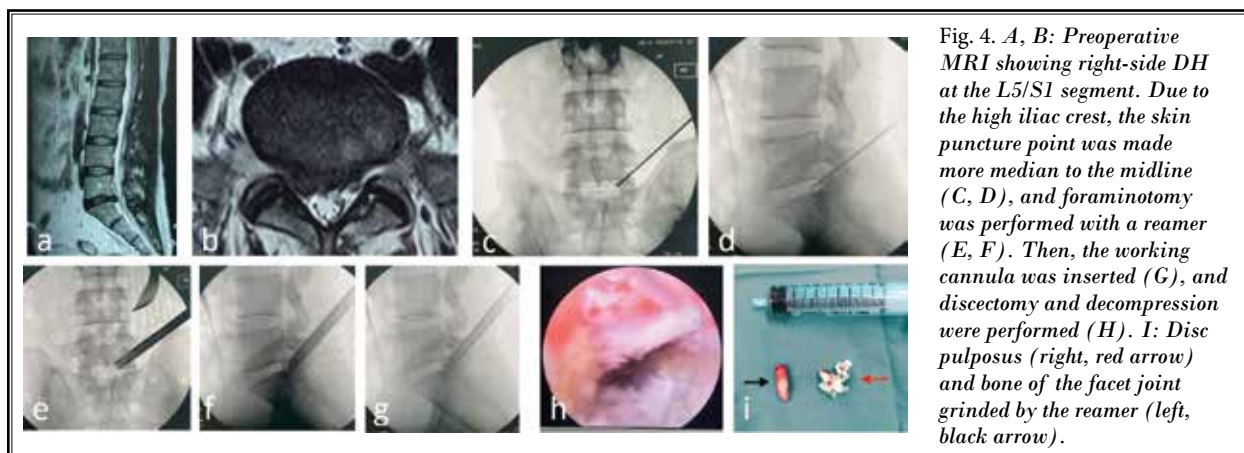


Fig. 4. A, B: Preoperative MRI showing right-side DH at the L5/S1 segment. Due to the high iliac crest, the skin puncture point was made more median to the midline (C, D), and foraminotomy was performed with a reamer (E, F). Then, the working cannula was inserted (G), and discectomy and decompression were performed (H). I: Disc pulposus (right, red arrow) and bone of the facet joint grinded by the reamer (left, black arrow).

REFERENCES

1. He DW, Xu YJ, Chen WC, et al. Meta-Analysis of the operative treatment of lumbar disc herniation via transforaminal percutaneous endoscopic discectomy versus interlaminar percutaneous endoscopic discectomy in randomized trials. *Medicine (Baltimore)* 2021; 100:e23193.
2. Li P, Yang F, Chen Y, et al. Percutaneous transforaminal endoscopic discectomy for different types of lumbar disc herniation: A retrospective study. *J Int Med Res* 2021; 49:3000605211055045.
3. Pan M, Li Q, Li S, et al. Percutaneous endoscopic lumbar discectomy: Indications and complications. *Pain Physician* 2020; 23:49-56.
4. Choi KC, Kim JS, Ryu KS, et al. Percutaneous endoscopic lumbar discectomy for L5-S1 disc herniation: Transforaminal versus interlaminar approach. *Pain Physician* 2013; 16:547-556.
5. Mo X, Shen J, Jiang W, et al.

- Percutaneous endoscopic lumbar discectomy for axillar herniation at L5-S1 via the transforaminal approach versus the interlaminar approach: A prospective clinical trial. *World Neurosurg* 2019; 125:e508-e514.
6. Nie H, Zeng J, Song Y, et al. Percutaneous endoscopic lumbar discectomy for L5-S1 disc herniation via an interlaminar approach versus a transforaminal approach: A prospective randomized controlled study with 2-year follow up. *Spine (Phila Pa 1976)* 2016; 41(suppl 19): B30-B37.
 7. Chen J, Jing X, Li C, et al. Percutaneous endoscopic lumbar discectomy for L5/S1 lumbar disc herniation using a transforaminal approach versus an interlaminar approach: A systematic review and meta-analysis. *World Neurosurg* 2018; 116:412-420.e412.
 8. Hua W, Zhang Y, Wu X, et al. Outcomes of discectomy by using full-endoscopic visualization technique via the interlaminar and transforaminal approaches in the treatment of L5-S1 disc herniation: An observational study. *Medicine (Baltimore)* 2018; 97:e13456.
 9. Feng WL, Yang JS, Wei D, et al. Gradient local anesthesia for percutaneous endoscopic interlaminar discectomy at the L5/S1 level: A feasibility study. *J Orthop Surg Res* 2020; 15:413.
 10. Ye XF, Wang S, Wu AM, et al. Comparison of the effects of general and local anesthesia in lumbar interlaminar endoscopic surgery. *Ann Palliat Med* 2020; 9:1103-1108.
 11. Jasper GP, Francisco GM, Telfeian A. Outpatient, awake, ultra-minimally invasive endoscopic treatment of lumbar disc herniations. *R I Med J* (2013) 2014; 97:47-49.
 12. Cook JA, Hislop J, Altman DG, et al. Specifying the target difference in the primary outcome for a randomised controlled trial: Guidance for researchers. *Trials* 2015; 16:12.
 13. Wu TL, Yuan JH, Jia JY, et al. Percutaneous endoscopic interlaminar discectomy via laminoplasty technique for L(5)-S(1) lumbar disc herniation with a narrow interlaminar window. *Orthop Surg* 2021; 13:825-832.
 14. Eun SS, Chachan S, Lee SH. Interlaminar percutaneous endoscopic lumbar discectomy: Rotate and retract technique. *World Neurosurg* 2018; 118:188-192.
 15. Song SK, Son S, Choi SW, et al. Comparison of the outcomes of percutaneous endoscopic interlaminar lumbar discectomy and open lumbar microdiscectomy at the L5-S1 level. *Pain Physician* 2021; 24:E467-E475.
 16. Zhang L, Chang T, Xu Y, et al. Epidural anesthesia with low concentration ropivacaine and sufentanil for percutaneous transforaminal endoscopic discectomy: A randomized controlled trial. *Front Med (Lausanne)* 2020; 7:362.
 17. Chen F, Xin J, Su C, et al. Pain variability of tissues under endoscope in percutaneous endoscopic lumbar discectomy and its significance: A retrospective study. *Pain Physician* 2021; 24:E877-E882.
 18. Liu J, Wu J, Zhang H, et al. Application of a targeted and quantificational foraminoplasty device in percutaneous transforaminal endoscopic discectomy for L5-S1 disc herniation: Preliminary clinical outcomes. *J Orthop Surg Res* 2021; 16:398.
 19. Gu YT, Cui Z, Shao HW, et al. Percutaneous transforaminal endoscopic surgery (PTES) for symptomatic lumbar disc herniation: A surgical technique, outcome, and complications in 209 consecutive cases. *J Orthop Surg Res* 2017; 12:25.
 20. Eun SS, Lee SH, Liu WC, et al. A novel preoperative trajectory evaluation method for L5-S1 transforaminal percutaneous endoscopic lumbar discectomy. *Spine J* 2018; 18:1286-1291.
 21. Jiang Y, Wang R, Chen C. Preoperative simulation of the trajectory for L5/S1 percutaneous endoscopic transforaminal discectomy: A novel approach for decision-making. *World Neurosurg* 2021; 145:77-82.
 22. Ipremburg M, Wagner R, Godschalx A, et al. Patient radiation exposure during transforaminal lumbar endoscopic spine surgery: A prospective study. *Neurosurg Focus* 2016; 40:E7.
 23. Li ZZ, Hou SX, Shang WL, et al. The strategy and early clinical outcome of full-endoscopic L5/S1 discectomy through interlaminar approach. *Clin Neurol Neurosurg* 2015; 133:40-45.
 24. Shi C, Kong W, Liao W, et al. The early clinical outcomes of a percutaneous full-endoscopic interlaminar approach via a surrounding nerve root discectomy operative route for the treatment of ventral-T type lumbar disc herniation. *Biomed Res Int* 2018; 2018:9157089.
 25. Kong W, Chen T, Ye S, et al. Treatment of L5 - S1 intervertebral disc herniation with posterior percutaneous full-endoscopic discectomy by grafting tubes at various positions via an interlaminar approach. *BMC Surg* 2019; 19:124.