

Prospective Study

# Comparison of Two Puncture Approaches in CT-guided Percutaneous Radiofrequency Ablation at the Stylomastoid Foramen for Treatment of Hemifacial Spasm

Huidan Lin, MD<sup>1</sup>, Gang Cao<sup>1</sup>, MD, Zhaodong Yang, MD<sup>1</sup>, Dan Wu, MD<sup>3</sup>, Ming Yao, PhD<sup>2</sup>, Guanjun Jin<sup>1</sup>, MD, Xindan Du, MD<sup>4</sup>, Changshun Huang, MD<sup>1</sup>, and Bing Huang, MD<sup>2</sup>

From: <sup>1</sup>Department of Pain Medicine, The First Hospital of Ningbo, Zhejiang province, China; <sup>2</sup>Department of Pain Medicine, The Affiliated Hospital of Jiaxing University, Jiaxing, Zhejiang province, China; <sup>3</sup>Department of Pain Medicine, The Central Hospital of Lishui, Lishui, Zhejiang province, China; <sup>4</sup>Department of Pain Medicine, Hangzhou Red Cross Hospital, Hangzhou, Zhejiang province, China

Address Correspondence: Bing Huang, MD  
Department of Anesthesiology and Pain Medical Center  
First Affiliated Hospital of Jiaxing University  
1882 Zhonghuan South Road  
Jiaxing 314001, China  
Email: 47485950@qq.com or jxhb999@sina.com

Joint-corresponding author: Changshun Huang, MD  
Department of Anesthesiology and Pain Medical Center, First Affiliated Hospital of Ningbo University, 59 Liuting Road, 315000 Ningbo, China  
E-mail: nbhcs1967@163.com

Disclaimer: This work was supported by Zhejiang social public welfare research and development project (GF20H090021: Radiofrequency treatment of hemifacial spasm by per-cutaneous puncture of stylomastoid foramen under CT guidance); Key Discipline Established by Zhejiang Province and Jiaxing City Jointly --Pain Medicine (2019-ss-ttyx); 2020 General Project of Agriculture and Social Development of Hangzhou city (20201203B173).

**Background:** Hemifacial spasm (HFS) is mainly characterized by paroxysmal involuntary twitches of one side of the facial muscles. We developed an awake CT-guided percutaneous puncture of the stylomastoid foramen for radiofrequency ablation (RFA) therapy for the treatment of hemifacial spasm and successfully used it in our clinic.

**Objective:** We aimed to compare anterior or posterior mastoid approaches in CT-guided percutaneous RFA at the stylomastoid foramen for the treatment of HFS.

**Study Design:** Prospective, clinical research study.

**Setting:** Department of Anesthesiology and Pain Medical Center, Ningbo, China.

**Methods:** Sixty-eight patients with HFS were recruited. They were divided into 2 groups: anterior mastoid approach and posterior mastoid approach. With the patient were under minimal sedation, a radiofrequency needle was used to reach the stylo-mastoid foramen on the affected side by an anterior approach or posterior approach; the facial nerve was localized using a low-frequency stimulation current. Ablation stopped when the patient's hemifacial contracture resolved. The puncture depth, angle, intraoperative and postoperative complications, and the short-term and long-term efficacy of the 2 puncture approaches were recorded.

**Results:** The HFS disappeared completely in 37 and 24 cases of the anterior and posterior group, but cases of both groups exhibited a House-Brackmann Facial Paralysis Scale Grade II or Grade III. During one-24 months of follow-up, 5 cases and 3 cases recurred respectively in the two groups. After 6 months of follow-up, the facial paralysis symptoms of patients in both groups disappeared.

**Conclusion:** There was no difference in the operation time or efficacy between the 2 approaches. The anterior mastoid approach is easier to perform and is recommended based on our experience.

**Key words:** Hemifacial spasm, radiofrequency ablation, stylomastoid foramen

**Pain Physician 2022; 25:E1063-E1071**

Conflict of interest: Each author certifies that he or she, or a member of his or her immediate family, has no commercial association (i.e., consultancies, stock ownership, equity interest, patent/licensing arrangements, etc.) that might pose a conflict of interest in connection with the submitted manuscript.

Manuscript received: 01-06-2022

Revised manuscript received: 05-30-2022

Accepted for publication: 05-16-2022

Free full manuscript:

www.painphysicianjournal.com

**H**emifacial spasm (HFS) is mainly characterized by paroxysmal involuntary twitches of one side of the facial muscles (1,2). There are many inconveniences in the daily lives of people with HFS, such as the eye on the affected side is difficult to open and the angulus oris is skewed. In more severe cases, the platysma muscle is involved. Unfortunately, the treatment options for HFS are limited. The most common of these therapies is to inject botulinum toxin into the facial muscles locally, which can lead to anesias of facial spasms for 2 to 4 months (3).

Microvascular decompression (MVD) is a classic surgical technique for the treatment of HFS (4-6). However, MVD requires it to be done under general anesthesia, which may not be tolerable for high-risk patients; the operation-related mortality rate is as high as 0.5% - 1% (7-9). Therefore, we developed an awake computed tomography (CT)-guided percutaneous puncture of the stylomastoid foramen radiofrequency ablation (RFA) therapy for the treatment of hemifacial spasm and successfully used it in the clinic (10,11). This procedure can provide sustained relief from symptoms for patients who have HFS, and it is a viable alternative to MVD for those who are poor surgical candidates, such as those without underlying vascular compression etiology or those who cannot tolerate general anesthesia. However, it was found in the clinical application that both anterior and posterior approaches under CT guidance could reach the stylomastoid foramen. Therefore, this study compared the differences and clinical efficacy between the 2 approaches in percutaneous RFA for HFS treatment.

## METHODS

### Patients

#### *Inclusion Criteria*

Patients with HFS who came to the pain department of the author from August 2018 through August 2020 and met the diagnostic criteria of HFS.

#### *Exclusion Criteria*

Patients with cerebellopontine lesions; patients with hemophilia or other coagulopathy; patients with mental disorders who could not complete intraoperative tympanic cheek closure; women who are pregnant or preparing for pregnancy who are not suitable for CT examination; patients with a cardiac pacemaker or defibrillator implants; those who were not willing to accept this technique.

This study was approved by the Ethics Committee of the Institutional Review Board of the Ningbo and Jiaxing First Hospital. All patients and their families were informed of the treatment process and possible complications before the operation. All enrolled patients signed an informed consent form.

### Operation Method and Grouping

#### *Puncture Path Design*

After fasting for 4-6 hours before surgery, the patients were changed into a sterile surgical gown, and a trocar was placed in the forearm vein. The patient was instructed to lie on the CT table on the healthy side and CT positioning grids were placed anterior or posterior to the patient's ear (Fig. 1). The head positioning and the mastoid region were scanned in 3 mm layers by using a maxillofacial CT scanning protocol. (Fig. 2). The stylomastoid foramen was identified on the image sequence as the puncture target, and the CT measurement tool software was used to draw a straight line from the target to the skin in front of the mastoid (anterior mastoid approach) or along the mastoid skull groove from the target point to the skin behind the mastoid (posterior mastoid approach). The intersection of the straight line and the skin was the puncture point. If there was no bone block in the 2 approaches, one approach was arbitrarily chosen.

The distance between the puncture point and the target point (puncture depth) and the angle between the puncture route and the sagittal plane (puncture angle) were measured with a software ruler (Fig. 3 and Fig. 4).

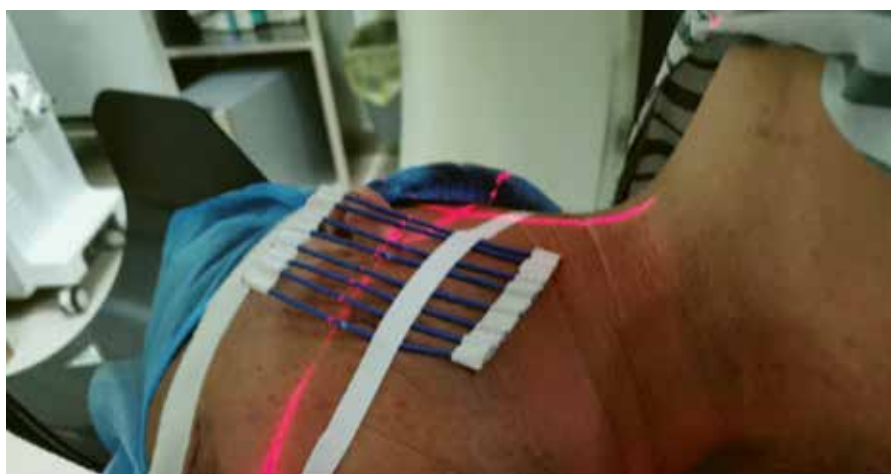

Fig. 1. *Computed tomography image of a positioning grid placed in the lateral decubitus position (the handmade positioning grid was cut off by the interventional catheter and placed longitudinally either anterior or posterior to the earlobe).*




Fig. 2. *An axial scanning frame of the mastoid region by computed tomography.*

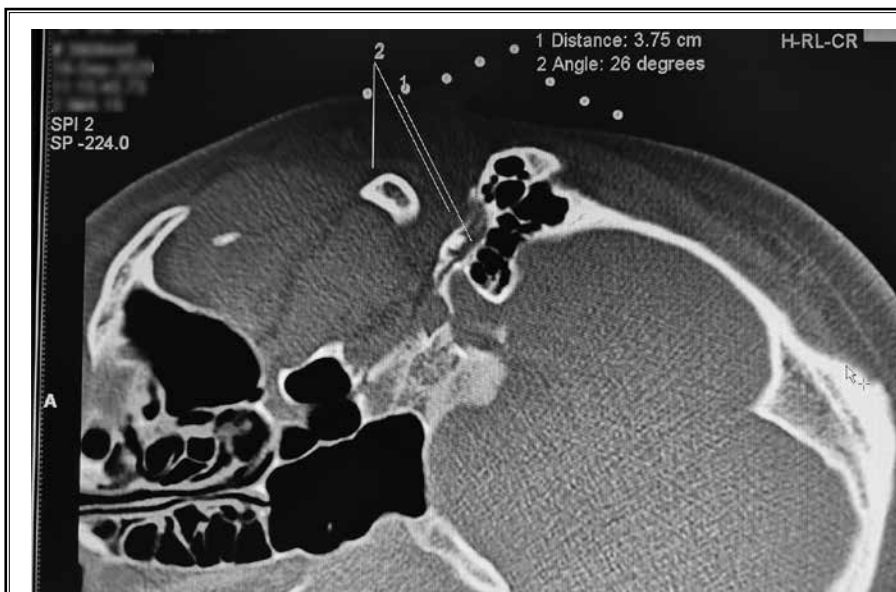


Fig. 3. *An example of the puncture path design through the anterior approach (puncture depth 3.75 cm, puncture angle [angle within the sagittal plane] 26°).*

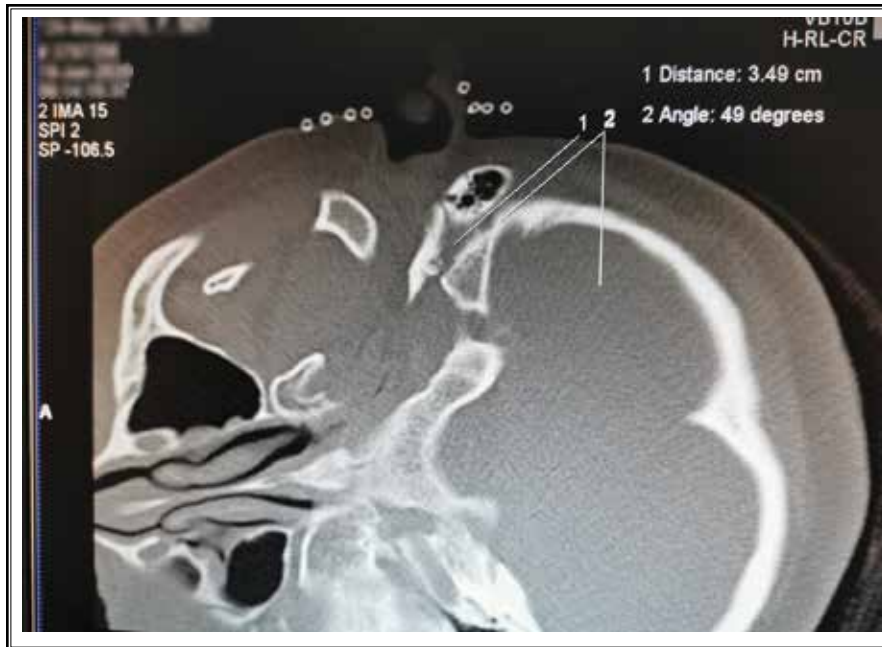

Fig. 4. An example of the puncture path design through the posterior approach (puncture depth 3.49 cm, puncture angle 49°).

### Stimulation Test

Local anesthetic was injected subcutaneously at the needle insertion site with 2% lidocaine, and a stylet 21G RF needle (model 240100, Englander Medical Technology Co., Ltd.) was slowly advanced toward the target under intermittent CT guidance (Figs. 5 and 6) and confirmed by CT scan with 3D reconstruction observation (Figs. 7 and 8). After that, An RF probe was then introduced and a low frequency (2 Hz) current of the RF instrument (model pmg230, Baylis Medical) was applied to stimulate the facial nerve. If the current stimulation falls below 0.8 mA, it can induce rhythmic facial muscle twitches, showing that the facial nerve was in the proximity. Otherwise, the angle and the depth of the RF needle was adjusted until facial muscle twitches were observed.

### Radiofrequency Ablation

Continuous RF was given after the stimulation test. The initial RF temperature was 60°C for 30 seconds. During the process of RFA, the patient was instructed to keep his eyes closed and cheeks bulged. The RF wave dosage was gradually increased by a 5°C increment in 30-second intervals (up to 90°C). Once the air leakage of the affected side's cheek and eye closure was not tight, the RFA was terminated immediately. If the radiofrequency could not achieve the therapeutic effect at 90°C for 30 seconds, the needle tip was adjusted again or the puncture path changed before testing and RFA. At the end of the treatment, the temperature, the operation

time (the time from the beginning of CT scanning to the end of RF treatment), the puncture angle, and the depth were recorded.

### Efficacy Evaluation and Follow-up Observation

The curative effect of hemifacial spasm was evaluated on the second day after treatment. If the involuntary twitch of the facial muscles disappeared completely, the therapeutic effect was determined to be a cure. If the degree of involuntary twitch of the facial muscles was weaker than that before the operation, the therapeutic effect was considered a relief. If the symptoms of facial twitch were the same as before treatment, the therapeutic effect was considered invalid. If the muscle spasms disappeared more than a week after the operation, but the hemifacial spasm occurred again, it was considered a recurrence.

After the operation, we observed whether there was a hematoma after the puncture, and asked the patient whether there was facial pain, tinnitus, or hearing loss. The degree of facial paralysis was recorded according to the House-Brackmann Facial Paralysis Scale (Grade I normal without facial paralysis, Grade II paraplegia, Grade III moderate palsy, Grade IV moderate-severe paralysis, Grade V severe paralysis, Grade VI total paralysis) (12). A follow-up database was established for all patients. The efficacy and complications were followed up monthly by telephone or WeChat video.



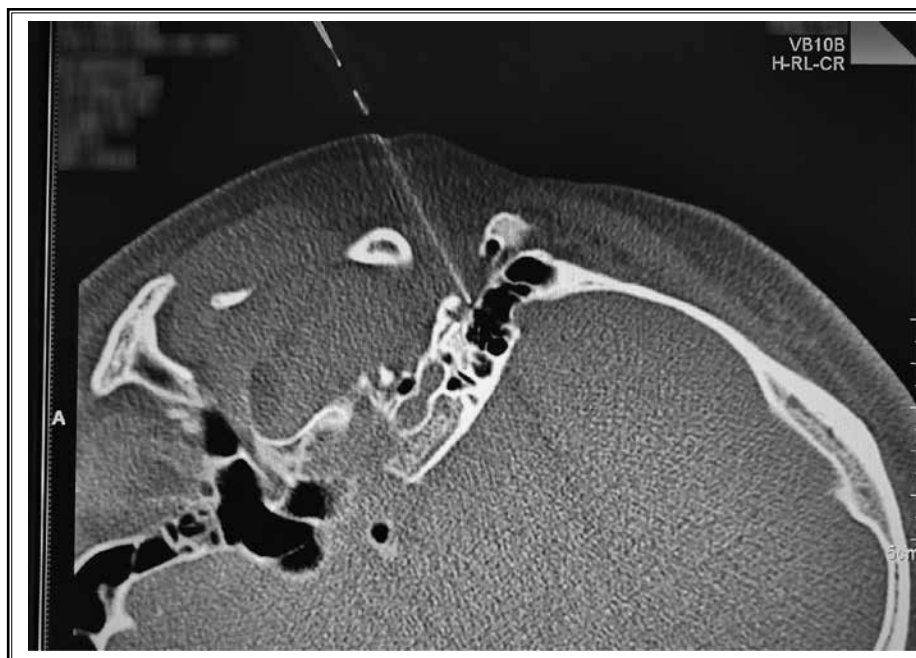

Fig. 5. *A successful puncture through the anterior approach.*

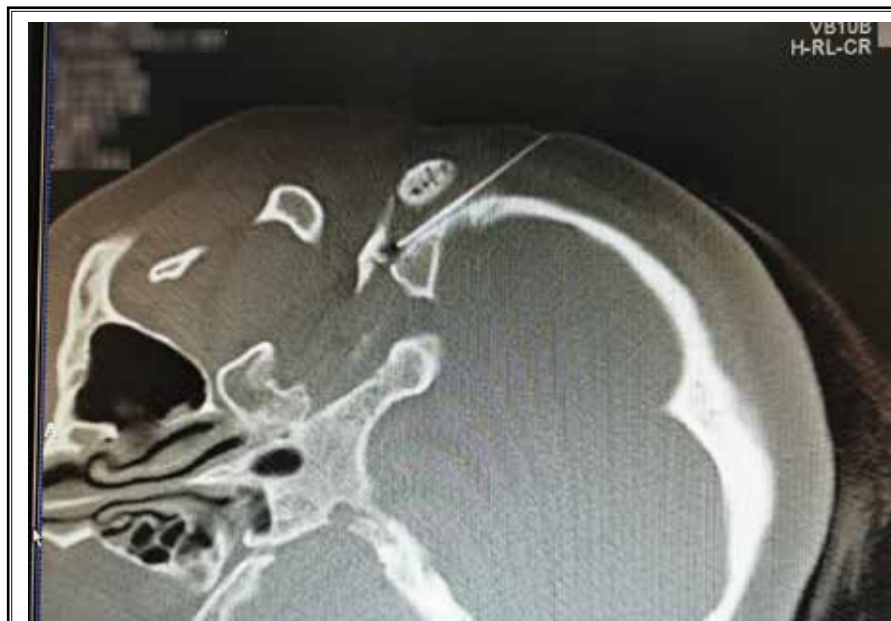

Fig. 6. *A successful puncture through the posterior approach.*

### Data and Statistical Analysis

All statistical analyses were conducted using SPSS 16.0 software (IBM Corporation). Data are presented as mean  $\pm$  standard deviation ( $x \pm s$ ). Analysis of variance was used for repeated measures. The difference in the puncture angle and depth of the approaches used a 2-sample mean t test.  $P < 0.05$  was considered statistically significant.

### RESULTS

#### General Information

During the observation period, 68 patients with HFS were enrolled in the treatment and observation group after screening according to the inclusion and exclusion criteria. The gender ratio of men to women was 21/47; age was 34-85 ( $58.7 \pm 10.6$ ) years; medical

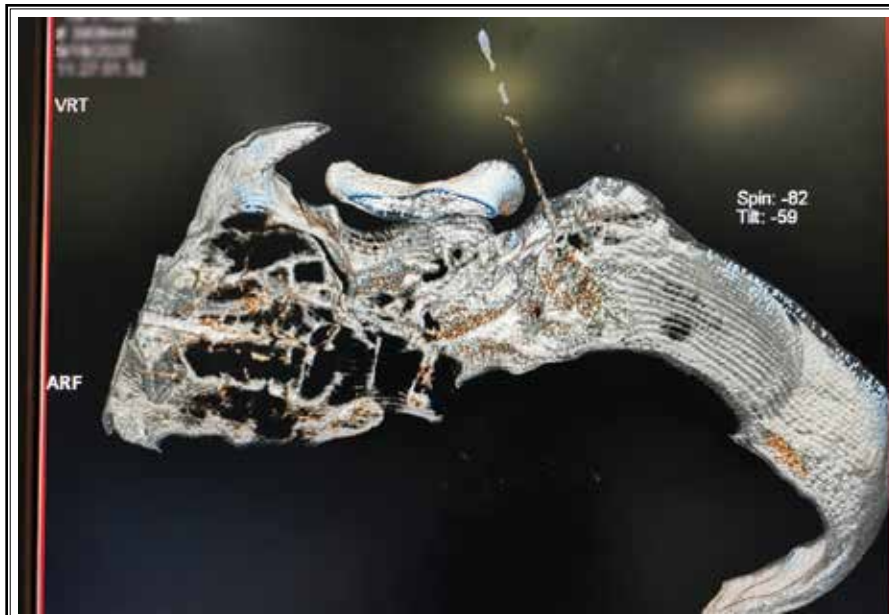


Fig. 7. Three-dimensional reconstruction of a successful puncture through the anterior approach.

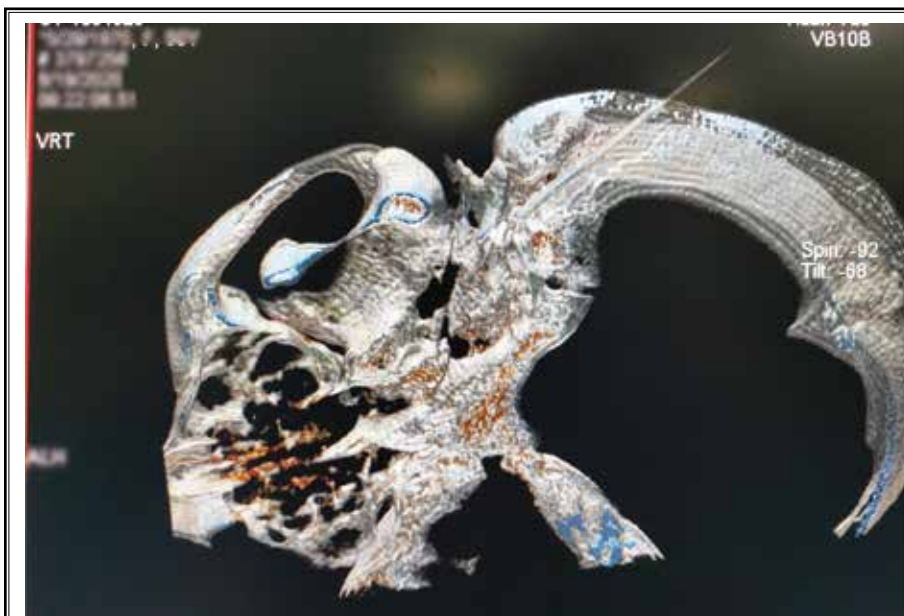

Fig. 8. Three-dimensional reconstruction of a successful puncture through the posterior approach.

history was 2-240 months, with an average of  $39.7 \pm 34.2$  months; left and right sides were 37/31. Twenty-one patients had a history of botulinum toxin local injection. Nine patients had been treated with MVD and were diagnosed because of the recurrence of HFS.

### Radiofrequency Ablation

In the present study, 41 patients were treated with an anterior approach and 27 patients with a posterior approach. The general conditions of the 2 groups are

shown in Table 1; there was no significant difference between the 2 groups. Under the CT guidance, the RF needle was punctured to the stylomastoid foramen on the affected side. The puncture depth, angle, radiofrequency temperature, radiofrequency time, and average operation time of the 2 groups are shown in Table 2. In the simulation tests, 28 patients treated with an anterior approach and 19 patients treated with a posterior approach had the same frequency twitch of the facial muscles with the first application of the test current

(0.1-0.8 mA, 2 Hz). The rest of the patients got positive test results after adjusting the needle tip position. After one radiofrequency treatment, HFS symptoms in 34 patients and 22 patients disappeared completely in the anterior and posterior groups, respectively. Seven patients in the anterior group and 5 cases in the posterior group were tested again after we adjusted the needle tip position.,

**Treatment Effects**

On the second postoperative day, 61 patients were determined to be cured, 7 had a degree of symptom relief, and no outcome was determined invalid.

In the anterior approach group, 37 patients were determined to be cured and 4 patients had a degree of symptom relief. In the posterior approach group, 24 patients were determined to be cured and 3 patients had a degree of symptom relief. However, all patients had a House-Brackmann Facial Paralysis Scale of Grade II or Grade III.

The patients were followed up for one-24 months. Among them, 11 were followed up within 3 months, 10 were followed up for 4-6 months, 22 were followed up for 7-12 months, and 25 were followed up for 13-24 months. During follow-up, 5 patients in the anterior group and 3 patients in the posterior group had a recurrence. In the anterior group, patients recurred at 7, 9, 9, 13, and 15 months after the operation. In the posterior group, patients recurred at 9, 11, and 14 months. Four patients from the anterior group received RFA again and the second therapies were effective. Four patients from the anterior group and 3 patients from the posterior group had transient mild to moderate auriculotemporal region pain, which lasted for a week. No patients had any facial hematoma, intracranial hemorrhage, infection, hearing impairment, or other complications. The degree of facial paralysis began to decrease in the second month after the operation. All patients who were followed up for more than 6 months recovered from facial paralysis.

**DISCUSSION**

Although the pathogenesis of HFS is not completely understood, the microvascular compression theory proposed by Jannetta et al (4) has been generally accepted. Although MVD is considered safe and effective with good microsurgical techniques, it risks serious complications (13-15).

A major postoperative complication of RFA for the facial nerve is mild to moderate facial paralysis occurring immediately after the procedure. In order to reduce the occurrence of severe facial paralysis complications, we have developed a set of strictoperation procedures based on our previous study (16). Briefly, to control partial damage of facial nerve function, we determined the initial temperature and time parameters of RFA according to electrophysiological tests.

In the previous study, we found that, for the primary trigeminal neuralgia caused by vascular compression of the trigeminal nerve root, extracranial RF thermocoagulation of a nonsemilunar ganglion can effectively treat trigeminal neuralgia as well as MVD does (17-21). Therefore, we proposed that facial nerve RFA through the extracranial stylomastoid foramen could also treat HFS, and successfully developed the approach. We found that the only complication related to RFA at the stylomastoid foramen is mild facial pa-

Table 1. *The gender, age, affected side, and time course of the 2 groups.*

Group	Gender (M/W)	Age	Affected Side (L/R)	Course of Disease
Anterior approach	12/29	59.5±11.5	20/21	43.3±39.4
Posterior approach	9/18	57.52±9.3	11/16	34.3±24.1
t value/X <sup>2</sup>	0.126	0.747	1.32	1.071
P value	0.723	0.458	0.251	0.228

Note: There was no significant difference between the 2 groups.

Table 2. *The puncture depth, angle, radiofrequency temperature, radiofrequency time, and average operation time of the 2 groups.*

Group	Puncture depth (cm)	Puncture angle (degree)	Stimulation intensity (mA)	Radiofrequency temperature (°C)	Radiofrequency temperature (S)	Average operation time (min)
Anterior approach	3.63±0.40	21.0±8.36	0.50±0.17	78.0±9.8	24.2±6.36	31.44±5.95
Posterior approach	4.27±0.54	61.3±7.73	0.41±0.15	76.7±8.86	22.16.76	33.22±10.81
t value	5.616	20.514	2.15	0.595	1.274	0.783
P value	<0.001	<0.001	0.035	0.554	0.207	0.439

Note: There were significant differences in puncture depth and angle between the 2 approaches.

ralysis, which is safer than MVD surgery, especially for elderly patients who cannot tolerate craniotomy under general anesthesia. Moreover, HFS treatment by RFA at the stylomastoid foramen not only greatly reduces the economic burden for patients, but also saves more medical and health resources.

We found that there are 2 approaches to the stylomastoid foramen. The facial nerve enters the facial nerve canal in the mastoid process from the internal auditory canal in the petrous part of the temporal bone and divides into the branches of the greater petrosal nerve, the stapes branch, and the chorda tympani branch. After the facial nerve trunk passes through the stylomastoid foramen, it divides into the temporal branch, the zygomatic branch, the buccal branch, the mandibular marginal branch, and the cervical branch to innervate the ipsilateral facial expression muscle and platysma muscle. The stylomastoid foramen is located between the styloid process root and the mastoid process and is a trumpet-shaped opening. The axial thin-layer scanning of the styloid process root shows that the diameter of the stylomastoid foramen is gradually reduced from the outside to the inside. The anterolateral orifice of the stylomastoid foramen is surrounded by the tympanic part of the temporal bone, and the posterolateral part is adjacent to the mastoid skull sulcus. Therefore, the stylomastoid foramen can be reached by crossing the tympanic part of the temporal bone through an anterior or a posterior approach.

What are the differences between the 2 approaches and how should one choose one approach over the other? We believe that because of the variation of the stylomastoid foramen and its adjacent structures, especially between the tympanic part of the temporal bone and mastoid process, the choice of puncture path is mainly based on the results of the CT scan. Once the CT section containing the outer orifice of the stylomastoid foramen is found, a straight line should be drawn forward or backward with the outer orifice of the stylomastoid foramen as the target. If the anterior approach is not obstructed by the tympanic part of the temporal bone, but the posterior approach is obstructed by the bone, the anterior mastoid approach should be chosen; otherwise, the posterior approach should be selected. When both approaches are unobstructed, either of them can be used. If both approaches are obstructed, the CT frame should be tilted 5°-15° to the end of the CT, and then scanning should be performed again to design the puncture path.

As found in the present study, the puncture site of the anterior approach is generally located on the skin near the earlobe where no hair grows; while the puncture point of the posterior mastoid approach is mostly in the hairline, which needs shaving and skin preparation. Moreover, the puncture depth of the anterior mastoid approach is shallower, and the angle between the puncture needle and the sagittal plane is smaller. Therefore, the anterior approach is more easily selected when puncturing through the stylomastoid foramen. However, there is a facial artery passing close to the mandibular angle which should be avoided when the anterior approach is chosen.

The posterior mastoid approach also has advantages. Because the puncture path is in the gap between the mastoid and occipital bone, the needle can only be inserted along the suture, which can avoid the needle from deviating from the puncture path designed before the operation (the skull or mastoid on both sides will block the puncture needle so that it does not deviate), making the puncture operation easier to reach the target point.

## CONCLUSION

In conclusion, the puncture approach should be designed based on the individual characteristics of the stylomastoid foramen structure and the CT scanning images. If the tympanic part of the temporal bone is large, it will block the anterior mastoid approach, so the posterior mastoid approach should be selected. Otherwise, it is more convenient to choose the anterior mastoid approach without skin preparation. It is suggested that surgeons should master both approaches so they can select the appropriate puncture approach according to the structural characteristics of a particular patient.

According to our study, the puncture needle can reach the stylomastoid foramen through both approaches; there is no significant difference in the efficacy and recurrence rate of HFS. Because of the extracranial puncture operation, there should be no intracranial injury, hemorrhage, or intracranial infection, and the treatment is convenient and safe.

Institutional review board/ethics committee approval was obtained from the Institutional Review Board of the Ningbo and Jiaying First Hospital.

## Consent for Publication

All patients consented to the submission of the study results .



## Acknowledgments

The authors want to thank members of the Department of Anesthesiology and Pain, Medical Center in Ningbo and Jiaying city for data acquisition of the 68 patients treated in the study.

## Authors' Contributions

Huidan Lin, and Bing Huang had the original idea for the manuscript and collected the data. Gang Cao,

Guanjun Jin, Zhaodong Yang, and Changshun Huang analyzed the data. Huidan Lin, Dan Wu, and Xindan Du reviewed the literature for the introduction and drafted the manuscript. Ming Yao revised the manuscript. Bing Huang assisted in drafting the manuscript, revising the text, and approving the final manuscript. All authors read and approved the final manuscript.

We would like to acknowledge Xiaowei Chen for his assistance in proofreading the manuscript.

## REFERENCES

- Rosenstengel C, Matthes M, Baldauf J, et al. Hemifacial spasm: Conservative and surgical treatment options. *DtschArztebl Int* 2012; 109:667-673.
- Chaudhry N, Srivastava A, Joshi L. Hemifacial spasm: The past, present and future. *J Neurol Sci* 2015; 356:27-31.
- Jost, WH, Laskawi, R, Palmowski-Wolfe A, et al. Therapy of hemifacial spasm with botulinum toxin. [Article in German] *Laryngorhinootologie* 2019; 98:247-251.
- Jannetta PJ, McLaughlin MR, Casey KF. Technique of microvascular decompression. *Neurosurg Focus* 2005; 18:E5-E9.
- Ghali MG, Srinivasan VM, Viswanathan A. Microvascular decompression for hemi-facial spasm. *Int Ophthalmol Clin* 2018; 58:111-121.
- Miller LE, Miller VM. Safety and effectiveness of microvascular decompression for treatment of hemifacial spasm: A systematic review. *Br J Neurosurg* 2012; 26:438-444.
- Zheng XK, Yu YB. Clinical research on hearing impairment after microvascular decompression of facial spasm. *Chin J Neurosurg* 2016; 32:1294-1296.
- Bartindale, M, Kircher, M, Adams, W, et al. Hearing loss following posterior fossa microvascular decompression: A systematic review. *Otolaryngol Head Neck Surg* 2017; 158:62-75.
- Yu YB. Efforts to improve the treatment of microvascular decompression. [Article in China] *Chin J Neurosurg* 2016; 32:325-328.
- Huang B, Yao M, Chen QL, et al. Awake CT-guided percutaneous stylomastoid foramen puncture and radiofrequency ablation of facial nerve for treatment of hemifacial spasm. *J Neurosurg* 2021;1-7.
- Huang B, Lin HD, Du XD, et al. CT-guided percutaneous puncture of stylomastoid foramen and radiofrequency ablation for treatment of primary hemifacial spasm. *Chin J Neurosurg* 2019; 18:933-938.
- Fattah AY, Gurusinge AD, Gavilan J, et al. Facial nerve grading instruments: Systematic review of the literature and suggestion for uniformity. *Plast Reconstr Surg* 2015; 135:569-579.
- Xia L, Liu MX, Zhong J, et al. Fatal complications following microvascular decompression: could it be avoided and salvaged? *Neurosurg Rev* 2017; 40:389-396.
- Amagasaki K, Takusagawa Y, Kanehashi K, et al. Supratentorial acute subdural haematoma during microvascular decompression surgery: Report of three cases. *J Surg Case Rep* 2017; 2017:rjx004.
- Bartindale M, Kircher M, Adams W, et al. Hearing loss following posterior fossa microvascular decompression: A systematic review. *Otolaryngol Head Neck Surg* 2018; 158:62-75.
- Huang B, Du XD, Huang H, et al. Treatment of hemifacial spasm by radiofrequency puncture under CT guidance. [Article in China] *Chin J Pain* 2020; 16:121-126.
- Huang B, Yao M, Feng ZY, et al. CT-guided percutaneous infrazygomatic radiofrequency neurolysis through foramen rotundum to treat V2 trigeminal neuralgia. *Pain Medicine* 2014; 15:1418-1428.
- Huang B, Yao M, Liu QY, et al. Personalized needle modification for CT-guided percutaneous infrazygomatic radiofrequency ablation of the maxillary nerve through the foramen rotundum in order to treat V2 trigeminal neuralgia. *J Pain Res* 2019; 12:2321-2329.
- Huang B, Xie KY, Chen YJ, et al. Bipolar radiofrequency ablation of mandibular branch for refractory V3 trigeminal neuralgia. *J Pain Res* 2019; 12:1465-1474.
- Lin HD, Cao G, Jin GJ, et al. Extracranial non-gasserian ganglion application of radiofrequency thermocoagulation on the mandibular branch of the trigeminal through the foramen ovale for trigeminal neuralgia. *Pain Physician* 2021; 24:E425-E432.

