

Review



# The Role of Neuromodulation in Chronic Pelvic Pain: A Review Article

Chandni B. Patel, DO<sup>1</sup>, Ankur A. Patel, DO<sup>2</sup>, and Sudhir Diwan, MD<sup>3</sup>

From: <sup>1</sup>Department of Physical Medicine and Rehabilitation, Icahn School of Medicine, Mount Sinai Hospital, New York, NY; <sup>2</sup>Department of Physical Medicine and Rehabilitation, New York-Presbyterian Hospital, Columbia University Medical Center, Weill Cornell Medical Center, New York, NY; <sup>3</sup>Advanced Spine on Park Avenue, New York, NY

Address Correspondence:  
Sudhir Diwan, MD  
Advanced Spine on Park Avenue  
115 East 57th Street, Suite 610  
New York, NY 10022, USA  
E-mail:  
sudhir.diwan63@gmail.com

Disclaimer: There was no external funding in the preparation of this manuscript.

Conflict of interest: Sudhir Diwan, MD. No conflicts of interest or financial support for this manuscript. The other authors certify that he or she, or a member of his or her immediate family, has no commercial association (i.e., consultancies, stock ownership, equity interest, patent/licensing arrangements, etc.) that might pose a conflict of interest in connection with the submitted manuscript.

Manuscript received: 08-10-2021  
Revised manuscript received: 02-03-2022  
Accepted for publication: 02-25-2022

Free full manuscript:  
[www.painphysicianjournal.com](http://www.painphysicianjournal.com)

**Background:** Chronic pelvic pain (CPP) is a complex, heterogeneous condition affecting both female and male patients with significant effects on quality of life. Chronic pelvic pain is a prevalent but often underdiagnosed condition due to the variation in patient presentation, a gap in communication among specialties, under-reporting of the syndrome, and lack of standardized diagnostic criteria with a subsequent delay in diagnosis. The mechanism of CPP is complex due to multifactorial etiologies of pain and its vast anatomy and innervation. Potential causes of pelvic pain include the nerves, muscles, bone, or organs of the reproductive, gastrointestinal, urological, musculoskeletal, vascular, neurological, and psychological systems.

**Objectives:** The objective of this article is to review the anatomy of the pelvis, share current lead placement locations, and discuss the current evidence for neuromodulation in the management of chronic pelvic pain.

**Study Design:** This is a narrative review of current literature on neuromodulation for chronic pelvic pain.

**Setting:** A database review.

**Methods:** A PubMed search was performed to gather literature on neuromodulation for chronic pelvic pain.

**Results:** Traditionally, pelvic pain has been managed with conservative therapies such as physical therapy, pharmacological agents, trigger point injections, botulinum toxin injections, ganglion impar blocks, caudal epidural steroid injections, or superior and inferior hypogastric blocks, but with the evolution of the neuromodulation, there are new advances to incorporate this modality in the management of chronic pelvic pain.

**Limitations:** This review article possesses limitations and includes published data, excluding case reports. For this reason, some applications of neuromodulation for chronic pelvic pain may be missed.

**Conclusions:** Neuromodulation may include spinal cord stimulation, dorsal root ganglion stimulation, and peripheral nerve stimulation. Specifically, neuromodulation utilizes electrical stimulation or pharmacological agents to modulate a nerve and alter pain signals. Currently used locations for lead placement include intracranial, spinal cord, dorsal root ganglion, sacral nerve roots, or at a peripheral nerve. As the field of pelvic pain continues to evolve, continued evidence for neuromodulatory interventions is needed.

**Key words:** Chronic pelvic pain, neuromodulation, peripheral nerve stimulation, dorsal root ganglion stimulation, spinal cord stimulation

**Pain Physician 2022: 25:E531-E542**

**P**elvic pain is a complex, multi-system syndrome affecting both females and males and can be identified as acute or chronic (1). Specifically, chronic pelvic pain (CPP) is defined as persistent, noncyclic pain located within the pelvic region lasting longer than 6 months (2,3). Affecting about 5% to 26% of women and 2% to 16% of males (4), CPP is a prevalent and debilitating condition (3,4,5). The wide range of prevalence exists due to the variation in patient presentation, a gap in communication among specialties, under-reporting of the syndrome, and a lack of standardized diagnostic criteria with subsequent delay in diagnosis. The mechanism of CPP is complex and dependent on etiology of pain.

Current treatments are targeted based on etiology of pelvic pain, with causes including reproductive, gastrointestinal, urological, musculoskeletal, vascular, neurological, and psychological (3). Of these, the common etiologies consist of endometriosis, pelvic inflammatory disease, pelvic adhesive disease, malignancy, irritable bowel syndrome, interstitial cystitis, and post-traumatic stress disorder (6). Oftentimes, focused physical therapy, pharmacologic agents, and nerve blocks are utilized early in the treatment algorithm. For refractory cases, the central and peripheral nervous systems may be targeted using neuromodulation. The use of neuromodulation for CPP primarily consists of spinal cord stimulation (SCS), dorsal root ganglion (DRG) stimulation, and peripheral nerve stimulation (PNS) (7). This review article will summarize the evidence of neuromodulation in the management of CPP.

## **Anatomy**

A thorough history and physical examination are required alongside a strong understanding of anatomy to differentiate between the various pain generators. Pelvic pain generators may include bones, organs, muscles, ligaments, and nerves.

### ***Pelvic Bones***

The bony pelvis is made of the 2 innominate bones and the sacrum (8). Each innominate is comprised of the ilium, ischium, and pubis (5). The sacrum is formed from 5 fused vertebrae, serving as the base of the vertebral column (8). The bones of the pelvis form 4 joints. Anteriorly, the pubic bones join to form the pubis symphysis, a cartilaginous joint, which plays a role in pelvic load transfer during normal gait (5,8). Posteriorly, the ilium joins the sacrum to form 2 sacroiliac (SI) joints, through which load is transferred from

the trunk to the limbs during standing (5,8). The fourth joint arises between the sacrum and coccyx, known as the sacrococcygeal joint.

### ***Pelvic Organs***

The pelvis houses organs of the gastrointestinal, urinary, and reproductive systems. Terminal ends of the gastrointestinal tract, the sigmoid colon and rectum, and urinary system, the bladder and urethra are contained within the pelvis (5,7,8). The female genital domains within the pelvic region include the vagina, vulva, perineum, ovaries, and fallopian tubes. The male genital domains consist of the prostate, scrotum, epididymis, testicles, and penis.

### ***Pelvic Muscles***

#### ***Pelvic Wall Muscles***

Supporting lateral wall muscles include the piriformis and obturator internus muscles. The piriformis muscle originates from the anterior surface of the sacrum and inserts onto the superior surface of the greater trochanter of the femur (9). The obturator internus muscle arises from the inner surface of the obturator membrane and inserts onto the medial border of the greater trochanter (10).

#### ***Pelvic Floor Muscles***

The pelvic floor muscles are separated into superficial and deep layers. The superficial layer is composed of the bulbocavernosus, ischiocavernosus, superficial transverse perineal muscle, and external anal sphincter (5). The deep layer consists of the ureterovaginal sphincter and deep, transverse perineal muscles (5). Each of the pelvic floor muscles is innervated by a branch of the pudendal nerve.

#### ***Pelvic Diaphragm***

Pelvic diaphragm is comprised of the levator ani and coccygeus muscles. Together, the levator ani and coccygeus connect the pubic symphysis to the coccyx, serving as the separation between the pelvic cavity and perineum (5,11). The levator ani is composed of the puborectalis, pubococcygeus, and iliococcygeus muscles. The puborectalis is an U-shaped muscle that originates at the pubic bone and encircles the anorectal junction (8,11). The pubococcygeus muscle is further divided into the pubovaginalis, puboperinealis, and puboanalis muscles. They course from the pubic bone and tendinous arch to the anococcygeal ligament and coccyx

(11). The iliococcygeus muscle originates at the ischial spine and inserts onto the lateral aspect of the sacrum and coccyx (11). The coccygeus muscle originates from the ischial spine traveling along the sacrospinous ligament to attach to the lateral aspect of the sacrum and coccyx (8).

### **Ligaments**

The pelvis has 3 supporting ligaments: iliolumbar, sacrospinous, and sacrotuberous ligaments. The iliolumbar ligament originates from the transverse process of the L5 vertebrae to the iliac crest and stabilizes the lumbosacral joint (11). The sacrotuberous ligament travels from the sacrum and coccyx to the ischial tuberosity (11). The sacrospinous ligament courses between the ischial spine and the sacrum and coccyx (11).

### **Neuroanatomy**

An understanding of the neural innervation of the pelvis is important in the management of chronic pelvic pain.

Dorsal afferent sensory roots and ventral efferent motor roots emerge from the dorsal and ventral horns of the spinal cord, respectively. As the dorsal afferent sensory root travels towards the periphery, pseudo-unipolar cell bodies are collected in a bundle forming the DRG (12). The dorsal afferent root fibers and ventral efferent root fibers converge to form mixed spinal nerves carrying signals from the spinal cord to the periphery. As the spinal nerve travels peripherally, it branches into the dorsal and ventral primary rami leading into peripheral nerves.

Somatic innervation transmitting sensory and motor signals to and from the pelvis includes ilioinguinal-iliohypogastric nerves (L1), genitofemoral (L1-L2), and pudendal nerves (S2, S3, S4). The pudendal nerve supplies sensory and motor innervation to the perineum, the external genitalia of both genders, and the skin around the anus, and anal canal. Branches of the pudendal nerve include the inferior rectal nerve, perineal nerve, and dorsal nerve of the penis/clitoris.

Visceral or autonomic innervation to organs is organized into the sympathetic and parasympathetic systems. Sympathetic trunk fibers possess cell bodies in the thoracolumbar DRG, and parasympathetic trunk fibers have cell bodies in the sacral DRG (13). The sympathetic innervation consists of the superior hypogastric plexus (SHP) or thoracic and lumbar splanchnic nerves, which enter the pelvic or inferior hypogastric plexus by the right and left hypogastric nerves (T10-L2). The

parasympathetic system (S2-S4) gives rise to the pelvic splanchnic nerve and contributes to the inferior hypogastric plexus (IHP), a continuation of SHP.

The ganglion of impar is a sympathetic ganglion located in the retroperitoneal space anterior to the sacrococcygeal joint (14). Specifically, the ganglion of impar is formed from the merging of 2 sacral sympathetic chains. Additionally, there are specific innervations of the pelvic joints. The pubic symphysis is innervated by branches of the iliohypogastric, ilioinguinal, and pudendal nerves. The sacrococcygeal junction is innervated by coccygeal plexus (L4-L5 ventral rami and coccygeal ventral rami).

### **Pathogenesis of Neuropathic Pain**

Damage from noxious stimuli activates primary afferent fiber nociceptors which are transmitted via the hypogastric and pudendal A-delta and C-fibers and synapse at the dorsal horns. These afferent neurons ascend to form the spinothalamic tract and synapse at the thalamus, and project to primary pain centers including primary and secondary somatosensory cortex, cingulate gyrus, prefrontal cortex, amygdala, and cerebellum. Descending pathways from the brain and spinal cord can modulate these pathways, thus altering sensory input. Descending pathways from the rostral ventromedial medulla play a key role in hyperalgesia and facilitation of spinal nociceptive transmission. This bidirectional modulation of nociception contributes to suppression and potentiation of pain (15).

### **Pelvic Pain Generators**

There are various pelvic pain generators requiring a thorough history and examination (Table 1). Many common pelvic pain generators arise from the pelvic floor or diaphragm. Sources of pain above the pelvic diaphragm are often generated from the viscera mediated by parasympathetic and sympathetic nerves. Pelvic floor pain may encompass myofascial pain or pelvic floor spasms.

### **Visceral Pelvic Pain Generators**

Due to the vast innervation of the visceral system, visceral pelvic pain is often challenging to localize, with up to 30% of cases where the source of pain is not found (16). Complex visceral pain pathways exist, which are triggered by nociceptors responding to mechanical, chemical, and thermal stimulations. Visceral sources of pelvic pain often arise from the gastrointestinal, urologic, and reproductive systems.

Table 1. *Pelvic pain generators.*

Pelvic Pain Generators	
Visceral Gastrointestinal: Anorectal	Anal fissures
	Hemorrhoids
	Proctitis
	Abscess
	Proctalgia
Urologic	Bladder pain syndrome/interstitial cystitis
	Urethritis
	Prostatitis
Reproductive - Female	Endometriosis
	Adenomyosis
	Ovarian cyst
	Fibroids
	Pelvic inflammatory disease
	Vulvodynia
	Adhesive disease
	Peri-pregnancy
Reproductive - Male	Orchitis
	Epididymitis
	Post-vasectomy
Neurologic	Disc herniation
	Nerve entrapment/impingement/irritation
	Pudendal neuralgia
Musculoskeletal	Dysfunction of pelvic floor muscles
	Uterosacral ligament
	Coccydynia
	Fibromyalgia
	Sacroiliac joint dysfunction
	Pubic symphysis pain
	Vaginismus
Psychosocial	Depression
	Anxiety
	Post-traumatic stress disorder
	Sexual abuse

Pain is often dull in character and poorly localized (17). Viscero-visceral or viscerosomatic sensitization may play an important role in increased pain perception. Constantini et al observed viscerovisceral sensitization where an organ with a previously painful process enhanced the pain from another organ. In his study, patients with previous dysmenorrhea and urinary calculi had enhanced pain with menstrual cycles and muscle hyperalgesia in the rectus abdominis muscle (18).

Within the gastrointestinal system, pelvic pain generators predominately arise as a result of pelvic floor muscular dysfunction with commonly associated symptoms of constipation, diarrhea, or abdominal cramps. Anatomically, a shortened puborectalis muscle may form an acute anorectal angle contributing to painful and difficult bowel evacuation (19). Further, a tight or spastic puborectalis muscle that cannot relax during defecation may lead to pelvic pain (19). Anorectal pain can result from structural abnormalities including anal fissures, hemorrhoids, proctitis, or abscesses (7). Proctalgia is anorectal pain lasting greater than 20 minutes without other causes of anorectal pain (7).

Common urologic pelvic pain generators often arise from the lower urinary tract. Bladder pain syndrome encompassing interstitial cystitis is a leading syndrome affecting 5-16 per 100,000 (19,20). Associated symptoms are often urinary frequency and urgency. Urethritis may present with urinary symptoms of burning but may also have associated abdominal or pelvic pain (20). Prostatitis is a condition that may present with pelvic pain or discomfort, may be acute or chronic in nature, and may or may not be attributed to bacterial etiology (20,21).

Reproductive sources of pelvic pain can arise from male and female domains. In females, common gynecologic causes include endometriosis, adenomyosis, ovarian cysts, pelvic fibroids, pelvic inflammatory disease, and vulvodynia (3,7). Post-operative pelvic pain may follow surgeries in the lower abdomen or pelvis and present as adhesive disease. Further, pregnancy-related pelvic pain may arise during pregnancy, peripartum, and post-partum. Of the pelvic pain generators in females, endometriosis remains a leading cause of pelvic pain. Bajaj et al found that patients with endometriosis experience central sensitization leading to hyperalgesia when compared to healthy participants (22). Studies show women with endometriosis have an increased prevalence of concomitant psychiatric disorders which should be managed while addressing pelvic pain (23). Additionally, patients with endometriosis often suffer from concomitant syndromes such as irritable bowel syndrome and interstitial cystitis (24). A study by Wu et al showed patients with endometriosis had an increased incidence and hazard ratio of interstitial cystitis during 3-year follow-up visits compared to patients without endometriosis (25). In males, scrotal pain syndrome may result from the testis including orchitis, epididymis, or post-vasectomy pain syndrome (21).

### **Neurologic Pelvic Pain Generators**

As previously highlighted, innervation of the pelvis is vast and complex. Pelvic pain may arise due to lumbar disc herniation or masses causing radiculopathy. As the nerves travel out of the foramen, they are at risk for entrapment, impingement, or irritation from the surrounding structures. Pudendal neuralgia can arise from entrapment of the pudendal nerve resulting in chronic neuropathic pain in the distribution of the genitalia, terminal urinary tract, rectum, and perineum that is exacerbated by sitting. There are many causes of pudendal neuralgia including pelvic surgery, childbirth, and certain sports including cycling (26).

### **Musculoskeletal Pelvic Pain Generators**

Myofascial pelvic pain can arise from dysfunction of the pelvic floor muscles, connective tissue, and surrounding tissues. Skeletal pain may be referred from the hip, sacroiliac joint, vertebrae, pubic symphysis, or coccyx. Muscular pain generators may arise from dysfunction of the levator ani and piriformis muscle as a result of overuse injury, strain, sprain, and postural dysfunction (19). Further, patients with fibromyalgia were more likely to have pelvic pain (4-31%) compared to the general population (27). The uterosacral ligament, attaching the cervix to the sacrum, can be a source of pelvic pain that may result from overstretching of the ligament, disruption of blood flow, or irritation of the Frankenhauser ganglion (28). Vaginismus, a condition where involuntary contraction of the muscles surrounding the vagina occurs, is another musculoskeletal source of pelvic pain (29).

### **Psychosocial Pelvic Pain Generators**

Pelvic pain may be associated with psychological stressors including pelvic trauma, sexual abuse, depression, anxiety, or post-traumatic stress disorder. Specifically, patients with pelvic pain associated with sexual dysfunction have been found to have pelvic floor muscle hypertonicity (21). As mentioned previously, patients with endometriosis have shown to have increased prevalence of concomitant disorders including post-traumatic stress disorder, depression, and anxiety that should be treated as part of comprehensive pelvic pain management (23).

### **Conventional Treatments**

Initial treatment of pelvic pain begins with conservative treatments including physical therapy, medical management, trigger point injections, and botulinum

toxin injections. Refractory cases of pain are trialed with ganglion impar blocks, caudal epidural steroid injections, or superior or inferior hypogastric blocks. In unresolved cases, neurostimulators may be trialed.

### **Role of Neuromodulation in Chronic Pelvic Pain**

The DRG was previously considered a passive structure connecting the central and peripheral nervous systems. There is now evidence supporting the role of the DRG in neuropathic pain. Following afferent nerve injury, cellular changes occur, leading to hyperexcitability. Alongside this concept is data showing stimulation of the DRG through neuromodulation decreases neuron hyperexcitability which follows nerve injury due to cellular ion changes therefore reducing neuropathic pain (12).

Despite conservative and pharmacologic therapies, there are patients with continued pelvic pain. It is this group of patients for which neuromodulation should be considered. The role of neuromodulation in chronic pelvic pain has expanded over the past 2 decades that includes PNS, DRG stimulation, and SCS (7).

### **Currently Used Locations for Lead Placement**

The currently used locations for lead placement include intracranial, spinal cord, dorsal root ganglion, sacral nerve roots, or at a peripheral nerve. In deep brain stimulation, electrodes are placed stereotactically at specific intracranial targets.

For spinal cord stimulation, lead placement is dependent on location of pain with electrodes placed over the dorsal spinal cord in the epidural space at the respective target region. In dorsal root ganglion stimulation, electrodes connected to a pulse generator are implanted over the dorsal root ganglion. Sacral nerve root stimulation involves lead placement most commonly along S3 sacral nerve root. With implantable peripheral nerve stimulation, wires connected to a pulse generator are placed in proximity to the targeted nerve. For percutaneous posterior tibial nerve stimulation, the needle is placed into the posterior tibial nerve located approximately 5 cm cephalad to the medial malleolus (7).

### **Peripheral Nerve Stimulation**

Peripheral nerve stimulator leads are ideally placed parallel to a peripheral nerve. The most common targets in chronic pelvic pain include the posterior tibial nerve and pudendal nerve. Other targets include the genitofemoral, ilioinguinal, and iliohypogastric nerves.

Summary of common targets for SCS and DRG based on pain:

- SI joint pain – S1
- Post laminectomy syndrome with failed traditional SCS – S1-S4
- Urge incontinence - S3
- Fecal incontinence - S4
- Interstitial cystitis – S2-S4
- Vulvodynia – S2-S5
- Coccydynia – S4-S5
- Urinary frequency disorders – S2-S3
- Pudendal Neuralgia – S2-S4
- Pelvic pain – S2-S3
- Rectal pain S3-S4

### Retrograde Versus Anterograde Lead Placement

In retrograde neuromodulation, a cephalocaudal approach is utilized with typical lead placement via epidural access at L3-L4 or L4-L5 (30) (Fig. 1). Advantages of this retrograde approach include lower risk of lead migration, decreased risk of dehiscence, and access site away from painful region (31). A few disadvantages

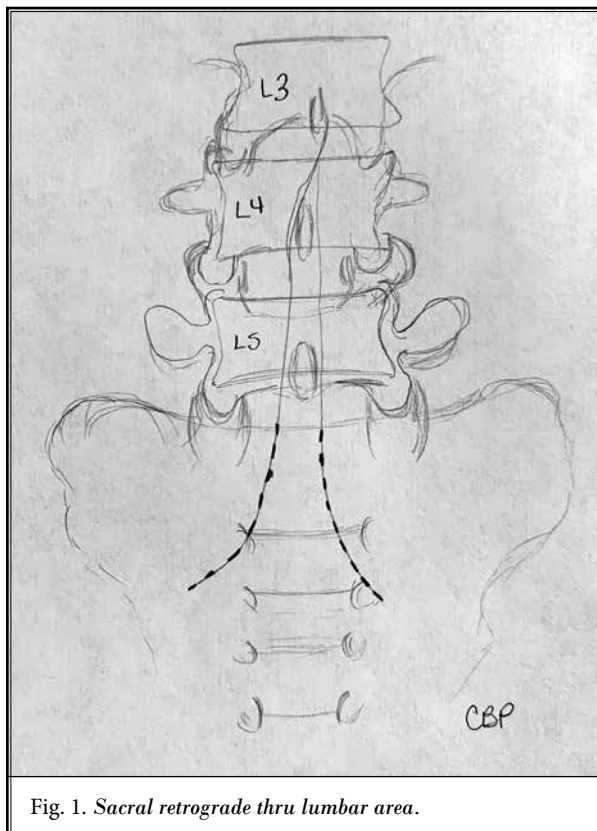


Fig. 1. Sacral retrograde thru lumbar area.

to note regarding the retrograde technique include increased risk of dural puncture and intrathecal lead placement (30).

Feler et al described sacral neuromodulation for chronic pain conditions where the S2, S3, and S4 nerve roots were stimulated through implantation of 2 lateral leads along the S2 roots and 2 medial leads over the S3 and S4 roots (31). Selective nerve root stimulation for pelvic pain and motor dysfunction with interstitial cystitis is described by Alo et al using retrograde dual-quadrupolar (32). Similarly, Yang et al applied the retrograde approach using dual-quadrupolar for anorectal pain (33). A case series of 10 patients undergoing retrograde stimulation was conducted by De Andres et al with a focus on analysis of variables that could improve outcomes. He found 7 of the 10 patients who had effective treatment had localized pain. In particular, retrograde neuromodulation was found to be more effective in the setting of radiculopathy related to failed back surgery syndrome and limited in relieving perineal pain (34)

In an anterograde approach, the needle is caudally placed with the leads advanced in posterior epidural space in an anterograde manner into the sacral canal (30) (Fig. 2). Most commonly, the epidural space at L2-L3 is accessed with lead placement at T10-T12 (Fig. 3). Advantages of the anterograde technique include decreased risk of dural puncture or intrathecal lead placement (30,35). Disadvantages of the anterograde approach exist primarily due to lack of tissue around the hiatus making lead anchoring and tunneling challenging due to the increased distance to travel around the buttock (30).

Falco et al describe a case using anterograde sacral nerve root stimulation via sacral hiatus to manage rectal, coccygeal, and perineal pain (35). Another study evaluated the use of sacral neuromodulation via the sacral hiatus with an electrode in 12 patients with perineal pain (36). Results found 8 of the 12 patients to have effective initial treatment and proceeded with final implantation.

## DISCUSSION

### Review of Literature

#### Spinal Cord Stimulation

Spinal cord stimulation can be an option for patients with refractory chronic pelvic pain. Although there is limited randomized controlled trials (RCT)

data, many case series and prospective studies have been conducted with varied lead placement locations. Overall, there has been no consensus on optimal lead placement due to complex pelvic innervation.

Kapural et al reported the first case series of SCS in 6 women with visceral pelvic pain who were poorly responsive to pharmacotherapies, injections, and conservative therapies. Leads were placed at T11-T12 via anterograde approach. On follow-up, mean visual analog scale (VAS) score was reduced from 8 to 3, the pain disability index reduced from an average of 58 to 19.7, and opioid use decreased from an average of 26 morphine milligram equivalents (MME) to 5 MME per day (37).

A prospective study by Buffenier et al evaluated the role of spinal cord stimulation of the conus medullaris for refractory pudendal neuralgia in 27 patients. Each patient underwent insertion of stimulation electrode for a trial period. Twenty patients were deemed to be responders with subsequent permanent electrode implantation, and all remained long-term responders. Results showed tripling of pain-free sitting time and mean improvement in pain by 55.5% at a mean of 15-months follow-up (38).

Simopoulous et al conducted a case series of 3 patients who underwent a high-frequency 10-kHz spinal cord stimulator for pelvic pain mediated at the conus medullaris. The first patient, a 65-year-old male with a 4-year history of refractory left-sided coccydynia following a coccygectomy, had > 50% improvement (8.2 to 4.0) in VAS scores at 9-month follow-up. The second patient of the case series was a 72-year-old male presenting with a 5-year history of perineal pain who experienced improvement in VAS scores from 8.3 to 3.3 at 12-month follow-up. The last patient of the case series, a 72-year-old female with a 10-year history of pudendal neuralgia, experienced improvement in VAS scores from 7.3 to 4.0 at 11-month follow-up (39).

Tate et al conducted a prospective, multi-center trial evaluating the efficacy of 10-kHz SCS in patients with chronic pelvic pain. Twenty-one patients underwent 10-kHz SCS trials. Of these patients, 17 were successful, with > 40% pain relief. Fourteen of these patients underwent permanent implantation. At 12-month follow-up, 77% of the patients who underwent implantation expressed > 50% pain relief and total VAS scores decreased by 72% (40).

One case series has been conducted using a retrograde neuromodulation approach by De Andres et al.

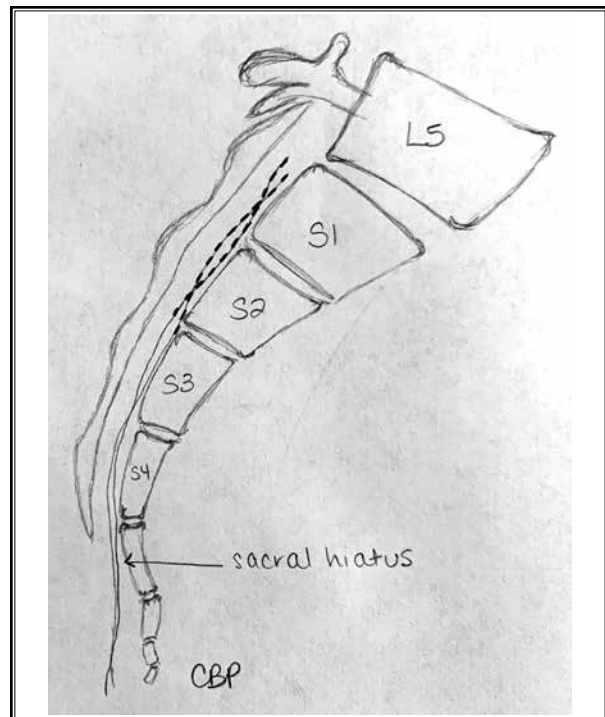


Fig. 2. Sacral anterograde thru sacral hiatus.

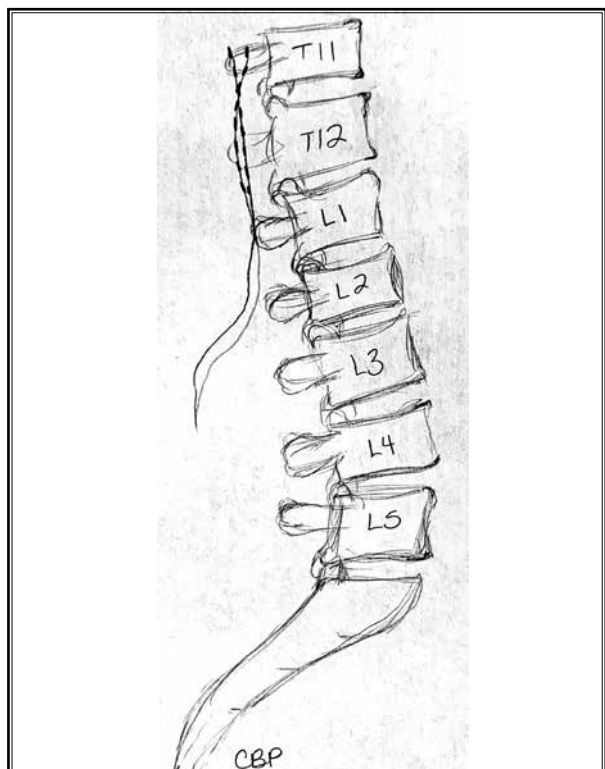


Fig. 3. Lumbar anterograde thru L1-L2.

This prospective study via chart review evaluated variables to improve outcomes of retrograde neuromodulation in 10 patients at the University General Hospital of Valencia (Spain). Seven of the 10 patients experienced effective treatment. Of this effective treatment group, the most prevalent symptoms were radiculopathy and perineal pain. Retrograde neuromodulation may be an effective treatment option for patients with radiculopathy related to failed back surgery syndrome (FBSS)(41).

Novel approaches regarding SCS lead placement for chronic pelvic pain have been explored by Hunter et al. Four patients underwent SCS with lead placement in mid-thoracic region for vaginal, rectal, low back, and feet pain. Two patients underwent trial at T6 level, and the remaining 2 patients at T7 level. Three of these patients underwent permanent implantation. Neuromodulation involving higher thoracic levels may be effective and an alternative site of placement in the management of chronic pelvic pain (42).

### **Dorsal Root Ganglion Stimulation**

The DRG is a collection of sensory neuron cell bodies carrying signals from the peripheral to the central nervous system. The DRG has been a targeted site of neuromodulation in patients with pelvic pain due to its pathway in pain transmission.

A retrospective review by Schu et al investigated the use of DRG stimulation in the management of groin pain. Twenty-nine patients were recruited and trialed with stimulation of the DRG between T12 and L4, and 25 of the 29 patients were deemed eligible for implantation. At follow-up, an average of 27.8 weeks, 82.6% of patients experienced a > 50% reduction in pain. The results suggest neuromodulation of the DRG may be an effective treatment for neuropathic pain syndromes, including neuropathic groin pain (43).

In 2018, Hunter et al conducted a case series of DRG stimulation in 7 patients with chronic pelvic pain with varied demographics, symptomology, and diagnoses. All 7 patients had successful trials and subsequently underwent placement of leads over the bilateral L1 and S2 DRGs. At follow-up, all patients reported significant pain relief. Some patients also experienced an improvement in urination and sexual function. The results of this study suggest that DRG stimulation may be an effective treatment modality for chronic pelvic pain acting through "crosstalk" mechanism. Hunter et al proposed mechanism of L1 and S2 DRG lead placement to be effective through generation of upstream and

downstream effects through crosstalk between DRG ganglia (44). Specifically, L1 is the most cephalad level where pain signals can be transferred from below L2 to the brain. Stimulating the L1 DRG interrupts the upper lumbar plexus pain signals from traveling to the brain. Similarly, stimulation of S2 DRG will disrupt pain signals from the lower lumbar and sacral plexus (Figs. 4 and 5).

At the time this review article was written, no known RCTs have been conducted regarding DRG stimulation for chronic pelvic pain. However, 2 known RCTs in DRG stimulation have been conducted by Leim et al and Mekhail et al in patients with CRPS.

### **Peripheral Nerve Stimulation**

The primary targets of peripheral nerve stimulation for chronic pelvic pain management are the sacral, pudendal, and posterior tibial nerves. The target choice should be decided upon based on patient symptoms. During sacral nerve stimulation, the roots of the sacral nerve are stimulated by an electrical current transmitted through an implanted lead. Specifically, the most commonly targeted sacral nerve root is the S3 nerve root. Sacral neuromodulation was initially approved for overactive bladder. Consequently, studies found patients with urinary symptoms experienced pelvic pain relief.

One of the first studies evaluating PNS for chronic pelvic pain was conducted by Siegel et al in 2001. This study evaluated the effectiveness of sacral nerve stimulation in 10 patients with intractable pelvic pain. After successful trials, leads were placed in either S3 or S4 foramen. Pain intensity was measured via a pain analog scale. Patients were assessed at baseline, 1, 3, and 6 months, and long-term follow-up at a median of 19 months. At the median long-term follow-up of 19 months, there was a greater than 50% reduction in VAS score (9.7 to 4.4) and a decrease in reported hours of pain from 13.1 hours to 6.9 hours (45).

Martellucci et al conducted a slightly larger study evaluating the efficacy of sacral nerve neuromodulation in 27 patients with chronic pelvic pain. Sixteen of the 27 patients showed success with trials and underwent implantation. Pre-operatively, these patients had a mean VAS of 8.1. Post-operatively VAS scores were 2.1, 2.1, 2.0, 2.3, 2.1, and 1.9 at 6, 12, 24, 36, 48, and 60-month follow-up, respectively, suggesting there is sustained long-term pain relief. This study further investigated factors contributing positively or negatively to success. Patients who had a positive response to gabapentin or pregabalin were found to be a positive



predictor for a successful response to neuromodulation. Comparatively, patients with poorly localized, diffuse pain were found to be a negative indicator for success with intervention (46).

Sokal et al conducted a case series including 9 patients with chronic pelvic pain treated with sacral root stimulation, which reported statistically significant improvement in VAS at 6-months follow-up. However, satisfactory results were not sustained at long-term 12-months follow-up. Of note, 33% of patients were complicated by infection, resulting in the removal of the device (47).

Additionally, Guardo et al conducted a study evaluating the effects of sacral neuromodulation in 12 patients with perineal pain. Each patient underwent sacral stimulation through the sacral hiatus with caudal insertion of the electrode. Of the 12 patients, 8 patients had success with initial implantation and underwent permanent implantation. On follow-up, efficacy was found to be similar to other types of electrodes. Additionally, the authors had no cases of electrode displacement (36). The caudal insertion of the InterStim electrode is an acceptable alternative in patients with perineal pain.

One of the largest PNS studies was conducted by Vancaillie et al, who conducted a case series including 52 patients evaluating the use of sacral neuromodulation for pelvic pain and pelvic organ dysfunction. Response to sacral neuromodulation was evaluated by surveys asking patients to describe symptoms before and after implantation. Forty-four of the total 52 patients completed the survey. Forty-eight of these patients had 2 leads placed at the sacral hiatus. Thirty-two patients reported improvement in pain, and 35 patients reported improvement in quality of life. The findings from this case series suggest that sacral neuromodulation is a promising option for managing pelvic pain (48).

Other peripheral nerve stimulation targets for chronic pelvic pain include the posterior tibial nerve and pudendal nerve. Limited studies have been conducted showing its efficacy in chronic pelvic pain management.

**CONCLUSION**

A review of the literature suggests neuromodulatory techniques encompassing peripheral nerve stimulation, dorsal root ganglion, and spinal cord stimulation to be an emerging therapeutic option for patients with chronic pelvic pain (Table 2). However, there is a lack of evidence to draw meaningful conclusions, and further research with high quality, randomized control trials are

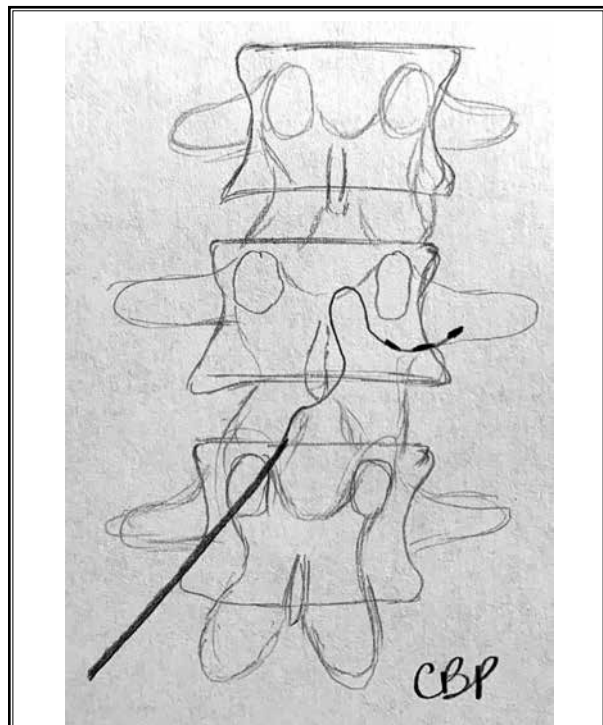


Fig. 4. DRG lead placement at L1-L2.

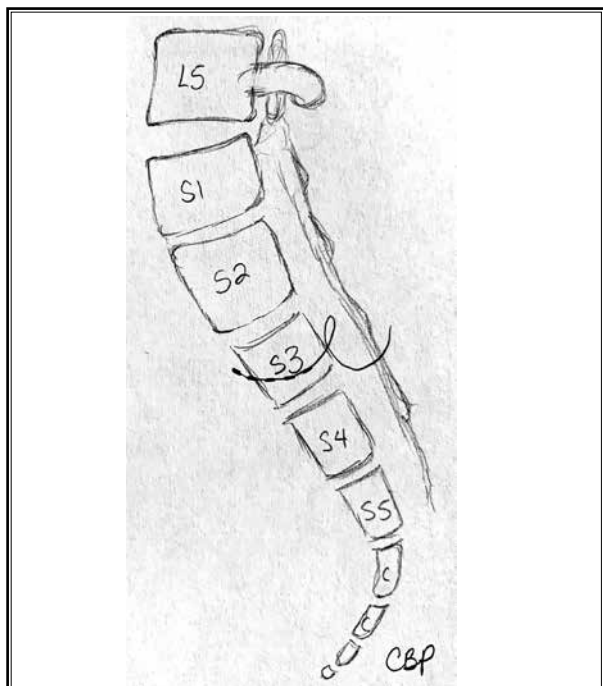


Fig. 5. DRG lead placement at S3.

Table 2. Clinical studies on the use of neuromodulation for chronic pelvic pain.

Author (Year published)	Study Title	Study Design	Number of Subjects	Intervention	Outcome Measures	Follow-up	Results
Segal (2001) (12)	Sacral Nerve Stimulation in Patients with Chronic Intractable Pelvic Pain	Prospective	10	PNS: Sacral nerve neuromodulation	Visual analog scale	Follow up at 1, 3, 6 months, and long-term median follow-up at 19 months	Reduction in VAS and hours of pain.
Martellucci (2011) (13)	Sacral nerve modulation in the treatment of chronic pelvic pain	Prospective	27	PNS: Sacral nerve neuromodulation	Visual analog scale	Follow-up at 6, 12, 24, 36, 48, and 60 months	Reduction in VAS.
Sokal (2015) (14)	Sacral Roots Stimulation In Chronic Pelvic Pain	Case series	9	PNS: Sacral root stimulation	Visual analog scale	Follow-up after implantation, 6 and 12 months	Short-term improvement in VAS from a median of 9 prior to surgery to 2 after implantation. At 6-month follow-up median VAS 3. At 12-month follow-up median VAS 6.
Guardo (2016) (15)	Caudal Neuromodulation with the Transforaminal Sacral Electrode (InterStim) Experience in a Pain Center Regarding 12 Implants	Prospective	12	PNS: Sacral nerve neuromodulation	Visual analog scale and subjective improvement in pain	Follow-up at 1, 3, and 6 months	Authors report good patient satisfaction. No statistical data analysis performed.
Vancaillie (2018) (16)	Sacral neuromodulation for pelvic pain and pelvic organ dysfunction: A case series	Case series	52	PNS: Sacral nerve neuromodulation	Patient-reported survey	Survey completed before and after procedure	32 patients reported improvement in pain. 35 patients reported improvement in quality of life.
Schu (2015) (18)	Spinal cord stimulation of the dorsal root ganglion for groin pain - a retrospective review	Retrospective review	29	DRG stimulation	Visual analog scale	Follow-up at an average of 27.8 weeks	Average pain reduction was 71.4% and 82.6% of patients experienced > 50% reduction in pain at follow-up.
Hunter (2018) (19)	Dorsal Root Ganglion Stimulation for Chronic Pelvic Pain: A Case Series and Technical Report on a Novel Lead Configuration	Case series	7	DRG stimulation with leads over L1 and S2	Patient-reported pain relief	Follow up over 12 months	Significant patient-reported pain relief at follow-up.
Kapural (2006) (21)	Spinal Cord Stimulation Is an Effective Treatment for the Chronic Intractable Visceral Pelvic Pain	Case series	6	Spinal cord stimulation	Visual analog scale pain score, pain disability index, opioid use (mg equivalents per day)	Follow-up was 30.6 months	Median visual analog scale pain score decreased from 8 to 3. All patients had more than 50% of pain relief. Pain Disability Index changed from an average of 57.7 ± 12 to 19.5 ± 7. Opiate use decreased from an average 22.5 mg to 6.6 mg of morphine sulfate milligram equivalents per day.
Buffenier (2015) (22)	Spinal cord stimulation of the conus medullaris for refractory pudendal neuralgia: a prospective study of 27 consecutive cases	Prospective	27	Spinal cord stimulation	Pain-free sitting time, maximum and average pain scores	Mean follow-up at 15 months	Tripling of pain-free sitting time, and mean percentage improvement of 55.5%.

Table 2 (cont). Clinical studies on the use of neuromodulation for chronic pelvic pain.

Author (Year published)	Study Title	Study Design	Number of Subjects	Intervention	Outcome Measures	Follow-up	Results
Simopoulos (2017) (23)	Treatment of Chronic Refractory Neuropathic Pelvic Pain with High-Frequency 10-kilohertz Spinal Cord Stimulation	Case series	3	10-kHz Spinal Cord Stimulation	Visual analog scale	Follow-up varied (9, 11, 12 months)	Improvement in VAS scores at follow-up.
Tate (2020) (24)	A Prospective, Multi-Center, Clinical Trial of a 10-kHz Spinal Cord Stimulation System in the Treatment of Chronic Pelvic Pain	Prospective	21	10-kHz Spinal Cord Stimulation	Visual analog scale	Follow-up at 12 months	At 12 month follow-up, 77% of the patients who underwent implantation expressed > 50% pain relief and total VAS scores decreased by 72%.
De Andres (2013) (25)	Role of lumbosacral retrograde neuromodulation in the treatment of painful disorders	Prospective chart review	10	Spinal cord stimulation	Effective vs ineffective stimulation	Follow-up over 12 months	Seven of 10 patients experienced effective treatment with retrograde neuromodulation. These patients primarily complained of radiculopathy/FBSS.
Hunter (2013) (26)	Neuromodulation of pelvic visceral pain review of the literature and case series of potential novel targets for treatment	Case series	4	Spinal cord stimulation	Patient-reported pain relief	Varied follow-up at 1 week, 3 or 10 months	Patient-reported pain improvement at follow-up.

still necessary at this time. Varied presentations of patients with CPP, complex pelvic innervation, and multifaceted generation of pain with the involvement of psychological components limit identification and consensus on neuromodulatory targets. Each technique possesses its respective risks and benefits. Decision-making on which technique to be utilized should be made based on the patient's pain location and individual factors.

### REFERENCES

- Paulson JD, Gor HB. Management of chronic pelvic pain. *Expert Rev Obstet Gynecol* 2007; 2:37-50.
- Alcock A. Chronic pelvic pain in women. *Br Med J* 1926; 1:609-612.
- Stein SL. Chronic pelvic pain. *Gastroenterol Clin North Am* 2013; 42:785-800.
- Smith CP. Male chronic pelvic pain: an update. *Indian J Urol* 2016; 32:34-39.
- Saddic L, Urman RD, Valovska AT. Pelvic Pain Management: An Introduction. In: Valovska AT, ed. *Pelvic Pain Management*. Oxford University Press; 2016:1-9.
- Siedentopf F, Sillem M. Chronischer unterbauchschmerz der frau [Chronic pelvic pain in women]. *Schmerz* 2014; 28:300-304.
- Roy H, Offiah I, Dua A. Neuromodulation for pelvic and urogenital pain. *Brain Sci* 2018; 8:1-16.
- George SE, Clinton SC, Borello-France DF. Physical therapy management of female chronic pelvic pain : anatomic considerations. *Clin Anat* 2013; 88:77-88.
- Chang C, Jenou SH, Varacallo M. Anatomy, bony pelvis and lower limb, piriformis muscle. In: *StatPearls*. Treasure Island (FL): StatPearls Publishing; October 11, 2021.
- Aung HH, Sakamoto H, Akita K, Sato T. Anatomical study of the obturator internus, gemelli and quadratus femoris muscles with special reference to their innervation. *Anat Rec* 2001; 263:41-52.
- Chaudhry SR, Nahian A, Chaudhry K. Anatomy, abdomen and pelvis, pelvis. In: *StatPearls*. Treasure Island (FL): StatPearls Publishing; 2020.
- Krames E. The dorsal root ganglion in chronic pain and as a target for neuromodulation: a review. *Neuromodulation* 2015; 18:24-32.
- Origoni M, Leone Roberti Maggiore U, Salvatore S, Candiani M. Neurobiological mechanisms of pelvic pain. *Biomed Res Int* 2014; 2014:903848.
- Gonnade N, Mehta N, Khera PS, Kumar D, Rajagopal R, Sharma PK. Ganglion impar block in patients with chronic coccydynia. *Indian J Radiol Imaging* 2017; 27:324-328.
- Origoni M, Leone Roberti Maggiore U, Salvatore S, Candiani M. Neurobiological Mechanisms of Pelvic Pain. *Biomed Res Int* 2014; 2014:903848.
- Vercellini P, Somigliana E, Viganò P, Abbiati A, Barbara G, Fedele L. Chronic pelvic pain in women: etiology, pathogenesis and diagnostic approach. *Gynecol Endocrinol*

- 2009; 25:149-158.
17. Gritsenko K, Cohen M. Pelvic Pain. In: *Essentials of Pain Medicine*. 4th ed. Elsevier; 2018:261-273.
  18. Costantini R, Affaitati G, Fiordaliso M, Giamberardino MA. Viscero-visceral hyperalgesia in dysmenorrhoea plus previous urinary calculosis: role of myofascial trigger points and their injection treatment in the referred area. *Eur J Pain* 2020; 24:933-944.
  19. Bonder JH, Chi M, Rispoli L. Myofascial pelvic pain and related disorders. *Phys Med Rehabil Clin N Am* 2017; 28:501-515.
  20. Fall M, Baranowski AP, Fowler CJ, et al. EAU guidelines on chronic pelvic pain. *Eur Urol* 2004; 46:681-689.
  21. Rosenbaum TY, Owens A. The role of pelvic floor physical therapy in the treatment of pelvic and genital pain-related sexual dysfunction (CME). *J Sex Med* 2008; 5:513-523.
  22. Bajaj P, Bajaj P, Madsen H, Arendt-Nielsen L. Endometriosis is associated with central sensitization: a psychophysical controlled study. *J pain* 2003; 4:372-380.
  23. Casalechi M, Vieira-Lopes M, Quessada MP, Araújo TC, Reis FM. Endometriosis and related pelvic pain: association with stress, anxiety and depressive symptoms. *Minerva Obstet Gynecol* 2021; 73:283-289.
  24. Overholt TL, Evans RJ, Lessey BA, et al. Non-bladder centric interstitial cystitis/bladder pain syndrome phenotype is significantly associated with co-occurring endometriosis. *Can J Urol* 2020; 27:10257-10262.
  25. Wu CC, Chung SD, Lin HC. Endometriosis increased the risk of bladder pain syndrome/interstitial cystitis: a population-based study. *NeuroUrol Urodyn* 2018; 37:1413-1418.
  26. Kaur J, Singh P. Pudendal nerve entrapment syndrome. In: *StatPearls*. Treasure Island (FL): StatPearls Publishing; November 14, 2021.
  27. Johnson CM, Makai GEH. Fibromyalgia and irritable bowel syndrome in female pelvic pain. *Semin Reprod Med* 2018; 36:136-142.
  28. Goeschen K. Role of uterosacral ligaments in the causation and cure of chronic pelvic pain syndrome. *Pelvipereineology [Internet]*. 2015; 34:2-20.
  29. Binik YM. The DSM diagnostic criteria for vaginismus. *Arch Sex Behav* 2010; 39:278-291.
  30. Hunter CW, Stovall B, Chen G, Carlson J, Levy R. Anatomy, pathophysiology and interventional therapies for chronic pelvic pain: a review. *Pain Physician* 2018; 21:147-167.
  31. Feler CA, Whitworth LA, Fernandez J. Sacral neuromodulation for chronic pain conditions. *Anesthesiol Clin North Am* 2003; 21:785-795.
  32. Aló KM, McKay E. Selective Nerve Root Stimulation (SNRS) for the treatment of intractable pelvic pain and motor dysfunction: a case report. *Neuromodulation* 2001; 4:19-23.
  33. Yang KS, Kim YH, Park HJ, Lee MH, Kim DH, Moon DE. Sacral nerve stimulation for treatment of chronic intractable anorectal pain -a case report-. *Korean J Pain* 2010; 23:60-64.
  34. De Andres J, Perotti L, Villaneuva-Perez VL, Asensio-Samper JM, Fabregat-Cid G. Role of lumbosacral retrograde neuromodulation in the treatment of painful disorders. *Pain Physician* 2013; 16:145-153.
  35. Falco FJE, Rubbani M, Heinbaugh J. Anterograde Sacral Nerve Root Stimulation (ASNRS) via the sacral hiatus: benefits, limitations, and percutaneous implantation technique. *Neuromodulation* 2003; 6:219-224.
  36. Alonso Guardo L, Cano Gala C, Sánchez Poveda D, et al. Caudal neuromodulation with the transforaminal sacral electrode (InterStim®): experience in a pain center regarding 12 implants. *Korean J Pain* 2016; 29:23-28.
  37. Kapural L, Narouze SN, Janicki TI, Mekhail N. Spinal cord stimulation is an effective treatment for the chronic intractable visceral pelvic pain. *Pain Med* 2006; 7:440-443.
  38. Buffenoir K, Rioult B, Hamel O, Labat JJ, Riant T, Robert R. Spinal cord stimulation of the conus medullaris for refractory pudendal neuralgia: a prospective study of 27 consecutive cases. *NeuroUrol Urodyn*. 2015;34(2):177-182.
  39. Simopoulos T, Yong RJ, Gill JS. Treatment of chronic refractory neuropathic pelvic pain with high-frequency 10-kilohertz spinal cord stimulation. *Pain Pract* 2018; 18:805-809.
  40. Tate JL, Stauss T, Li S, Rotte A, Subbaroyan J. A prospective, multi-center, clinical trial of a 10-kHz spinal cord stimulation system in the treatment of chronic pelvic pain. *Pain Pract* 2021; 21:45-53.
  41. De Andres J, Perotti L, Villaneuva-Perez VL, Asensio-Samper JM, Fabregat-Cid G. Role of lumbosacral retrograde neuromodulation in the treatment of painful disorders. *Pain Physician* 2013; 16:145-153.
  42. Hunter C, Davé N, Diwan S, Deer T. Neuromodulation of pelvic visceral pain: review of the literature and case series of potential novel targets for treatment. *Pain Pract* 2013; 13:3-17.
  43. Schu S, Gulve A, Eldabe S, et al. Spinal cord stimulation of the dorsal root ganglion for groin pain-a retrospective review. *Pain Pract* 2015; 15:293-299.
  44. Hunter CW, Yang A. Dorsal root ganglion stimulation for chronic pelvic pain: a case series and technical report on a novel lead configuration. *Neuromodulation* 2019; 22:87-95.
  45. Paszkiewicz E, Siegel S, Kirkpatrick C, Hinkel B, Keeisha J, Kirkemo A. Sacral nerve stimulation in patients with chronic intractable pelvic pain. *Urology* 2001; 57:124.
  46. Martellucci, J, Naldini, G, Carriero A. Sacral nerve modulation in the treatment of chronic pelvic pain. *Int J Colorectal Dis* 2012; 27:921-926.
  47. Sokal, Pawel, Zieliński, Piotr, Harat M. Sacral roots stimulation in chronic pelvic pain. *Neurol Neurochir Pol* 2015; 49:307-312.
  48. Vancaillie T, Kite L, Howard E, Chow J. Sacral neuromodulation for pelvic pain and pelvic organ dysfunction: a case series. *Aust N Z J Obstet Gynaecol* 2018; 58:102-107.