

## Scoping Review



# Superior and Middle Cluneal Nerve Entrapment: A Cause of Low Back and Radicular Pain

Helen W. Karl, MD<sup>1</sup>, Standiford Helm, MD<sup>2</sup>, and Andrea M. Trescot, MD<sup>3,4</sup>

From: <sup>1</sup>Anesthesiology and Pain Medicine, University of Washington School of Medicine, Anesthesiologist, Seattle Children's Hospital, WA; <sup>2</sup>Clinical Professor in the Department of Anesthesia and Pain Medicine at University of California, Irvine, CA; <sup>3</sup>Florida Pain Relief Group, Orange Park, FL; <sup>4</sup>Chief Medical Officer of Stimwave Technologies

Address Correspondence:  
Standiford Helm, MD  
Department of Anesthesia and Pain Medicine, University of California, Irvine, UCI Health Center for Pain and Wellness  
Gottschalk Medical Plaza  
1 Medical Plaza Dr,  
Irvine, CA 92617  
E-mail:  
drhelm@thehelmcenter.com

Disclaimer: There was no external funding in the preparation of this manuscript.

Conflict of interest: Dr. Trescot is Chief Medical Officer, Stimwave Technologies. Dr. Helm is a shareholder in Stimwave Technologies. Dr. Karl certifies that he or a member of his or her immediate family, has no commercial association (i.e., consultancies, stock ownership, equity interest, patent/licensing arrangements, etc.) that might pose a conflict of interest in connection with the submitted manuscript.

Manuscript received: 12-29-2020  
Revised manuscript received:  
12-19-2021  
Accepted for publication:  
01-25-2022

Free full manuscript:  
www.painphysicianjournal.com

**Background:** The superior and middle cluneal nerves are sources of low back, buttock, and leg pain. These nerves are cutaneous branches of the lateral branches of the dorsal rami of T11- S4. Pain arising from entrapment or dysfunction of one or more of these nerves is called "cluneal nerve syndrome." A clear understanding of the anatomy underlying cluneal nerve syndrome and its treatment has been hampered by the very small size of the cluneal nerves and their complex, varying anatomy. Because of differing methods and foci of investigation, the literature regarding cluneal nerves has been confusing and even contradictory.

**Objectives:** This paper provides a thorough critical literature review of cluneal nerve anatomy and implications for therapy.

**Study Design:** A modified scoping review.

**Methods:** The bibliographic trail of English language papers on the anatomy and treatment of cluneal nerve syndrome was used to resolve the contradictions that have appeared in some of the anatomic descriptions and, where applicable, to examine their implications for therapy.

**Results:** Recent anatomic and surgical investigations confirm a wider than previously realized range of central nervous system origins of these peripheral nerves, explaining why cluneal nerve dysfunction can cause a wide array of symptoms, including low back, buttock, and/or leg pain or "pseudosciatica."

**Conclusions:** Cluneal nerve syndrome is characterized by a triad of pain, tender points, and relief with local anesthetic injections. The pain is a deep, aching, poorly localized low back pain with variable involvement of the buttocks and/or legs. Tender points are localized at the iliac crest or caudal to the posterior superior iliac spine. Muscle weakness and dermatomal sensory changes are absent in cluneal nerve syndrome. If the pain returns after injections, neuroablation, nerve stimulation, or surgical release may be needed.

**Key words:** Low back pain, buttock pain, leg pain, superior cluneal nerves, middle cluneal nerves, entrapment neuropathy, pseudosciatica

**Pain Physician 2022; 25:E503-E521**

Low back pain remains one of the most common health complaints in the United States and around the world. Despite advances in imaging and diagnostic interventional pain management

techniques, the cause of low back pain can frequently not be found (1,2). Of those structures which can cause low back or leg pain, the greatest focus has been on the intervertebral disc, the lumbar facet joints, and the sacroiliac joint (3,4).

The role of peripheral nerve entrapment as a cause of pain has been overshadowed by spinal causes of pain and only recently has received increasing attention (5,6). Although peripheral nerves are now the focus of increasing interest, they were among the first structures investigated when the field of pain management developed (7). Cluneal nerve disorders specifically were first described in 1957 by Strong and Davila (The word cluneal derives from the Latin *clunes*, English buttocks. An acceptable alternative spelling is *clunial* [8]) (9). By pressing on the superior or middle cluneal nerves while operating under local anesthesia, they were able to generate pain in the back, groin, leg, or foot.

Unfortunately, the work of Strong and Davila on the cluneal nerves did not attract much attention. Later work by Bogduk and others focused more on the medial branches and provided confusing, even contradictory results regarding the cluneal nerves (10-19). Areas of discrepancy included both the anatomy of the nerves and the extent to which they contribute to chronic low back pain.

This review is written because of the importance of low back pain, the increasing understanding of the role of peripheral nerves, specifically cluneal nerves, as a cause of low back and leg pain, and the new technologies available for interventional pain physicians to treat cluneal pain. The goal of the review is to examine what is known of the anatomy of the cluneal nerves, focusing on where they are vulnerable to injury, as an understanding of the anatomic location of dysfunction can help guide therapy.

There are 3 cluneal nerves, the superior cluneal nerves, the middle cluneal nerves, and the inferior cluneal nerves. Because only the superior cluneal nerves and middle cluneal nerves are significant in terms of being sources of low back, groin, leg, or foot pain, this review will focus on the superior and middle cluneal nerves only.

The nerves are described in the pleural to emphasize the wide anatomic variation of these nerves.

## **METHODS**

### **Study question**

The study questions are:

- What is known about the anatomy of the cluneal nerves; and
- How does that knowledge assist with the diagnosis and treatment of low back, buttock, and leg pain?

### **Methodology**

This review is done using “scoping” study methodology (20). A scoping study is distinguished from a systematic review in that a systematic review “typically focuses on a well-defined question,...while a scoping study tends to address broader topics where many different study designs might be applicable.” Scoping studies and systematic reviews also differ in that systematic reviews draw conclusions regarding very specific research questions from a narrow range of studies assessed for their quality, while a scoping study focuses on broader questions without the need for quality assessment. Scoping studies differ from literature reviews in that scoping studies require analytical interpretation of the literature (21).

There are several reasons why scoping studies would be used, the current reason being to summarize and disseminate research findings related to the cluneal nerves. Performing a scoping study involves 5 steps: identifying the research question, searching for relevant studies, selecting studies, charting the data, and collating and summarizing the results.

Relevant studies were searched for and selected from the bibliographies of clinical and anatomic reports and by reviewing studies that referenced the clinical and anatomic reports. Data was charted in 4 separate spreadsheets and organized by clinical and cadaver studies for the superior cluneal nerves and the middle cluneal nerves. Data items followed included information about the study population (patient or specimens), methods, and key outcome measures.

Only English language studies were included.

### **Results of Literature Search**

Twelve recent surgical reports (16-18,22-30) and 9 anatomical studies (14,15,19,31-36) were identified as new contributions to the literature. The majority of this work is from researchers in Japan. Four potentially valuable Japanese language studies were excluded (37-40). Other foundational studies are presented in the discussion of the anatomy.

### **Anatomy**

To understand the role played by the cluneal nerves as sources of low back or leg pain, it is necessary to understand the spinal anatomy. Each spinal cord segment gives rise to a dorsal (sensory) and a ventral (motor) root. These roots combine in the intervertebral foramen to form a short, less than 1 cm, spinal nerve. The spinal nerve, which has both motor and sensory

fibers, then divides into the dorsal ramus and the ventral ramus (Fig. 1). The dorsal ramus divides into 3 branches: the medial branch, the intermediate branch, and the lateral branch, with the intermediate and lateral branches sometimes arising from a common stem (Fig. 2)(12,19,31,32,41).

The medial branch innervates the facet joints, the multifidus, and a small area of skin medial to the facet joint. The medial branches have been a major area of focus for interventional pain management because of their role in the treatment of facet-mediated pain (42). Having been thoroughly evaluated elsewhere, they are not further described here.

The intermediate and lateral branches were first described in detail in 1908 by Johnston (41). Johnston emphasized the long, somewhat curved course of these branches as they reached their termination in the skin, a course necessitated by the extensive movement of the spine and hips. Johnston also noted both the frequent communication of these nerves with one another and the variation that existed between individuals and also within individuals, with the course of the nerve on the right varying even from that on the left in the same cadaver.

This variation of the nerve between and within patients highlights the need for a careful physical exam and low volume local anesthetic diagnostic injections when attempting to diagnosis cluneal nerve pathology.

Both Bogduk and Maigne clarified the relationship between the paravertebral muscles and the branches of the dorsal ramus (10-12,43-46). The longissimus thoracis and iliocostalis lumborum muscles, along with the multifidus muscle, are covered by the thoracolumbar fascia (also known as the erector spinae aponeurosis) (Fig. 3). A fascial plane, the lumbar intermuscular aponeurosis, extends from the thoracolumbar fascia to the transverse process, separating the longissimus thoracis from the more lateral iliocostalis lumborum. There is a fat filled space ventral to the aponeurosis and between the 2 muscles in which the lateral and intermediate branches travel (19,31,32).

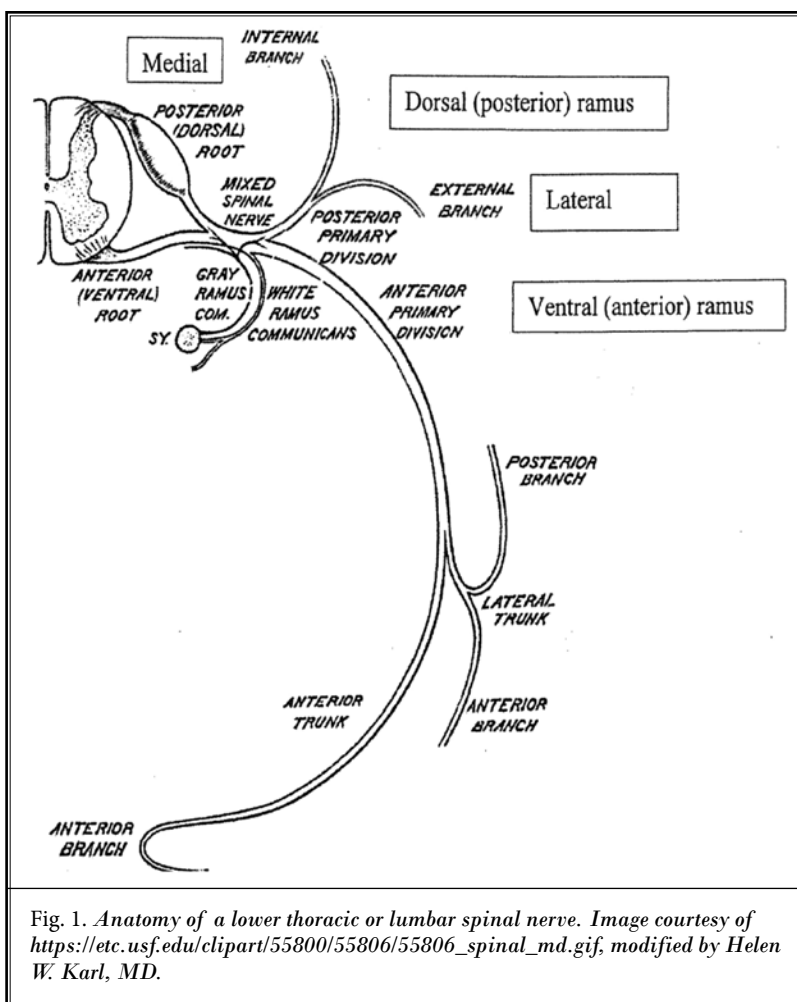


Fig. 1. Anatomy of a lower thoracic or lumbar spinal nerve. Image courtesy of [https://etc.usf.edu/clipart/55800/55806/55806\\_spinal\\_md.gif](https://etc.usf.edu/clipart/55800/55806/55806_spinal_md.gif), modified by Helen W. Karl, MD.

Between T11 and L4, there is usually an intermediate branch in addition to the lateral branch. The intermediate branch, when present, often communicates with the branches at nearby levels and terminates in the longissimus thoracis. Some investigators believe the intermediate branch extends to the skin (19,31).

The lateral branches cross posterior to the transverse process and travel caudally, laterally, and dorsally through the iliocostalis lumborum, innervating it (47) (Fig. 2). The lateral branches pierce the thoracolumbar fascia and become the cluneal nerves. The cluneal nerves are purely sensory.

There are 3 cluneal nerves, the superior, middle, and inferior. These nerves are distinguished by their origin, but all exhibit extensive and variable branching. Designating them as a single nerve, such as the superior cluneal nerve, is misleading because of this variability

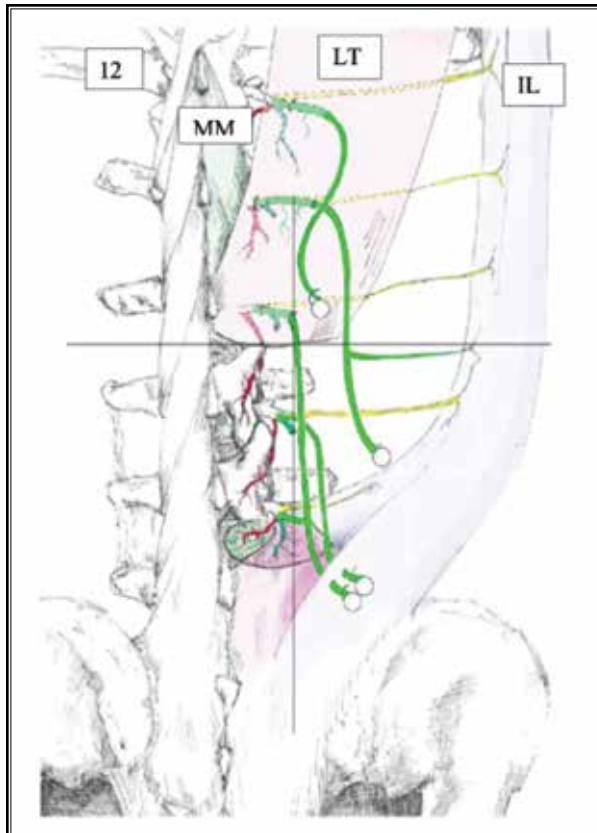


Fig. 2. Dorsal view of dorsal ramus (DR) branches from T12 to L3. The DR divides into 3 main branches and heads in a dorsal direction. The lateral ascending branches (yellow) follow the direction of the transverse process to the iliocostalis lumborum muscle (IL, blue; here flipped laterally to demonstrate the lateral branches). The medial branches (red) innervate the multifidus muscle (MM, green). The intermediate branches (green) innervate the longissimus thoracis muscle (LT, magenta); they also innervate the IL from the medial direction. The intermediate branches run toward the skin; here intermediate branches from L2, L3, and L4 become superior cluneal nerves (SCNN). Connecting branches are not shown. 12 = 12th rib; interrupted line = branch crossing muscle compartments, straight line = free branch; ° = perforation of the intermediate branch of the DR through the fascia to the skin. From Steinke H, Saito T, Miyaki T, Oi Y, Itoh M, Spanel-Borowski K. *Anatomy of the human thoracolumbar rami dorsales nervi spinalis*. *Ann Anat*. 2009;191(4):408-416. (19), with permission.

so that they are best described as the superior, middle, and inferior cluneal nerves, not nerve.

The inferior cluneal nerves is a branch of the posterior femoral cutaneous nerve and hence arises from the ventral rami (48). The inferior cluneal nerve may cause

pain with sitting but does not cause back pain, and it is not at risk from iliac crest bone graft procurement (34,49). The inferior cluneal nerve will not be further covered in this report.

### Superior Cluneal Nerves

The superior cluneal nerves (SCNN) are the cutaneous branches of the dorsal rami of T11 to L5 (14,15,41,45). They either pierce the thoracolumbar fascia (superior to the iliac crest) or the gluteal fascia (inferior to the crest) to become superficial (14,45) (Figs. 4 and 5). In a statement unusually decisive for anatomy papers, Maigne states "the most medial orifice was invariably located 7-8 cm from the midline. After piercing the fascia, the nerves innervate the skin over the upper 2/3 of the gluteal muscles as far laterally as the greater trochanter."

The superior cluneal nerves pierce the thoracolumbar fascia roughly equally above or below the iliac crest (15). When the nerves pierce the fascia caudal to the iliac crest, they pass through a fibro-osseous tunnel (14,15) (Fig. 6). The most medial branch of the cluneal nerves, located 7-8 cm from midline, is the branch most frequently (approximately 40% of the time) surrounded by the fibro-osseous tunnel.

Injury to the superior cluneal nerves is thought to most commonly involve the medial branch (50,51). Because of the common involvement of the most medial branch of the superior cluneal nerves, the term "medial superior cluneal neuralgia" has been suggested. Given the multiple branching of the dorsal ramus, this term is confusing and should not be adopted. Further, Kuniya examined 109 specimens, finding great variability (15), with only a quarter of the specimens having solely the most medial branch of the superior cluneal nerves running through a fibro-osseous tunnel, with approximately 1/2 of the dissections showing at least one branch going through a tunnel (Fig. 7). These findings have been confirmed by other observers, with one author describing the tunnels as "grooves" (14,52).

The superior cluneal nerves have been grouped according to their distance from midline as they cross the iliac crest into medial, intermediate, and lateral superior cluneal nerves (Fig. 8). This nomenclature creates confusion with the branches of the dorsal ramus (12). An alternative approach is to label the branches of the superior cluneal nerves a1 to a5 as they cross the dorsal ramus (Fig. 9) (14). To maximize clarity, in this manuscript, the terms medial, intermediate, and lateral will be associated specifically with the dorsal ramus or superior cluneal nerves, as appropriate.

The branches of the superior cluneal nerves can arise from any of the nerve roots from T12 to L5 or from multiple nerve roots (Fig. 9). The nerve roots supplying any one branch of the superior cluneal nerves do not need to be adjacent so that T12 and L2 can give rise to one branch.

Different authors have presented markedly different findings as to the nerve root of origin of the most medial branch of the superior cluneal nerves as they traverse the iliac crest. Maigne found L1 to be the most common root of origin (45), while Konno, in a more recent study, reports L4 and L5 as the vastly predominate roots of origin (14). This point has clinical relevance in that the most medial branch of the superior cluneal nerves is most likely to be entrapped by the fascia as the nerve crosses the iliac crest because the fascia is thickest towards the midline. The thinner fascia more laterally is less likely to injure the nerve. Given the role of superior cluneal nerves in causing buttock and leg pain, Konno's findings appear to support what is seen clinically, which is back pain as well as pain radiating down to the foot. This leg pain is often called "pseudosciatica" (13) because it mimics the pain from a herniated disc.

These marked differences in reports regarding the anatomy of the superior cluneal nerves are mirrored by other authors and appear to reflect differences in focus and difference of technique. Authors have focused on low back pain with a trigger (tender) point (11); without a trigger (tender) point (9,46); with leg pain (16); or without leg pain (45,46). Some have focused on anatomical description (41), while others have focused on surgical concerns related to iliac crest procedures (34,35). Studies using the technique of a ventral approach provide more precision proximally but seem less detailed as they extend peripherally. Some earlier researchers studied the dorsal ramus as a whole (11,12,41), while others focused solely on the lateral branches (14,15,45). Finally, the nerves are very small, with a mean diameter of less than 2 mm where they cross the iliac crest, making preservation difficult (14,35,53). Early anatomists complained that, given the absence of refrigeration, evaluating nerves smaller than a pencil tip was difficult (54).

The lateral branches of the dorsal ramus are the primary source of the superior cluneal nerves (12). There is a possibility, given the variability, branching, and anastomoses of the intermediate and lateral branches of the

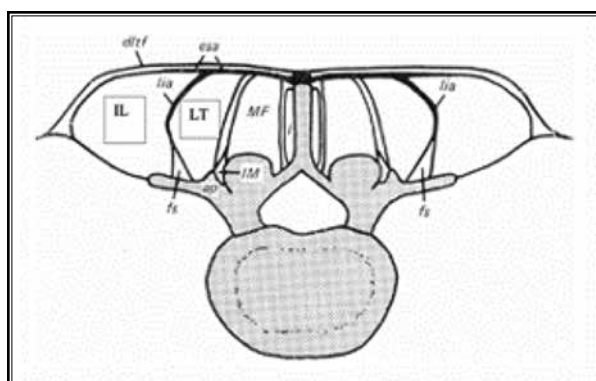


Fig. 3. A transverse section in the lower lumbar region showing the relative positions of the muscles and fascia. The erector spinae aponeurosis (esa, also known as the thoracolumbar fascia, TLF) covers the longissimus thoracis (LT), as well as the multifidus (MF) and interspinalis (I) muscles. It is continuous ventrally with the lumbar intermuscular aponeurosis (lia) which envelops the lateral surface of the LT, segregating it from the iliocostalis lumborum (IL). The fat-filled space (fs) ventral to the lia maintains this segregation as far as the transverse process and is a conduit for the external branches of the dorsal ramus (DR). The LT inserts about the accessory process (ap), while the IL inserts further laterally on the transverse process. Lateral to the lia, the esa extends for a limited distance over the dorsal surface of the IL. The intertransversarii mediales (IM) are marked.

From Bogduk N. A reappraisal of the anatomy of the human lumbar erector spinae. *Journal of Anatomy*. 1980;131(Pt 3):525-540. (63), with permission.

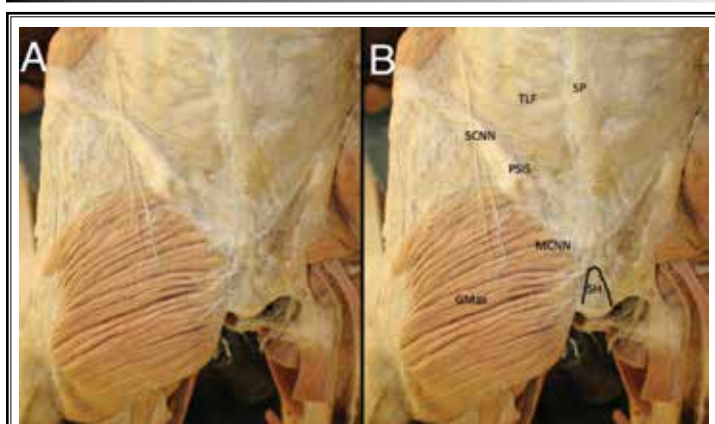


Fig. 4. Superficial posterior spine dissection. SCNN = superior cluneal nerves; MCNN = middle cluneal nerves; PSIS = posterior superior iliac spine; GMax = Gluteus maximus; SH = sacral hiatus; SP = spinous process; TLF = thoracolumbar fascia. The most likely place for the SCNN to be injured or entrapped is where they cross the iliac crest, about 7 cm lateral to the midline and about 5 cm superior to the PSIS. (Image courtesy of Andrea Trescot MD, modified from an image from *Bodies, The Exhibition*, with permission).

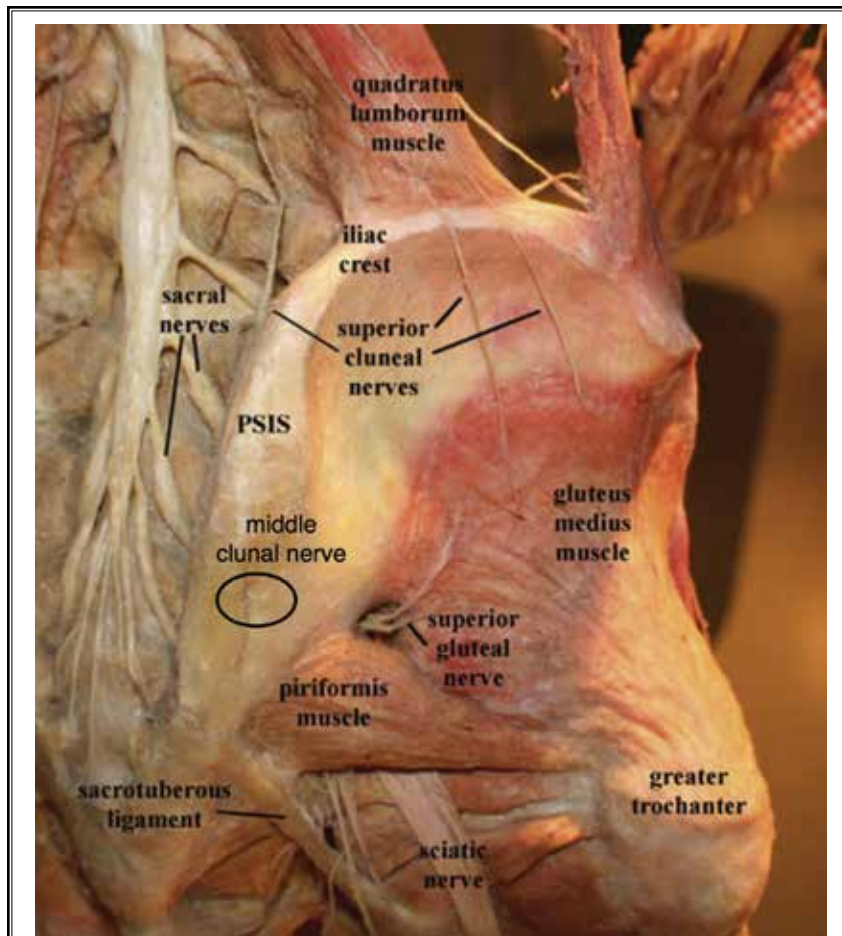


Fig. 5. Dissection of the buttocks. GMe = gluteus medius muscle; GT = greater trochanter; LPSL = long posterior sacral ligament; MCN = middle cluneal nerve (circled); PIR = piriformis muscle; SCN = superior cluneal nerve; SGN = superior gluteal nerve; SN = sciatic nerve; ST = sacrotuberous ligament. (Image courtesy of Andrea Trescot, MD, modified from an image from *Bodies, The Exhibition*, with permission).

dorsal rami, that the intermediate branches also contribute to the superior cluneal nerves. Given the small size of the nerves involved and the technical difficulties in examining this question, the question is probably not answerable and not of clinical significance.

However, a clinically important question is the location of the branch of the superior cluneal nerves most likely to be entrapped, the medial branch. This entrapment was first reported by Maigne (12) and later confirmed by direct anatomical evidence of entrapment (15). While Maigne stated that the entrapment was 7-8 cm from midline, the anatomical evaluation found variations between 5 and 9 cm from midline,

depending upon patient size. Because of the wide variability of origin and anastomoses of the lateral and intermediate branches of the dorsal ramus as they course to the skin (12,41,53), superior cluneal nerve entrapment can present with a wide variety of symptoms. This protean presentation emphasizes the need to consider superior cluneal nerve entrapment as a part of the differential diagnosis of low back pain with or without leg or groin pain.

### **Middle Cluneal Nerves**

The middle cluneal nerves (MCNN) are the cutaneous branches of the dorsal rami of L5-S4. The sacral dorsal rami emerge from the foramina and divide into medial and lateral branches. The medial branches innervate the multifidus. The lateral branches, also called lateral trunks (55), form loops, joining each other on the posterior surface of the sacrum.

The lateral branches then form secondary loops covered by the posterior sacroiliac ligament or long sacral ligament (36,55,56) (Fig. 6). Radiofrequency procedures aimed at the lateral trunks seek to ablate the nerves prior to their being covered by the ligament. These loops are referred to as the sacrococcygeal plexus or the posterior sacral nerve plexus. The nerves of the plexus then pass through the gluteus maximus muscle and aponeurosis to become the middle cluneal nerves, innervating the skin inferior to the posterior superior iliac spine (9,14,29,34-36,41,55,57) (Fig. 5). A branch ultimately arising from L5 and S1 will run horizontally across the posterior sacroiliac ligament and pass through the gluteus maximus near its origin (29,34,35,41,45) (Figs. 4 and 5). Similar loops from S2, S3, and S4 join to make a branch with a similar or descending course, resulting in 1 to 2 cutaneous branches.

The middle cluneal nerves can be involved in pain arising from other structures, confusing the diagnostic

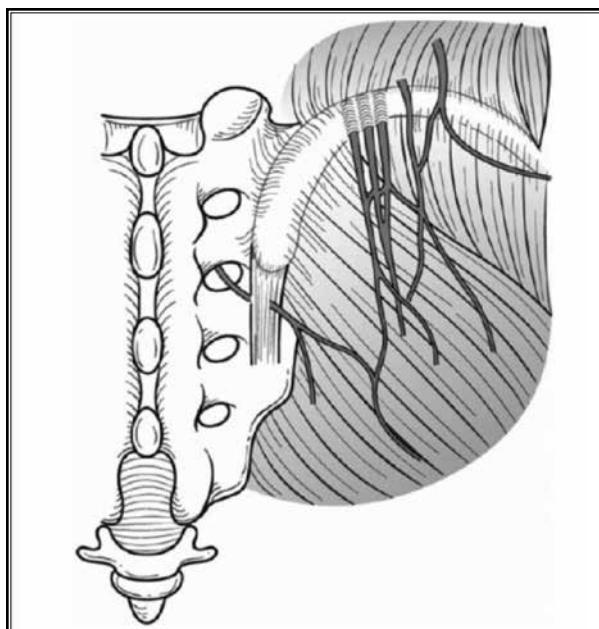


Fig. 6. Schematic overview of the typical course and potential entrapment locations of the superior and middle cluneal nerves. Branches of the superior cluneal nerves may be entrapped where they pierce the thoracolumbar fascia (TLF) at the iliac crest. Branches of the middle cluneal nerves may be entrapped where they pass under or through the long posterior sacroiliac ligament. From Aota Y. Entrapment of middle cluneal nerves as an unknown cause of low back pain. *World J Orthop.* 2016;7(3):167-170. (25), with permission.

picture. They can send a branch to the SI joint or the posterior sacroiliac ligament and communicate with either the superior cluneal nerves or the superior gluteal nerve (33,58). The innervation of the posterior sacroiliac ligament provides evidence that the ligament is a potential pain generator (48).

Cox and Fortin, in describing the anatomic considerations for radiofrequency ablation of the sacral lateral branches, described the wide variability in the points at which these branches exit the dorsal sacral foramina (58). They further found that in 75% of the specimens, L5 contributed to the dorsal sacral plexus. Subsequently, Kikuta defined the middle cluneal nerves as starting at the point at which the branches pierce the gluteus maximus. Proximally, they are labeled the medial and lateral trunks of the posterior sacrocygeal plexus (48,55). This nomenclature brings the middle cluneal nerves in line with the superior cluneal nerves, which arise upon passing through the dorsal thoracolumbar fascia and crossing the iliac crest.

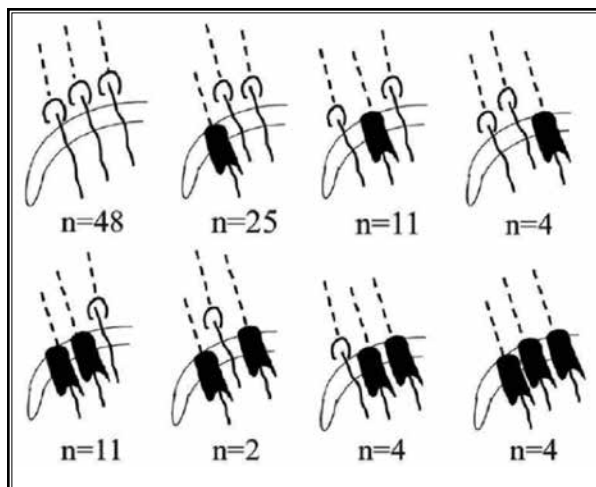


Fig. 7. Schematic variations in the running patterns of the branches of the SCN around the iliac crest (n = 109). Numbers of specimens with each course are indicated. Dotted lines = SCN branches under the thoracolumbar fascia (TLF); black semicylindrical areas = the fibro-osseous tunnel; solid lines = branches exiting from the TLF into subcutaneous tissues. From Kuniya H, Aota Y, Saito T, et al. Anatomical study of superior cluneal nerve entrapment. *J Neurosurg Spine.* 2013;19(1):76-80. (18), with permission.

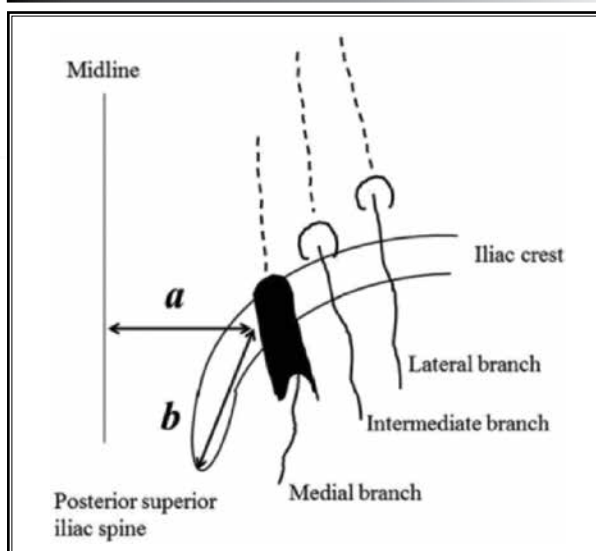
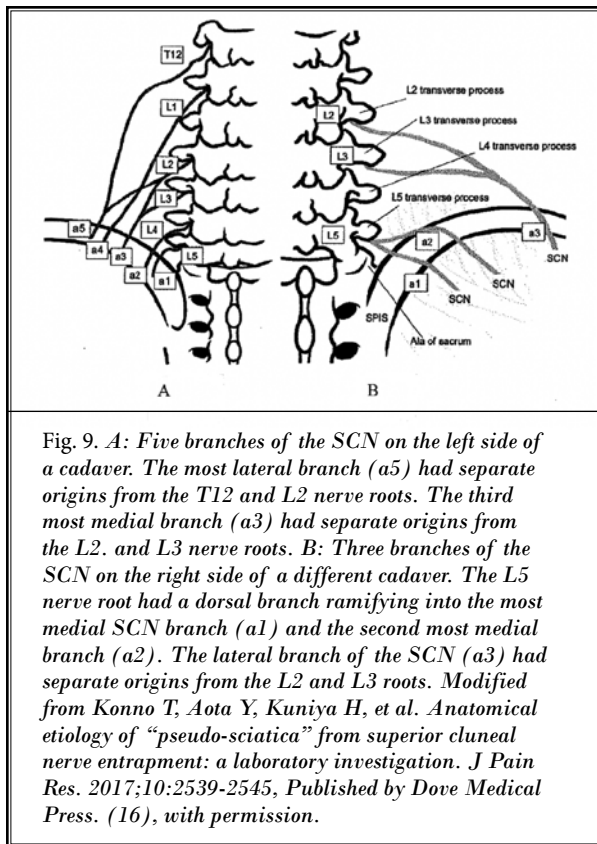


Fig. 8. Schematic illustration of measurements for linear distances from the midline (distance a) and the posterior superior iliac spine (distance b) to a branch of the SCN coursing over the iliac crest in a specimen in which the medial branch of the right SCN runs through an osteofibrous tunnel (black semicylindrical area). From Kuniya H, Aota Y, Saito T, et al. Anatomical study of superior cluneal nerve entrapment. *J Neurosurg Spine.* 2013;19(1):76-80. (18), with permission.



### Cluneal Nerve Induced Low Back and Leg Pain: Causes and Pathophysiology

Iatrogenic injury to the superior cluneal nerves caused by bone graft harvesting from the posterior iliac crest used to be a common cause of postoperative pain (59,60). With the increased use of cadaver allografts or synthetic bone substitutes, the incidence of surgical iatrogenic injury has lessened (61). Superior cluneal neuralgia is more likely now to be the result of nerve entrapment rather than injury (13).

As with estimates of incidence from other causes of low back pain, studies have found a wide variation in estimates of the incidence of low back and/or leg pain caused by superior cluneal nerves dysfunction, ranging from 1.6% to 14% (16,50,62). Isu cites Japanese language studies indicating that the incidence of bilateral superior cluneal nerve entrapment was between 20% and 33% (63).

Recent studies have identified the middle cluneal nerves as an additional potential source of low back or leg pain (14,29,30,35,63).

Nerve entrapment usually results from the combination of several types of trauma, such as traction,

friction, and repetitive compression. An example is the case report of superior cluneal nerve entrapment in an elite cricket player (64). These stresses lead to edema, inflammatory cell infiltration, and scarring in the tissue surrounding the nerve, interfering with its normal sliding movement (65).

Contraction of the latissimus dorsi and gluteus maximus can increase tension in the thoracolumbar fascia, providing a second site of entrapment (66,67). Conditions associated with increased muscle tone, such as Parkinson's disease or vertebral body fracture, or increased stretching are associated with an increased incidence of superior cluneal nerve entrapment (27).

The middle cluneal nerves are often narrowed where they pass under or through the posterior sacroiliac ligament, putting them at risk for entrapment and pain. The nerves at this point may show marked narrowing. Further, the gluteus maximus and the skin stretch over a large range when the hip joint is flexed and extended, especially during sports activities, providing a further mechanism for entrapment. When the middle cluneal nerves pass the aponeurosis of the gluteus maximus, this repeated and extensive stretching places the nerves at risk for entrapment (33,55).

Nerve root irritation from foraminal stenosis or a herniated disc at T12, L1, or L2 can cause pain radiating to the iliac crest, thereby setting up the conditions for a "double crush," a situation in which a nerve that is compromised in one region is more vulnerable when it is injured in another (68,69). If one of the many intermediate branches of the dorsal ramus has been injured by a needle during a paramedian approach to the epidural space, it may also contribute to a double crush phenomenon (32).

### Differential Diagnosis

The differential diagnosis of low back and buttock pain with or without radiation to the leg is extensive (70). The described pain can be the result of injury to one or more of the many structures in that area, including vertebrae, intervertebral discs, nerve roots, facet or sacroiliac joints, muscles, ligaments, and peripheral nerves.

Potential sources of pain that are relatively easy to image, such as intervertebral disc protrusions, compression fractures, and spinal stenosis, have received the most attention. Given that therapy for these diagnoses often fails, we must consider the role of other structures as pain generators. It is essential to remember that about 1/3 of patients with significant pathology on MRI are asymptomatic (71,72).



A complete discussion of the evaluation and treatment of all these sources is beyond the scope of this paper; rather, our purpose is to encourage explicit inclusion of the superior and middle cluneal nerves in the differential diagnosis. The contribution of these nerves to low back and buttocks pain is relatively easy to diagnose on physical examination if the examiner is thinking of them.

Table 1 presents a brief compendium of the differential diagnosis of low back and/or leg pain. Some of these differential diagnoses, such as facet or sacroiliac arthropathy, piriformis syndrome, and myofascitis, are at the core of interventional pain management. Others, such as iliolumbar syndrome (73,74), gluteus medius syndrome (75-79), inferior cluneal nerve entrapment (80), and Maigne's syndrome (81-84), are less familiar but are diagnoses with which the interventionalist should be familiar.

Weakness of the gluteus medius muscle or injury to its aponeurosis are rare but easily treated causes of buttocks pain.

Maigne's syndrome, or thoracolumbar syndrome, is a heterogeneous term that includes arthropathy of various facet joints, most specifically T12-L1, and entrapment of the medial branch of the superior cluneal nerve. The T9-L1 facet joints are known as transitional zone joints because the thoracic facets are in the frontal plane, suitable for rotation, while the lumbar facets are in the sagittal plane, suitable for flexion (85). This disharmony of structure is hypothesized to leave the joints (particularly T12-L1) exposed to arthropathy and subluxation, with referred pain to the back, hip, or groin. A recent study documented a high incidence (40%) of degenerative disc disease and endplate changes at this level in elite gymnasts (86). Blockade of the T12-L1 facet joint (although neighboring joints can be involved) is diagnostic. Maigne also described relief of pain with injection of the medial branch of the superior cluneal nerves (87), although it is likely that thoracolumbar syndrome and medial branch entrapment are distinct entities (83,88).

The iliolumbar ligament, which passes from the iliac crest to the transverse process of L4 and L5, has been hypothesized as a cause of low back pain. Maigne specifically differentiated iliolumbar ligament syndrome from superior cluneal nerve entrapment (87). While the ligament has recently been shown to not have a nerve supply (74), the adjacent tissues are richly innervated so that the concept of iliolumbar ligament syndrome remains, with local anesthetic injections or regenerative injection therapy as treatment options.

Table 1. *Differential Diagnosis of low back and/or leg pain*

<b>Etiology of Pain</b>	<b>Potential Distinguishing Factors</b>
<b>Lumbar Spine Disorders</b>	
Vertebral Fractures	Local pain in the affected area, aggravated by palpation with chronicity of fracture, confirmed by MRI or Bone Scan.
Lumbar Disc Disease/spinal stenosis	Physical exam and MRI concordant with diagnosis. Dermatomal sensory, motor, or reflex changes.
Facet Joint Disorders	Pain relief with diagnostic medial branch injections.
Thoracolumbar Junction Syndrome (Maigne Syndrome) (81-84)	Pain in the distribution of T12 or L1, relieved by diagnostic facet injection; term is also used to describe entrapment of the medial branch of the superior cluneal nerve.
Sacroiliac Joint Disorders	Axial low back pain with confirmatory signs on physical exam, such as FABERs, Gaenslen, pelvic compression, and distraction, with relief with diagnostic testing.
Iliolumbar syndrome	Unilateral low back pain produced by hip flexion and FABER. Confirmed by local anesthetic injection into the iliolumbar ligament.
<b>Myofascial Pain Syndromes</b>	
Paraspinal myofascitis	Spasm or trigger points in the muscle, relieved by trigger point injections.
Gluteus medius muscle pain or compartment syndrome	Trigger point in the gluteus medius replicating the low back or leg pain, relieved with either injections or release of the gluteus medius aponeurosis.
Piriformis syndrome	Pain with palpation of the piriformis muscle, relieved by injection into the muscle.
<b>Nerve entrapments</b>	
Inferior cluneal (posterior femoral cutaneous) nerve entrapment	Pain at the ischium with sitting, relieved by local anesthetic injections.

**Physical Examination**

The physical examination should begin by examining the thoracolumbar region, looking for physical findings suggesting the anatomic basis for the pain. The most common causes are lumbar facet and sacroiliac joint disorder, in addition to the cluneal nerves, but all of the items in the differential diagnosis should be considered.

Segmental examination may provide evidence of the level of thoracolumbar dysfunction even when the patient is pain free (82). Gentle lateral pressure in each horizontal direction on the spinous processes may produce pain in one direction, an indication of facet

joint dysfunction. Deep palpation of these joints using firm pressure down a line parallel to and 1 cm lateral to either side of the spinous processes can also reveal a tender region at an abnormal joint. These examination techniques are not usually painful in the absence of joint pathology.

Rolling a fold of skin between the examiner's fingers almost always leads to pain in the area of skin supplied by a particular injured dorsal ramus branch, a finding Maigne described as the neurotrophic reflex. The response should be compared to that of the other side and of surrounding areas. A positive skin test over the lower abdomen/inguinal canal (inguinal nerve) or greater trochanter (lateral perforator nerve) may indicate a more proximal spinal nerve injury (82).

Examination of the paraspinal and gluteal muscles may reveal cords of muscle in spasm with or without tender trigger points (89). Palpation with enough pressure to blanch the examiner's nail may reproduce the patient's pain complaint (75). Palpate the gluteus medius from its insertion on the greater trochanter toward the posterior superior iliac spine and over its origin along the ilium just below the iliac crest to look for gluteus medius weakness or nerve entrapment by its aponeurosis.

A more focused search for dysfunction of specific nerves should begin by searching for the maximally tender point at which the pressure of the examiner's finger reproduces the patient's pain. The descriptive "tender points" is useful for areas where patients say "ouch" when you push on them. All trigger points are tender points, but not all tender points are trigger points: they could be nerves, tendons, bursas, or other structures. Frequently, the symptoms of entrapment of the medial branch of the superior cluneal nerves can be reproduced by palpation of the iliac crest approximately 7 cm lateral to the midline, although there may be variability in the location based upon patient size (87,90). This tender point may elicit pain radiating from the low back to the posterior thigh, consistent with the distribution of the superior cluneal nerves. Pain may also be elicited with hyperextension, lateral bending towards the side opposite the complaint, and rotation of the lumbar spine. Aly et al (91) proposed simultaneous full flexion of the ipsilateral hip and knee joints as a provocative test that reproduces symptoms, but this test may not be specific.

Symptoms of entrapment of the middle cluneal

nerves may be reproduced by pressure on the posterior sacroiliac ligament, approximately 3.5 cm caudal to the posterior superior iliac spine, with numbness and radiating pain when this site is palpated (29,30). This site is distinct from that of the Fortin finger test (pressure 1 cm below the posterior superior iliac spine) for sacroiliac joint dysfunction (92) in that it is slightly more caudal. In practical terms, this area contains many potential pain-generating structures, and further diagnostic injections may be needed to refine the diagnosis.

The frequent communication between these nerves at all levels and the variability between subjects and between the right and left sides of the same subject underline the importance of the physical examination and low volume local anesthetic injections in leading to an accurate diagnosis.

### **Confirmation of the Clinical Diagnosis of Entrapment of the Cluneal Nerves**

The suggestion of superior cluneal nerves entrapment neuropathy found on clinical exam can be supported by a diagnostic local anesthetic injection, although the sensitivity and specificity of single local anesthetic injections of peripheral nerves have not been studied. North has suggested that diagnostic blockade of central structures may lack specificity (93). High resolution ultrasound of the tender areas may provide information as to anatomic abnormalities and is useful in ensuring the accuracy of diagnostic injections (94-96).

The diagnostic criteria for cluneal neuralgia are presented in Table 2. These criteria are supported by multiple authors (15,16,50,97).

Other authors have suggested that the diagnosis of middle cluneal nerves entrapment neuropathy include a tender point 3-4 cm caudal to the posterior superior iliac spine (PSIS) (29,30).

Obtaining plain x-rays to check for vertebral body compression fractures is prudent since, in Kuniya's analysis, a superior cluneal nerves entrapment diagnosis was seen more frequently in patients with vertebral fractures than in patients without compression fractures (16,27). Ultrasound is being used more frequently for the diagnosis of entrapment neuropathies as well as for the diagnostic injections (vide infra) (98,99).

The most important part of the diagnosis of neuropathy of the superior or middle cluneal nerves is thinking of the possibility!

**Treatment**

**Non-invasive therapies**

Conservative approaches are the mainstay of the initial treatment of any pain condition, including nerve entrapments (100,101). Conservative approaches include non-scheduled medications, physical and chiropractic therapy, and acupuncture. A review of conservative treatments is beyond the scope of this paper.

**Injection**

Injections can be performed using landmark, fluoroscopy, or ultrasound guidance.

**Landmark-Guided Technique**

With the patient standing flexed at the hips or in a prone position, palpate and mark the posterior iliac crest 6-7 cm lateral from the midline to determine the point of maximum tenderness. Using aseptic technique, advance a 1.5 to 2 inch 25- to 22-gauge needle perpendicularly to the skin until the bone is contacted. For diagnostic purposes, following negative aspiration, inject 1 mL of a local anesthetic/steroid solution. A peripheral nerve stimulator may also help to identify the proper site of injection (65). In one report, 4 of 8 patients with entrapment of the medial branch of the superior cluneal nerves and Parkinson’s disease achieved satisfactory pain reduction using landmark-guided injections of 2 cc of 1% lidocaine (28). Herring et al also described a landmark-guided superior cluneal nerve block to provide analgesia for a buttocks abscess drainage (102).

The middle cluneal nerves do not have a landmark-guided approach described in the literature. However, consistent with the physical exam locating the middle cluneal nerves by finding the site of maximal tenderness with palpation medial and just inferior to the posterior superior iliac spine, it is likely that “blind SI joint injections” are actually middle cluneal nerve injections (103).

**Fluoroscopy-Guided Technique**

Under fluoroscopy, the point of maximum tenderness for superior cluneal nerves neuropathy is usually found at the medial iliac crest, and a traction spur of the attachment of the iliolumbar ligament can occasionally be seen (Fig. 10). Palpate the area to confirm the target and inject 1 mL of a local anesthetic/steroid solution on the top of the iliac crest. Nerve stimulation localization devices can help to confirm the proper needle placement.

The middle cluneal nerves can have multiple sacral contributions. However, since it is primarily centered at

Table 2. *Diagnostic Characteristics of Cluneal Neuralgia*

Physical Exam	Symptoms of entrapment may be reproduced by palpation of tender points, hyperextension, or lateral bending to the side opposite the complaints.
Diagnostic injection	May be done with 1 cc of local anesthetics, using either landmarks, ultrasound, or fluoroscopic guidance.
Ultrasound	The nerves appear as small, hypoechoic structures just inferior to the border of the iliac crest.
X-ray	Non-specific. Useful in ruling out other causes of low back/leg pain. The presence of vertebral compression fractures should increase the level of suspicion for superior cluneal nerves entrapment (19).
MRI	Non-specific. Useful in ruling out other causes of low back/leg pain.
CT scan	May show a bony groove at the osteofibrous tunnel (18).
Electrodiagnostic studies	Not useful.

S2, 1 mL of local anesthetic/steroid at the lateral border of the S2 foramen is usually sufficient (Fig. 11).

**Ultrasound-Guided Technique**

The patient is placed in a prone position. Palpate the posterior wing of the iliac crest approximately 6-7 cm lateral to the midline and mark the area. A high-frequency linear array probe is placed at the marked site on the iliac crest in a transverse view. The iliac crest is seen as a bony shadow. Moving the ultrasound (US) probe superior and posterior from this point will reveal the superior cluneal nerves as small hypoechoic structures inferior to the border of the iliac crest (Fig. 12). An in-plane or out-of-plane needle approach may be used. Bodner et al performed cadaveric studies confirming that the medial branch of the superior cluneal nerves could be identified under ultrasound (104). Nielsen demonstrated that the superior cluneal nerves could successfully be blocked using ultrasound (96).

Identification of the middle cluneal nerves can also be aided by the use of ultrasound (105). The posterior superior iliac spine, an area of variable size and shape, may be difficult to locate precisely by palpation, particularly in obese patients. Locate the most posterior and inferior point of the PSIS on ultrasound, then use this as a reference point to find the second sacral foramen (Fig. 13) approximately 2-3 cm medial to the PSIS, 45° below the horizontal line. The first sacral foramen is 1-1.5 cm above the second; the third is 1-1.5 cm below it.

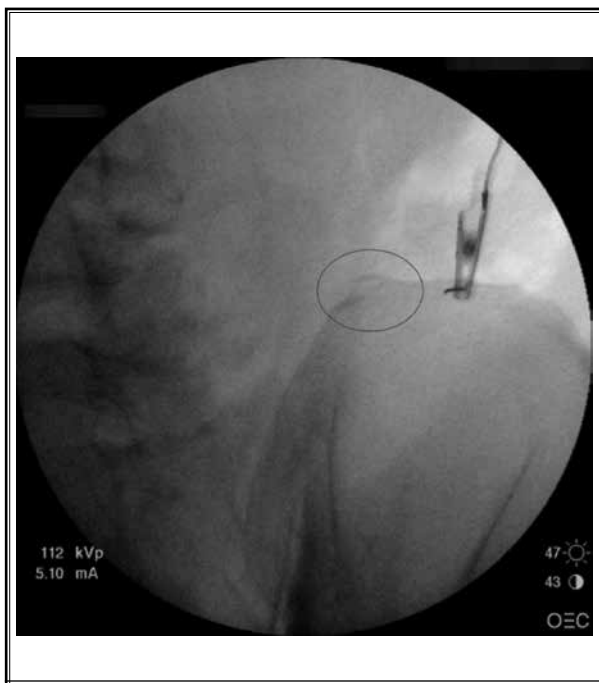


Fig. 10. Fluoroscopic injection of a superior cluneal nerve. An iliolumbar traction spur is circled. (Image courtesy of Andrea Trescot MD)

### Neurolysis

If pain relief from the diagnostic injection is complete but only temporary, longer lasting modalities such as cryoneuroablation, radiofrequency lesioning, and chemical neurolysis may be offered. Other options include peripheral nerve stimulation or surgery.

### Cryoablation

Cryoablation of the medial branch of the superior cluneal nerves may be performed using landmark, fluoroscopic, or ultrasound guidance. Cryoablation of the middle cluneal nerves should be done using either ultrasound or fluoroscopic imaging.

With the patient in a prone position, utilizing aseptic technique, infiltrate a small amount of local anesthetic subcutaneously using a small gauge 1.5-inch needle. Pass an introducer catheter with a sharp stylet to the target area. Use either a 12- or 14-gauge catheter, depending on the probe size. Remove the introducer stylet and advance the cryoprobe through the catheter to the target area (Figs. 14 and 15), using appropriate guidance. If necessary, pull the introducer catheter back to fully expose the tip of the probe so that the ice ball will form fully. Confirm proper probe placement on the

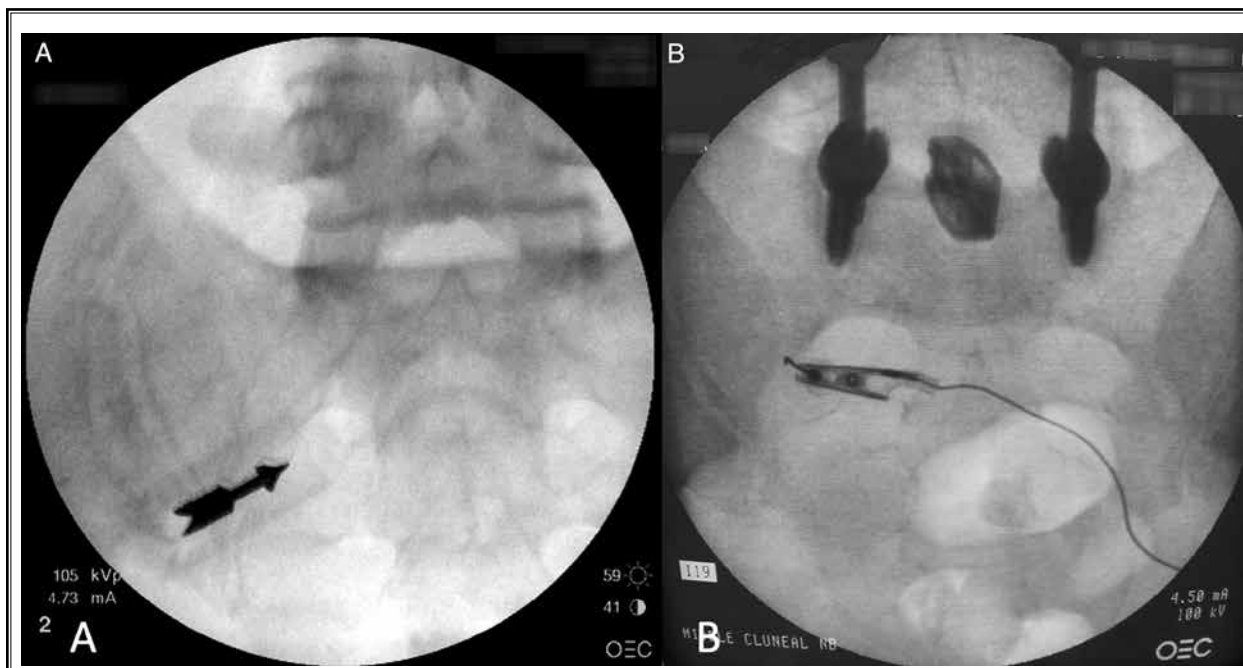
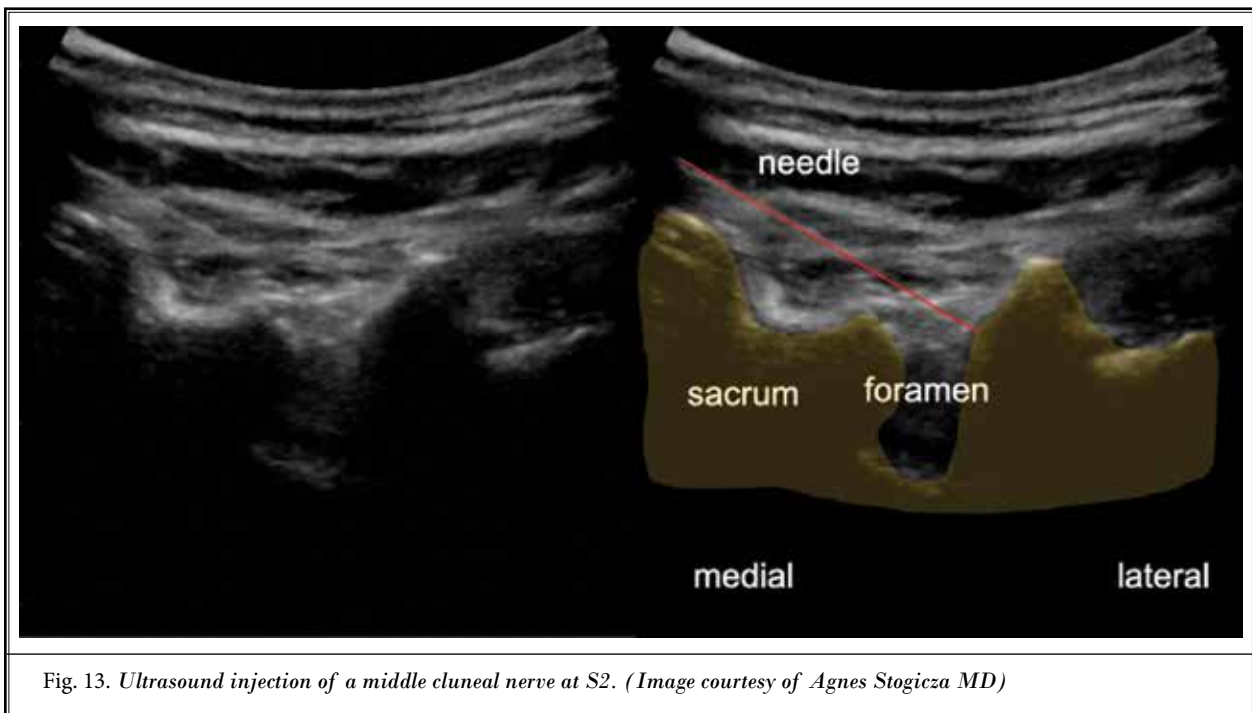
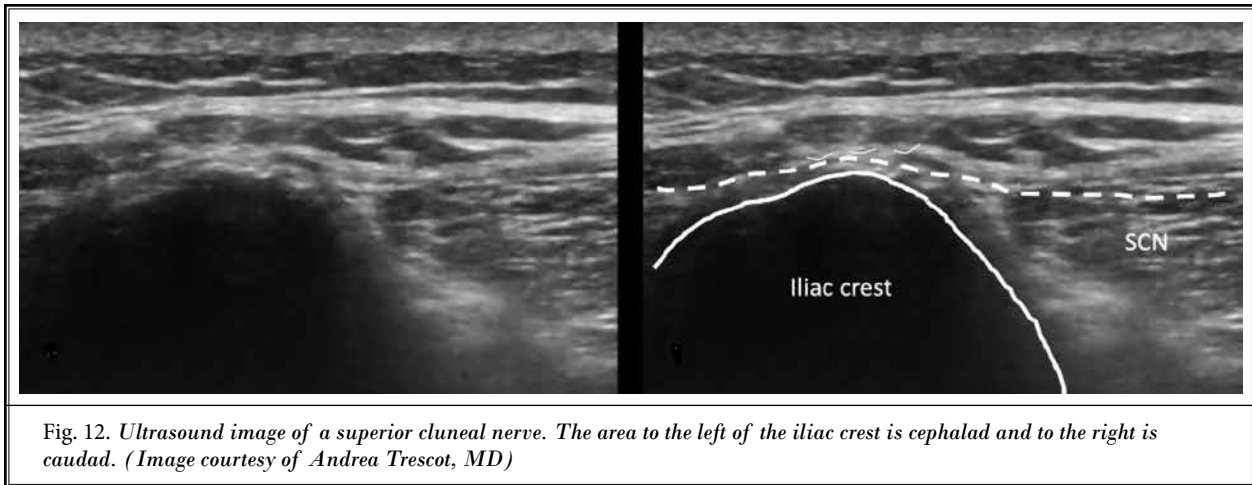


Fig. 11. Fluoroscopic injection of a middle cluneal nerve. A: Marker showing the lateral border of S2. B: Needle with nerve stimulator at the lateral border of S2, the site of the middle cluneal nerve injection. (Image courtesy of Andrea Trescot MD)



nerve by identifying maximal sensory stimulation and the lack of motor stimulation. Neurolysis results from a series of 2, 2-minute freezes, with 30 seconds of defrosting between each cycle. There may be burning pain that replicates the initial pain on initiation of the first freeze cycle, but this should resolve within approximately 30 seconds (13), though this can be obviated by using a side-port injection introducer (106).

#### Radiofrequency Lesioning

A technique very similar to that described above

for cryoablation has been used for radiofrequency lesioning. The target is identified, and the site sterilely prepped appropriately. After local anesthetic is infiltrated subcutaneously, the radiofrequency probe is advanced to the target site at the iliac crest or lateral S2 foramen using fluoroscopy, ultrasound, or, for the medial branch of the superior cluneal nerves, anatomical landmarks. After the radiofrequency probe is in place, the presence of sensory stimulation and absence of motor stimulation is used to confirm that the tip of the probe is placed adequately. A lesion is made using the

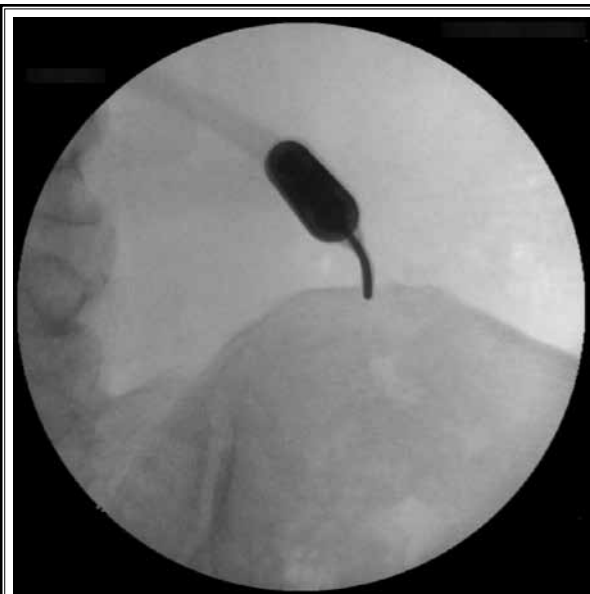

Fig. 14. Cryoneuroablation of a superior cluneal nerve. (Image courtesy of Andrea Trescot MD)

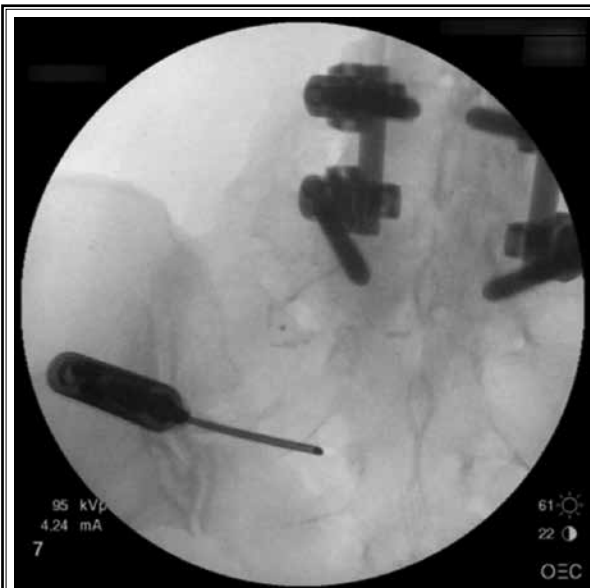


Fig. 15. Cryoablation of a middle cluneal nerve. (Image courtesy of Andrea Trescot MD)

same parameter that the practitioner would use for medial branch ablation procedures.

Relief of symptoms from middle cluneal neuralgia has been reported with the use of radiofrequency (58). Internally cooled probes create larger lesions and have also been used at the sacral sites.

### Neurolysis with Alcohol or Phenol

Alcohol neurolysis has been studied for the treatment of persistent pain caused by the entrapment of the medial branch of the superior cluneal nerves using 1 mL of 0.5% lidocaine followed by 1 mL of absolute alcohol (100%) via the same cannula. If after 1 week the pain was not resolved, the procedure was repeated. The 4 described patients were observed up to 4 years; none reported complications or recurrent pain (107).

### Peripheral Nerve Stimulation

Until recently, peripheral nerve stimulation was limited in its use because of the need to use an implantable power generator with extensions that had to be tunneled from the target nerve to an area with enough tissue to hold the generator. The recent advent of a variety of wireless peripheral nerve stimulator systems has dramatically expanded the feasibility of peripheral nerve stimulation. Since the technology is new, there is relatively little literature currently available, though several articles and posters have been published recently (108-110).

For the medial branch of the superior cluneal nerves, a stimulator is placed across the top of the iliac crest (Fig. 16). The middle cluneal nerves are stimulated by placing the stimulator lateral to the foramen and medial to the sacroiliac joint (Fig. 17). The stimulator is tunneled to a small subcutaneous pocket, where it is coiled and sutured to the fascia and then connected wirelessly to the external power pack and a wearable antenna assembly (WAA).

### Surgery

Surgery is considered when repeated superior cluneal nerves procedures fail to control the patient's symptoms (17,22,25,50,51,64,97). An early report of surgical intervention described extensive dissection under local anesthesia of the area surrounding and including the tender point; nerves identified as painful in response to pressure by the surgeon's finger were sectioned (9). In another paper, 34 patients underwent surgical release under local anesthesia; in all of the patients, the superior cluneal nerves penetrated the orifice of the thoracolumbar fascia and could be released by dissection of the fascia (25). Others reported successful outcomes under general anesthesia (GA) (50,64,97). Kuniya et al described an extensive decompression under GA, tracing several superior cluneal nerve branches from the lateral margin of the deep layer of the thoracolumbar fascia to their exit into the subcutaneous tissue. They also removed

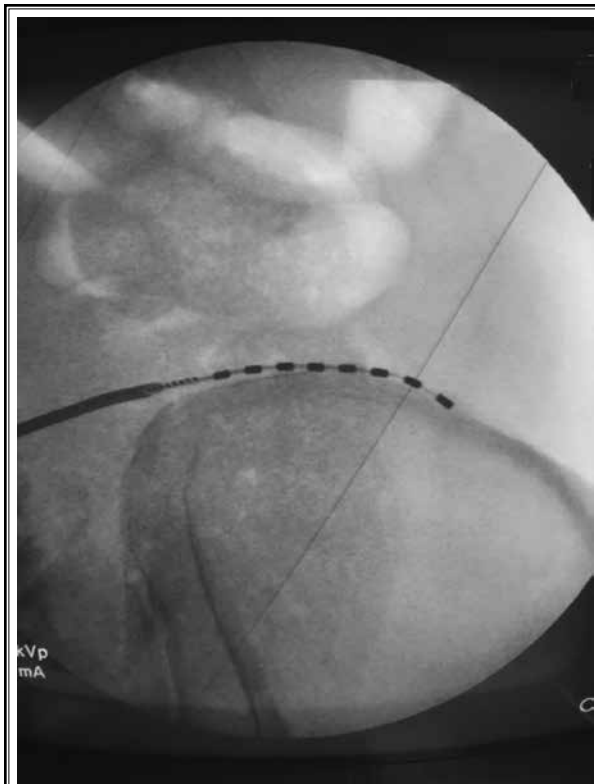


Fig. 16. *Peripheral nerve stimulation of a superior cluneal nerve (Image courtesy of Andrea Trescot, MD)*

a portion of the iliac crest “approximately fingertip in size” to ensure complete decompression (16).

A particular problem in surgery for cluneal nerve syndrome is that identification of these very small nerves within the fatty subcutaneous tissue is difficult. Surgeons have used patient reports that their symptoms are reproduced by pressure of the surgeon’s finger (9,17,25), nerve stimulators (25), or indocyanine green video angiography to find these nerves and document sufficient decompression (22). Operating microscopes have also been used (16,17,22,25,27,64).

Results of these intraoperative techniques are also used to help the surgeon choose between neurolysis and neurectomy (23). “Neurolysis” can be a confusing term; one must distinguish between lysis of adhesions in the fascia around a nerve and lysis of the nerve itself by chemical or physical methods (vide supra). Lysis of adhesions around an entrapped superior cluneal nerve is performed by cutting the thoracolumbar fascia from distal to rostral until the nerve is seen to be free of kinks, no longer responds to digital pressure, or indocyanine green video angiography shows good blood

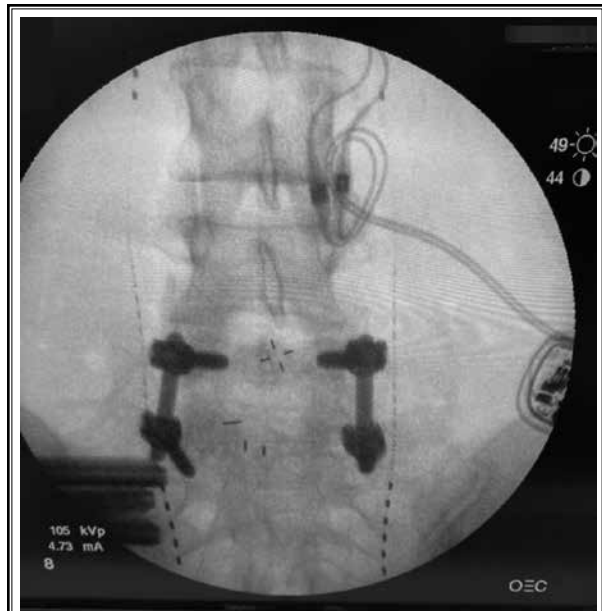


Fig. 17. *Bilateral peripheral nerve stimulation of the middle cluneal nerves. Note the lumbar fusion and the spinal cord stimulator as well as the left sacroiliac fusion. (Image courtesy of Jocelyn Bush MD, with permission).*

flow in the small vessels, the vasa nervorum, around the nerves (22). “Neurectomy” involves cutting the nerve and is often used when the neurolysis has failed to alleviate the patient’s symptoms (17).

Postoperative recurrence is, at least in part, technique-dependent; additional unidentified branches may be present, or an identified branch may be insufficiently released. Some surgeons recommend wide release under general anesthesia. Others recommend neurolysis of as many branches as possible during the initial procedure (17). Very elderly and/or fragile patients may especially benefit from a trial of a more limited procedure under local anesthesia (17,24,25).

Surgery has also been reported to relieve symptoms of entrapment of the middle cluneal nerves (9,18,29,30).

### Complications

As with all interventional techniques, precautions regarding anticoagulant therapy and proximity to vascular structures and other cavities are critical. In general, complications are based on the location of the needle, neural trauma, and bleeding. Infectious complications include abscess. Standard precautions regarding the use of local anesthetics and steroids should be maintained.

If using landmarks only for performing a procedure, care must be taken to keep the needle on the iliac crest.

Depigmentation or hyperpigmentation at a cryolesion site has been reported (111).

Reported complications of radiofrequency ablation include a worsening of the usual pain, burning or dysesthesias, decreased sensation, and allodynia over the skin (105).

Alcohol and phenol are fluids that can spread to unintended locations, leading to potentially devastating consequences. The use of fluoroscopy is strongly encouraged to minimize the risk of undesired spread. Since these medications are designed to destroy tissue, tissue sloughing and infarcts are potential complications. Clearing the needle prior to withdrawal may decrease the risk of superficial tissue damage. Although temporary local pain at the injection site is to be expected, prolonged pain at the injection site may represent neuritis.

## DISCUSSION

Many authors have noted the importance of considering structures other than the intervertebral discs as potential sources of low back pain. Entrapment or injury of the lateral branches of the dorsal rami of T11-S4 can be a cause of severe, debilitating low back and/or leg pain. Understanding the long and complex path of these nerves is key to evaluating a given clinical picture. The clinical triad which defines cluneal nerve neuropathy includes deeply aching and poorly localized low back pain with a variable pattern of referred pain in the buttocks and/or legs, the presence of a tender

point at the iliac crest or caudal to the PSIS, and relief of symptoms by a low-dose injection of local anesthetics at the tender point. Notable by their absence are the dermatomal sensory changes and muscle weakness that would be seen with disc abnormalities or spinal stenosis.

Having the patient point to the site of pain can help to diagnose this treatable cause of low back pain. When clinical features lead to suspicion of cluneal neuralgia, relief of pain after an injection of a low volume of local anesthesia into presumed areas of entrapment provides confirmation of the diagnosis.

If injury to the superior or middle cluneal nerves is the cause of a patient's symptoms, a relatively simple, low-morbidity procedure may provide long-lasting relief.

## CONCLUSION

Over more than a century, the long and complex course of the relatively small lateral branches of the lower thoracic, lumbar, and sacral dorsal rami has led to often confusing representations of their anatomy. This modified scoping review has clarified these discrepancies and serves as a basis for a greater appreciation of the role of their cutaneous terminal branches, the superior and middle cluneal nerves, as possible causes of a patient's low back, buttock, and/or leg pain. Although it is a relatively rare cause of low back pain, superior and middle cluneal nerve entrapment is under-recognized and therefore undertreated. This lesion should be included as part of the differential diagnosis of low back pain, even in the presence of buttock or leg pain.

## REFERENCES

1. Deyo RA, Weinstein JN. Low back pain. *N Engl J Med* 2001; 344:363-370.
2. Chou R, Qaseem A, Snow V, et al. Diagnosis and treatment of low back pain: a joint clinical practice guideline from the American College of Physicians and the American Pain Society. *Ann Intern Med* 2007; 147:478-491.
3. Kuslich SD, Ulstrom CL, Michael CJ. The tissue origin of low back pain and sciatica: a report of pain response to tissue stimulation during operations on the lumbar spine using local anesthesia. *Orthop Clin North Am* 1991; 22:181-187.
4. Hansen HC, Helm S. Sacroiliac joint pain and dysfunction. *Pain Physician* 2003; 6:179-189.
5. Trescot AM. *Peripheral nerve entrapments: clinical diagnosis and management*. Springer, Switzerland, 2016.
6. Helm S, Shirsat N, Calodney A, et al. Peripheral nerve stimulation for chronic pain: a systematic review of effectiveness and safety. *Pain Ther* 2021; 10:985-1002.
7. Moore DC. *Regional Block*. Charles C Thomas, Springfield, IL, 1953.
8. classics@fas.harvard.edu. Both cluneal and clunial are acceptable spellings. Harvard Department of Classics.
9. Strong EK, Davila JC. The cluneal nerve syndrome; a distinct type of low back pain. *Ind Med Surg* 1957; 26:417-429.
10. Bogduk N. Proceedings: the lumbosacral dorsal rami of the monkey and dog. *J Anat* 1974; 118:393-394.
11. Bogduk N. Lumbar dorsal ramus syndrome. *Med J Aust* 1980; 2:537-541.
12. Bogduk N, Wilson AS, Tynan W. The human lumbar dorsal rami. *J Anat* 1982; 134:383-397.
13. Trescot AM. Cryoanalgesia in interventional pain management. *Pain Physician* 2003; 6:345-360.
14. Konno T, Aota Y, Kuniya H, et al. Anatomical etiology of "pseudosciatica" from superior cluneal nerve entrapment: a laboratory investigation. *J Pain Res* 2017; 10:2539-2545.
15. Kuniya H, Aota Y, Saito T, et al. Anatomical study of superior cluneal nerve entrapment. *J Neurosurg Spine* 2013; 19:76-80.
16. Kuniya H, Aota Y, Kawai T, Kaneko K, Konno T, Saito T. Prospective study of



- superior cluneal nerve disorder as a potential cause of low back pain and leg symptoms. *J Orthop Surg Res* 2014; 9:1-12.
17. Morimoto D, Isu T, Kim K, et al. Long-term outcome of surgical treatment for superior cluneal nerve entrapment neuropathy. *Spine* 2017; 42:783-788.
  18. Matsumoto J, Isu T, Kim K, Iwamoto N, Morimoto D, Isobe M. Surgical treatment of middle cluneal nerve entrapment neuropathy: technical note. *J Neurosurg Spine* 2018; 29:208-213.
  19. Steinke H, Saito T, Miyaki T, Oi Y, Itoh M, Spanel-Borowski K. Anatomy of the human thoracolumbar Rami dorsales nervi spinalis. *Ann Anat* 2009; 191:408-416.
  20. Arksey H, O'Malley L. Scoping studies: towards a methodological framework. *Int J Soc Res Methodol* 2005; 8:19-32.
  21. Levac D, Colquhoun H, O'Brien KK. Scoping studies: advancing the methodology. *Implement Sci* 2010; 5:1-9.
  22. Kim K, Isu T, Chiba Y, et al. The usefulness of ICG video angiography in the surgical treatment of superior cluneal nerve entrapment neuropathy: technical note. *J Neurosurg Spine* 2013; 19:624-628.
  23. Kim K, Shimizu J, Isu T, et al. Low back pain due to superior cluneal nerve entrapment: a clinicopathologic study. *Muscle Nerve* 2018; 57:777-783.
  24. Kokubo R, Kim K, Isu T, et al. Superior cluneal nerve entrapment neuropathy and gluteus medius muscle pain: their effect on very old patients with low back pain. *World Neurosurg* 2017; 98:132-139.
  25. Morimoto D, Isu T, Kim K, et al. Surgical treatment of superior cluneal nerve entrapment neuropathy. *J Neurosurg Spine* 2013;19: 71-75.
  26. Chiba Y, Isu T, Kim K, et al. Association between intermittent low-back pain and superior cluneal nerve entrapment neuropathy. *J Neurosurg Spine* 2016; 24:263-267.
  27. Kim K, Isu T, Chiba Y, et al. Treatment of low back pain in patients with vertebral compression fractures and superior cluneal nerve entrapment neuropathies. *Surg Neurol Int* 2015; 6:S619-S621.
  28. Iwamoto N, Isu T, Kim K, et al. Low back pain caused by superior cluneal nerve entrapment neuropathy in patients with Parkinson disease. *World Neurosurg* 2016; 87:250-254.
  29. Aota Y. Entrapment of middle cluneal nerves as an unknown cause of low back pain. *World J Orthop* 2016; 7:167-170.
  30. Kim K, Isu T, Matsumoto J, Yamazaki K, Isobe M. Low back pain due to middle cluneal nerve entrapment neuropathy. *Eur Spine J* 2018; 27:309-313.
  31. Saito T, Steinke H, Miyaki T, et al. Analysis of the posterior ramus of the lumbar spinal nerve: the structure of the posterior ramus of the spinal nerve. *Anesthesiology* 2013; 118:88-94.
  32. Saito T, Yoshimoto M, Yamamoto Y, et al. The medial branch of the lateral branch of the posterior ramus of the spinal nerve. *Surg Radiol Anat* 2006; 28:228-234.
  33. Konno T, Aota Y, Saito T, et al. Anatomical study of middle cluneal nerve entrapment. *J Pain Res* 2017; 10:1431-1435.
  34. Sittitavornwong S, Falconer DS, Shah R, Brown N, Tubbs RS. Anatomic considerations for posterior iliac crest bone procurement. *J Oral Maxillofac Surg* 2013; 71:1777-1788.
  35. Tubbs RS, Levin MR, Loukas M, Potts EA, Cohen-Gadol AA. Anatomy and landmarks for the superior and middle cluneal nerves: application to posterior iliac crest harvest and entrapment syndromes. *J Neurosurg Spine* 2010; 13:356-359.
  36. McGrath MC, Zhang M. Lateral branches of dorsal sacral nerve plexus and the long posterior sacroiliac ligament. *Surg Radiol Anat* 2005; 27:327-330.
  37. Aizawa Y, Kumaki K. The courses and the segmental origins of the cutaneous branches of the thoracic dorsal rami. *Kaibogaku zasshi* 1996; 71:195-210.
  38. Yazaki S, Ohwaki Y, Urata S, Watanabe K. Chronic posterior iliac crest donor site pain and anatomic considerations for superior cluneal nerves. *Seikei Geka* 1997; 48:397-403.
  39. Moro T, Kikuchi S, Kon-no S, Aoki, Y. Anatomy study of the superior cluneal nerves. The prevention of nerve injury when harvesting bone from the posterior iliac crest. *Rinsho Seikei Geka* 2007; 42:101-104.
  40. Kuniya H, Aota Y, Nakamura N, et al. Low back pain patients with suspected entrapment of the superior cluneal nerve. *J Spine Res* 2011; 21:1032-1035.
  41. Johnston HM. The cutaneous branches of the posterior primary divisions of the spinal nerves, and their distribution in the skin. *J Anat Physiol* 1908; 43:80-92.
  42. Lau P, Mercer S, Govind J, Bogduk N. The surgical anatomy of lumbar medial branch neurotomy (facet denervation). *Pain Med* 2004; 5:289-298.
  43. Bogduk N. Proceedings: the posterior lumbar muscles and nerves of the cat. *J Anat* 1973; 116:476-477.
  44. Bogduk N. A reappraisal of the anatomy of the human lumbar erector spinae. *J Anat* 1980; 131:525-540.
  45. Maigne JY, Lazareth JP, Guérin Surville H, Maigne R. The lateral cutaneous branches of the dorsal rami of the thoraco-lumbar junction. An anatomical study on 37 dissections. *Surg Radiologic Anatomy* 1989; 11:289-293.
  46. Maigne R. Low back pain of thoracolumbar origin. *Arch Phys Med Rehabil* 1980; 61:389-395.
  47. Iwanaga J, Simonds E, Patel M, Oskouian RJ, Tubbs RS. Anatomic study of superior cluneal nerves: application to low back pain and surgical approaches to lumbar vertebrae. *World Neurosurg* 2018; 116:e766-e768.
  48. Kikuta S, Iwanaga J, Watanabe K, Tubbs RS. Revisiting the middle cluneal nerves: an anatomic study with application to pain syndromes and invasive procedures around the sacrum. *World Neurosurg* 2019; 127:e1228-e1231.
  49. Dellon AL. Pain with sitting related to injury of the posterior femoral cutaneous nerve. *Microsurgery* 2015; 35:463-468.
  50. Maigne JY, Doursounian L. Entrapment neuropathy of the medial superior cluneal nerve. Nineteen cases surgically treated, with a minimum of 2 years' follow-up. *Spine (Phila Pa 1976)* 1997; 22:1156-1159.
  51. Berthelot JM, Delecricin J, Maugars Y, Caillon F, Prost A. A potentially underrecognized and treatable cause of chronic back pain: entrapment neuropathy of the cluneal nerves. *J Rheumatol* 1996; 23:2179-2181.
  52. Iwanaga J, Simonds E, Schumacher M, Yilmaz E, Altafulla J, Tubbs RS. Anatomic study of the superior cluneal nerve and its related groove on the iliac crest. *World Neurosurg* 2019; 125:e925-e928.
  53. Iwanaga J, Simonds E, Schumacher M, Oskouian RJ, Tubbs RS. Anatomic study of superior cluneal nerves: revisiting the contribution of lumbar spinal nerves. *World Neurosurg* 2019; 128:e12-e15.
  54. Myers BD. *The History of Medical Education in Indiana*. Indiana University Press, 1956.
  55. Kikuta S, Iwanaga J, Watanabe K, et al. Posterior sacrococcygeal plexus: application to spine surgery and better understanding low-back pain. *World*

- Neurosurg* 2020; 135:e567-e572.
56. Vleeming A, Pool-Goudzwaard AL, Hammudoghlu D, Stoeckart R, Snijders CJ, Mens JM. The function of the long dorsal sacroiliac ligament: its implication for understanding low back pain. *Spine (Phila Pa 1976)* 1996; 21:556-562.
  57. Horwitz MT. The anatomy of (A) the lumbosacral nerve plexus-its relation to variations of vertebral segmentation, and (B), the posterior sacral nerve plexus. *The Anatomical Record* 1939; 74:91-107.
  58. Cox RC, Fortin JD. The anatomy of the lateral branches of the sacral dorsal rami: implications for radiofrequency ablation. *Pain Physician* 2014; 17:459-464.
  59. Mahli A, Coskun D, Altun NS, Simsek A, Ocal E, Kostekci M. Alcohol neurolysis for persistent pain caused by superior cluneal nerves injury after iliac crest bone graft harvesting in orthopedic surgery: report of four cases and review of the literature. *Spine (Phila Pa 1976)* 2002; 27:E478-E481.
  60. Delawi D, Dhert WJ, Castelein RM, Verbout AJ, Oner FC. The incidence of donor site pain after bone graft harvesting from the posterior iliac crest may be overestimated: a study on spine fracture patients. *Spine (Phila Pa 1976)* 2007; 32:1865-1868.
  61. Gupta A, Kukkar N, Sharif K, Main BJ, Albers CE, El-Amin Iii SF. Bone graft substitutes for spine fusion: a brief review. *World J Orthop* 2015; 6:449-456.
  62. Fujihara F, Kim K, Isu T. Incidence of Paralumbar Spine Disease. In: *Entrapment Neuropathy of the Lumbar Spine and Lower Limbs*. Springer, 2021, pp 113-120.
  63. Isu T, Kim K, Morimoto D, Iwamoto N. Superior and middle cluneal nerve entrapment as a cause of low back pain. *Neurospine* 2018; 15:25-32.
  64. Speed S, Sims K, Weinrauch P. Entrapment of the medial branch of the superior cluneal nerve. *J Med Cases* 2011; 2:101-103.
  65. Trescot AM, Krashin D, Karl HW. Epidemiology and Pathophysiology. In: Trescot AM (ed). *Peripheral Nerve Entrapments: Clinical Diagnosis and Management*, 2016, pp 3-10.
  66. Vleeming A, Pool-Goudzwaard A, Stoeckart R, van Wingerden JP, Snijders CJ. The posterior layer of the thoracolumbar fascia. *Spine (Phila Pa 1976)* 1995; 20:753-758.
  67. Willard FH, Vleeming A, Schuenke MD, Danneels L, Schleip R. The thoracolumbar fascia: anatomy, function and clinical considerations. *J Anat* 2012; 221:507-536.
  68. Felder JM. Double Crush Syndrome. In Illig KA, Thompson RW, Freischlag JA, et al (eds). *Thoracic Outlet Syndrome*. Springer International Publishing, Cham, 2021, pp 145-151.
  69. Upton AR, McComas AJ. The double crush in nerve-entrapment syndromes. *Lancet* 1973; 302:359-362.
  70. Kim K, Isu T, Morimoto D, et al. Common diseases mimicking lumbar disc herniation and their treatment. *Mini-invasive Surg* 2017; 1:43-51.
  71. Boden SD, Davis DO, Dina TS, Patronas NJ, Wiesel SW. Abnormal magnetic-resonance scans of the lumbar spine in asymptomatic subjects. A prospective investigation. *J Bone Joint Surg Am* 1990; 72:403-408.
  72. Jensen MC, Brant-Zawadzki MN, Obuchowski N, Modic MT, Malkasian D, Ross JS. Magnetic resonance imaging of the lumbar spine in people without back pain. *N Engl J Med* 1994; 331:69-73.
  73. Naeim F, Froetscher L, Hirschberg GG. Treatment of the chronic iliolumbar syndrome by infiltration of the iliolumbar ligament. *West J Med* 1982; 136:372-374.
  74. Wang JM, Kirkpatrick C, Loukas M. The iliolumbar ligament does not have a direct nerve supply. *The Spine Scholar* 2018; 2:3661-3665.
  75. Cooper NA, Scavo KM, Strickland KJ, et al. Prevalence of gluteus medius weakness in people with chronic low back pain compared to healthy controls. *Eur Spine J* 2016; 25:1258-1265.
  76. Kim K, Isu T, Chiba Y, Iwamoto N, Morimoto D, Isoe M. Decompression of the gluteus medius muscle as a new treatment for buttock pain. *Eur Spine J* 2016; 25:1282-1288.
  77. Kameda M, Tanimae H. Effectiveness of active soft tissue release and trigger point block for the diagnosis and treatment of low back and leg pain of predominantly gluteus medius origin: a report of 115 cases. *J Phys Ther Sci* 2019; 31:141-148.
  78. Kim K, Isu T, Matsumoto J, et al. Gluteus medius muscle decompression for buttock pain: a case-series analysis. *Acta Neurochir (Wien)* 2019; 161:1397-1401.
  79. Ward SR, Winters TM, Blemker SS. The architectural design of the gluteal muscle group: implications for movement and rehabilitation. *J Orthop Sports Phys Ther* 2010; 40:95-102.
  80. Pouliquen U, Riant T, Robert R, Labat JJ. Cluneal inferior neuralgia by conflict around the ischium: identification of a clinical entity from a series of anesthetic blocks in 72 patients. *Prog Urol* 2012; 22:1051-1057.
  81. Randhawa S, Garvin G, Roth M, Wozniak A, Miller T. Maigne Syndrome—A potentially treatable yet underdiagnosed cause of low back pain: a review. *J Back Musculoskelet Rehabil* 2022; 35: 153-159.
  82. Maigne R. Thoracolumbar junction syndrome a source of diagnostic error. *J Orthop Med* 1995; 17:84-89.
  83. Alptekin K, Örnek NI, Aydın T, et al. Effectiveness of exercise and local steroid injections for the thoracolumbar junction syndrome (The Maigne's syndrome) treatment. *Open Orthop J* 2017; 11:467-477.
  84. Fortin JD. Thoracolumbar syndrome in athletes. *Pain Physician* 2003; 6:373-375.
  85. Murphy J, McLoughlin E, Davies AM, James SL, Botchu R. Is T9-11 the true thoracolumbar transition zone? *J Clin Orthop Trauma* 2020; 11:891-895.
  86. Fawcett L, James S, Botchu R, Martin J, Heneghan NR, Rushton A. The influence of spinal position on imaging findings: an observational study of thoracolumbar spine upright MRI in elite gymnasts. *Eur Spine J* 2022; 31:225-232.
  87. Maigne JY, Maigne R. Trigger point of the posterior iliac crest: painful iliolumbar ligament insertion or cutaneous dorsal ramus pain? An anatomic study. *Arch Phys Med Rehabil* 1991; 72:734-737.
  88. Fortin JD. Thoracolumbar syndrome in athletes. *Pain Physician* 2003; 6:373-376.
  89. Travell JG, Simons DG, Simons LS. *Myofascial pain and dysfunction: the trigger point manual*. Lippincott Williams & Wilkins, 1983.
  90. Lu J, Ebraheim NA, Huntoon M, Heck BE, Yeasting RA. Anatomic considerations of superior cluneal nerve at posterior iliac crest region. *Clin Orthop Relat Res* 1998; 347:224-228.
  91. Aly TA, Tanaka Y, Aizawa T, Ozawa H, Kokubun S. Medial superior cluneal nerve entrapment neuropathy in teenagers: a report of two cases. *Tohoku J Exp Med* 2002; 197:229-231.
  92. Fortin JD, Falco FJ. The Fortin finger test: an indicator of sacroiliac pain. *Am J Orthop (Belle Mead)* 1997; 26:477-480.

93. North RB, Kidd DH, Zahurak M, Piantadosi S. Specificity of diagnostic nerve blocks: a prospective, randomized study of sciatica due to lumbosacral spine disease. *Pain* 1996; 65:77-85.
94. Ermis MN, Yıldırım D, Durakbasa MO, Tamam C, Ermis OE. Medial superior cluneal nerve entrapment neuropathy in military personnel; diagnosis and etiologic factors. *J Back Musculoskelet Rehabil* 2011; 24:137-144.
95. Peer S, Kovacs P, Harpf C, Bodner G. High-resolution sonography of lower extremity peripheral nerves: anatomic correlation and spectrum of disease. *J Ultrasound Med* 2002; 21:315-322.
96. Nielsen TD, Moriggl B, Barckman J, et al. Randomized trial of ultrasound-guided superior cluneal nerve block. *Reg Anesth Pain Med* 2019; 44:772-780.
97. Talu GK, Özyalçın S, Talu U. Superior cluneal nerve entrapment. *Reg Anesth Pain Med* 2000; 25:648-650.
98. Kerasnoudis A, Tsivgoulis G. Nerve ultrasound in peripheral neuropathies: a review. *J Neuroimaging* 2015; 25:528-538.
99. Carroll AS, Simon NG. Current and future applications of ultrasound imaging in peripheral nerve disorders. *World J Radiol* 2020; 12:101-129.
100. Moore D, Semciw AI, Pizzari T. A systematic review and meta-analysis of common therapeutic exercises that generate highest muscle activity in the gluteus medius and gluteus minimus segments. *Int J Sports Phys Ther* 2020; 15:856-881.
101. Silver S, Ledford CC, Vogel KJ, Arnold JJ. Peripheral nerve entrapment and injury in the upper extremity. *Am Fam Physician* 2021; 103:275-285.
102. Herring A, Price DD, Nagdev A, Simon B. Superior cluneal nerve block for treatment of buttock abscesses in the emergency department. *J Emerg Med* 2010; 39:83-85.
103. Cohen SP, Bicket MC, Kurihara C, et al. Fluoroscopically guided vs landmark-guided sacroiliac joint injections: a randomized controlled study. *Mayo Clin Proc* 2019; 94:628-642.
104. Bodner G, Platzgummer H, Meng S, Brugger PC, Gruber GM, Lieba-Samal D. Successful identification and assessment of the superior cluneal nerves with high-resolution sonography. *Pain Physician* 2016; 19:197-202.
105. McGrath MC, Stringer MD. Bony landmarks in the sacral region: the posterior superior iliac spine and the second dorsal sacral foramina: a potential guide for sonography. *Surg Radiol Anat* 2011; 33:279-286.
106. Finneran J, Alexander B, Ilfeld BM, Trescot AM. A novel introducer for ultrasound-guided cryoneurolysis administration to improve patient safety and functionality. *Korean J Anesthesiol* 2021; In Press.
107. Mahli A, Coskun D, Altun NS, Simsek A, Ocal E, Kostekci M. Alcohol neurolysis for persistent pain caused by superior cluneal nerves injury after iliac crest bone graft harvesting in orthopedic surgery: report of four cases and review of the literature. *Spine (Phila Pa 1976)* 2002; 27:E478-E481.
108. McRoberts WP, Deer TR, Abejón D, Barolat G. Stimulation of the extraspinal peripheral nervous system. In: Deer TR, Pope JE (eds). *Atlas of Implantable Therapies for Pain Management*, Springer, 2016, pp 171-183.
109. Abd-Elseyed A. Wireless peripheral nerve stimulation for treatment of peripheral neuralgias. *Neuromodulation* 2020; 23:827-830.
110. Deer T, Pope J, Benyamin R, et al. Prospective, multicenter, randomized, double-blinded, partial crossover study to assess the safety and efficacy of the novel neuromodulation system in the treatment of patients with chronic pain of peripheral nerve origin. *Neuromodulation* 2016; 19:91-100.
111. Shields KG, Levy MJ, Goadsby PJ. Alopecia and cutaneous atrophy after greater occipital nerve infiltration with corticosteroid. *Neurology* 2004; 63:2193-2194.

