

Prospective Study

e Alleviating Paravertebral Muscle Spasm after Radiofrequency Ablation Treatment of Hypersensitive Basivertebral and Sinuvertebral Nerves for Chronic Discogenic Back Pain

Ji Yeon Kim, MD¹, Hyeun Sung Kim, MD, PhD¹, Pang Hung Wu, MBBS, FRCS², and Il-Tae Jang MD, PhD¹

From: ¹Nanoori Gangnam Hospital, Seoul, Spine Surgery, Korea, Rep. of South; ²National University Health System, JurongHealth Campus, Orthopaedic Surgery, Singapore

Address Correspondence: Hyeun Sung Kim, MD, PhD
Department of Neurosurgery,
Nanoori Gangnam Hospital
731 Eonju-ro, Gangnam-gu,
Seoul 06048, Korea
E-mail:
neurospinekim@gmail.com

Disclaimer: There was no external funding in the preparation of this manuscript.

Conflict of interest: Each author certifies that he or she, or a member of his or her immediate family, has no commercial association (i.e., consultancies, stock ownership, equity interest, patent/licensing arrangements, etc.) that might pose a conflict of interest in connection with the submitted manuscript.

Manuscript received:
10-21-2020

Revised manuscript received:
03-02-2021

Accepted for publication:
03-19-2021

Free full manuscript:
www.painphysicianjournal.com

Background: Paraspinal muscle spasm caused by pain from a lumbar degenerative disc is frequently investigated in patients with low back pain. Radiofrequency ablation (RFA) surgery could alleviate paraspinal muscle spasms.

Objectives: We performed RFA surgery on the high-intensity zone (HIZ) and hypersensitive sinuvertebral and basivertebral nerves to evaluate its outcome. The paravertebral muscle cross-sectional area (CSA) was measured on magnetic resonance imaging (MRI) before and after surgery to evaluate the effect of RFA surgery on the paravertebral muscle.

Study Design: Prospective cohort study.

Setting: A single spine surgery center.

Methods: A comparative study was performed on 2 different uniportal spinal endoscopic surgery groups; 23 patients who underwent RFA surgery for chronic discogenic back pain and 45 patients who underwent posterior decompression surgery for lumbar spinal stenosis with 12 months of follow-up. Paravertebral muscle cross-sectional area, Schiza grade, Modic type, and HIZ size were measured on pre- and post-operative MRI. An endoscopic video review was performed to evaluate the presence of intraoperative twitching and grade the degree of epidural neovascularization and adhesion. Visual analog scale VAS, modified Oswestry Disability Index, ODI and MacNab's criteria were evaluated for outcome measures.

Results: Intraoperative endoscopic video evaluation showed neovascularization and adhesion adjacent to the disc and pedicle. In the RFA surgery group, there were 7 patients (30.43%) with grade 2 and 16 (69.57%) with grade 3 neovascularization; intraoperative twitching was observed in 19 out of 23 patients (82.61%). After performing an RFA on the sinuvertebral and basivertebral nerves for the treatment of discogenic back pain, the results showed significant improvement in pain and disability scores. The mean CSA of the paraspinal muscle in the RFA surgery group was significantly increased after surgery at the L4–L5 and L5–S1 levels (L4–L5: $3901 \pm 1096.7 \text{ mm}^2$ to $4167 \pm 1052.1 \text{ mm}^2$, $P = 0.000$; L5–S1: $3059 \pm 968.5 \text{ mm}^2$ to $3323 \pm 1046.2 \text{ mm}^2$, $P = 0.000$) compared to preoperative CSA.

Limitations: This study was limited by its small sample size.

Conclusion: Hypersensitive sinuvertebral and basivertebral nerves are strongly associated with epidural neovascularization with adhesion and the pathological pain pathway in degenerative disc disease. Epidural neovascularization with adhesion reflects aberrant neurological connections, which are associated with reflex inhibitory mechanisms of the multifidus muscle, which induces spasm. RFA treatment of the region of epidural neovascularization with adhesion effectively treated chronic discogenic back pain and could induce paraspinal muscle spasm release.

Key words: Discogenic back pain, high-intensity zone, sinuvertebral nerve, basivertebral nerve, radiofrequency ablation, multifidus muscle

Pain Physician 2021; 24:E883-E892

Chronic low back pain (CLBP) is one of the most disabling conditions globally and is associated with tremendous socioeconomic and health care consequences (1). In the normal intervertebral disc (IVD), there is no nerve structure in the inner layer of the fibrous ring (2) and no significant difference in nerve density distribution between the outer fibrous ring and endplate (3). In degenerative conditions, inflammatory pathways involving secreted cytokines induce nerve fibers and granulation tissue to grow in the fissure of a degenerated IVD, leading to discogenic back pain (4,5). Previous reports have suggested that the high-intensity zone (HIZ) forms because annular tears cause injured disc material to accumulate and cause further degenerative changes within the IVD (6-9). However, a recent systematic review found evidence that an HIZ is a risk factor for CLBP (10-12).

In the present prospective study, we performed endoscopic radiofrequency ablation (RFA) surgery on the HIZ with the surrounding sinuvertebral nerve (SVN) and basivertebral nerve (BVN) to treat discogenic low back pain (LBP). We then evaluated the short- and long-term effects of this procedure on the patient's score, MacNab's criteria, and disability score. A recent study observed "Kim's twitching" of the buttock and paraspinal muscle during RFA (13). Therefore, we measured the cross-sectional area (CSA) of the paravertebral muscle on magnetic resonance imaging (MRI) before and after surgery to evaluate the effect of RFA on the paravertebral muscle and find the neurological connections between the SVN, BVN, and paravertebral muscles.

METHODS

Study Patients

This was a prospective study involving 23 patients who underwent uniportal spinal endoscopic RFA surgery due to chronic discogenic back pain and 45 patients who underwent uniportal spinal endoscopic posterior decompression surgery due to lumbar spinal stenosis. The procedures were performed by a single professional senior spine surgeon at a single center during the calendar year 2018. All patients were followed for at least 12 months. We set the posterior decompression group as a comparative group because pain relief could be obtained by posterior neural decompression without RFA surgery or discectomy, which may influence the paraspinal muscle.

The patients included in the endoscopic RFA

surgery group met the following inclusion criteria: 1) interlaminar approach at the L4-L5 or L5-S1 levels; 2) Schiza grade A spinal stenosis or none; 3) HIZ in the posterior annulus fibrosis on T2-weighted MRI; 4) disc degeneration on MRI; 5) no nerve root compressive lesions, such as disc protrusion or degenerative bulging disc; 6) severe LBP with less leg pain or without leg pain for more than 6 months. We also applied the following exclusion criteria: 1) predominant nonmechanical leg pain and neurogenic claudication; 2) MRI showing prolapsed uncontained disc or significant facet arthropathy; 3) necessity of discectomy or removal of any disc fragment for neural compression during endoscopic spine surgery.

The patients included in the endoscopic posterior decompression surgery group met the following inclusion criteria: 1) Schiza grade B-D; 2) severe leg pain with neurogenic intermittent claudication; 3) one symptomatic lesion at the L4-L5 or L5-S1 level. The following exclusion criteria were applied to both surgery groups: 1) previous spinal surgery, traumatic fracture, infection, or tumor; 2) postoperative epidural or muscle hematoma on postoperative MRI; 3) inability to measure the CSA of the paravertebral muscle because of severe sarcopenia.

The Ethics Committee of Nanoori Hospital approved this study. Informed consent was obtained from all patients.

Surgical Procedures

Patients were classified into the following 2 categories according to the type of disease and the endoscopic surgical procedures conducted:

RFA via Interlaminar Endoscopic Lumbar Discectomy (RF-IELD)

This procedure was performed under seated regional epidural anesthesia. The patient was placed prone. The approach side was decided based on either symptom severity or, in the case of mid-axial back pain, the location of the HIZ. Under intraoperative fluoroscopy, the endoscope was docked in the junction of the ipsilateral facet joint and IVD line. The endoscope had a 30° viewing angle, a 7.3 mm outer diameter, and a 4.7 mm diameter working channel. The working channel was pushed into the spinal canal away from the neural elements toward the disc space. A bipolar radiofrequency electrocoagulator was used to ablate the hypersensitive basivertebral nerve around the suprapedicular area and sinuvertebral nerve be-

tween the posterior annulus and posterior longitudinal ligament, which was covered with epidural neovascularization and adhesions (Fig. 1) (13). The procedure was performed unilaterally on the symptomatic side, and RFA was also performed on the annulus containing the HIZ lesion. The procedure was performed with the working channel protecting the neural elements from possible damage.

Lumbar Endoscopic Unilateral Laminotomy For Bilateral Decompression (LE-ULBD)

This procedure was performed under regional epidural or general anesthesia. The patient was placed prone. The endoscopic system has a working cannula with a 13.7 mm outer diameter and a 10.2 mm inner diameter, and a 15° view angle. The endoscope was docked on the junction of the ipsilateral facet joint and IVD line. We drilled just enough lamina to safely remove the thickened flavum and sufficiently decompress the neural tissues. Next, we confirmed the neovascularization grade, but RFA was not performed in this group.

Data Collection

Clinical Data Collection

Information on patient characteristics such as age, gender, symptom duration, and surgery indication were collected; the nature of the surgery and the level of operation were also documented. For each patient, the following information was collected before and after surgery (one week, 3 month, and final follow-ups) by attending physicians: visual analog scale (VAS) scores for LBP and leg pain, modified Oswestry Disability score (ODI), and MacNab's criteria for evaluating patient's pain response and disability.

MRI Acquisition

One junior professional neurosurgeon analyzed and measured the MRI parameters. Images were obtained using a GE Signa 1.5-T HDxT MRI Machine (GE Healthcare, Milwaukee, WI). All measurements were performed using an Infinitt PACS M6 Version (Infinitt Healthcare Co., Seoul, Republic of Korea). The images were obtained using a fast spin-echo sequence with an echo train length of 28, a bandwidth of 25 Hz, a repetition time of 3,000 milliseconds, an echo time of 110 milliseconds, a field of view of 160 × 160 mm, a number of excitations of 2, a slice thickness of 3 mm, and a slice gap of 0.5 mm. MRI was performed within one week

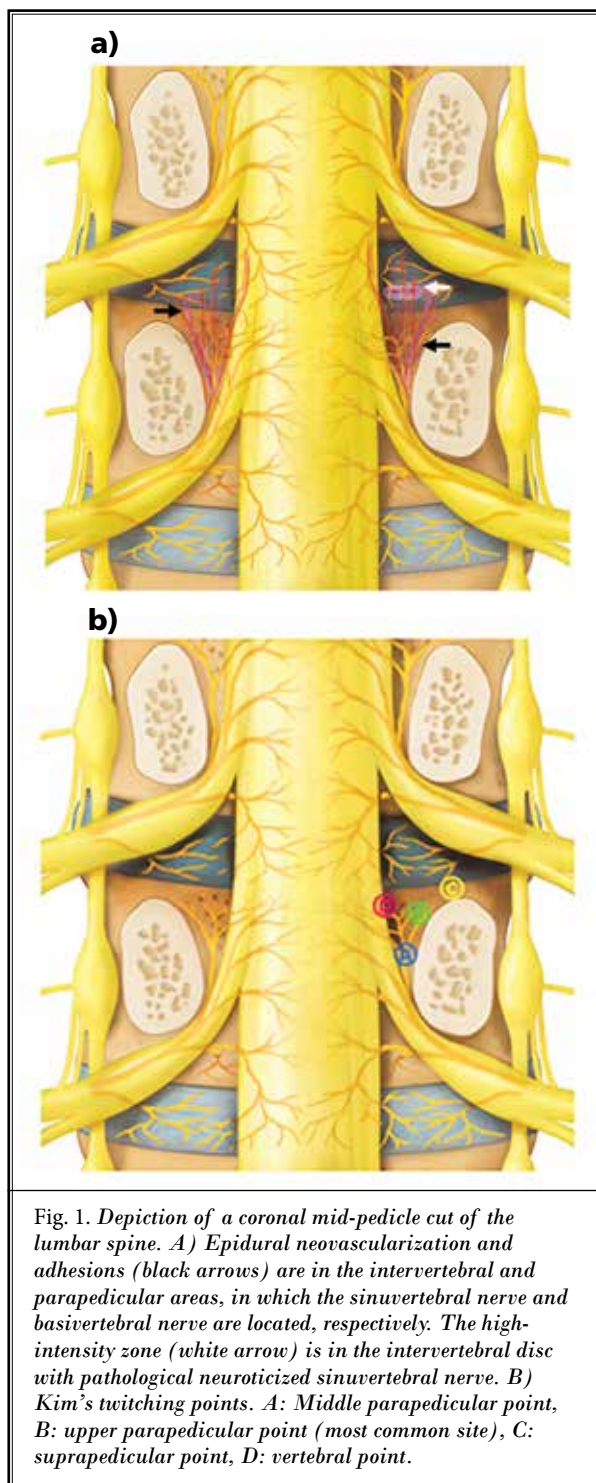


Fig. 1. Depiction of a coronal mid-pedicle cut of the lumbar spine. A) Epidural neovascularization and adhesions (black arrows) are in the intervertebral and parapedicular areas, in which the sinuvertebral nerve and basivertebral nerve are located, respectively. The high-intensity zone (white arrow) is in the intervertebral disc with pathological neurotized sinuvertebral nerve. B) Kim's twitching points. A: Middle parapedicular point, B: upper parapedicular point (most common site), C: suprapedicular point, D: vertebral point.

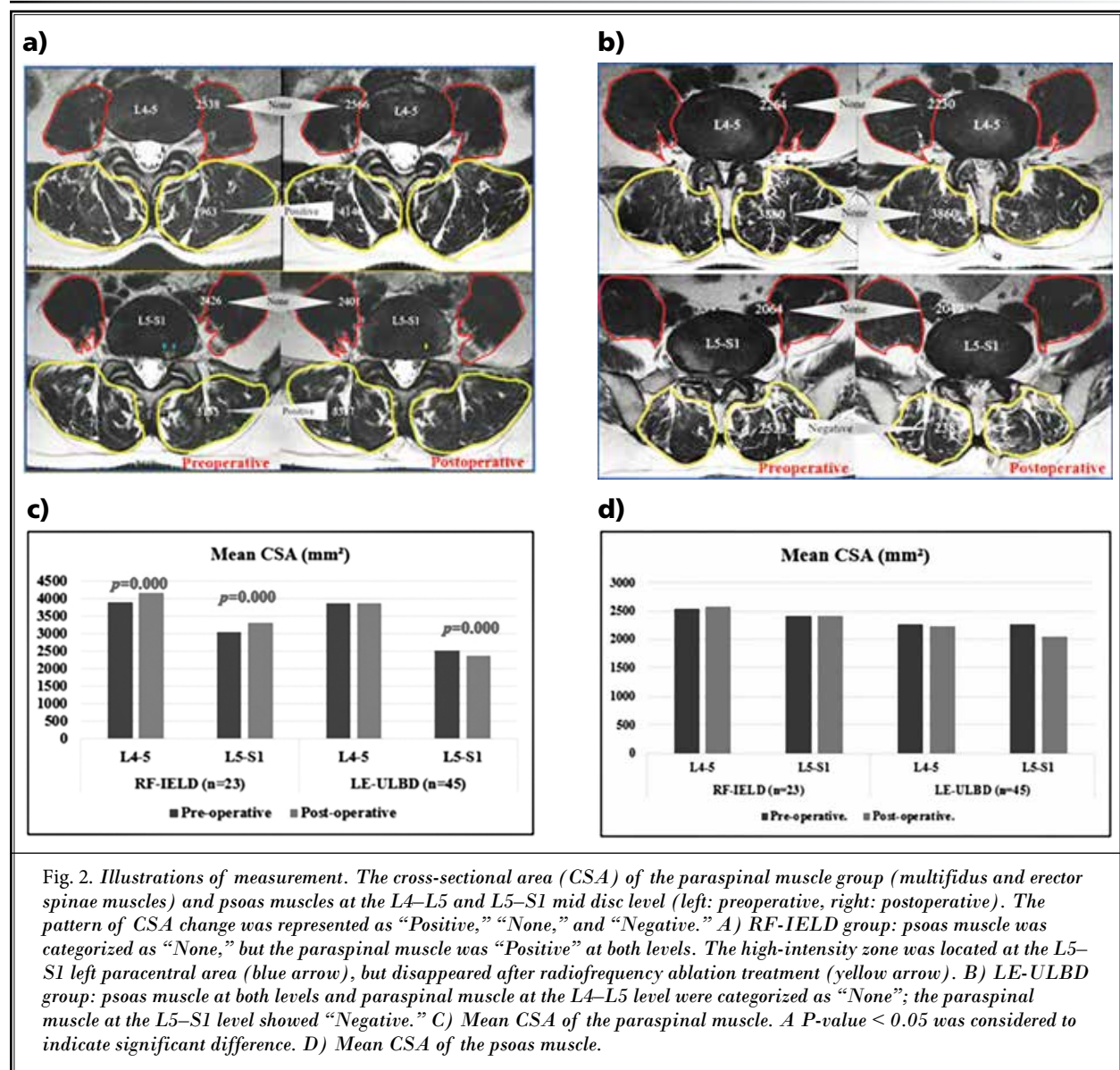
before surgery and within 3 days after surgery without a drain.

Before surgery, we observed the types of Modic changes and Schiza grade (14) for the degree of spinal

stenosis. The transverse diameter and CSA of the HIZ were measured on axial T2-weighted MRI before and after surgery by pixel counting in the RF-IELD group. Transverse images were acquired obliquely at each disc level. Paravertebral muscle CSA was assessed by carefully outlining the muscle mass on the T2-weighted axial images, excluding fat and/or fibrous tissue external to the muscle fascia. Next, the CSA was automatically measured by pixel counting (Figs. 2A,3B). One study of CSA reported significant modifications when the slice orientation was modified (15). To mini-

mize the change in value, the CSA was obtained from 2 consecutive transverse images at the same position (mid and upper disc level), and the average value was obtained.

Surgical procedures were performed within the sublaminar space from the caudal to the cranial direction, so the paraspinal muscle at the mid and upper disc levels was not directly violated. Furthermore, patients with postoperative muscle or epidural hematoma were excluded. The paravertebral muscle was classified into 2 sections: the paraspinal muscle (multifidus + erector



spinae) and the psoas muscle, and the CSA was obtained from each section. Although value modification was minimized, it could not be excluded entirely, so differences between +100 and -100 mm² were defined as no change (“None”). When the CSA increased by more than 100 mm², it was described as “Positive”; when it decreased more than 100 mm², it was defined as “Negative” (Fig. 3).

Intraoperative Findings

Two experienced neurosurgeons reviewed the endoscopic videos to evaluate intraoperative twitching and to grade the degree of neovascularization and adhesion. In mismatched cases, the results were adjusted to reflect agreements after repeated assessments. We used a novel degenerative spinal neovascularization grading described in a previous study (13), as follows: Grade 1, normal vascularization; Grade 2, neovascularization without adhesion; Grade 3, neovascularization with adhesion. Neovascularization and adhesion were observed in the epidural space between the thecal sac, traversing and exiting nerve roots, posterior longitudinal ligament, annulus, and vertebral bodies (Fig. 1A). The bipolar radiofrequency probe was applied to the medial suprapedicular area (Fig. 1B); twitching of the buttock and paraspinal region were then observed, which typically starts when the BVN is coagulated; a previous study termed this iatrogenic twitching “Kim’s twitching” (13). Once the BVN was completely ablated, Kim’s twitching stopped, even when the radiofrequency was applied to the same area. Kim’s twitching was also observed when the SVN was coagulated around the HIZ in the intervertebral disc (Fig. 1A). During regional epidural anesthesia, pain sensation was decreased, but motor function was not, so no problems were encountered when evaluating muscle twitching.

Statistical Analysis

Statistical analyses were performed using PASW Statistics ver. 18.0 (SPSS Inc., Chicago, IL, USA). The paired t-test was used to compare pre- and postoperative VAS, ODI, and MacNab’s outcome criteria to assess the outcomes as well as HIZ size, disc height, and paravertebral muscle CSA to evaluate the morphological changes. Independent t-test was used to compare outcomes and measured values between the 2 independent groups. A *P*-value < 0.05 was considered to indicate significant difference.

RESULTS

We included a total of 23 patients in the RF-IELD

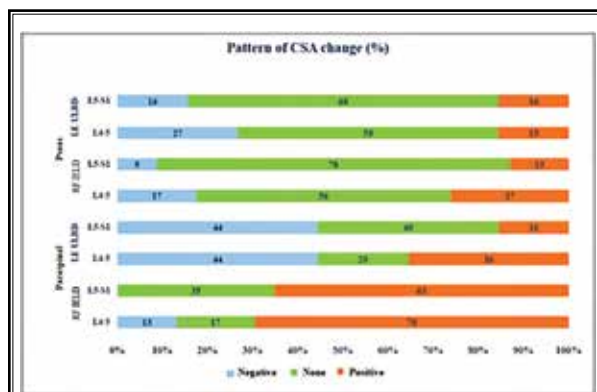

Fig. 3. The pattern of paravertebral (paraspinal + psoas) muscle cross-sectional area (CSA) change was described as a percentage within each group. When the CSA increased by more than 100 mm², it was “Positive”; when it decreased by more than 100 mm², it was “Negative”; when it was between +100 mm² and -100 mm², it was categorized as “None”.

group and 45 patients in the LE-ULBD group. The mean age was 47.1 ± 12.5 years (range: 19–76 years) in the RE-IELD group and 59.8 ± 13.8 years (range: 33–81 years) in the LE-ULBD group. The mean symptom duration was 20.1 ± 7.5 months in the RF-IELD group and 9.5 ± 2.6 months in LE-ULBD group. The mean follow-up duration was 15.5 ± 3.4 months in the RF-IELD group and 16.6 ± 4.1 months in the LE-ULBD group. The treated spinal levels in the RF-IELD group were L4–L5 (n = 10) and L5–S1 (n = 13); in the group LE-ULBD, they were L4–L5 (n = 42) and L5–S1 (n = 3; Table 1).

Preoperative MRI showed Modic change in 12 out of 23 patients in the RF-IELD group (52.12%) and in 14 out of 45 patients in the LE-ULBD group (31.11%). There was a higher proportion of patients with Modic change in the RF-IELD group (Table 1). All patients in the RF-IELD group showed Schiza grade A, which means no or minor stenosis. In the LE-ULBD group, there were 7 patients with Grade B (moderate stenosis), 23 with Grade C (severe stenosis), and 15 with Grade D (extreme stenosis) (Table 1).

Intraoperative endoscopic videos showed neovascularization and adhesion in the epidural space adjacent to the disc and pedicle; there were 7 patients with Grade 2 and 16 with Grade 3 in the RF-IELD group; in the LE-ULBD group, there were 8 with Grade 1, 23 with Grade 2, and 10 with Grade 3. Kim’s twitching was observed in 19 out of the 23 patients in the RF-IELD group (Table 1) when the BVN is coagulated at the parape- dicular point and when the SVN is coagulated around

Table 1. Background data and clinical results of the 2 groups.

Variable	RF-IELD (n = 23)	LE-ULBD (n = 45)	P-value
Gender (men/women)	9/14	20/25	N/A
Age (years, mean/range)	47.1 ± 12.5 (19~76)	59.8 ± 13.8 (33~81)	N/A
Symptom duration (months)	20.1 ± 7.5	9.5 ± 2.6	N/A
Follow-up duration (months)	15.5 ± 3.4	16.6 ± 4.1	N/A
Treated level (n / %)			N/A
L4-L5	10 (48)	42 (93)	
L5-S1	13 (52)	3 (7)	
Modic type (n)			N/A
Type 1	6	7	
Type 2	5	7	
Type 3	1	0	
Total (n/%)	12 (52)	14 (31)	N/A
Schiza grade (n/%)			N/A
A	23 (100)	0	
B	0	7 (16)	
C	0	23 (51)	
D	0	15 (33)	
Neovascularization grade (n/%)			N/A
Grade 1	0	8 (18)	
Grade 2	7 (30)	27 (60)	
Grade 3	16 (70)	10 (22)	
Kim's twitching (n/%)			N/A
Negative	4 (17)		
Positive	19 (83)		
HIZ size (range)			
Transverse diameter (mm, before and after) (Range)	6.25 ± 3.05 (2 ~ 12), 1.65 ± 1.90 (0 ~ 9.64)		P = 0.000*
CSA (mm ² , Pre and Post) (Range)	13.43 ± 10.63 (3.4 ~ 35.4), 1.84 ± 4.28(0 ~ 15.33)		P = 0.000*
VAS (before surgery, 1-week, 3-month, and final follow-ups)	7.22 ± 1.28, 2.17 ± 0.64 (P = 0.000*), 1.65 ± 0.56 (P = 0.000*), 1.65 ± 0.56 (P = 0.000*)	7.73 ± 1.29, 3.22 ± 0.63 (P = 0.000*), 2.4 ± 0.74 (P = 0.000*), 2.2 ± 0.75 (P = 0.000*)	P = 0.929
ODI (before surgery, 1-week, 3-month, and final follow-ups)	68.3 ± 10.56, 25.3 ± 2.98 (P = 0.000*), 22.3 ± 2.38 (P = 0.000*), 21.4 ± 2.60 (P = 0.000*)	73.2 ± 10.89, 29.3 ± 2.96 (P = 0.000*), 25.6 ± 2.44 (P = 0.000*), 24.4 ± 2.56 (P = 0.000*)	P = 0.444
MacNab's criteria (n)			N/A
Fair	0	3	
Good	11	33	
Excellent	12	9	

Descriptive details of outcome measurement for preoperative MRI (Modic type, disc height, Schiza grade), intraoperative findings (neovascularization grade, Kim's twitching), pain measurement (VAS, ODI before surgery and at one week, 3 month and final follow-ups, MacNab's criteria). Independent t-test is used to compare the measured values between the 2 independent groups. Values are presented as mean ± standard deviation. *P < 0.05 was considered to indicate significant difference. N/A; not applicable. HIZ; high-intensity zone.

the HIZ in the intervertebral disc (Fig. 1). The transverse length and CSA of the HIZ were measured before and after surgery in the RF-IELD group. The mean value of the transverse length was changed from 6.25 ± 3.05 mm to 1.65 ± 1.90 mm, and the CSA was changed from 13.43 ± 10.63 mm² to 1.84 ± 4.28 mm². There was a statistically significant decrease in both parameter values ($P = 0.00$) (Table 1).

We measured VAS score (mean and range) before surgery and at the one week, 3 month, and final follow-ups, with the following results: 7.22 (5–9), 2.17 (1–4), 1.65 (1–3), and 1.65 (1–3), respectively, in the RF-IELD group and 7.73 (6–9), 3.22 (2–4), 2.40 (1–4), and 2.20 (1–4), respectively, in the LE-ULBD group (Table 1). There was a significant improvement at the one week, 3 month, and final follow-ups in all surgical groups ($P = 0.000$ in all cases and in both groups) (Fig. 4A). However, there was no significant difference between the 2 surgical groups ($P = 0.929$).

The ODI scores (mean and range) were measured before surgery and at the one week, 3 month, and final follow-ups, with the following results: 68.30 (48–84), 25.30 (20–34), 22.30 (18–26), and 21.40 (16–24) in the RF-IELD group and 73.18 (56–86), 29.33 (22–42), 25.60 (18–42), and 24.40 (16–38) in the LE-ULBD group (Table 1). There was a statistical improvement at the one week, 3 month, and final follow-ups in both surgical groups ($P = 0.000$ in all cases and in both groups) (Fig. 4B). There was no significant difference between the 2 groups ($P = 0.444$). MacNab’s criteria showed excellent outcomes in 12 cases and good outcomes in 11 cases in the RF-IELD group, as well as excellent outcomes in 9 cases, good outcomes in 33 cases, and fair outcomes in 3 cases in the LE-ULBD group (Table 1). Table 2 and Figs. 2 and 3 detail the mean CSA and pattern of CSA change in the paraspinal and psoas muscles. The mean CSA at each level was calculated as the sum of the bilateral measured values.

The mean CSA of the paraspinal muscle in the RF-IELD group was significantly increased after surgery at both the L4–L5 and L5–S1 levels (L4–L5: 3901 ± 1096.7 mm² to 4167 ± 1052.1 mm²; $P = 0.000$, L5–S1: 3059 ± 968.5 mm² to 3323 ± 1046.2 mm²; $P = 0.000$). However, in the LE-ULBD group, it was significantly decreased after surgery at the L5–S1 level (2533 ± 820.8 mm² to 2383 ± 781.3 mm²; $P = 0.001$), but not at the L4–L5 level (3880 ± 750.4 mm² to 3860 ± 738.2 mm²; $P = 0.067$) (Fig. 2C). The pattern of CSA change in the paraspinal muscle was strictly measured. In the RF-IELD group, there were 16 (70%) “Positive” changes, 4 (17%) “None” changes, and 3 (13%) “Negative” changes

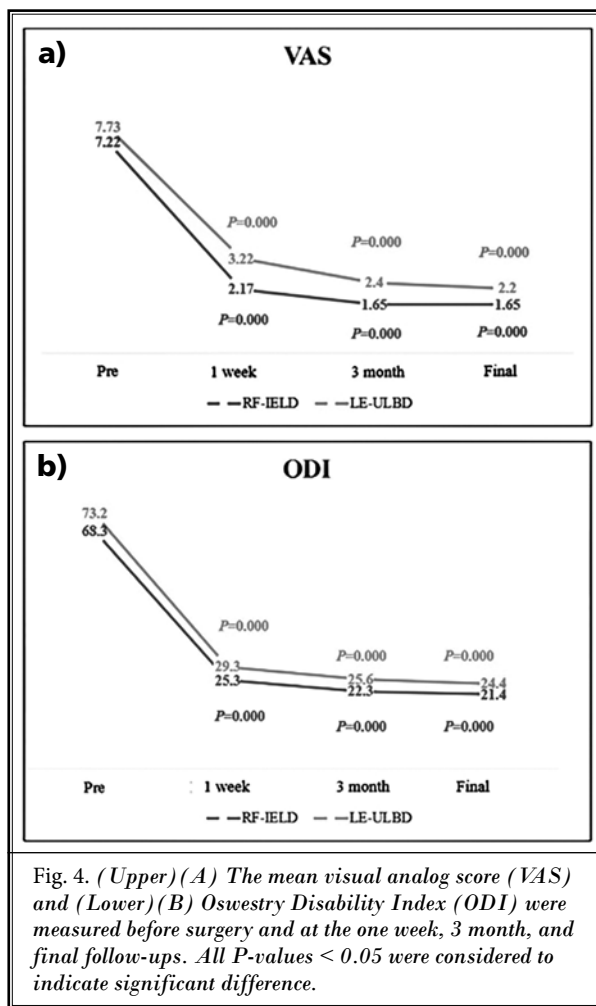


Fig. 4. (Upper) (A) The mean visual analog score (VAS) and (Lower) (B) Oswestry Disability Index (ODI) were measured before surgery and at the one week, 3 month, and final follow-ups. All P-values < 0.05 were considered to indicate significant difference.

at the L4–L5 level, while there were 15 (65%) “Positive” changes and 8 (35%) “None” changes out of 23 patients at the L5–S1 level (Table 2) (Fig. 3). In the LE-ULBD group, significantly more patients had changed to “Negative” (L4–L5: 44%, L5–S1: 44%) or “None” (L4–L5: 20%, L5–S1: 40%) than to “Positive” (L4–L5: 36%, L5–S1: 16%) (Fig. 3). The mean CSA of the psoas muscle showed an inconsistent direction of increase and decrease at the L4–L5 and L5–S1 levels in both surgical groups, unlike the paraspinal muscle (Fig. 2D). The pattern of psoas CSA change was not affected by surgery regardless of surgical type, because more than half of the patients were classified as “None” (L4–L5: 56%, L5–S1: 78% in the RF-IELD group; L4–L5: 58%, L5–S1: 68% in the LE-ULBD) (Fig. 3).

DISCUSSION

Several treatment strategies are effective in degenerative disc disease, including RFA of the BVN through

Table 2. Paraspinal muscle and psoas muscle changes of the 2 groups.

Muscle	Procedure	Level	Mean CSA (mm ²)			Pattern of CSA change (n)		
			Pre-op.	Post-op.	P-value	Negative	None	Positive
Paraspinal	RF-IELD (n = 23)	L4-L5	3901 ± 1096.7	4167 ± 1052.1	P = 0.000*	3	4	16
		L5-S1	3059 ± 968.5	3323 ± 1046.2	P = 0.000*	0	8	15
		Total	3220 ± 1284.9	3366 ± 1352.4	P = 0.000*			
	LE-ULBD (n = 45)	L4-L5	3880 ± 750.4	3860 ± 738.2	P = 0.067	20	9	16
		L5-S1	2533 ± 820.8	2383 ± 781.3	P = 0.000*	20	18	7
		Total	3072 ± 1138.6	3045 ± 1145.8	P = 0.238			
Psoas	RF-IELD (n = 23)	L4-L5	2538 ± 1081.9	2566 ± 1126.5	P = 0.271	4	13	6
		L5-S1	2418 ± 893.0	2413 ± 919.3	P = 0.814	2	18	3
		Total	2738 ± 985.1	2868 ± 985.1	P = 0.553			
	LE-ULBD (n = 45)	L4-L5	2264 ± 851.3	2230 ± 867.5	P = 0.287	12	26	7
		L5-S1	2064 ± 778.5	2049 ± 816.3	P = 0.463	7	31	7
		Total	2299 ± 833.5	2216 ± 816.3	P = 0.788			

The mean cross-sectional area (CSA) and pattern of CSA change of the paraspinal muscle and psoas muscle at the L4-L5 and L5-S1 levels for the RF-IELD and LE-ULBD groups. When CSA increased by more than 100 mm², it was defined as "Positive"; when it decreased by more than 100 mm², it was defined as "Negative"; when it was between +100 mm² and -100 mm², it was defined as no change ("None"). Values are presented as mean ± standard deviation. *P < 0.05 was considered to indicate significant difference.

intraosseous probe insertion (16). The sinuvertebral nerve is involved in nociceptive transmission in degenerative IVD. The ascending branch, which becomes intraosseous near the pedicle and plays a vital role in endplate nociceptive transmission, is termed the BVN (13) (Fig. 1B). In the present study, we performed an RFA on the SVN and BVN for discogenic back pain in young patients; the results showed significant improvement in pain and disability scores (Table 1).

Changes in HIZ size were measured using transverse diameter and CSA; we sought to confirm that postoperative HIZ change was associated with symptom improvement. Of the 23 patients in the RF-IELD group, the HIZ was eliminated in 17 after RFA on the annulus containing the HIZ lesion. Nonetheless, we found no clear correlation between elimination of the HIZ and the degree of symptom improvement. To further investigate whether such a correlation occurs, a prospective study should be carried out with a control group of patients suffering from discogenic back pain without HIZ.

Patients included in the present study who had symptomatic HIZ and discogenic back pain showed a high association with Kim's twitching (19 out of 23) and a high grade of neovascularization (Grade 3 in 16 out of 23 patients); they also showed significant improvements in VAS, ODI, and MacNab's criteria after RFA surgery. Therefore, high neovascularization grade and Kim's twitching are closely correlated with changed

hypersensitive nerves and favorable clinical outcomes after RFA surgery. Furthermore, neovascularization grade is probably a crucial inferred sign, because neither the SVN nor the BVN are usually seen, even with endoscopic magnified vision (Fig. 1A).

The mean CSA of the paraspinal muscle in the RF-IELD group was significantly increased after surgery, and more than half of the patients had a "Positive" CSA value at all levels (Figs. 2C, 3). This result could mean that paraspinal muscle spasm was alleviated after RFA in more than half of the patients, even though no needle electromyography was carried out. The leading causes of the paraspinal muscle changes, pain reduction, or secondary RFA effect were unclear. Both reduced pain after decompression surgery and pain inhibition by RFA could alleviate paraspinal muscle spasm. Therefore, we formed the LE-ULBD surgical group as a control to evaluate the paraspinal muscle response to the RFA procedure.

However, in the LE-ULBD group, the number of "Positive" changes was much less than in the RF-IELD group. Instead, there were more "Negative" changes (Fig. 3), probably because the paraspinal muscle reacted and was changed by postoperative pain in patients with negative changes. Therefore, even though muscle stimulation does occur due to postoperative pain, the increased CSA values in the RF-IELD group must have been meaningful.

The psoas muscle at the L4-L5 and L5-S1 levels was

unaffected by the RFA or decompression surgery—almost all patients were categorized as “None”. Similar results of the psoas CSA in patients with LBP have occurred previously (17,18), perhaps because the psoas major is innervated by direct branches of the anterior rami of the lumbar plexus at the L1–L3 levels.

Several etiologies of multifidus muscle atrophy in patients with LBP have been reported, including disuse atrophy, reflex inhibition, and dorsal ramus syndrome (19-21). Postoperative paraspinal muscle change is likely more correlated with the medial branches of the posterior primary ramus and its reflex inhibitory mechanism to the multifidus than with other paraspinal muscles.

In the present study, we observed Kim’s twitching; this indicated a close connection between the SVN (including the BVN) and the paraspinal muscles innervated by the posterior ramus of the spinal nerve. When RFA is applied to the hypersensitive SVN and BVN, branches of the primary ventral ramus stimulate aberrant connections with the traversing nerve or exiting nerve root. A strong impulse then propagates along the posterior ramus of the spinal nerve and knock down its inhibitory mechanism. Eventually, the multifidus alleviated. This mechanism may be the main cause of postoperative paraspinal (multifidus + erector spinae) CSA increase. The results of the present study suggest that multifidus muscle spasms would be alleviated if the reflex inhibitory mechanism were disconnected or diminished by RFA.

The present study has several limitations. First, the study populations were not homogeneous in age, gender, pathology, or number of patients, so the results may not have represented the actual difference between these 2 patient groups. Second, to reduce modification to the minimum, the CSA was assessed by carefully outlining the muscle mass, excluding fat and fibrous tissue external to the muscle fascia, and measuring the average value from 2 consecutive slices. Al-

though value modification was minimized in this way, it could not be excluded entirely. Third, the study did not show changes in the entire lumbar paravertebral muscle, because only the L4–L5 and L5–S1 levels were included. A larger prospective trial with 3D muscle reconstruction using specific software (Muscl’ X or custom software) should be performed to measure the entire muscle volume. Fourth, the changed muscle observed after surgery may not have been permanent.

Despite these limitations, the present study was meaningful as a first step to find an aberrant pathway between the hypersensitive SVN, BVN, and paraspinal muscles, especially the multifidus.

CONCLUSION

Hypersensitive SVN and BVN are strongly associated with epidural neovascularization with adhesion and the pathological pain pathway in degenerative disc disease. Epidural neovascularization with adhesion reflects the aberrant neurological connections, which are associated with reflex inhibitory mechanisms of the multifidus muscle, which induces the spasm. RFA treatment of epidural neovascularization with adhesion effectively treated chronic discogenic back pain and could alleviate paraspinal muscle spasm.

Acknowledgments

Hyeun-Sung Kim and Ji Yeon Kim contributed equally to this work as first authors. We thank Keong Rae Kim who contributed to the statistical analysis of the data and Jae Eun Park for coordinating the scientific research. We would like to thank Editage (www.editage.co.kr) for English language editing.

Ethics Statement

This study was approved by the Ethics Committee of Nanoori Hospital. Informed consent was obtained from the patients. IRB approval number: NR-IRB 2020-018.

REFERENCES

1. Simon J, McAuliffe M, Shamim F, Vuong N, Tahaei A. Discogenic low back pain. *Phys Med Rehabil Clin N Am* 2014; 25:305-317.
2. Roberts S, Evans EH, Kletsas D, Jaffray DC, Eisenstein SM. Senescence in human intervertebral discs. *Eur Spine J* 2006; 15:S312-316.
3. Fagan A, Moore R, Vernon Roberts B, Blumbergs P, Fraser R. ISSLS prize winner: The innervation of the intervertebral disc: A quantitative analysis. *Spine (Phila Pa 1976)* 2003; 28:2570-2576.
4. Ohtori S, Miyagi M, Inoue G. Sensory nerve ingrowth, cytokines, and instability of discogenic low back pain: A review. *Spine Surg Relat Res* 2018; 2:11-17.
5. Garcia-Cosamalon J, del Valle ME, Calavia MG, et al. Intervertebral disc, sensory nerves and neurotrophins: Who is who in discogenic pain? *J Anat* 2010; 217:1-15.
6. Chen JY, Ding Y, Lv RY, et al. Correlation between MR imaging and discography with provocative concordant pain in patients with low back pain. *Clin J Pain*

- 2011; 27:125-130.
7. Lam KS, Carlin D, Mulholland RC. Lumbar disc high-intensity zone: The value and significance of provocative discography in the determination of the discogenic pain source. *Eur Spine J* 2000; 9:36-41.
 8. Carragee EJ, Paragioudakis SJ, Khurana S. 2000 Volvo Award winner in clinical studies: Lumbar high-intensity zone and discography in subjects without low back problems. *Spine (Phila Pa 1976)* 2000; 25:2987-2992.
 9. Park KW, Song KS, Chung JY, et al. High-intensity zone on L-spine MRI: Clinical relevance and association with trauma history. *Asian Spine J* 2007; 1:38-42.
 10. Teraguchi M, Yim R, Cheung JP, Samartzis D. The association of high-intensity zones on MRI and low back pain: A systematic review. *Scoliosis Spinal Disord* 2018; 13:22.
 11. Brinjikji W, Diehn FE, Jarvik JG, et al. MRI findings of disc degeneration are more prevalent in adults with low back pain than in asymptomatic controls: A systematic review and meta-analysis. *AJNR Am J Neuroradiol* 2015; 36:2394-2399.
 12. Hartvigsen J, Hancock MJ, Kongsted A, et al. What low back pain is and why we need to pay attention. *Lancet* 2018; 391:2356-2367.
 13. Kim HS, Wu PH, Jang IT. Lumbar degenerative disease part 1: Anatomy and pathophysiology of intervertebral discogenic pain and radiofrequency ablation of basivertebral and sinuvertebral nerve treatment for chronic discogenic back pain: A prospective case series and review of literature. *Int J Mol Sci* 2020; 21:1483.
 14. Schizas C, Theumann N, Burn A, et al. Qualitative grading of severity of lumbar spinal stenosis based on the morphology of the dural sac on magnetic resonance images. *Spine (Phila Pa 1976)* 2010; 35:1919-1924.
 15. Henderson L, Kulik G, Richarme D, Theumann N, Schizas C. Is spinal stenosis assessment dependent on slice orientation? A magnetic resonance imaging study. *Eur Spine J* 2012; 21:S760-S764.
 16. Li Y, Feng X, Tan J, Peng B. Letter to the Editor concerning "Intraosseous basivertebral nerve ablation for the treatment of chronic low back pain: A prospective randomized double-blind sham-controlled multi-center study" by Fischgrund JS, et al. (Qualitative grading of severity of lumbar spinal stenosis based on the morphology of the dural sac on magnetic resonance images. 2018 27:1146-1156). *Eur Spine J* 2019; 28:2223.
 17. Danneels LA, Vanderstraeten GG, Cambier DC, Witvrouw EE, De Cuyper HJ. CT imaging of trunk muscles in chronic low back pain patients and healthy control subjects. *Eur Spine J* 2000; 9:266-272.
 18. Cooper RG, St Clair Forbes W, Jayson MI. Radiographic demonstration of paraspinal muscle wasting in patients with chronic low back pain. *Br J Rheumatol* 1992; 31:389-394.
 19. Hultman G, Nordin M, Saraste H, Ohlson H. Body composition, endurance, strength, cross-sectional area, and density of MM erector spinae in men with and without low back pain. *J Spinal Disord* 1993; 6:114-123.
 20. Hodges P, Holm AK, Hansson T, Holm S. Rapid atrophy of the lumbar multifidus follows experimental disc or nerve root injury. *Spine (Phila Pa 1976)* 2006; 31:2926-2933. doi:10.1097/01.brs.0000248453.51165.ob
 21. Kader DF, Wardlaw D, Smith FW. Correlation between the MRI changes in the lumbar multifidus muscles and leg pain. *Clin Radiol* 2000; 55:145-149.