

Narrative Review

Ultrasound-Guided Nerve Blocks in the Head and Neck for Chronic Pain Management: The Anatomy, Sonoanatomy, and Procedure

Jinpu Li, MD¹, and Alexandra Szabova, MD²

From: ¹Department of Physical Medicine and Rehabilitation, Montefiore Medicine Center, Albert Einstein College of Medicine, Bronx, NY;

²Department of Anesthesiology, Cincinnati Children's Hospital, Cincinnati, OH

Address Correspondence: Jinpu Li, MD

Department of Physical Medicine and Rehabilitation, Montefiore Medicine Center, Albert Einstein College of Medicine
150 East 210 St.
Bronx, NY 10461

E-mail: jili@montefiore.org

Disclaimer: There was no external funding in the preparation of this manuscript.

Conflict of interest: Each author certifies that he or she, or a member of his or her immediate family, has no commercial association (i.e., consultancies, stock ownership, equity interest, patent/licensing arrangements, etc.) that might pose a conflict of interest in connection with the submitted manuscript.

Manuscript received: 02-19-2021

Revised manuscript received: 07-16-2021

Accepted for publication: 08-16-2021

Free full manuscript: www.painphysicianjournal.com

Background: Ultrasound guided nerve blocks have become a popular tool in the armamentarium for pain physicians because of its advantages over fluoroscopy by offering portable, radiation-free and real-time imaging. But ultrasound guided procedures require training and practice to gain the expertise. There is a scarcity of review articles describing ultrasound guided injections techniques for nerve blocks of the head and neck.

Objective: To elucidate the anatomy, sonoanatomy, indications, techniques, side effects and complications for the most frequently utilized nerve blocks of the head and neck in chronic pain management.

Study Design: Narrative review.

Setting: Academic medical center.

Methods: Literature review of publications in English language of the related topics using Medline (Ovid) search engine.

Results: Deep cervical plexus block, cervical sympathetic ganglion block, trigeminal nerve and pterygopalatine ganglion block at the pterygopalatine fossa, greater occipital nerve block, third occipital nerve and medial branch block, and cervical selective nerve root block are discussed in this paper. The review begins with in depth discussion about the anatomy of the target nerve, followed by reviewing the available literature on the indications for the procedures. Detailed description of the procedure techniques is also presented. The volume and selection of medications is also discussed if there is available research. The review will conclude with summary of side effects, complications and precautions.

Limitation: We only review those nerve blocks of the head and neck that would benefit from ultrasound guided injections in chronic pain management. Other nerve blocks such as transnasal sphenopalatine ganglion block, the interscalene brachial plexus block, superficial and intermediate cervical plexus block, anterior suprascapular nerve block, superficial trigeminal nerve block are not discussed due to either that ultrasound guidance is not warranted or they are rarely utilized in chronic pain management. This paper is not a systematic review, thus it might not include all the available evidence. Many of the available evidence is case series and case reports. More randomized control studies are warranted in the future to validate these techniques.

Conclusion: Ultrasound guided nerve blocks of the head and neck are useful techniques for pain physicians to learn.

Key words: Cervical plexus block, cervical ganglion block, pterygopalatine ganglion block, trigeminal nerve block, greater occipital nerve block, medial branch block, selective nerve root block

Pain Physician 2021; 24:533-548

Various nerve blocks that have been developed to treat chronic pain in the head, neck, and upper extremities. Over the years, the techniques evolved from landmark-based blind injections to fluoroscopy-guided procedures, which are not without limitations. These techniques rely on the bony landmarks seen on the fluoroscopy without visualization of the soft tissues, such as spinal cord, nerve, vessels, ligaments, tendons, and muscles in the area of interest. With the increased availability and affordability of high resolution ultrasound machines, it has become a common practice to use ultrasound guidance in chronic pain management procedures. With real-time ultrasound guidance, one can plan the needle trajectory to avoid injury to the nerve and vasculature, visualize the needle tip, avoid intravascular injection, and directly visualize the injectate being deposited at the target structure. Ultrasound examination is operator dependent and requires training and practice to gain expertise. At times, it may be limited by the patient's body habitus. Under these circumstances, fluoroscopy and ultrasound can complement each other. In this article, we describe some of the commonly utilized ultrasound-guided nerve blocks in the head and neck.

Deep Cervical Plexus Blocks

Anatomy

The cervical plexus, formed by the anterior rami of the C1-C4 spinal nerves, emerges the vertebral column from a groove between the longus capitis and the middle scalene muscles, lying deep to the internal jugular vein. Its 4 cutaneous branches, namely the lesser occipital nerve (C2), the great auricular nerve (C2, C3), transverse cervical nerve (C2, C3), and supraclavicular nerve (C3, C4), emerge near the midpoint of the posterior border of the sternocleidomastoid (SCM) muscle and supply the cutaneous sensation of the upper neck, the scalp behind the ear, the skin over the parotid gland, the anterior triangle of the neck, and the top of the shoulder and upper chest (1), (Fig. 1). The deep cervical plexus consists of the ansa cervicalis, with its motor branches supplying the infrahyoid muscles. It is thought that the deep cervical plexus also has afferent components, and the cervical plexus has anastomosis with cranial nerves X, XI, XII, and sympathetic trunk (2). The phrenic nerve arises from the ventral rami of the C3, C4, and C5 spinal nerves and is in close vicinity of the deep cervical plexus.

The deep cervical fascia is divided into 3 distinctive layers: the superficial (SLDCF), middle (MLDCF), and

deep (DLDCF), (Fig. 2). The SLDCF, also known as investing fascia, encases the sternocleidomastoid and trapezius muscles at the neck. Conventionally, the MLDCF, also known as the visceral fascia or pretracheal fascia, invests around the infrahyoid muscles, thyroid gland, trachea, esophagus, and pharynx. DLDCF, also known as prevertebral fascia, is described as the fascia layer that encompasses the vertebral column and intrinsic spinal muscles. The DLDCF attaches to the transverse and spinous processes of the cervical vertebrae (3).

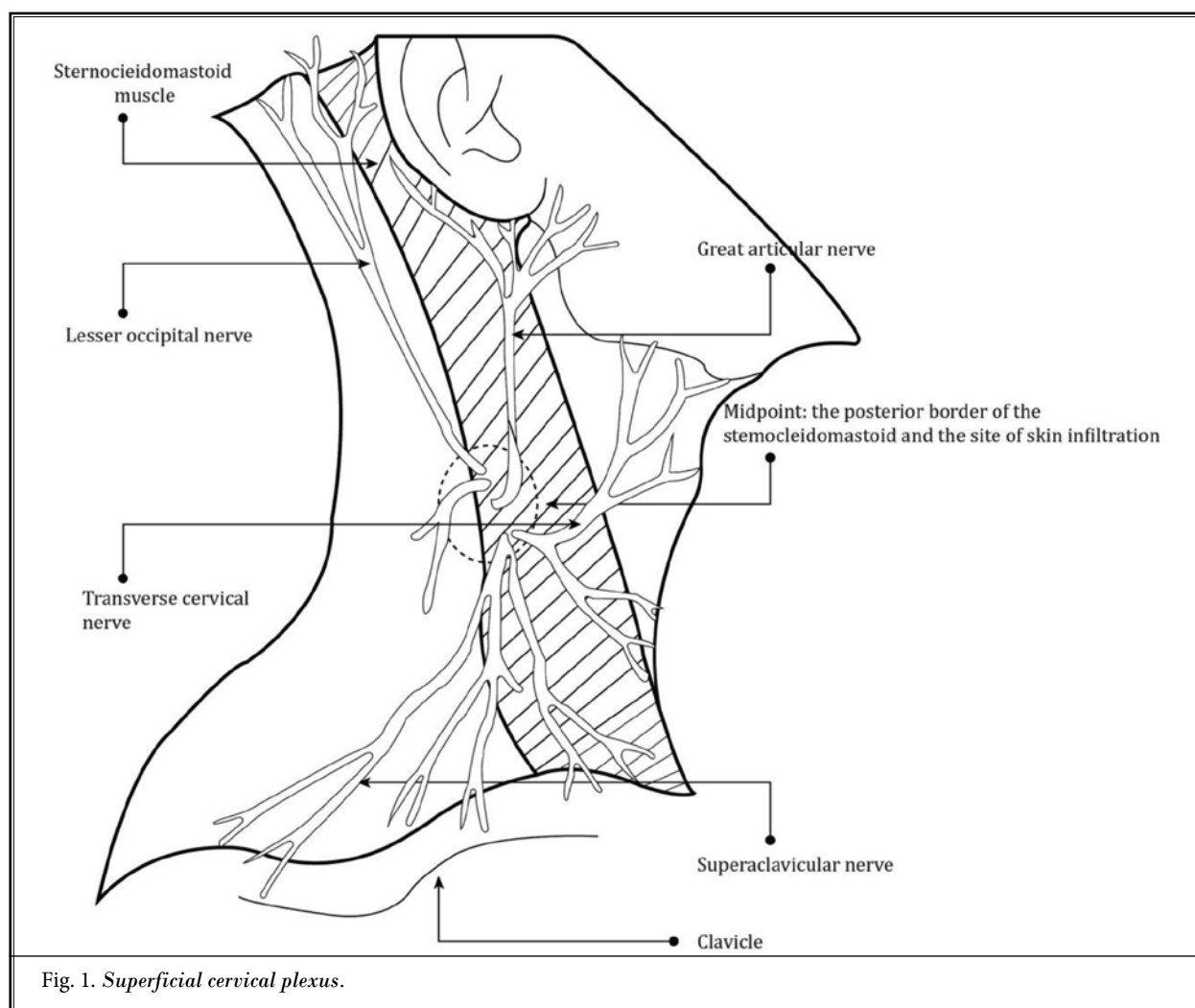
There are 3 different cervical plexus blocks - superficial, intermediate, and deep. In a superficial cervical plexus block, the injectate is deposited in the subcutaneous tissue superficial to the SLDCF/investing fascia. In the intermediate cervical plexus block, the injectate is deposited between investing fascia and the prevertebral fascia. In the deep cervical plexus, the injectate is deposited between the prevertebral fascia and the cervical transverse process (4).

Indications

Superficial and intermediate cervical plexus blocks are mainly used for operative and post-operative pain control. The deep cervical plexus block has been used to treat cervicogenic headache (5). In addition to cutaneous blockage, deep cervical plexus block also causes motor blockade of the infrahyoid muscles, thus is appropriate for surgeries requiring retraction or involving the infrahyoid and SCM muscles, such as carotid endarterectomy (6) and minimally invasive parathyroidectomy (7).

Technique

With the patient in a supine position, head and ipsilateral shoulder resting on a pillow or towel roll, head turning to the opposite side, a linear transducer is placed in the axial plane at the posterior border of the SCM at the cricoid cartilage level, which corresponds to the C6 vertebral level (Image 1). Move the transducer rostrally until the bifurcation of the carotid artery is seen; this is the C3-C4 vertebral level. Move the probe rostrally and caudally, anteriorly and posteriorly to optimize the view of the C4 transverse process, the longus capitis, and scalene muscles. The transverse process has hyperechoic anterior and posterior tubercles with posterior shadowing. The anterior tubercle of the C4 transverse process is equal to or smaller than its posterior tubercle. This characteristic helps to differentiate C4 from the C5 and C6, whose anterior tubercles are bigger than the posterior tubercle. The C4 nerve root will be seen



exiting between the tubercles. At this level, the anterior scalene, middle scalene, and levator scapulae lie posterior and deep to the SCM and are wrapped in the prevertebral fascia (Image 2). Use color Doppler to identify the vessels and the nerve roots, which should be avoided in the needle trajectory. With an in-plane approach, a 22-25G block needle is advanced from posterolateral to anteromedial until it pierces the prevertebral fascia and is in contact with the posterior tubercle of C4 transverse process. Slightly withdraw the needle, deposit 1-2 mL local anesthetic to confirm proper location, then a total of 10-15 mL of local anesthetic is administered after negative aspiration. Up to date, there is no study that investigates the spread of different volumes of the injectate used in the deep cervical plexus block; 10-15 mL is the conventional volume.

Side Effects and Complications

Side effects and complications include: epidural spread; intrathecal injection; blockade of the phrenic nerve causing diaphragm paresis (8); vocal cord paralysis and airway obstruction due to inadvertent block of vagus and hypoglossal nerves (9); Horner's syndrome due to cervical sympathetic block (10); and risk of intravascular injection. There is widely accepted agreement that both sides should not be blocked simultaneously, and proceeding with the block should be cautious in patients with compromised respiratory capacity.

Cervical Sympathetic Ganglion Block

Anatomy: Cervical sympathetic chain fibers originate from T1-T6 spinal cord and ascend along the neck anterior to the longus colli and longus capitis muscles. They are posteromedial to the carotid artery and under

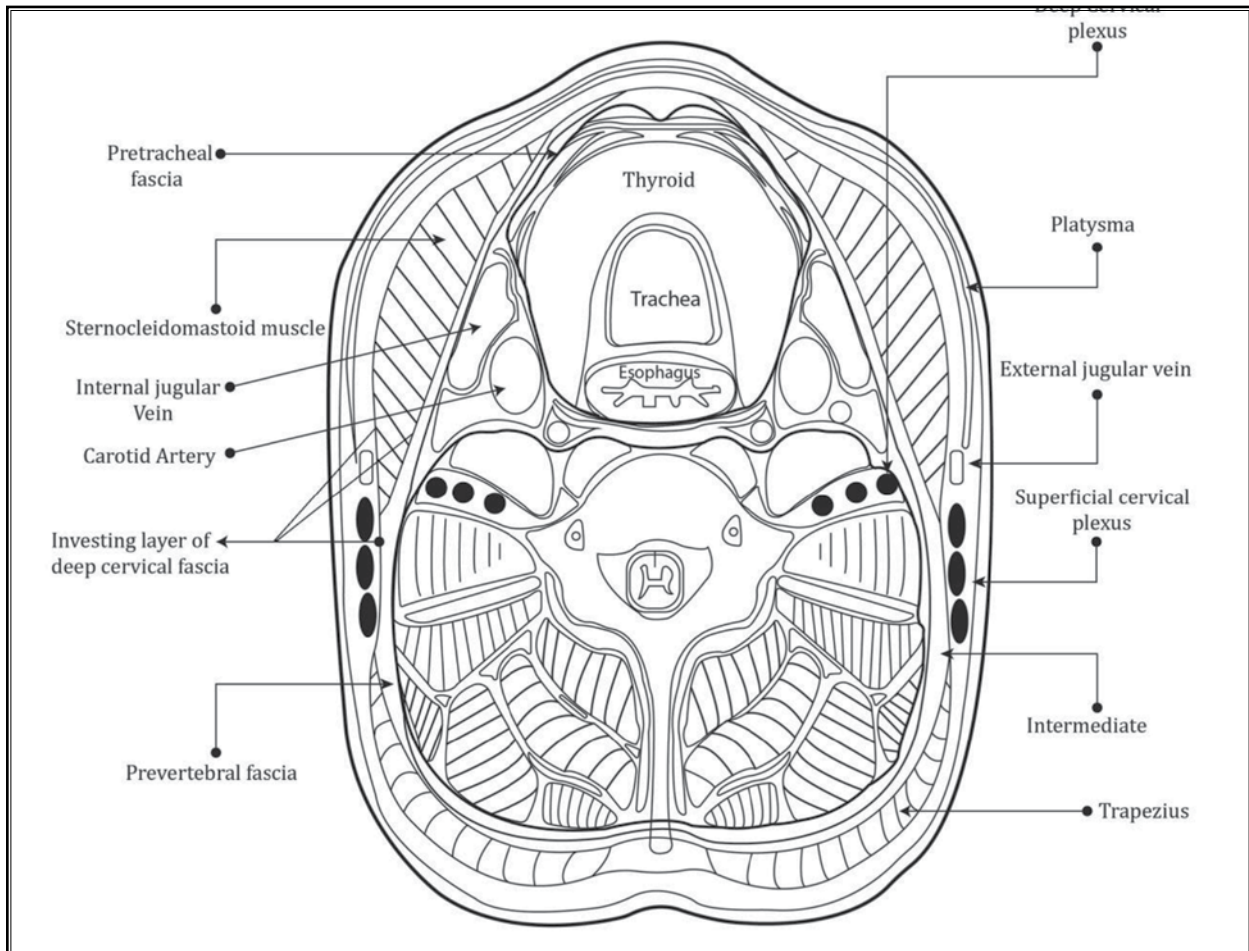


Fig. 2. Deep cervical fascia.

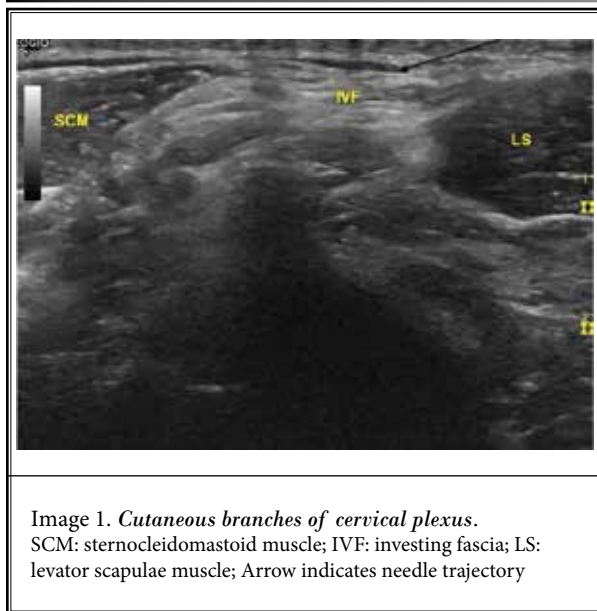


Image 1. Cutaneous branches of cervical plexus.
SCM: sternocleidomastoid muscle; IVF: investing fascia; LS: levator scapulae muscle; Arrow indicates needle trajectory

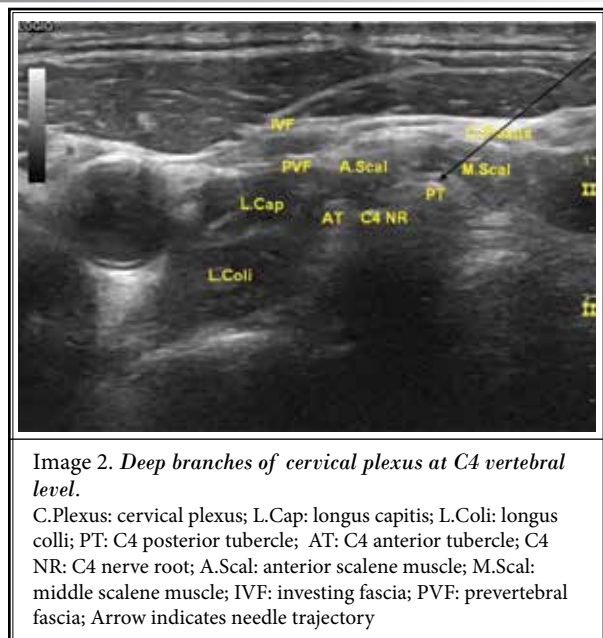


Image 2. Deep branches of cervical plexus at C4 vertebral level.
C.Plexus: cervical plexus; L.Cap: longus capitis; L.Coli: longus colli; PT: C4 posterior tubercle; AT: C4 anterior tubercle; C4 NR: C4 nerve root; A.Scal: anterior scalene muscle; M.Scal: middle scalene muscle; IVF: investing fascia; PVF: prevertebral fascia; Arrow indicates needle trajectory

the prevertebral fascia. Their cell bodies congregate to form the superior, middle, and inferior cervical sympathetic ganglion.

The superior cervical sympathetic ganglion is the most superior ganglion of the sympathetic chain, and its relation to the vertebral level varies. In one study by Mistuoka et al, it is at the C2, C3 level, and in another study by Erdinc et al it is at the C4 level (11,12). The superior cervical sympathetic ganglion has postganglionic fibers to the dilator pupillae muscle, the internal and external carotid artery, the cardiac plexus, the pharyngeal plexus, CN IX, X, and gray rami communicantes of the C1-C4 spinal nerves. The location of the middle cervical sympathetic ganglion is variable, most commonly at C6 level, but can be as high as C5 and as low as C7, and sometimes can be absent. Its postganglionic fibers contribute to the C5, C6 gray rami com-

municantes and the cardiac plexus (11,12). The inferior cervical ganglion is situated at the C7 level and often fuses with the first thoracic ganglion to form the stellate ganglion (Fig. 3). It sends gray rami communicantes to the seventh and eighth cervical spinal nerves, and its postganglionic fibers contribute to the cardiac plexus.

Indications

Complex regional pain syndrome types I and II of the upper limb and sympathetic mediated pain of the head and face. There are also case reports for epileptic pain (13) and poststroke thalamic mediated pain (14). Cervical sympathetic ganglion block has gained attention in treating post traumatic stress disorder (PTSD) in chronic pain patients. But a randomized, double-blind, controlled study by Hanling et al (15) failed to show superiority of stellate ganglion block over sham block.

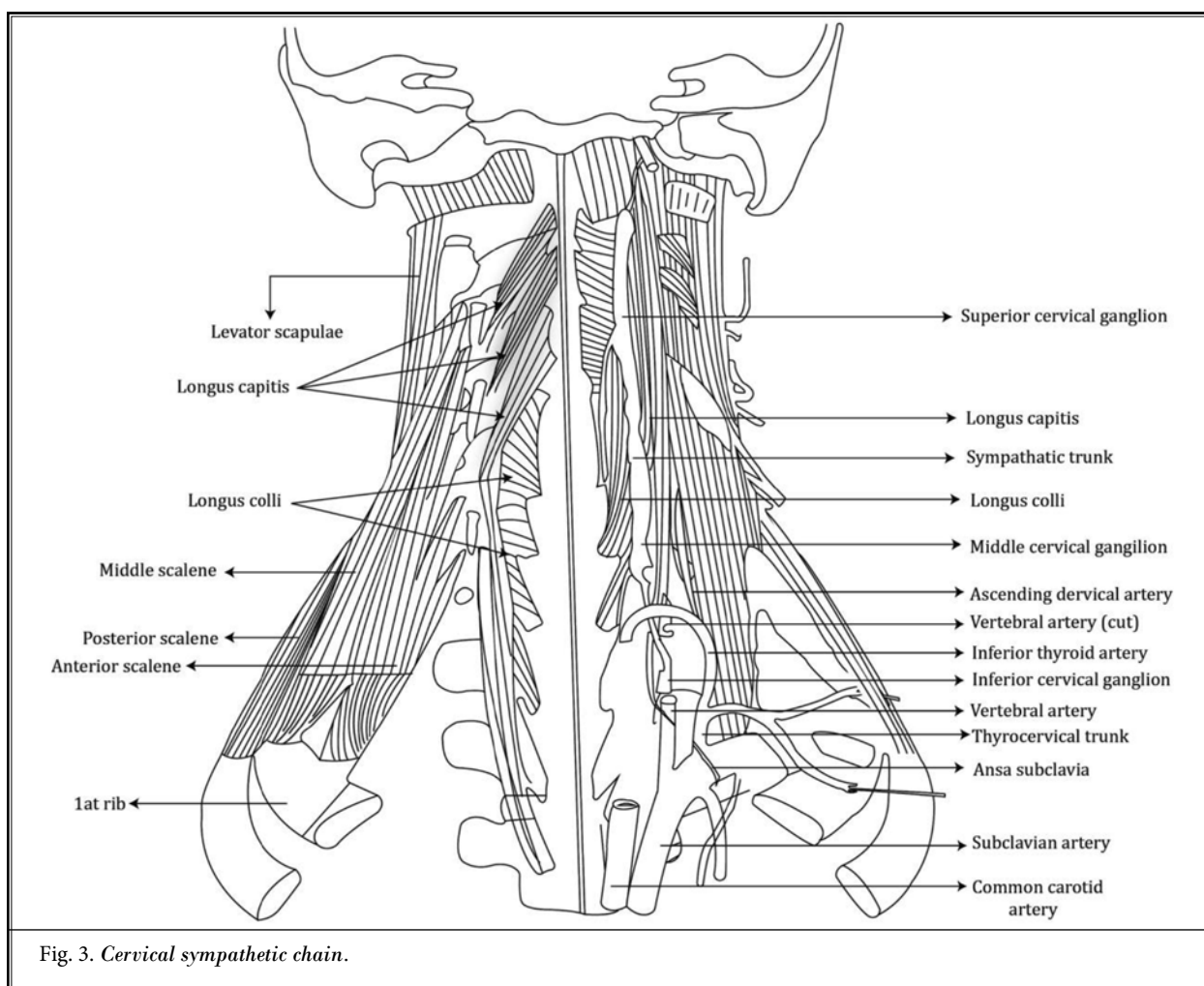


Fig. 3. Cervical sympathetic chain.

Technique

The patient is placed in a supine position with the neck in slight extension, head turning to the opposite side. The linear transducer is positioned posterior to the SCM at the level of the cricoid cartilage (C6 vertebral level). Identify the Chassaignac’s (anterior) tubercle of the C6 transverse process, which is bigger than its posterior tubercle. It is a useful sonographic characteristic to differentiate it from C7 whose transverse process is lack of an anterior tubercle. The inferior cervical/stellate ganglion situates anterior to the longus colli muscle behind the wrapping prevertebral fascia. At the C4 level, the superior ganglion is anterior to the longus capitis muscle beneath the prevertebral fascia. For stellate ganglion block, with in-plane approach, a 22-25 G block needle, from posterolateral to anteromedial, is directed to the prevertebral fascia between the carotid artery and the tip of C6 anterior tubercle, anterior to the longus colli muscle (Image 3). Five to 10 mL of local anesthetic is injected under the prevertebral fascia plane. Indications of a successful block are one or more of the following signs and symptoms: patient develops ipsilateral Horner’s syndrome (ptosis, miosis, and anhidrosis), nasal congestion, facial flushing, or increase in temperature of the upper extremity. The symptoms will appear in about 10 minutes and last for several hours depending on the local anesthetics used. When treating head and facial

pain and PTSD, some practitioners prefer to block the cervical ganglions at the C4 (Image 4), and C6 level with 5 mL injectate at each site. A total 10 mL of injectate is usually used, although one research study showed that 5 mL of local anesthetics injected at C6 level is enough to distribute from C4 to T3 (16). The most frequently used injectate is local anesthetic. Clonidine, ketamine, and buprenorphine (ganglionic local opioid analgesia [GLOA]) have also been investigated, but the evidence is limited (17-19).

Side Effects and Complications

Horner’s syndrome, hoarseness, subjective feeling of lump in the throat, or subjective shortness of breath due to blockade of the recurrent laryngeal nerve. Local spread of anesthetics can cause cervical and brachial plexus blockade. Respiratory difficulty can result from phrenic paralysis. There was a report of patient death due to massive hematoma leading to airway obstruction (20). Quadriplegia due to cervical epidural abscess and discitis have been reported (20). Intravascular injection can result in seizure, hypotension, and loss of consciousness (21). Intrathecal, subdural injection and epidural spread can cause respiratory compromise. One case of locked-in syndrome was also reported (22). Risk of pneumothorax is also a concern. Standard monitoring and full resuscitative equipment should always be available when cervical ganglion block is performed.

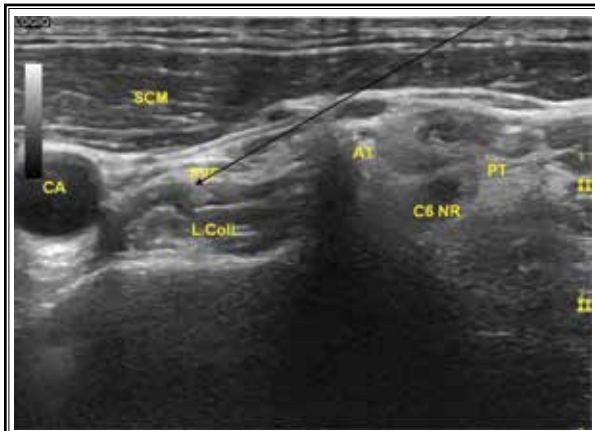


Image 3. *Superior cervical ganglion at C4 vertebral level.* SCM: sternocleidomastoid muscle; IVF: investing fascia; PVF: prevertebral fascia; L.Cap: longus capitis muscle; L.Coli: longus colli muscle; A.Scal: anterior scalene muscle; M.Scal: middle scalene muscle; CA: carotid artery; AT: C4 anterior tubercle; PT: C4 posterior tubercle; Arrow indicates needle trajectory

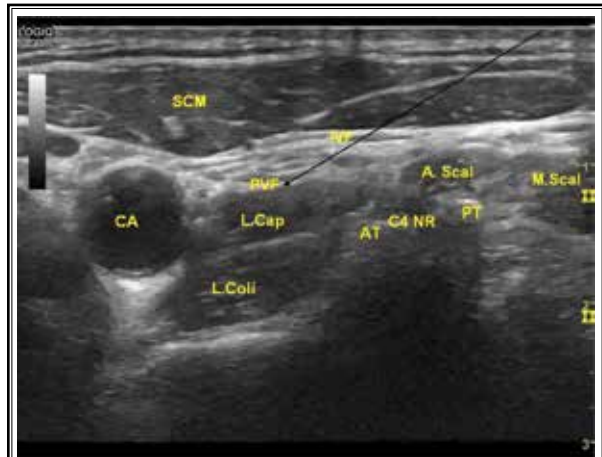


Image 4. *Inferior cervical ganglion at C6 vertebral level.* SCM: sternocleidomastoid muscle; PVF: prevertebral fascia; L.Coli: Longus colli muscle; CA: carotid artery; AT: C6 anterior tubercle; PT: C6 posterior tubercle; C6 NR: C6 nerve root; Arrow indicates needle trajectory

Trigeminal Nerve and Pterygopalatine Ganglion Block at the Pterygopalatine Fossa

Anatomy

The trigeminal nerve carries sensory fibers to the face and motor fibers of mastication. The trigeminal ganglion (the Gasserian or semilunar ganglion) lies in Meckel's cave in the middle cranial fossa. Three of its divisions, namely the ophthalmic nerve (V1), the maxillary nerve (V2), and the mandibular nerve (V3) pass through the cranium via the superior orbital fissure (V1), foramen rotundum (V2), and foramen ovale (V3). The maxillary nerve exits the cranium through the foramen rotundum and enters the pterygopalatine fossa, which is a small pyramidal space inferior to the apex of the orbit. Posteriorly, it is bordered by the lateral pterygoid plate of the sphenoid. Anteriorly, is the posterior aspect of the maxilla. Its medial wall is the perpendicular plate of the palatine bone. Laterally, through the pterygomaxillary fissure, it communicates with the infratemporal fossa, where the mandibular nerve lies. Posterosuperiorly, through the foramen rotundum and pterygoid canal, it communicates with the middle cranial fossa, where the trigeminal ganglion sits on the Meckel's cave (Fig. 4). The

pterygopalatine ganglion (also known as sphenopalatine ganglion, Meckel's ganglion, nasal ganglion) lies in the superior part of the pterygopalatine fossa (23). The lateral pterygoid plate, maxillae, and the maxillary artery can be identified through the mandibular notch with ultrasound. Using bony lateral pterygoid plate and maxillae seen on ultrasonography as landmarks, the pterygopalatine fossa is easily identifiable and accessible with ultrasound guidance. Local anesthetics injected into the pterygopalatine fossa theoretically can anesthetize the maxillary nerve, mandibular nerve, the pterygopalatine ganglion, and trigeminal ganglion through the spread of the injectate to the infratemporal fossa and the Meckel's cave (24).

Indications are: trigeminal neuralgia, atypical facial pain (25), postherpetic neuralgia, and migraine (26).

Technique

The patient is placed in a lateral decubitus position with the affected side facing up. A curvilinear transducer is preferred. The transducer is placed just below the zygomatic arch in the axial plane, bringing the coronoid and condylar processes into view, which are seen as a hyperechoic line and a hyperechoic dot.

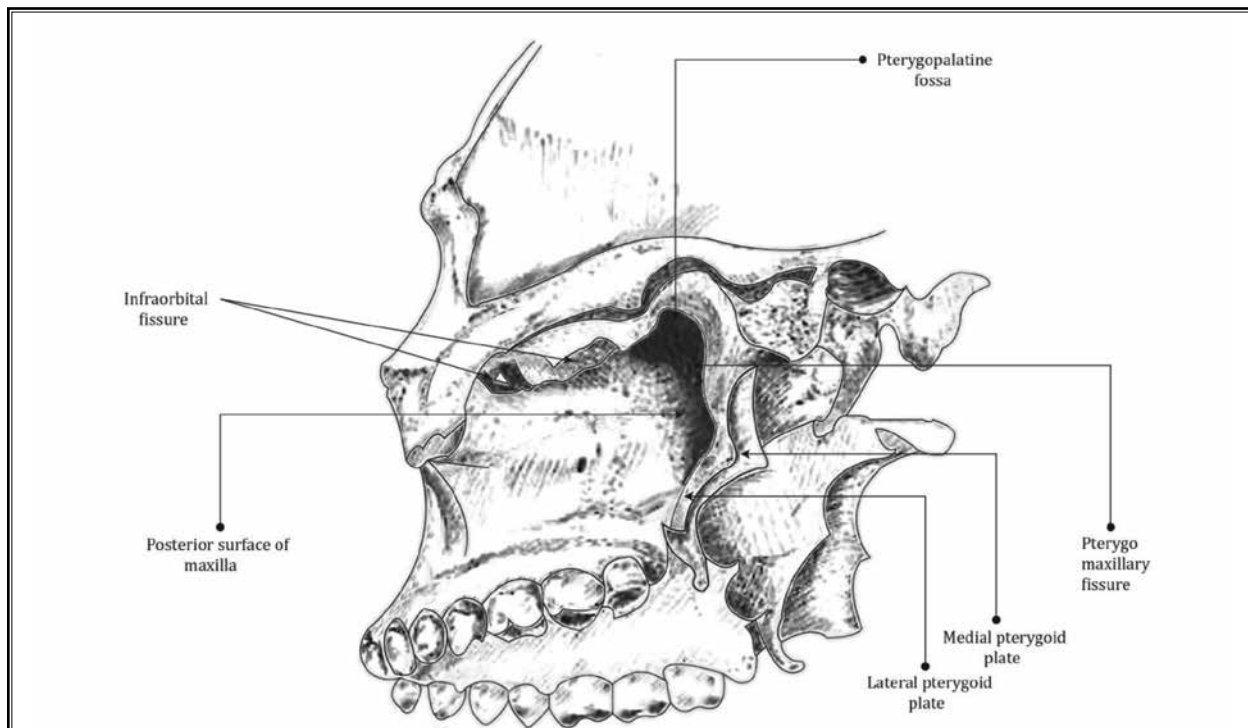


Fig. 4. *Pterygopalantine fossa.*

Between them is the mandibular notch, through which the deeper structures will be seen. The lateral pterygoid plate is seen posterior and the maxilla bone is seen anterior. The space between them is the pterygopalatine fossa. The lateral pterygoid muscle is seen on top of the lateral pterygoid plate and the pulsatile maxillary artery will be seen just superficial to the lateral pterygoid muscle. The sphenopalatine artery, which is a branch of the maxillary artery, can be seen just anterior to the lateral pterygoid plate in the pterygoid palatine fossa (Image 5). Due to the steep trajectory, the needle is advanced using an out-of-plane approach targeting the pterygopalatine fossa. The volume of pterygopalatine fossa is about 1.2 mL on average (27). In the study by Nader, when 1.8 mL of lohexitol 180 was injected, the contrast was seen spreading to Meckel's cave (24). Approximately 2-3 mL of local anesthetics or a combination of local anesthetics and steroid are usually injected, but the optimal injectate volume still needs to be investigated.

Side Effects and Complications

In the case series by Antoun Nader (25), no side effects or complications were reported. But due to the close vicinity of the surrounding neurovascular structures, facial paralysis, difficulty chewing, diplopia, exophthalmos, eye edema, persistent numbness of the face, and hematoma formation were reported in blind injection using a greater palatine foramen approach (28).

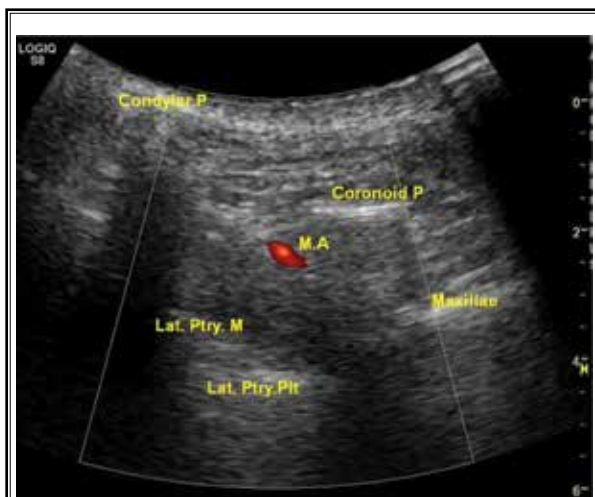

Image 5. *Pterygopalatine fossa through mandibular notch.* Condylar P: condylar process of mandibulae; Coronoid P: coronoid process of mandibulae; M.A.: maxillary artery; Lat.Ptry.M: lateral pterygoid muscle; Lat.Ptry.Plt: lateral pterygoid plate; Maxillae: maxilla bone

Great Occipital Nerve Block

Anatomy: The greater occipital nerve (GON) is the medial branch of the dorsal ramus of the C2 spinal nerve, which lies between the first and second cervical vertebrae. It emerges from the suboccipital triangle just beneath the obliquus capitis inferior (OCI), ascends in the fascia plane between the OCI and semispinalis capitis, and then pierces the semispinalis capitis and travels cephalad deep to the trapezius muscle. It becomes subcutaneous just inferior to the superior nuchal line by piercing through the aponeurotic sling formed by the insertions of the trapezius and sternocleidomastoid. At this point, it lies immediately medial to the occipital artery (Fig. 5). It innervates the scalp at the top of the head, over the ear, and over the parotid glands. The complex involvement with the nearby musculature makes the GON prone to potential compression, entrapment, and irritation. In addition to the GON, the C2 spinal nerve also gives off the sinuvertebral nerve and has meningeal branches (29). Weatherall et al, reported successful treatment of idiopathic trigeminal neuralgia with greater occipital nerve block, proposing that there may be an anatomical pathway between the trigeminal nerve and the upper cervical nerve roots in the trigeminocervical complex (30).

Indications

The GON block is often used to treat occipital neuralgia, cervicogenic headaches, tension headache, and migraine headache (31,32).

Technique

The patient is placed in a prone or sitting position, head in neutral and neck slightly flexing forward. A linear transducer is placed in the axial plane, and can scan from theinion down until the bifurcate spinal process of the C2 is seen, or can scan cephalad from the mid posterior neck, until the OCI appears under the semispinalis capitis. Then turn the lateral edge of the transducer slightly upward toward the C1 transverse process to align with the long axis of the OCI. The greater occipital nerve will be seen lying between the semispinalis capitis and OCI as a hyperechoic dot (Image 6). With an in-plane approach, from lateral to medial, aim to position the needle tip next to the great occipital nerve in the fascia plane between OCI and semispinalis capitis. Caution should be taken to avoid the vertebral artery and the C2 dorsal root ganglion which are lateral to the GON and deep to the COI. The spinal cord is medial and deep to the OCI. After negative aspiration, 5 mL of local anesthetics with

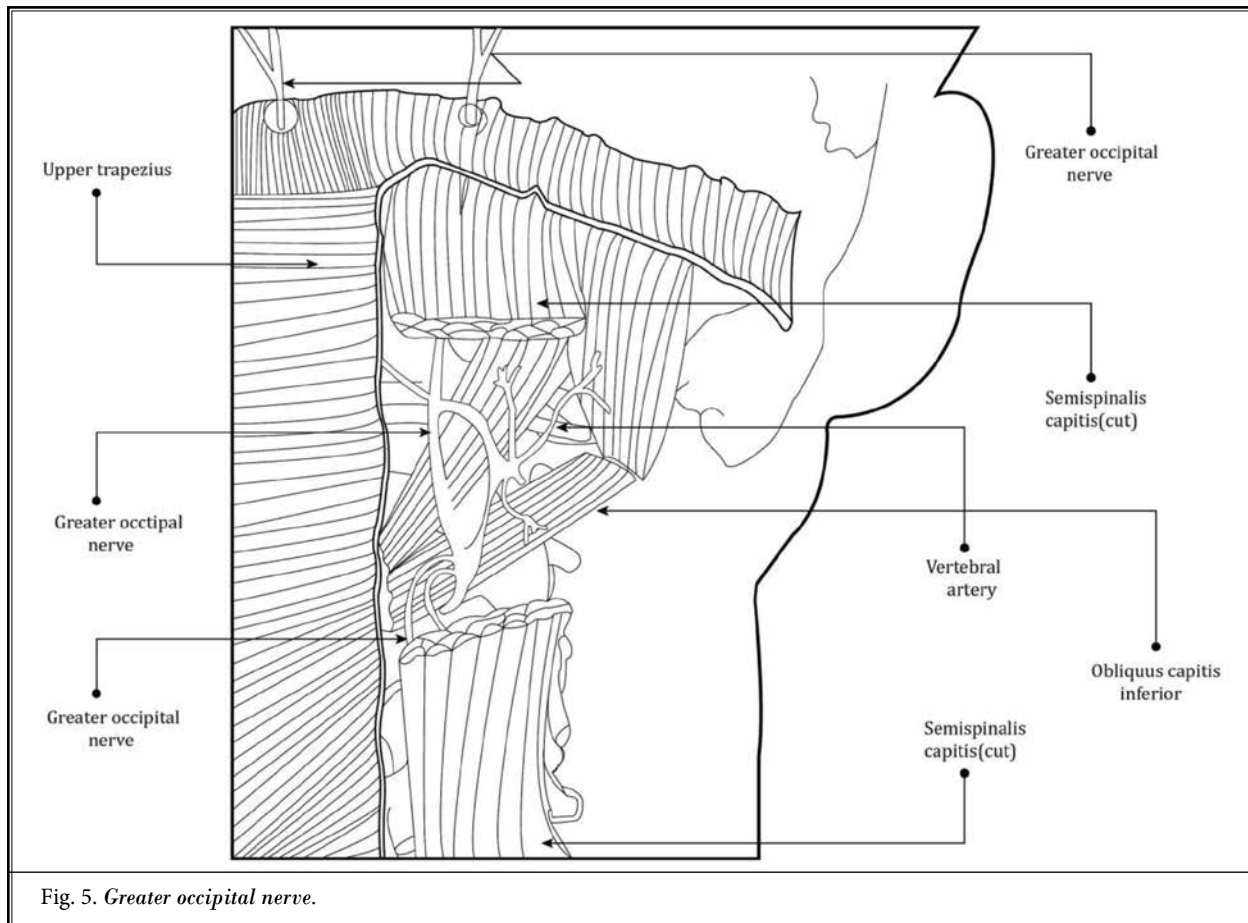


Fig. 5. *Greater occipital nerve.*

or without steroid can be injected. Study showed no difference between 5 mL, 10 mL, and 15 mL injectate in the clinic outcome when treating cervicogenic headache (33). Currently, there are no reported data in regard to if the injectate can spread and anesthetize sinuvertebral nerve or the meningeal branches.

Side Effects and Complications

Although the complications are rare, dizziness, slurred speech, lightheadedness, extreme numbness of the head, hypertension, and asterixis were reported (34). The side effects happen more when the procedure is done bilaterally, in older patients, and in females (34). Given the proximity to neurovascular structures such as the vertebral artery and its branches, the epidural space, and spinal cord, it is important to control the position of the tip of the needle at all times. The needle tip should never be deep to the OCI. The procedure should not be performed bilaterally in one session.

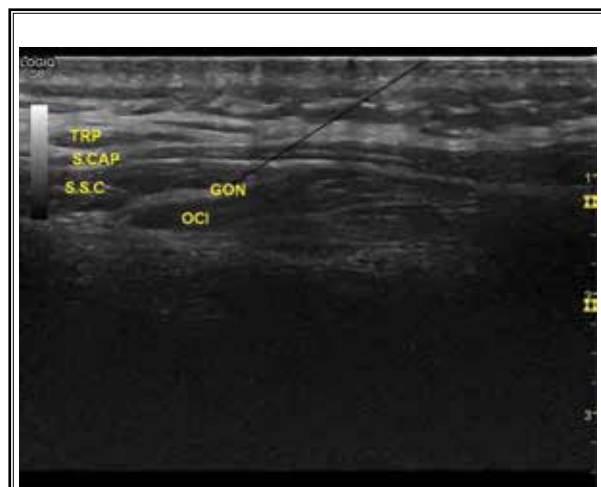


Image 6. *Greater occipital nerve.*

TRP: trapezius; S.Cap: splenius capitis; S.S.C: semispinalis capitis; GON: greater occipital nerve; OCI: obliquus capitis inferior; Arrow indicates needle trajectory

Third Occipital Nerve and Medial Branch Block

Anatomy

The third occipital nerve (TON) is the superficial medial branch of the dorsal ramus of the C3 spinal nerve. It innervates the semispinalis capitis, the C2-C3 zygapophyseal joint, and the skin in the suboccipital region. Immediately after its origin, the third occipital nerve curves around the lateral and posterior aspects of the C2-C3 zygapophyseal joint and crosses the joint laterally. As it crosses this joint, it is embedded in the fascia surrounding the joint capsule, and supplies articular branches to the joint (29).

C4-C8 medial branches arise from the dorsal rami of respective spinal nerves. Each medial branch curves medially and posteriorly around the waist of the articular pillar under the tendinous slips of the semispinalis capitis. Most of the cervical dorsal rami give off one medial branch; however, the higher the vertebral level of dorsal rami is, the higher the chance that it gives off 2 medial branches, namely the superficial and deep medial branches. According to cadaveric studies (35,36), at the C7 and C8 level, the medial branches consistently do not divide into the superficial and deep branch. The superfi-

cial and deep medial branches run together around the articular pillar. Cervical medial branches pass through close to the midpoint of a line between the tips of 2 consecutive superior articular processes and the upper one third of a line between the midpoints of 2 consecutive facet joints (Fig. 6, Fig. 7). The cervical medial branch is about 1.0 mm in diameter. The medial branch innervates the multifidus and interspinales. Its rostral and caudal articular branches, which usually derive from the deep medial branch when the medial branch has deep and superficial branches, innervate the zygapophyseal joint above and below. Each articular branch crosses the joint capsule dorsally and passes through under a pericapsular fibrous tissue deep to the semispinalis capitis (35,36).

Indications are: chronic neck pain from the zygapophyseal joint (37); cervicogenic and suboccipital headache (38) in combination with GON block for migraine; the procedure is possibly effective for trigeminal neuralgia (39).

Technique

The patient is in the lateral decubitus position with the affected side facing up, and a linear transducer is placed in the coronal plane with the cephalic end of

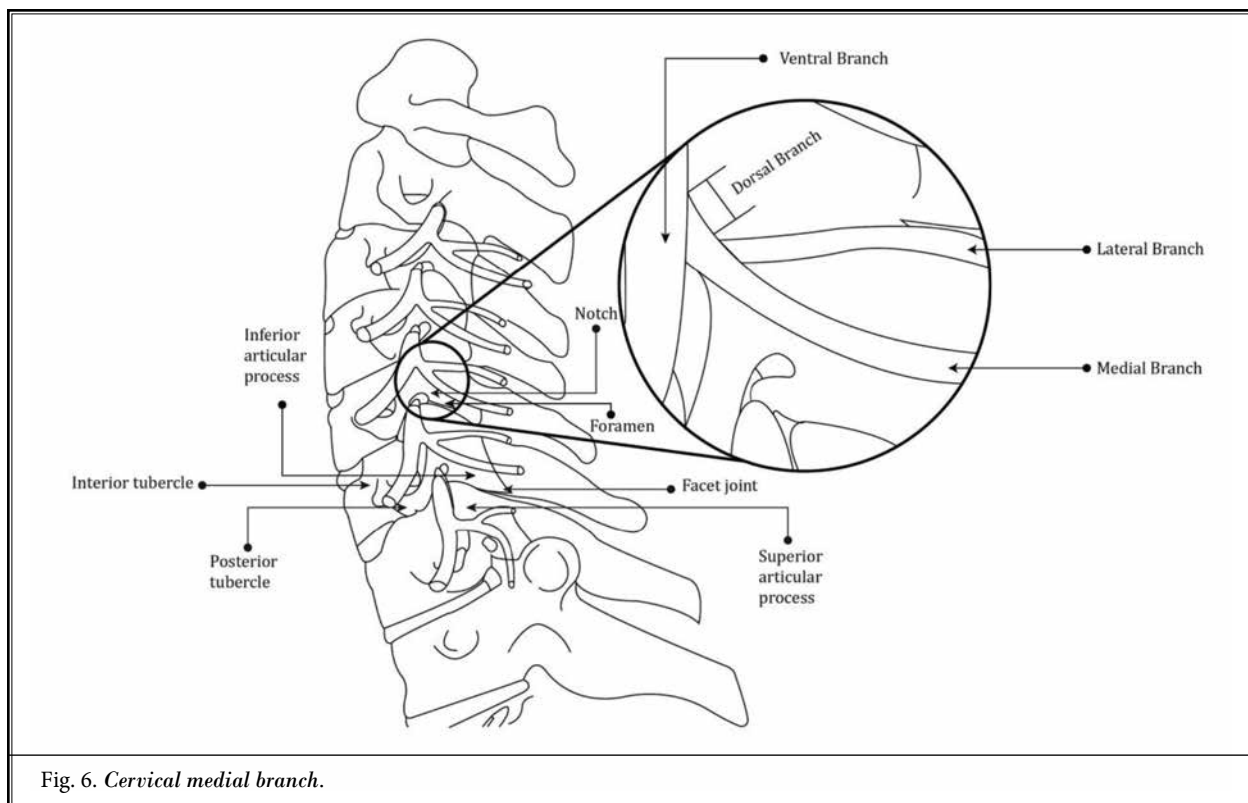


Fig. 6. Cervical medial branch.

the transducer contacting the mastoid process. Move the transducer posteriorly and anteriorly to identify the inferior articular process of C2, which is shown as a drop-off. The vertebral artery can be seen pulsating cephalic to it. Move the transducer caudally to identify the C2-C3 facet joint which shows as a small hypoechoic cleft. The TON sometimes can be seen lying on top of the C2 inferior articular process. Move the transducer caudally while maintaining the coronal position, the articular processes and facet joint are seen as hyperechoic peaks with a hypoechoic cleft. Whereas the hyperechoic medial branches lie at the bottom of the valley (Image 7).

With an in-plane approach, a 22-25G block needle is advanced from inferior to superior or superior to inferior, depending on the intended level, from superficial to deep. For a TON block, the target is the near C2-C3 facet joint. For the C4-C7 medial branches, the target is the deepest point of the valley formed by the continuous hyperechoic bony ridge. Under direct observation, 0.3-0.9 mL of a local anesthetic is injected. In a cadaveric study using fluoroscopic guidance by Wahezi et al (40) 0.25 mL injectate is adequate to bathe the medial branches and less spread to the surrounding structures,

thus increasing the specificity when it is done for diagnostic purposes. Precaution should be taken to avoid the nearby vertebral artery, radicular feeder arteries, nerve roots, and spinal cord.

Side Effect and Complications

There is scarce information in regard to the safety profile of the ultrasound guided cervical medial branch block. Injuries to the vertebral artery, cervical nerve roots, spinal cord, and intravascular injection are all legitimate concerns. From the literature about the fluoroscopy guided injections, severe complications such as respiratory failure and quadriplegia have been reported (41). It is advised to avoid blocking more than 3 levels on one side or blocking both sides on the same day.

Cervical Selective Nerve Root Block (cSNRB)

Anatomy

Each spinal cord segment gives off about 8 rootlets on each side to form one dorsal and one ventral spinal nerve root, which then merge together to form the spinal nerve. The dorsal root ganglion lies on the

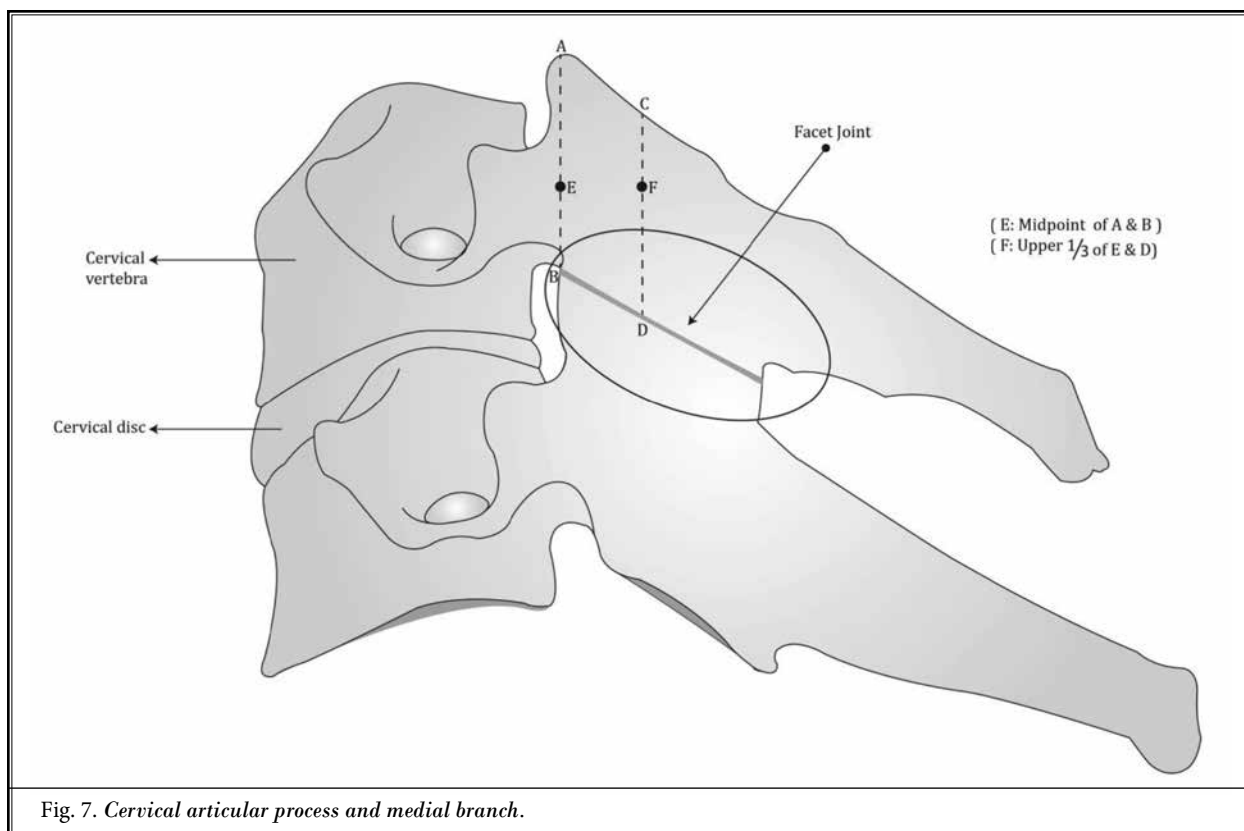


Fig. 7. Cervical articular process and medial branch.

dorsal spinal nerve root proximal to the spinal nerve. The dural root sleeve covers and travels with the spinal nerve roots and stops just beyond the dorsal root ganglion (42) (Fig. 8).

The spinal nerve is very short and branches into the dorsal and ventral rami when it exits the lower part of intervertebral foramen. The ventral and dorsal rami emerge from a groove between the anterior and

posterior tubercle of the transverse process, with the exception of C7 vertebrae, whose transverse process does not have an anterior tubercle. In the vicinity of the spinal nerve, the ventral and posterior ramus, and the epidural vein occupies the upper part of the intervertebral foramen. The ascending cervical, deep cervical, and vertebral arteries are also in proximity and they often enter the foramen posteriorly (43). These arteries contribute to the radicular arteries which supply the spinal cord. The abundance of vasculature near the spinal nerves increases the risk of inadvertent intravascular injection when performing the cSNRB.

The conventionally used term, cervical selective nerve root block, is not totally accurate. The structure identified for cSNRB is actually the rami of the spinal nerve. The spinal nerve root is actually more proximal and is covered by the dural root sleeve. But due to the close vicinity of these neural structures, we would expect the injectate to diffuse to the spinal nerve roots. For the purpose to conform with the conventional terminology, we continue to use the term nerve root here when in reference to the spinal nerve ramus.

There are a total 8 pairs of spinal nerves. Ventral ramus of C1 spinal nerve gives off branches to the suprahyoid muscles that are essential for normal oropharynx function. Ventral rami of C1-C4 spinal nerves

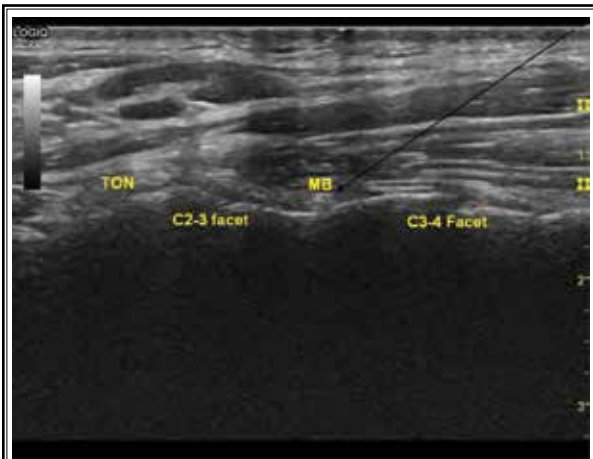


Image 7. Third occipital nerve and medial branches. TON: third occipital nerve; MB: medial branch; Arrow indicates needle trajectory

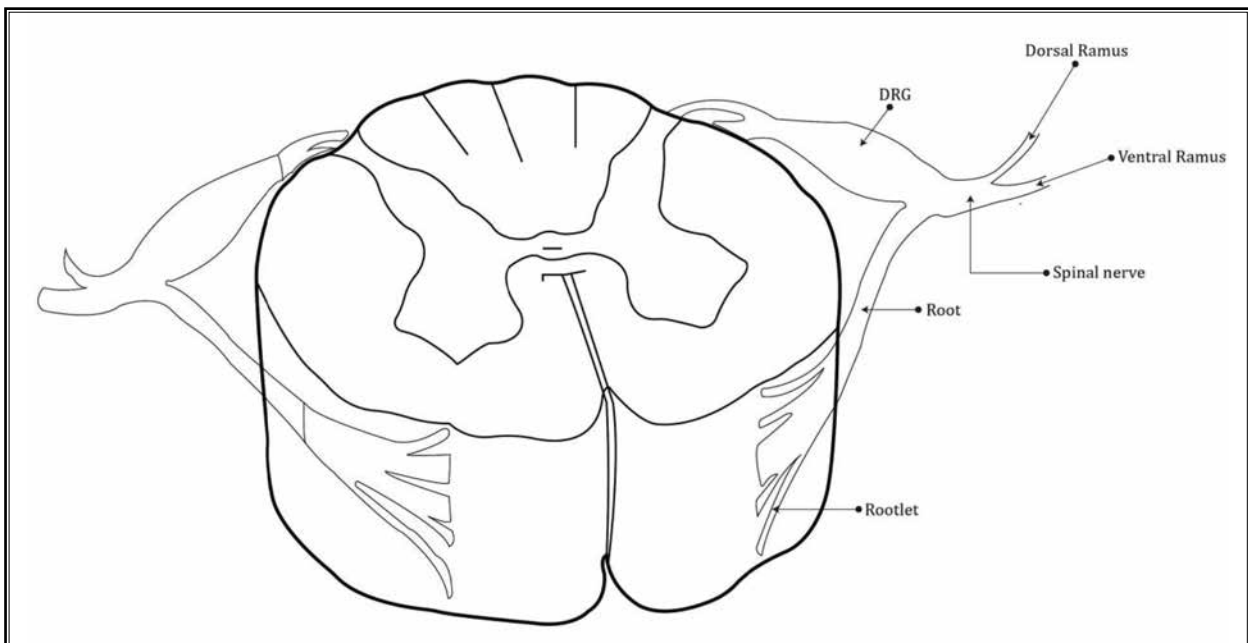


Fig. 8. Rootlet, root, spinal nerve, dorsal ramus and ventral ramus.

form the cervical plexus, which is discussed in detail in the previous session.

The C3, C4, and C5 ventral rami contribute to form the phrenic nerves which are essential for respiration. They arise at the lateral border of the anterior scalene muscle then pass inferiorly over the anterior surface of anterior scalene, deep to the prevertebral layer of cervical fascia.

The C5-C8 ventral rami form the brachial plexus which provides sensory and motor innervations to the upper extremity and some back muscles.

Indications include: diagnosis and treatment for cervical radiculopathy (C4-C8).

Technique

The patient is in a supine position with head resting on a pillow, turning to the opposite side, a towel roll can be used under the ipsilateral shoulder to increase the space between the posterior neck and the bed. A linear transducer is placed in the axial plane at the posterior border of SCM at the cricoid cartilage level. Scan rostrally and caudally to identify the correct vertebral level. The cricoid cartilage is corresponding to the C6 vertebrae level, whereas the thyroid cartilage is usually at C4-C5 vertebrae level. The common carotid artery usually bifurcates at the C3-C4 level. The distinctive characteristics of the C4, C5, C6, and C7 transverse process also help to identify the vertebral levels (see previous descriptions in the section of deep cervical plexus block and cervical sympathetic ganglion block).

At C7 level, the vertebral artery can be visualized just anterior and outside of the transverse process. The vertebral artery usually enters and then ascends through the transverse process foramen at C6 level, but it is not uncommon that it enters the transverse process foramen at a higher level and travels outside the C6 transverse process. The nerve root will be seen as a hypoechoic round structure exiting in a groove formed by the anterior and posterior tubercles of C4-C6 transverse process. At C7 level, the hypoechoic nerve root will be seen anterior to the posterior tubercle. The pulsating vertebral artery can be seen just anterior to it. Once the level is counted and the nerve root is identified, the doppler should be used to identify the vasculature in the vicinity of the nerve root. Too much pressure of the transducer on the skin should be avoided so as not to collapse the pulsation of the vessels (Images 8-11).

The needle is advanced from a posterolateral to anteromedial trajectory with an in-plane approach at the intended level. The target is the external intervertebral foraminal opening between the anterior and posterior tubercles of the transverse process. About 1-2 mL of local anesthetics with or without steroid can be deposited surrounding the nerve root after negative aspiration. If epidural spread is desired, a larger volume (4 mL) of injectate will be required (44). Efforts should be made to avoid the vasculature and neural structures in the needle trajectory and to avoid intravascular and intraneural injection. Use doppler to help identify the surrounding vessels. Using real time fluoroscopy with

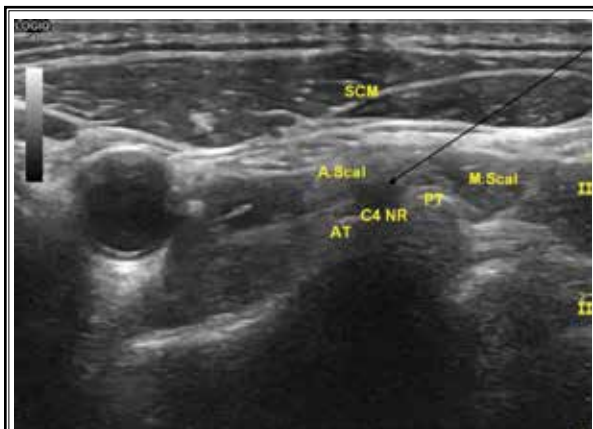


Image 8. C4 nerve root.
C4 NR: C4 nerve root; AT: C4 anterior tubercle; PT: C4 posterior tubercle; A.Scal: anterior scalene muscle; M.Scal: middle scalene muscle; SCM: sternocleidomastoid muscle; Arrow indicates needle trajectory

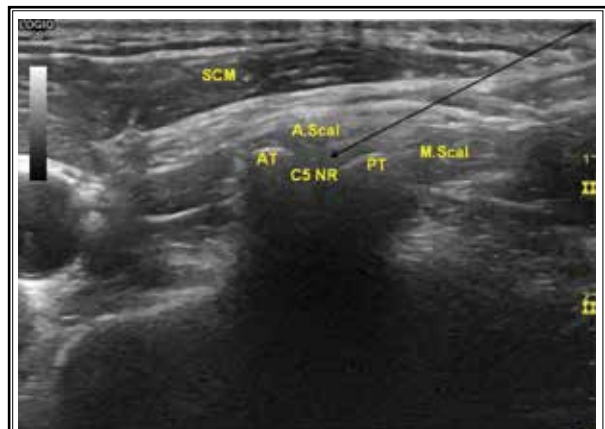

Image 9. C5 nerve root.
C5 NR: C5 nerve root; AT: C5 anterior tubercle; PT: C5 posterior tubercle; A.Scal: anterior scalene muscle; M.Scal: middle scalene muscle; SCM: sternocleidomastoid muscle; Arrow indicates needle trajectory

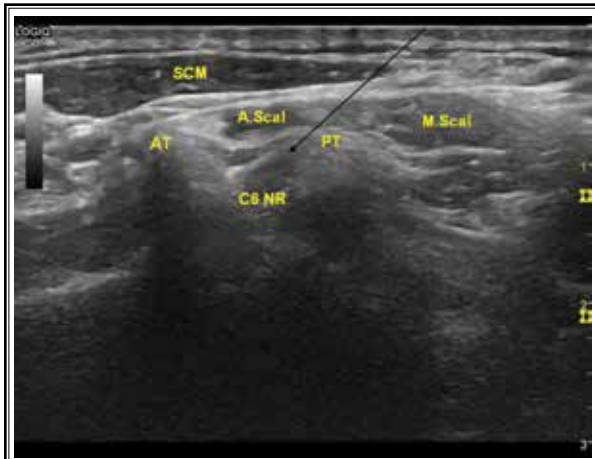


Image 10. C6 nerve root.
 C6 NR: C6 nerve root; AT: C6 anterior tubercle; PT: C6 posterior tubercle; A.Scal: anterior scalene muscle; M.Scal: middle scalene muscle; SCM: sternocleidomastoid muscle; Arrow indicates needle trajectory

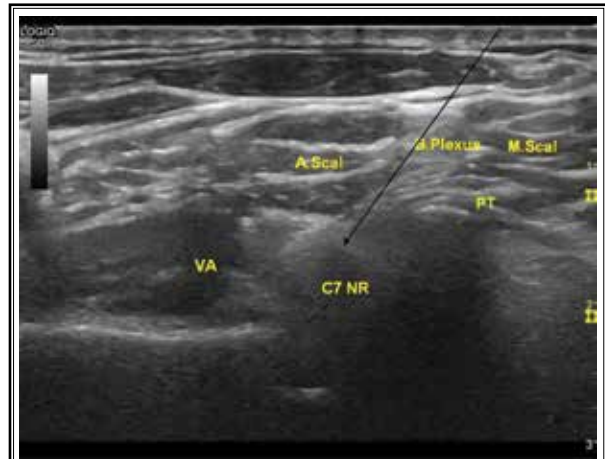


Image 11. C7 nerve root.
 C7 NR: C7 nerve root; PT: C7 posterior tubercle; A.Scal: anterior scalene muscle; M.Scal: middle scalene muscle; VA: vertebral artery; B.Plexus: brachial plexus; Arrow indicates needle trajectory

contrast and digital subtraction, in addition to real time ultrasound, will help identify the correct level and the nearby vessels.

Side Effects and Complications

One of the most feared complications of fluoroscopy guided cervical transforaminal injection is the injury of the vertebral artery and intravascular injection to the contributory branches of the anterior spinal arteries (45). In the study by Shizumasa et al (46) using doppler ultrasound examination, the frequency of a blood vessel existing within 4 mm from the center of the C5 and C6 nerve root was about 3%, whereas it was about 23% for the C7 nerve root. In the study by Jin Hyuk Jang, comparing the ultrasound-guided selective nerve root block (US-guided cSNRB) versus fluoroscopy-guided interlaminar epidural block (FL-guided IL) versus fluoroscopy-guided transforaminal epidural block (FL-guided TF), bloody aspiration was significantly lower in the US-guided cSNRB (0%, 6%, and 14% respectively). The study also showed that US-guided cSNRB required a shorter procedure time while providing similar pain relief and functional outcomes (47). The data regarding the complications of the ultrasound guided cSNRB are lacking. But in the paper by Malhotra et al (48) who reviewed the complications of the fluoroscopic guided cervical transforaminal epidural steroid might shed some light into the possible complications for cSNRB. The reported complications include nausea, dural punctures, vasovagal bradycardic

response, cervical epidural hematoma, paraspinal hematoma, peripheral neurapraxia, increased spine pain, nonspecific headache, high spinal anesthesia, transient ischemic attack, seizure, transient neurologic deficits (pain or weakness), transient global amnesia, verte-brobasilar brain infarcts, cervical spinal cord infarct, combined brain/spinal cord infarct, spinal cord edema, brainstem edema with herniation, brain edema with reversible ischemic neurologic deficit, cortical blindness due to air embolism, and even death (48). Intravascular injection into the contributory vessels to the radicular artery and anterior spinal artery with particulate steroid is thought to be one likely cause of spinal infarct. It is recommended to use only the non-particulate steroid if steroid is used.

Common Practice to Prevent and Manage Complications

Strict sterile skin preparation and draping and sterile techniques should be followed to prevent infection. Prophylactic antibiotics are usually not indicated. Using a noncutting needle reduces the risk of nerve injury and dural puncture. Bilateral blocks above the clavicles are contraindicated due to the risk of bilateral diaphragmatic paresis. If accidental phrenic nerve paralysis occurs, washing off the local anesthetics through a dwelling interscalene catheter is sufficient to restore the diaphragmatic function (49). According to the Guidelines from the American Society of Regional Anesthesia and Pain Medicine (2nd Edition), for patients

who are on antiplatelets and anticoagulation medications, peripheral nerve blocks are low risk procedures, and the stellate ganglion block, trigeminal ganglion block, medial branch block, and nerve root block are intermediate risk. Readers are strongly encouraged to refer to the guideline, in consultation with the prescribing specialists, for when to stop and restart individual NSAIDs and anticoagulant medications (50). If the patient complains of bilateral lower limb weakness, back pain, or local spinal tenderness, epidural hematoma and abscesses should be investigated. MRI is the preferred modality of diagnosis. The maximal dose of the indi-

vidual local anesthetics should be calculated by weight. If a patient has the classic toxicity symptoms, such as metallic taste, perioral and/or tongue numbness, light-headedness, visual and auditory disturbances/tinnitus, disorientation and drowsiness, medicine intoxicity or intravascular injection should be considered. In severe cases, cardiac arrhythmia and seizure can happen. Planning the needle trajectory carefully, using doppler and only injecting after negative aspiration helps to mitigate the risk. The resuscitating equipment including various airways and emergency medication should remain immediately available.

REFERENCES

1. Singh SK. The cervical plexus: Anatomy and ultrasound guided blocks. *Anaesth Pain Intensive Care* 2015; 19:323-332.
2. Kikuta S, Jenkins S, Kusukawa J, Iwanaga J, Loukas M, Tubbs RS. Ansa cervicalis: A comprehensive review of its anatomy, variations, pathology, and surgical applications. *Anat Cell Biol* 2019; 52:221-225.
3. Guidera AK, Dawes PJ, Fong A, Stringer MD. Head and neck fascia and compartments: No space for spaces. *Head Neck* 2014; 36:1058-1068.
4. Kim JS, Ko JS, Bang S, Kim H, Lee SY. Cervical plexus block. *Korean J Anesthesiol* 2018; 71:274-288.
5. Goldberg ME, Schwartzman RJ, Domskey R, Sabia M, Marc C Torjman. Deep cervical plexus block for the treatment of cervicogenic headache. *Pain Physician* 2008; 11:849-854.
6. Sait Kavaklı A, Kavrut Öztürk N, Umut Ayoğlu R, et al. Comparison of combined (deep and superficial) and intermediate cervical plexus block by use of ultrasound guidance for carotid endarterectomy. *J Cardiothorac Vasc Anesth* 2016; 30:317-322.
7. Pintaric TS, Hocevar M, Jereb S, Casati A, Novak Jankovic V. A prospective, randomized comparison between combined (deep and superficial) and superficial cervical plexus block with levobupivacaine for minimally invasive parathyroidectomy. *Anesth Analg* 2007; 105:1160-1163.
8. Castresana MR, Masters RD, Castresana EJ, Stefansson S, Shaker IJ, Newman WH. Incidence and clinical significance of hemidiaphragmatic paresis in patients undergoing carotid endarterectomy during cervical plexus block anesthesia. *J Neurosurg Anesthesiol* 1994; 6:21-23.
9. Weiss A, Isselhorst C, Gahlen J, et al. Acute respiratory failure after deep cervical plexus block for carotid endarterectomy as a result of bilateral recurrent laryngeal nerve paralysis. *Acta Anaesthesiol Scand* 2005; 49:715-719.
10. Padaki AS, Fitch RW, Stack LB, Thurman RJ. Horner's Syndrome after scalene block and carotid dissection. *J Emerg Med* 2016; 50:e215-e218.
11. Mitsuoaka K, Kikutani T, Sato I. Morphological relationship between the superior cervical ganglion and cervical nerves in Japanese cadaver donors. *Brain Behav* 2017; 7:e00619.
12. Civelek E, Karasu A, Cansever T, et al. Surgical anatomy of the cervical sympathetic trunk during anterolateral approach to cervical spine. *Eur Spine J* 2008; 17:991-995.
13. Wang S, Zhu Y. A case report of stellate ganglion block in the treatment of epileptic pain. *Medicine (Baltimore)* 2017; 96:e6044.
14. Liao C, Yang M, Liu P, Zhong W, Zhang W. Thalamic pain alleviated by stellate ganglion block: A case report. *Medicine (Baltimore)* 2017; 96:e6058.
15. Hanling S, Hickey A, Lesnik I, et al. Stellate ganglion block for the treatment of posttraumatic stress disorder: A randomized, double-blind, controlled trial. *Reg Anesth Pain Med* 2016; 41:494-500.
16. Feigl GC, Rosmarin W, Stelzl A, Weninger B, Likar R. Comparison of different injectate volumes for stellate ganglion block: An anatomic and radiologic study. *Reg Anesth Pain Med* 2007; 32:203-208.
17. Nascimento MS, Klamt JG, Prado WA. Intravenous regional block is similar to sympathetic ganglion block for pain management in patients with complex regional pain syndrome type I. *Braz J Med Biol Res* 2010; 43:1239-1244.
18. Goebel A, Lawson A, Allen S, Glynn C. Buprenorphine injection to the stellate ganglion in the treatment of upper body chronic pain syndromes. *Eur J Pain* 2008; 12: 266-274.
19. Kulkarni KR, Kadam AI, Namazi IJ. Efficacy of stellate ganglion block with an adjuvant ketamine for peripheral vascular disease of the upper limbs. *Indian J Anaesth* 2010; 54:546-551.
20. Goel V, Patwardhan AM, Ibrahim M, Howe CL, Schultz DM, Shankar H. Complications associated with stellate ganglion nerve block: A systematic review. *Reg Anesth Pain Med* 2016; 41:494-500.
21. Kimura T, Nishiwaki K, Yokota S, Komatsu T, Shimada Y. Severe hypertension after stellate ganglion block. *Br J Anaesth* 2005; 94:840-842.
22. Chaturvedi A, Dash H. Locked-in syndrome during stellate ganglion block. *Indian J Anaesth* 2010; 54:324-326.
23. Erdogan N, Unur E, Baykara M. CT anatomy of pterygopalatine fossa and its communications: A pictorial review. *Comput Med Imaging Graph* 2003; 27:481-487.
24. Nader A, Schitteck H, Kendall MC. Lateral pterygoid muscle and maxillary artery are key anatomical landmarks for ultrasound-guided trigeminal nerve block. *Anesthesiology* 2013; 118:957.
25. Nader A, Kendall MC, De Oliveria GS, et al. Ultrasound-guided trigeminal nerve block via the pterygopalatine fossa: An effective treatment for trigeminal neuralgia and atypical facial pain. *Pain*

- Physician 2013; 16:E537-E545.
26. Ho KWD, Przkora R, Kumar S. Sphenopalatine ganglion: Block, radiofrequency ablation and neurostimulation - a systematic review. *J Headache Pain*. 2017; 18:118.
 27. Coronado Gallardo CA, Suazo Galdames IC, Cantín López MG, Zavando Matamala DA. Relationship between pterygopalatine fossa volume and cephalic and upper facial indexes. *Int J Morphol* 2008; 26:393-396.
 28. Magliocca KR, Kessel NC, Cortright GW. Transient diplopia following maxillary local anesthetic injection. *Oral Surg Oral Med Oral Pathol Oral Radiol Endod* 2006; 101:730-733.
 29. Bogduk N. Cervicogenic Headache: Anatomic basis and pathophysiologic mechanisms. *Curr Pain Headache Rep* 2001; 5:382-386.
 30. Weatherall MW. Idiopathic trigeminal neuropathy may respond to greater occipital nerve injection. *Cephalalgia* 2008; 28:664-666.
 31. Choi I, Jeon SR. Neuralgias of the head: occipital neuralgia. *J Korean Med Sci* 2016; 31:479-488.
 32. Santos Lasasosa S, Cuadrado Pérez ML, Guerrero Peral AL, et al. Consensus recommendations for anaesthetic peripheral nerve block. *Neurología* 2017; 32:316-330.
 33. Lauretti GR, Corrêa SW, Mattos AL. Efficacy of the greater occipital nerve block for cervicogenic headache: Comparing classical and subcompartmental techniques. *Pain Pract* 2015; 15:654-661.
 34. Sahai-Srivastava S, Subhani D. Adverse effect profile of lidocaine injections for occipital nerve block in occipital neuralgia. *J Headache Pain*. 2010; 11:519-523.
 35. Kweon TD, Kim JY, Lee HY, Kim MH, Lee YW. Anatomical analysis of medial branches of dorsal rami of cervical nerves for radiofrequency thermocoagulation. *Reg Anesth Pain Med* 2014; 39:465-471.
 36. Bogduk N. *Spine* The clinical anatomy of the cervical dorsal rami. 1982; 7:319-330.
 37. Lord SM, Barnsley L, Wallis BJ, McDonald GJ, Bogduk N. Percutaneous radio-frequency neurotomy for chronic cervical zygapophyseal-joint pain. *N Engl J Med* 1996; 335:1721-1726.
 38. Lord SM, Barnsley L, Wallis BJ, Bogduk N. Third occipital nerve headache: A prevalence study. *J Neurol Neurosurg Psychiatry* 1994; 57:1187-1190.
 39. Giblin K, Newmark JL, Brenner GJ, Wainger BJ. Headache plus: Trigeminal and autonomic features in a case of cervicogenic headache responsive to third occipital nerve radiofrequency ablation. *Pain Medicine* 2014; 15:473-478.
 40. Wahezi SE, Molina JJ, Alexeev E, et al. Cervical medial branch block volume dependent dispersion patterns as a predictor for ablation success: A cadaveric study. *PM R* 2019; 11:631-639.
 41. Lee HI, Park YS, Cho TG, Park SW, Kwon JT, Kim YB. Transient adverse neurologic effects of spinal pain blocks. *J Korean Neurosurg Soc* 2012; 52:228-233.
 42. Wiltse LL. Anatomy of the extradural compartments of the lumbar spinal canal. Peridural membrane and circumneural sheath. *Radiol Clin North Am* 2000; 38:1177-1206.
 43. Huntoon, MA. Anatomy of the cervical intervertebral foramina: Vulnerable arteries and ischemic neurologic injuries after transforaminal epidural injections. *Pain* 2005; 117:104-111.
 44. Kang S, Yang SN, Kim SH, Byun CW, Yoon JS. Ultrasound-guided cervical nerve root block: Does volume affect the spreading pattern. *Pain Med* 2016; 17:1978-1984.
 45. Brouwers PJAM, Kottink EJBL, Simon MAM, Prevo RL. A cervical anterior spinal artery syndrome after diagnostic blockade of the right C6 nerve root. *Pain* 2001; 91:397-399.
 46. Murata S, Iwasaki H, Natsumi Y, Minagawa H, Yamada H. Vascular evaluation around the cervical nerve roots during ultrasound-guided cervical nerve root block. *Spine Surg Relat Res* 2020; 4:18-22.
 47. Jang JH, Lee WY, Kim JW, Cho KR, Nam SH, Park Y. Ultrasound-guided selective nerve root block versus fluoroscopy-guided interlaminar epidural block versus fluoroscopy-guided transforaminal epidural block for the treatment of radicular pain in the lower cervical spine: A retrospective comparative study. *Pain Res Manag* 2020; 9103421.
 48. Malhotra G, Abbasi A, Rhee M. Complications of transforaminal cervical epidural steroid injections. *Spine* 2009; 34:731-739.
 49. Tsui BC, Dillane D. Reducing and washing off local anesthetic for continuous interscalene block. *Reg Anesth Pain Med* 2014; 39:116-176.
 50. Narouze S, Benzon HT, Provenzano D, et al. *Interventional spine and pain procedures in patients on antiplatelet and anticoagulant medications (Second Edition): Guidelines from the American Society of Regional Anesthesia and Pain Medicine, the European Society of Regional Anaesthesia and Pain Therapy, the American Academy of Pain Medicine, the International Neuromodulation Society, the North American Neuromodulation Society, and the World Institute of Pain.* *Reg Anesth Pain Med* 2018; 43:225-262.