

Letters to the Editor

e Transincisional Ultrasound-Guided Quadratus Lumborum Block in Open Renal Surgeries

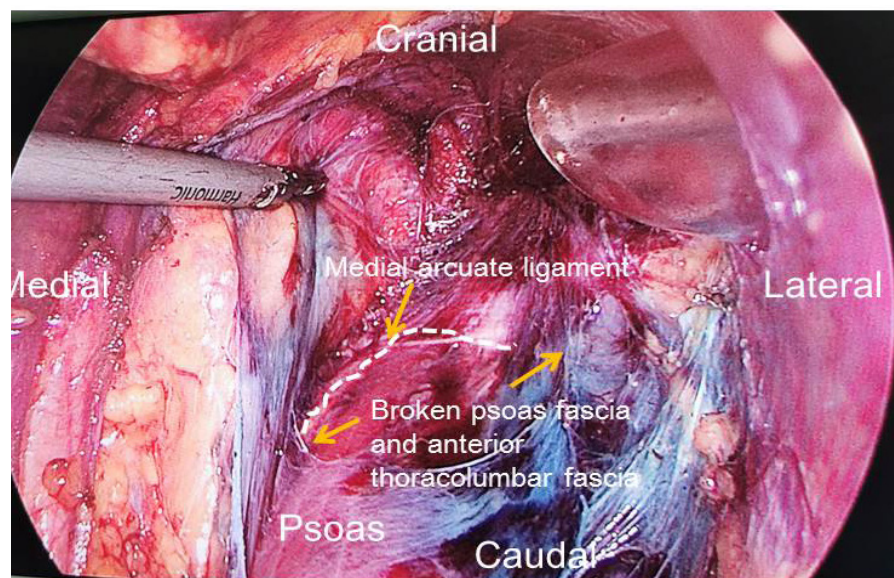
TO THE EDITOR:

We read with great interest the article by Alansary et al (1), which describe the ultrasound guided transincisional quadratus lumborum block (TiQLB) as a new approach, and to compare the addition of dexmedetomidine to bupivacaine versus bupivacaine alone for TiQLB, in combination with general anesthesia regarding postoperative analgesia, and adverse effects in open renal surgery. The authors demonstrated that ultrasound guided TiQLB was effective and easy to perform and by adding dexmedetomidine to bupivacaine in TiQLBs it was associated with potent and prolonged postoperative analgesia with fewer postoperative adverse effects. We highly appreciate their efforts on this innovative study. However, there are several aspects of this study that need to be clarified and may affect the validity of their conclusions.

Firstly, the transmuscular QLB targets the local anesthetic (LA) into the compartment between the quadratus lumborum muscle (QLM) and psoas major muscle (PMM) and allows the LA to spread cranially under the

medial and lateral arcuate ligaments and reaches the lower thoracic paravertebral space (2,3). However, the spread of LA into the lower thoracic paravertebral space via medial and lateral arcuate ligaments after transmuscular QLB depends on the intact psoas fascia and anterior thoracolumbar fascia. Interestingly, for urologists, the medial arcuate ligament serves as a landmark of dissecting the renal artery during the nephrectomy and the urologists often do damage to the psoas fascia and anterior thoracolumbar fascia (4). It may lead to the failure of LA spread into the lower thoracic paravertebral space. We have observed 5 cases undergoing total or partial nephrectomy under retroperitoneal laparoscopy and the apparent damage to psoas major fascia and anterior thoracolumbar fascia occurred in 4 out of 5 patients when the urologists dissected the medial arcuate ligament and renal artery, which is indicated by the spread of LA containing methylene blue after transmuscular QLB blockade (Fig. 1).

Fig. 1. Damage to psoas major fascia and anterior thoracolumbar fascia in total or partial nephrectomy under retroperitoneal laparoscopy. The white dashed lines represent medial arcuate ligament. The broken psoas fascia and anterior thoracolumbar fascia are shown.



Secondly, the authors did not provide the sensory block levels after TiQLB. Although the TiQLB was performed after completing the renal procedure and before wound closure, the sensory block levels could be easily detected 30 minutes or 1 hour after the patient emerged from general anesthesia. It is not clear whether all these patients obtained the successful TiQLB with adequate block coverage and we suggest the authors provide the data on the sensory block levels in order to validate the conclusions of this study as reliable and authenticated.

Thirdly, although the authors provided the ultrasound image showing the hydrodissection of LA between the QLM and PMM, the image quality is very poor. The author did not label "lateral" side or "medial" side. The PMM and QLM are indistinct. We suggest that authors provide a perfect ultrasound image to show the correct position of LA injection.

We believe that addressing these points would help to support the conclusions of the study.

Acknowledgement

This work was supported by the creative projects of clinical techniques, Yangfan Plan, Beijing Hospitals Authority (XMLX202106).

Huili Li, MD

Department of Anesthesiology, Beijing Chaoyang Hospital, Capital Medical University, Beijing, China

Rong Shi, MD

Department of Anesthesiology, Beijing Chaoyang Hospital, Capital Medical University, Beijing, China

Yun Wang, MD, PhD

Department of Anesthesiology, Beijing Chaoyang Hospital, Capital Medical University

Beijing 100020, China

E-mail: wangyun129@ccmu.edu.cn

REFERENCES

1. Alansary AM, Badawy A, Elbeialy MAK. Dexmedetomidine added to bupivacaine versus bupivacaine in transincisional ultrasound-guided quadratus lumborum block in open renal surgeries: A randomized trial. *Pain Physician* 2020; 23:271-282.
2. Børglum J, Jensen K, Moriggl B, Lønnqvist P, Christensen A, Sauter A. Ultrasound-guided transmuscular quadratus lumborum blockade. *Br J Anaesth* 2013; 111. https://doi.org/10.1093/bja/el_9919.
3. Dam M, Moriggl B, Hansen CK, Hoermann R, Bendtsen TF, Børglum J. The pathway of injectate spread with the transmuscular quadratus lumborum block: A cadaver study. *Anesth Analg* 2017; 125:303-312.
4. Cai W, Li HZ, Zhang X, et al. Medial arcuate ligament: A new anatomic landmark facilitates the location of the renal artery in retroperitoneal laparoscopic renal surgery. *J Endourol* 2013; 27:64-67.