

Retrospective Study

Percutaneous Vertebroplasty Versus Kyphoplasty for Thoracolumbar Osteoporotic Vertebral Compression Fractures in Patients with Distant Lumbosacral Pain

Yongchao Li, MD¹, Xiaofei Feng, MD¹, Jie Pan, MD¹, Mingjie Yang, MD, PhD¹,
Lijun Li, MD, PhD¹, Qihang Su, MD^{1,2}, and Jun Tan, MD, PhD¹

From: ¹Department of Spinal Surgery, Shanghai East Hospital, Tongji University School of Medicine, Shanghai, China; ²Department of Orthopedics, Tenth People's Hospital Affiliated To Tongji University, Tongji University School of Medicine, Shanghai, China

Address Correspondence:
Qihang Su, MD
Department of Spinal Surgery,
Shanghai East Hospital, Tongji
University School of Medicine
No. 150 Jimo Road
Shanghai 200120, China
E-mail: 15221378017@163.com

Disclaimer: This study was supported by grants from the Multicenter Clinical Trial of hUC-MSCs in the Treatment of Late Chronic Spinal Cord Injury (2017YFA0105404), and the Key Discipline Construction Project of Pudong Health Bureau of Shanghai (PWZxk2017-08).

Conflict of interest: Each author certifies that he or she, or a member of his or her immediate family, has no commercial association (i.e., consultancies, stock ownership, equity interest, patent/licensing arrangements, etc.) that might pose a conflict of interest in connection with the submitted manuscript.

Manuscript received:
06-21-2020

Revised manuscript received:
10-26-2020

Accepted for publication:
11-06-2020

Free full manuscript:
www.painphysicianjournal.com

Background: In clinical practice, we have found that the pain caused by thoracolumbar osteoporotic vertebral compression fracture (OVCF) is sometimes not limited to the level of the fractured vertebrae but instead occurs in areas far away from the injured vertebrae, such as the lower back, area surrounding the iliac crest, or buttocks, and this type of pain is known as distant lumbosacral pain. The pathogenesis of pain in distant regions caused by thoracolumbar OVCF remains unclear.

Objectives: To compare the clinical efficacy and imaging outcomes of percutaneous vertebroplasty (PVP) and percutaneous kyphoplasty (PKP) in the treatment of distant lumbosacral pain accompanied by thoracolumbar OVCF and to explore the possible pathogenesis of distant lumbosacral pain caused by thoracolumbar OVCF.

Study Design: Retrospective study.

Setting: A university hospital spinal surgery departments.

Methods: A total of 62 patients who underwent vertebral augmentation for thoracolumbar OVCF with lumbosacral pain were included and divided into the PVP group (28 cases) and the PKP group (34 cases). The Visual Analog Scale (VAS) was used to evaluate the severity of local and distant lumbosacral pain, and the Chinese modified Oswestry Disability Index (CMODI) was used for functional assessment. The anterior vertebral height (AVH) of the fractured vertebrae and local kyphotic angle were measured on plain radiographs. The average follow-up time was 28.62 ± 8.43 months in the PVP group and 29.22 ± 9.09 months in the PKP group.

Results: Within the 2 groups, the VAS score of local pain, VAS score of distant lumbosacral pain, and CMODI score at 3 days postoperatively and at the last follow-up improved significantly compared with the scores before surgery. However, there was no significant difference between the 2 groups. At 3 days postoperatively and at last follow-up, the AVH and Cobb angle in the 2 groups improved significantly compared with those before surgery, but the magnitudes of AVH improvement and Cobb angle correction were significantly larger in the PKP group than in the PVP group.

Limitations: First, this study is retrospective and may be prone to selection bias. Second, because of cultural and linguistic differences, the original version of the Oswestry Disability Index could not be properly understood and completed by people in mainland China. Therefore in this study, the CMODI was used, but the correlation coefficients of the CMODI within and between groups were 0.953 and 0.912, respectively. Third, a pain diagram was not used to accurately reflect the location of pain in the distant lumbosacral region.

Conclusions: Both PVP and PKP can effectively alleviate pain in the distant lumbosacral region caused by thoracolumbar OVCF, and distant lumbosacral pain associated with thoracolumbar OVCF may be considered vertebrotoxic referred pain.

Key words: Osteoporotic vertebral compression fracture, distant pain, non-midline pain, kyphoplasty, vertebroplasty, vertebral augmentation, lumbosacral pain, Chinese modified Oswestry Disability Index

Pain Physician 2021: 24:E349-E356

Osteoporotic vertebral compression fracture (OVCF) seriously affects the quality of life and health of elderly people because of the constant pain (1). OVCF mostly occurs in the thoracolumbar region (T12-L2), and the typical symptoms include focal pain at the level of the injured vertebral body that is aggravated when the individual changes body position and is alleviated or resolved by bed rest. Typical signs include restricted mobility, kyphosis, and local tenderness in the diseased vertebra. For patients with recent OVCF and whose symptoms and signs are consistent with imaging results, vertebral augmentation is a safe and effective treatment and can quickly relieve pain, correct kyphosis, improve quality of life, and reduce long-term mortality (2-4). However, it has been observed in clinical practice that the pain caused by thoracolumbar OVCF is sometimes not limited to the level of the fractured vertebrae but instead occurs in areas far away from the injured vertebrae, such as the lower back, area surrounding the iliac crest (ASIC), or buttocks. This pain is known as distant pain (5-9) or non-midline pain (10). Because of the differences in criteria used to identify pain in the distant region, the incidence of distant pain has been reported to be 17.2% to 46.2% in the literature (6,8,11,12). More interestingly, some patients with a final diagnosis of OVCF often complain of pain in the distant location only and do not experience local pain in the injured vertebral body. In other words, pain in the distant region is sometimes the main complaint or even the only symptom of thoracolumbar OVCF (8,12). If the understanding of the pathogenesis of OVCF is insufficient, these patients can be easily misdiagnosed and mistreated.

A limited number of studies have shown that either percutaneous kyphoplasty (PKP) (5-8,13) or percutaneous vertebroplasty (PVP) (8,10) can improve distal pain associated with OVCF. However, to the best of our knowledge, no studies have compared the efficacy of these 2 techniques in treating distant pain associated with OVCF. The purposes of this study were to compare the clinical efficacy and imaging outcomes of PVP and PKP in the treatment of pain in the distant region accompanied by thoracolumbar OVCF, and to explore the possible pathogenesis of distant pain caused by thoracolumbar OVCF.

METHODS

Patient Population

Patients with OVCF treated by vertebral augmenta-

tion in our hospital from June 2013 to June 2018 were retrospectively analyzed. This study received the approval of the ethical review committees of East Hospital Affiliated to Tongji University. Patients were included if they met the following criteria: (1) a recent preoperative magnetic resonance imaging (MRI)-confirmed single-segment thoracolumbar OVCF (T12-L2), that is, a fracture in a vertebral body showing a bone marrow edema signal; (2) preoperative lumbosacral pain, that is, pain felt far away from the thoracolumbar fracture, such as in the lower back, ASIC, or in the buttocks, associated with a history of trauma, often persisting and worsening when changing positions; (3) no symptoms of nerve root and/or spinal cord compression; (4) conditions meeting the diagnostic criteria for osteoporosis (World Health Organization), including a L1-L4 bone mineral density T value of -2.5 or less on dual-energy x-ray imaging; and (5) complete initial and follow-up data.

Patients were excluded if they met the following criteria: (1) a history of spinal surgery; (2) complications from severe spinal degenerative diseases such as lumbar spondylolisthesis or lumbar spinal stenosis; (3) lumbar pain for more than 6 weeks; (4) thoracolumbar fascial injury on MRI before the operation; (5) other pathological fractures, such as hemangioma, multiple myeloma, and bone tuberculosis; (6) complications with severe cardiovascular and cerebrovascular, respiratory, and other medical diseases; and (7) psychological or mental illness.

A total of 62 patients who underwent vertebral augmentation for thoracolumbar OVCF with lumbosacral pain were included. Among them, 21 patients had only distant lumbosacral pain and did not have local pain at the fractured vertebral level. According to the type of surgery received, the included patients were divided into the PVP group (28 cases) and the PKP group (34 cases). Before surgery, informed signed consent was obtained from the included patients. There was no significant difference in baseline characteristics between the 2 groups ($P > 0.05$) (Table 1).

Surgical Techniques

The patients were placed in the prone position with a cushion under the chest and waist to suspend the chest and abdomen. First, spinal hyperextension was maintained for the reduction of the fractured vertebral bodies. The diseased vertebrae were positioned via C-arm x-ray, and all patients underwent the unilateral pedicle approach under local anesthesia.

With the zygapophyseal joint as the target, the muscle was punctured until the 1/3 junction of the vertebra along the outer edge of the vertebral pedicle, the guide needle was placed, and the expansion cannula was inserted to establish a working channel. In the PVP group, polymethylmethacrylate (PMMA) cement was prepared into a filiform shape and infused into the diseased vertebra directly and slowly under C-arm monitoring. In the PKP group, a balloon dilation system (Kyphon Inc., Sunnyvale, CA) was first placed, and the pressure in the balloon was gradually increased. When the height of the vertebral body reached a satisfactory level, the expansion process was stopped, and the balloon was removed. Then, PMMA cement was prepared into a filiform shape and slowly infused into the fractured vertebra. In both groups, the injection was stopped when the cement had diffused to the posterior wall of the vertebral body. After the bone cement was infused, the trochar and working cannula were removed sequentially, hemostasis was reached by compression, and the incision was sutured. During the puncture and infusion of the bone cement, lower limb movement was monitored. The operation time, bone cement content, and complications were recorded. On postoperative day 1, the patients were able to get out of bed with waist support, and bisphosphonates and vitamin D were administered to prevent osteoporosis.

Clinical and Radiologic Assessments

The Visual Analog Scale (VAS) score (in the range of 0 = no pain to 10 = worst pain) was used to evaluate the severity of local and distant lumbosacral pain, and the Chinese modified Oswestry Disability Index (CMODI) was used for functional assessment. There were 2 changes in the CMODI from the original Oswestry Disability Index (ODI): considering Chinese people's hesitance to answer questions about sex, item 8, which addressed the patient's sex life, was removed, and the units of measurement were changed from miles and yards to kilometers and meters. Therefore the CMODI contained 9 items, with a maximum score of 45 points (14). The measures were recorded preoperatively, 3 days after surgery, and at last follow-up.

Plain radiographs were taken preoperatively, 3 days after surgery, and at last follow-up with patients in the supine position. Using the method described by Teng et al (15), on the lateral radiographs, the anterior vertebral height (AVH) of the fractured vertebrae and posterior border height of an adjacent normal vertebral body were measured. To correct the magnification

Table 1. Comparison of the characteristics of the patients in the 2 treatment groups at baseline.

Characteristic	PVP Group (n = 28)	PKP Group (n = 34)	P Value
Gender, male/female	10/18	12/22	0.973
Age, years	65.3 ± 4.94	65.4 ± 4.42	0.920
Bone mineral density	-2.84 ± 0.18	-2.85 ± 0.20	0.816
Level of fractured vertebrae (T12/L1/L2)	8/12/8	9/14/11	0.948

Data are mean ± standard deviation or number.

ratio on the radiographs, the vertebral height was expressed as a relative value: the fractured AVH/the adjacent posterior border height. We used the Cobb angle between the superior endplate of the adjacent upper vertebra and the inferior endplate of the lower vertebra to evaluate the severity of the local kyphotic deformity (5).

Statistical Analysis

Statistical analyses were carried out using SPSS 23.0 (IBM Corporation, Armonk, NY). The baseline characteristics of the 2 groups were compared by the independent sample t-test or the χ^2 test. The AVH, Cobb angle, VAS score, and CMODI within groups were compared using the paired t-test. One-way analysis of variance was used for comparisons between the 2 groups. The significance level was set to 0.05.

RESULTS

Surgery was successful in all patients, and none of the patients experienced lower-limb deep venous thrombosis, pulmonary embolism, or spinal nerve injury. The operation time was significantly longer in the PKP group (35.79 ± 3.26 min) than in the PVP group (30.82 ± 2.79 min) ($P = 0.000$). Eleven patients (17.7%) had bone cement leakage, including 7 patients (25.0%) in the PVP group and 4 patients (11.8%) in the PKP group. There was no significant difference between the 2 groups ($P = 0.175$).

The mean follow-up duration was not significantly different between the 2 groups (28.62 ± 8.43 months in the PVP group vs. 29.22 ± 9.09 months in the PKP group, $P = 0.678$). During the follow-up period, there were 7 cases (12.1%) of secondary vertebral fractures, including 3 cases (11.5%) in the PVP group and 4 cases (12.5%) in the PKP group. Symptoms improved after vertebral augmentation was performed a second time.

Within the 2 groups, the VAS score of local pain, VAS score of distant lumbosacral pain, and CMODI score

at 3 days postoperatively and at last follow-up significantly improved compared with those before surgery ($P < 0.05$, Table 2). However, there was no significant difference in the VAS score of local pain, VAS score of distant lumbosacral pain, or CMODI score between the 2 groups at 3 days postoperatively or at last follow-up ($P > 0.05$, Table 2).

At 3 days postoperatively and at last follow-up, the AVHs in the 2 groups significantly improved compared with those before surgery ($P < 0.05$, Table 3, Fig. 1), but the magnitude of improvement in the AVH was significantly larger in the PKP group than in the PVP group ($P < 0.05$, Table 3, Fig. 1). In the 2 groups, the Cobb angles at 3 days postoperatively and last follow-up were corrected significantly compared with those before surgery ($P < 0.05$, Table 3, Fig. 2). However, the magnitude of Cobb angle correction in the PKP group was significantly larger than that in the PVP group ($P < 0.05$, Table 3, Fig. 2). The typical cases of PVP and PKP groups are shown in Figs. 3 and 4, respectively.

DISCUSSION

For patients with recent OVCFs whose symptoms and signs are consistent with imaging results, vertebral augmentation is a safe and effective treatment and is significantly better than conservative treatment in reducing long-term mortality (2,4). In addition, the ef-

fectiveness of PVP (16) or PKP (5) is not affected when there is no local tenderness of the fractured vertebral body before surgery. However, we have observed that some patients with thoracolumbar OVCFs have definite MRI vertebral edema signals but often complain of pain in the lumbosacral site, with slight or no pain in the thoracolumbar region. Some scholars have referred to this condition as "distant pain," which occurs at the same time as the OVCF but is felt in regions far from the fractured vertebra (5,6,9). Can patients with thoracolumbar OVCF associated with distant pain benefit from vertebral augmentation as well? This study showed that at 3 days postoperatively and at last follow-up, the VAS scores of focal pain and distant pain in the PVP and PKP groups were significantly lower than those before surgery, indicating that patients with OVCF associated with distant lumbosacral pain can benefit from either PVP or PKP treatment. Previous studies have shown that PVP (8,10) or PKP (6-8) can significantly improve the overall (including local and distant pain) VAS scores of patients with OVCF with pain in the distal region. However, only Niu et al (5) used the VAS score to evaluate the severity of distant lumbosacral pain associated with thoracolumbar OVCFs (T12-L2) without local pain in the fracture vertebral body. They found that PKP significantly improved the VAS score of lumbosacral pain associated with thoracolumbar OVCFs, consistent with our findings. In addition, our study showed that PVP can also significantly improve the VAS score of distant lumbosacral pain.

Distal pain most commonly occurs in the lower back, ASIC, and buttocks but can also be experienced in

Table 2. Comparison of the changes in the VAS score and ODI for each group before and after surgery.

Measure	PVP Group	PKP Group	P Value
VAS score (LP)			
Baseline	4.32 ± 0.82	4.36 ± 0.85	0.911
Three days postoperatively	1.37 ± 0.83*	1.41 ± 0.67*	0.853
At final follow-up	1.26 ± 0.73*†	1.36 ± 0.73*†	0.602
VAS score (DLR)			
Baseline	6.29 ± 0.81	6.44 ± 0.89	0.460
Three days postoperatively	2.04 ± 0.58*	2.06 ± 0.55*	0.875
At final follow-up	1.85 ± 0.73*†	1.94 ± 0.80*†	0.733
Chinese modified ODI, %			
Baseline	65.46 ± 3.11	65.62 ± 2.94	0.726
Three days postoperatively	30.46 ± 1.84*	30.65 ± 1.86*	0.625
At final follow-up	29.12 ± 1.53*†	29.28 ± 1.81*†	0.830

Data are mean ± standard deviation.

Abbreviations: DLR, distant lumbosacral region; LP, local pain.

* $P < 0.05$ versus the preoperative values.

† $P > 0.05$ versus the 3-day postoperative values.

Table 3. Comparison of the changes in the AVH and local kyphotic angle for each group before and after surgery.

Measure	PVP Group	PKP Group	P Value
AVH, %			
Baseline	65.07 ± 4.56	64.88 ± 4.56	0.837
Three days postoperatively	71.07 ± 4.34*	81.18 ± 4.00*	0.000
At final follow-up	70.54 ± 4.66*†	79.34 ± 4.22*†	0.000
LKA, °			
Baseline	18.14 ± 2.51	18.18 ± 2.96	0.972
Three days postoperatively	14.61 ± 2.17*	9.38 ± 2.88*	0.000
At final follow-up	14.96 ± 2.11*†	9.63 ± 2.59*†	0.000

Data are mean ± standard deviation or number.

Abbreviation: LKA, local kyphotic angle.

* $P < 0.05$ versus the preoperative values.

† $P > 0.05$ versus the 3-day postoperative values.

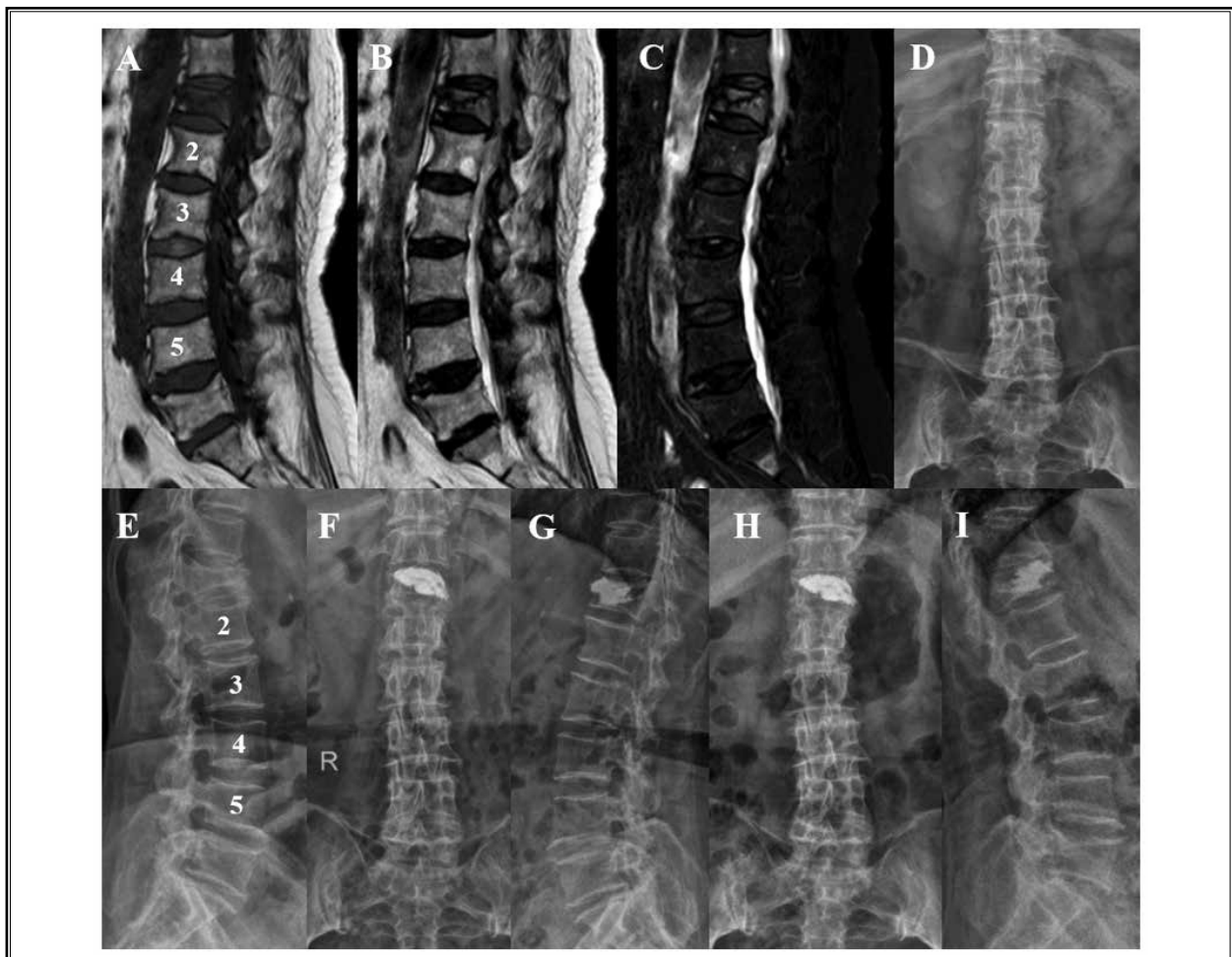
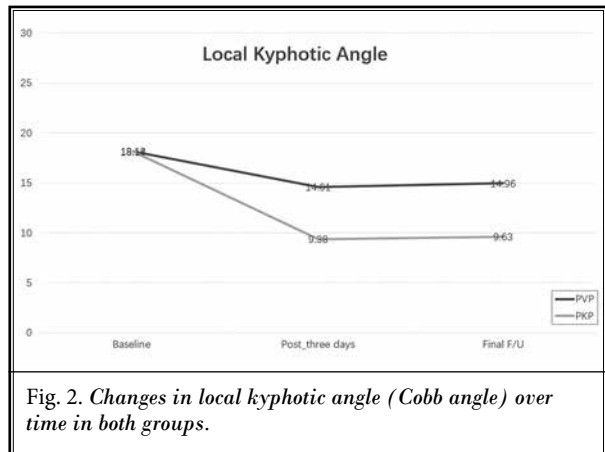
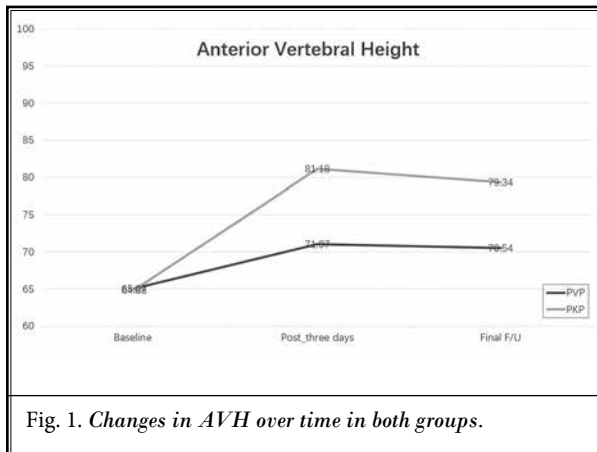


Fig. 3. The imaging data of a 72-year-old woman showed L1 vertebral compression fracture and lumbarization of the most superior sacral segment. However, she complained of lower back pain, with a VAS score of 6. After surgery and 52 months of follow-up, the patient's lower back pain was significantly improved, and the VAS score was 2 and 1 points, respectively. (A–C) Preoperative MRI; (D, E) preoperative lumbar radiograph; (F, G) lumbar radiograph 3 days after operation; (H, I) lumbar radiograph 52 months after operation.

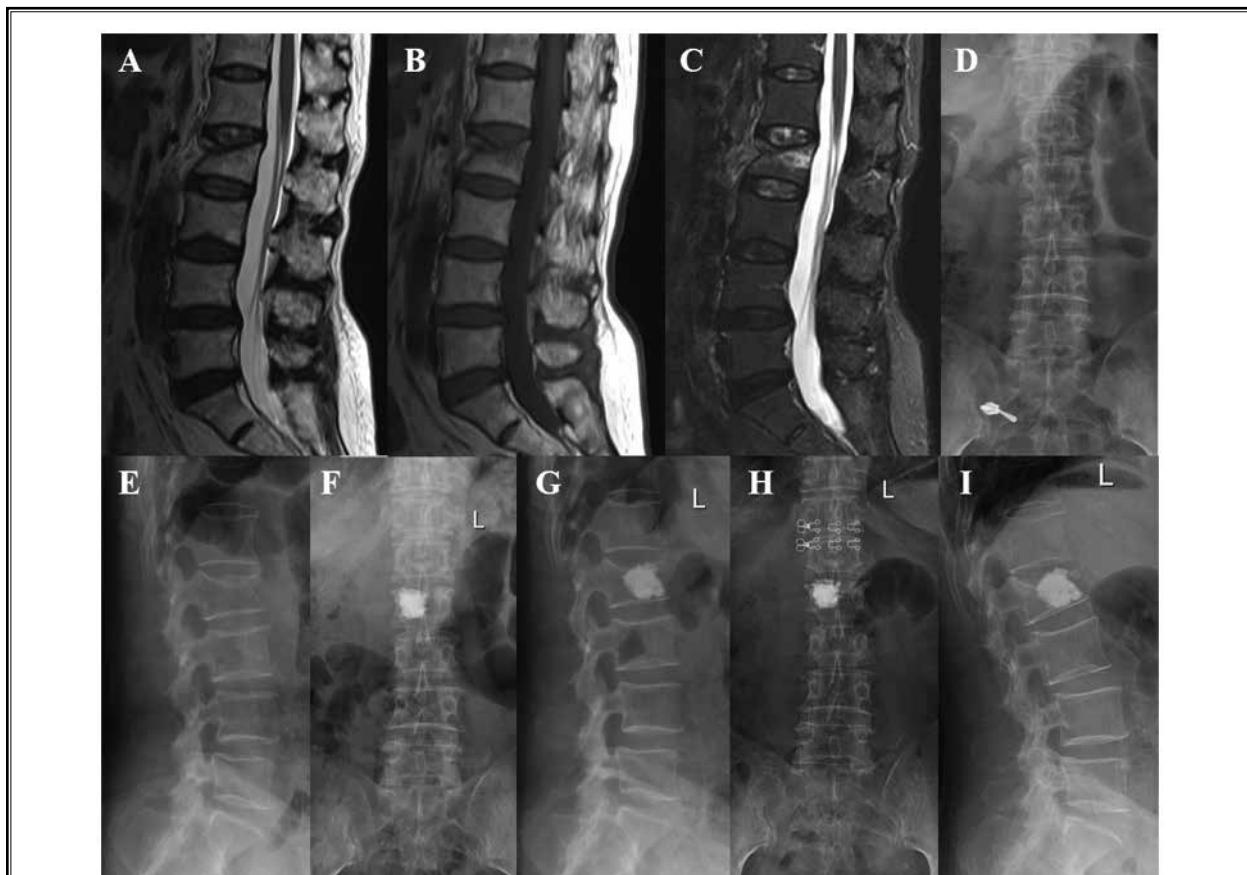


Fig. 4. The imaging data of a 70-year-old woman showed L2 vertebral compression fracture. However, she complained of ASIC pain, with a VAS score of 6. After surgery and 18 months of follow-up, the patient's ASIC pain was significantly improved, and the VAS score was 1 and 0 points, respectively. (A–C) Preoperative MRI; (D, E) preoperative lumbar radiograph; (F, G) lumbar radiograph 3 days after operation; (H, I) lumbar radiograph 18 months after operation.

the groin, trochanteric region, abdominal areas, chest, and costal region (6-8,10). Shi et al (13) classified distal pain into types A–E according to the pain distribution patterns. Type A: pain is located in the lumbosacral region and buttocks; type B: pain is located in abdomen, ASIC, or groin; type C: pain is located in the back or anterolateral side of the thigh; type D: pain over the knee, reaching the posterior or anterolateral calf; and type E: pain in 2 or more different parts of type A–D. In addition, they also found that distant pain is common in patients with OVCF, type A is the most common type, and types D and E are relatively rare.

Lumbar degenerative changes are often present in elderly people, so pain in distal areas should be distinguished from lumbosacral pain caused by lumbar degenerative diseases. In general, the pain in the distant region and focal pain in the fractured vertebrae occur at the

same time after the trauma (or no trauma) or later than local pain; distal pain is often more severe than local pain; distal pain is relieved during bed rest but aggravated when an individual changes body position; and percussion at the local level of the fractured vertebral body may sometimes cause distant pain (6). Our study showed that the average VAS score (6.37 ± 0.85) of distal pain was significantly higher than the local pain VAS score (4.34 ± 0.83) ($P = 0.000$). In addition, we found that 33.9% (21/62) of the included patients had pain in the distant lumbosacral region only and no local pain. These patients are most likely to be misdiagnosed with lumbar degenerative diseases. Therefore if elderly people with osteoporosis have lumbosacral pain, especially with a history of trauma, we should pay attention to the thoracolumbar examination results to exclude OVCF.

The specific pathogenesis of thoracolumbar OVCF

in patients with pain in the distant region remains unclear. The first hypothesis is the involvement of thoracolumbar joint syndrome, as proposed by Maigne (17). The T12, L1, and L2 dermatomes are localized in the lower back area, whereas the buttocks and ASIC skin are innervated by the superior gluteal nerve, which originates from the posterolateral branches of the L1-L3 spinal nerves (17,18). If the posterior branches or dorsal root ganglia of the spinal nerve at T12, L1, and L2 are irritated, oppressed, or stretched by the narrowing of the intervertebral foramen, kyphosis, or abnormal facet joint alignment resulting from decreased heights of the thoracolumbar OVCF vertebral bodies, pain may be distributed in the lower back, buttocks, or ASIC and be considered radicular or somatic referred pain (17,19). Therefore some scholars (5,7,19) believe that the vertebral height, kyphosis, and facet joint orientation are partially corrected after vertebral augmentation, which may reduce the stimulation of the posterior branch of the spinal nerve, thereby alleviating pain in the distal region. In this study, we found that at 3 days after surgery and last follow-up, the anterior height and Cobb angle of the vertebral body in the PVP and PKP groups significantly improved compared with before surgery, but the PKP group showed significantly larger improvements than the PVP group. However, there were no significant differences in the CMODI score or local or distant pain VAS scores between the 2 groups. In other words, the postoperative clinical efficacy did not significantly improve with the apparent correction of the AVH and Cobb angle. In addition, in clinical practice, OVCF rarely decreases the posterior edge height of the vertebral body, causes obvious stenosis of the intervertebral foramen, or causes radicular pain.

Another mechanism that can explain the development of pain in the distant region in patients with OVCF is the theory of vertebro-genic referred pain. The mechanism of referred pain is explained by the convergence-projection hypothesis, which states that primary afferent nerve fibers from 2 different areas converge into the same secondary neuron in the spinal cord, causing the central nervous system to incorrectly identify the source of pain (6,20,21). In animal experiments involving Sprague-Dawley rats, Sameda et al (20) found that dorsal root ganglion (DRG) neurons with dichotomizing afferent fibers connect to both the lumbar disc and the groin skin. In view of the neuroanatomic basis and the principle of referred pain, it is widely accepted that discogenic low back pain can cause referred pain in the groin area. The vertebral body is rich in sensory

nerve endings. These nerves mainly come from the basivertebral nerve of the branch of the sinuvertebral nerve. The positive reactions of substance P, PGP 9.5, and calcitonin gene-related peptide in the basivertebral nerve indicate that the basivertebral nerve is a pain-transmitting nerve that can conduct pain (22-25). In addition, Ohtori et al (26) found that sensory nerve fibers in the L2 vertebral body are derived from the T11-L3 DRGs, and that some sensory nerves from the L2 vertebral body enter the paravertebral sympathetic trunks and reach the DRGs at multisegmental levels. This finding may explain why elderly patients feel pain in several portions of the body after OVCF (26). Indeed, in postmenopausal women with back pain, the presence of lateral waist area pain has been found to be associated with a 4.5-fold increased risk of vertebral fractures (27). Moreover, using neural tracer technology, Fujii et al (21) found that dichotomizing sensory nerve fibers innervated both the vertebral L2 body and the ASIC. This finding provides a possible neuroanatomic explanation for referred pain in the ASIC from vertebral bodies. In clinical practice, we have found that thoracolumbar vertebral tuberculosis can sometimes cause lumbosacral pain. Therefore we believe that distant lumbosacral pain may be considered vertebro-genic referred pain caused by thoracolumbar OVCF. This study showed that both PVP and PKP can quickly and effectively alleviate the symptoms of distal lumbosacral pain, which may be related to the stabilization of the vertebral body with bone cement and the deactivation of sensory nerve endings in the vertebral body.

This study has some limitations. First, this study is retrospective and may be prone to selection bias. However, the degree of bias may be limited because we used strict inclusion and exclusion criteria and matched patients. Second, because of cultural and linguistic differences, the original version of the ODI could not be properly understood and completed by people in mainland China. Therefore in this study, the CMODI was used, but the correlation coefficients of the CMODI within and between groups were 0.953 and 0.912, respectively (14). Third, a pain diagram was not used to accurately reflect the location of pain in the distant lumbosacral region.

CONCLUSIONS

Both PVP and PKP can effectively alleviate pain in the distant lumbosacral region caused by thoracolumbar OVCF, and distant lumbosacral pain associated with thoracolumbar OVCF may be considered vertebro-genic referred pain.

REFERENCES

1. Choi SH, Kim DY, Koo JW, Lee SG, Jeong SY, Kang CN. Incidence and management trends of osteoporotic vertebral compression fractures in South Korea: A nationwide population-based study. *Asian Spine J* 2020; 14:220-228.
2. Hinde K, Maingard J, Hirsch JA, Phan K, Asadi H, Chandra RV. Mortality outcomes of vertebral augmentation (vertebroplasty and/or balloon kyphoplasty) for osteoporotic vertebral compression fractures: A systematic review and meta-analysis. *Radiology* 2020; 295:96-103.
3. Wang H, Sribastav SS, Ye F, et al. Comparison of percutaneous vertebroplasty and balloon kyphoplasty for the treatment of single level vertebral compression fractures: A meta-analysis of the literature. *Pain Physician* 2015; 18:209-222.
4. Sanli I, van Kuijk SMJ, de Bie RA, van Rhijn LW, Willems PC. Percutaneous cement augmentation in the treatment of osteoporotic vertebral fractures (OVFs) in the elderly: A systematic review. *Eur Spine J* 2020; 29:1553-1572.
5. Niu J, Song D, Gan M, et al. Percutaneous kyphoplasty for the treatment of distal lumbosacral pain caused by osteoporotic thoracolumbar vertebral fracture. *Acta Radiol* 2018; 59:1351-1357.
6. Shi M, Chen T, Liang J, Lu W, Xu Y, Lu S. Percutaneous kyphoplasty for treatment of distant pain associated with osteoporotic vertebral compression fracture. *Chin J Orthop Trauma* 2018; 20:136-141.
7. Yang YM, Ren ZW, Ma W, Jha RK. Kyphoplasty for the treatment of pain distant to osteoporotic thoracolumbar compressive fractures. *Cell Biochem Biophys* 2014; 68:523-527.
8. Wang L, Guo D, Hou Z. Response of pain beyond the osteoporotic vertebral compression fracture to percutaneous vertebral augmentation. *Chin J Orthop Trauma* 2010; 12:122-125.
9. Liu X, Li C, Yu Z, et al. Distant pain after thoracolumbar compressive fracture. *Natl Med J China* 2010; 90:346-348.
10. Gibson JE, Pilgram TK, Gilula LA. Response of nonmidline pain to percutaneous vertebroplasty. *AJR Am J Roentgenol* 2006; 187:869-872.
11. Friedrich M, Gittler G, Pieler-Bruha E. Misleading history of pain location in 51 patients with osteoporotic vertebral fractures. *Eur Spine J* 2006; 15:1797-1800.
12. Shan J, Zhang Y, Shan Z, Li F. Mechanism of lumbosacral pain in thoracolumbar vertebral compression fractures. *J Spinal Surg* 2015; 13:33-36.
13. Shi M, Chen T, Liang J, Lu W, Xu Y, Lu S. Clinical classification and treatment of somatic referred pain of osteoporotic vertebral compression fracture. *J Pract Orthop* 2019; 25:201-204.
14. Zheng G, Zhao X, Liu G, Zhang L. Reliability of the modified Oswestry Disability Index for evaluating patients with low back pain. *Chin J Spine Spinal Cord* 2002; 12:13-15.
15. Teng MM, Wei CJ, Wei LC, et al. Kyphosis correction and height restoration effects of percutaneous vertebroplasty. *AJNR Am J Neuroradiol* 2003; 24:1893-1900.
16. Gaughen JR Jr, Jensen ME, Schweickert PA, Kaufmann TJ, Marx WF, Kallmes DF. Lack of preoperative spinous process tenderness does not affect clinical success of percutaneous vertebroplasty. *J Vasc Interv Radiol* 2002; 13:1135-1138.
17. Maigne R. Low back pain of thoracolumbar origin. *Arch Phys Med Rehabil* 1980; 61:389-395.
18. Iwanaga J, Simonds E, Patel M, Oskouian RJ, Tubbs RS. Anatomic study of superior cluneal nerves: Application to low back pain and surgical approaches to lumbar vertebrae. *World Neurosurg* 2018; 116:e766-e768.
19. Doo TH, Shin DA, Kim HI, et al. Clinical relevance of pain patterns in osteoporotic vertebral compression fractures. *J Korean Med Sci* 2008; 23:1005-1010.
20. Sameda H, Takahashi Y, Takahashi K, Chiba T, Ohtori S, Moriya H. Dorsal root ganglion neurones with dichotomising afferent fibres to both the lumbar disc and the groin skin. A possible neuronal mechanism underlying referred groin pain in lower lumbar disc diseases. *J Bone Joint Surg Br* 2003; 85:600-603.
21. Fujii T, Sakuma Y, Orita S, et al. Dichotomizing sensory nerve fibers innervating both the lumbar vertebral body and the area surrounding the iliac crest: A possible mechanism of referred lateral back pain from lumbar vertebral body. *Spine (Phila Pa 1976)* 2013; 38:E1571-E1574.
22. Ohtori S, Inoue G, Koshi T, et al. Characteristics of sensory dorsal root ganglia neurons innervating the lumbar vertebral body in rats. *J Pain* 2007; 8:483-488.
23. Frasc C, Kravetz P, Mody DR, Heggeness MH. Substance P-containing nerves within the human vertebral body. An immunohistochemical study of the basivertebral nerve. *Spine J* 2003; 3:63-67.
24. Antonacci MD, Mody DR, Heggeness MH. Innervation of the human vertebral body: A histologic study. *J Spinal Disord* 1998; 11:526-531.
25. Bailey JF, Liebenberg E, Degmetich S, Lotz JC. Innervation patterns of PGP 9.5-positive nerve fibers within the human lumbar vertebra. *J Anat* 2011; 218:263-270.
26. Ohtori S, Inoue G, Koshi T, et al. Sensory innervation of lumbar vertebral bodies in rats. *Spine (Phila Pa 1976)* 2007; 32:1498-1502.
27. Clark EM, Hutchinson AP, McCloskey EV, et al. Lateral back pain identifies prevalent vertebral fractures in postmenopausal women: Cross-sectional analysis of a primary care-based cohort. *Rheumatology (Oxford)* 2010; 49:505-512.