

Prospective Trial

# Comparison of Thoracic Epidural Access with Lateral Decubitus and Shoulder Rotation Positions for Repeat Thoracic Epidural Blockade

Byung-Gun Kim, MD<sup>1</sup>, Jong-Kwon Jung, MD<sup>1</sup>, Chunwoo Yang, MD<sup>1</sup>, Woojoo Lee, PhD<sup>2</sup>, Hyunmin Kim, MD<sup>1</sup>, Ki-Hyun Park, MD<sup>1</sup>, and Hyunzu Kim, MD, PhD<sup>1</sup>

From: <sup>1</sup>Department of Anesthesiology and Pain Medicine, Inha University College of Medicine, Incheon, Republic of Korea; <sup>2</sup>Department of Public Health Science, Graduate School of Public Health, Seoul National University, Seoul, Republic of Korea

Address Correspondence: Hyunzu Kim, MD, PhD  
Department of Anesthesiology and Pain Medicine, Inha University College of Medicine, 27, Inhang-ro, Jung-gu, Incheon, Republic of Korea  
Email: aneshyunzu@gmail.com

Disclaimer: This work was supported by Inha University, Research Grant no. INHA-60138-01.

Conflict of interest: Each author certifies that he or she, or a member of his or her immediate family, has no commercial association (i.e., consultancies, stock ownership, equity interest, patent/licensing arrangements, etc.) that might pose a conflict of interest in connection with the submitted manuscript.

Manuscript received: 05-18-2020  
Revised manuscript received: 09-09-2020  
Accepted for publication: 10-16-2020

Free full manuscript: [www.painphysicianjournal.com](http://www.painphysicianjournal.com)

**Background:** Shoulder rotation has been shown to increase the acoustic window of ultrasound for thoracic epidural access. However, this effect of shoulder rotation has not yet been confirmed in clinical practice.

**Objective:** This study aimed to evaluate the effects of shoulder rotation on the thoracic epidural blockade in patients with acute or chronic pain in the thoracic region.

**Study Design:** Prospective crossover trial.

**Setting:** Pain clinic of our university in the Republic of Korea.

**Methods:** Forty patients aged 20 – 80 years with acute or chronic pain in the thoracic region who were scheduled to undergo thoracic epidural blockade more than twice.

Interventions: The patients underwent repeated fluoroscopy-guided thoracic epidural blockade via the paramedian approach in the lateral decubitus position either with or without shoulder rotation.

The primary outcome measure was the attempt time to the confirmed spread of contrast. The number of attempts, total procedure time, vertical interpedicular distance, contrast spreading length, and complications were compared between the 2 positions.

**Results:** The median attempt times in the lateral decubitus and shoulder rotation positions were 138.8 and 132.5 seconds, respectively, and this difference was significant ( $P = 0.004$ ). Compared with the lateral decubitus position, the shoulder rotation position was also associated with a significantly lower number of attempts ( $P = 0.03$ ), shorter total procedure time ( $P < 0.001$ ), and greater vertical interpedicular and contrast spreading distances ( $P < 0.001$  and  $P = 0.02$ , respectively).

**Limitations:** The operator in this study was not blinded to the patient groups. Other researchers observed the operator's procedure and evaluated and recorded the data in an attempt to overcome this bias. However, it was difficult to completely avoid the bias. Second, epidural blockade was performed at various levels (T3–11), and the anatomical features vary among thoracic spine levels.

**Conclusions:** The study findings demonstrate the clinical benefits of the shoulder rotation position versus the lateral decubitus position in terms of successful epidural access during thoracic epidural blockade using the paramedian approach.

**Key words:** contrast spreading length, fluoroscopy, lateral decubitus position, paramedian approach, shoulder rotation, thoracic epidural blockade, vertical interpedicular distance

Pain Physician 2021; 24:E327-E334

**T**horacic epidural blockade has been used for postoperative analgesia and the treatment of chronic pain in the thoracic and upper abdominal area (1,2). Compared with intravenous patient-controlled analgesia, the thoracic epidural blockade has superior analgesic properties and additionally suppresses neuro-humoral responses (3,4).

The thoracic epidural blockade is a relatively difficult procedure, even for expert anesthesiologists (5,6). Despite various efforts, failure rates of 30% – 50% have been reported for this type of blockade (7,8). In the thoracic spine, the intervertebral spaces are narrower and spinous process overlaps are steeper than those in the lumbar spine. Therefore, the paramedian approach is generally preferred over the midline approach, as needle obstruction by the spinous process represents a disadvantage of the latter process (9,10). One study reported that the sitting position allows relatively easy thoracic epidural access because it induces a more negative epidural pressure than the lateral decubitus position (11). Previous studies have presented rare strategies for optimizing the actual procedure of thoracic epidural access (9-11).

The ultrasound measurement of the length of the posterior longitudinal ligament (PLL) has been reported as a useful predictor of the success of various neuro-axial approach clinical procedures, including thoracic epidural access (12,13). Particularly, several studies have demonstrated that the shoulder rotation increases the acoustic window indicating the length of the PLL of the thoracic spine under ultrasound. However, those studies only compared the acoustic window of ultrasound, and the effect of shoulder rotation has not yet been confirmed in clinical practice (14-16). In this study, we aimed to determine whether shoulder rotation could improve thoracic epidural access in the lateral decubitus position.

## METHODS

### Ethics and Patients

The study was approved by the Institutional Review Board of our university in the Republic of Korea. Written informed consent was obtained from all patients. The trial was registered at the Clinical Research Information. This manuscript adheres to the applicable CONSORT guidelines.

We enrolled adults with acute or chronic pain in the thoracic region who were scheduled to undergo

thoracic epidural blockade more than twice at the pain clinic. Forty patients aged 20 – 80 years who had an American Society of Anesthesiologists physical status of I – III were recruited. Patients with any contraindications to thoracic epidural blockade (e.g., increased intracranial pressure, bleeding tendency, infection at the injection site, hypersensitivity to amide-group local anesthesia), a body mass index > 40 kg m<sup>-2</sup>, history of spinal surgery, or congenital spinal deformity were excluded. All patients received one thoracic epidural blockade in the conventional lateral decubitus position and an additional blockade in the shoulder rotation position. The procedures were performed twice at intervals of one week and the sequence of the 2 positions was assigned randomly using sealed envelopes.

### Position

All procedures were performed by a single physician with experience of more than 1,000 fluoroscopy-guided thoracic epidural blockade procedures. Upon arrival in the procedure room, the patients were monitored using echocardiography, a blood pressure meter, and a pulse oximeter. Thoracic epidural blocks were performed under C-arm fluoroscopy (SPINEL 3G, GEMSS MEDICAL, Seongnam, Republic of Korea). To meet specific needs according to the level of thoracic spine block, the patients were additionally instructed to raise both arms above their head to allow a clear path for the C-arm fluoroscope.

In the procedure involving the conventional lateral decubitus position, each participant was placed on a horizontal operating table in the right or left lateral decubitus position with the cervical and lumbar spine flexed and was requested to flex their hips and knees as much as possible to maintain the position. In the procedure involving the shoulder rotation position, the patient was placed on a horizontal operating table in the conventional right or left lateral decubitus position. The patient was then requested by the investigator to rotate the independent shoulder using the contralateral dependent shoulder as the axis of rotation. The shoulder was rotated to 30° by another assistant using a protractor tool (KHTSXR, Seoul, Republic of Korea) on a Samsung Galaxy S9 smartphone (Samsung Electronics Co., Seoul, Republic of Korea) (15).

### Procedure

Under C-arm guidance, the anterior-posterior view was adjusted such that the target thoracic spinous process was at the midline of the vertebral body and the

thoracic vertebral body formed a square. The needle insertion site was cleaned and sterilized with betadine solution and covered with sterile cloth. Local infiltration of 2% lidocaine was performed at the entry point using a 25-gauge needle, and a 20-gauge Tuohy needle (Insung Medical, Republic of Korea) was used to pierce the skin. The needle entry point was at the junction of the pedicle midline parallel to the target thoracic vertebral body midline and the lower target thoracic vertebral body border on the anterior-posterior fluoroscopy view. The Tuohy needle was advanced medially at an approximate 10° angle to the level of the vertebral lamina, withdrawn slightly, and advanced in a more medial and cephalad direction until the needle tip reached the midline at the height of the pedicle. For further needle advancement, care was taken to avoid touching the bone and to ensure entry directly within the interlaminar space. This step was accomplished slowly using the hanging drop method until the needle was located in the epidural space. In case of a failure to identify the epidural space, the needle was completely removed and reinserted. After a loss-of-resistance was obtained, a 3-mL bolus of contrast media (300 mg mL<sup>-1</sup> Omnipaque; GE Healthcare) was injected under real-time continuous fluoroscopy, and lateral and anterior-

posterior view images were obtained. The absence of contrast spread at the intravascular, subarachnoid, subdural, or intradiscal space was verified using real-time continuous fluoroscopy. The success of the epidural blockade was then confirmed (Fig. 1).

### Assessments

Another researcher who did not participate in the procedure recorded the attempt time, total procedure time, attempt number, vertical interpedicular distance, and contrast spreading distance. The attempt time was considered to be the primary outcome and was defined as the time required for one successful blockade trial, i.e., the total time from the insertion of the Tuohy needle to the confirmation of successful access via fluoroscopy. The total procedure time was defined as the total time taken for the entire blockade, including multiple trials, from the initial insertion of the Tuohy needle to the confirmation of successful access via fluoroscopy. The attempt number was defined as the total number of needle insertions required to complete the entire procedure. In all patients, complications such as hypotension, skin and subcutaneous hematoma, paresthesia, hemothorax, pneumothorax, and postural puncture headache were recorded.

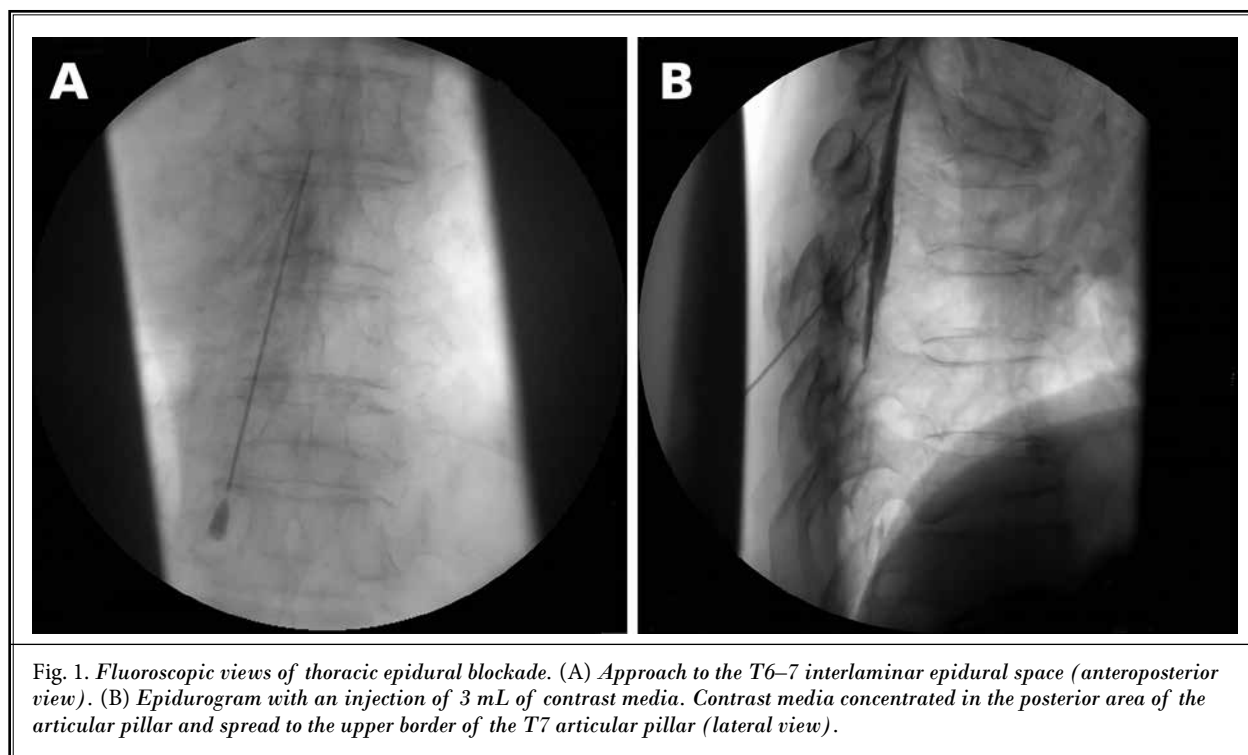


Fig. 1. Fluoroscopic views of thoracic epidural blockade. (A) Approach to the T6–7 interlaminar epidural space (anteroposterior view). (B) Epidurogram with an injection of 3 mL of contrast media. Contrast media concentrated in the posterior area of the articular pillar and spread to the upper border of the T7 articular pillar (lateral view).

## Statistical Analysis

The sample size estimation was based on data from a pilot study that compared the attempt time in a conventional lateral position in 10 patients. Based on a reduction in the attempt time of  $169 \pm 57$  seconds, a minimum 20% difference in the attempt time, and a sample size of 32 patients at an  $\alpha$  of 0.05 would be required for clinically relevant results. Assuming a lost-to-follow-up rate of 20%, a total sample size of 40 was needed to achieve a power of 90%. Statistical analyses were performed using the Statistical Package for the Social Sciences (SPSS) version 19.0 (SPSS Inc., Chicago, IL, USA). All data are expressed as means  $\pm$  standard deviations, numbers, or medians (interquartile range [IQR]), as indicated. After testing for normally distributed data using the Kolmogorov–Smirnov test and Shapiro–Wilk test, continuous variables were analyzed using a paired t-test. Non-normally distributed variables were analyzed using the Wilcoxon signed-rank test. Statistical significance was defined as a  $P < 0.05$ .

## RESULTS

Figure 2 illustrates the study enrollment and participant flow. Forty patients completed all the procedures without any range limitation of the shoulder joint motion. The characteristics of these patients are presented in Table 1 according to the procedure sequence.

Table 2 presents the thoracic epidural access data by position. The median (IQR) procedure attempt time in

the shoulder rotation position was significantly shorter than that in the conventional lateral decubitus position ( $P = 0.004$ ). Figure 3A indicates the attempt times in the conventional lateral decubitus and shoulder rotation positions. Similarly, the total procedure time was significantly shorter in the shoulder rotation position ( $P < 0.001$ ). The median number of attempts was one (zero) in the shoulder rotation position and one (one) in the conventional lateral decubitus position ( $P = 0.033$ ). The vertical interpedicular and contrast spread distances were significantly longer in the shoulder rotation position than in the conventional lateral decubitus position ( $P < 0.001$  and  $P = 0.02$ , respectively).

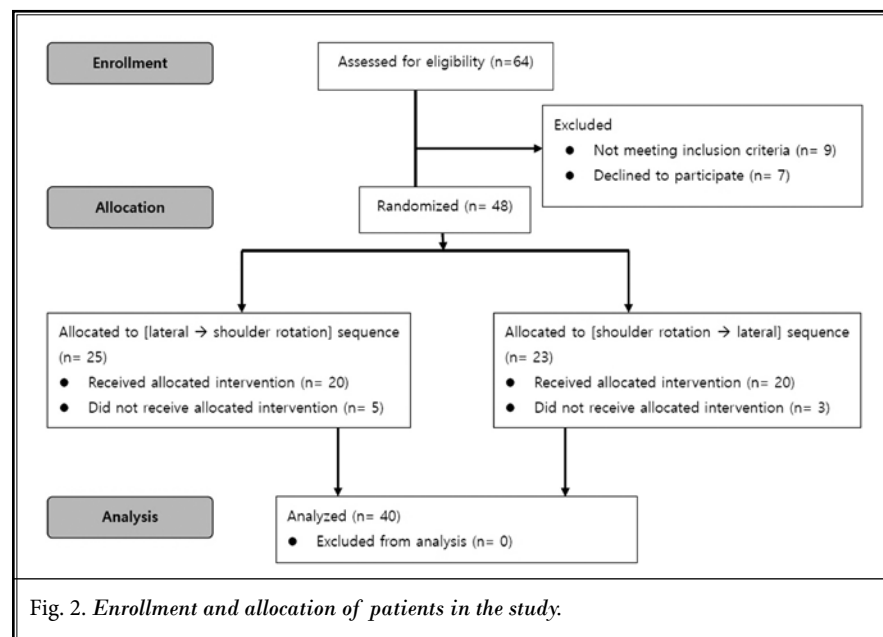
Subsequently, a subgroup analysis of the thoracic epidural blockade data was conducted according to the number of attempts in the lateral decubitus position. Cases in which access was achieved on the first attempt in the conventional lateral position were classified as easy access cases. Those in which access was achieved after 2 or more attempts were classified as difficult access cases. Table 3 presents the results of the subgroup analysis. Of the 40 patients, 27 and 13 were classified as easy and difficult access cases in the conventional lateral decubitus position, respectively. Differences in the attempt time and total procedure time before and after shoulder rotation were significantly greater in the difficult access cases than in the easy access cases ( $P = 0.00197$  and  $P = 0.0019$ , respectively). Figure 3B indicates the attempt times in the different positions among the difficult access cases. The vertical interpedicular and contrast spreading distances after shoulder rotation did not differ significantly between the easy access and difficult access cases ( $P = 0.0624$  and  $P = 0.502$ , respectively).

Regarding safety, none of the patients experienced complications such as hypotension, skin and subcutaneous hematoma, paresthesia, hemothorax, or postural puncture headache.

Regarding safety, none of the patients experienced complications such as hypotension, skin and subcutaneous hematoma, paresthesia, hemothorax, or postural puncture headache.

## DISCUSSION

In this prospective comparison study, the shoulder rotation maneuver in the lateral decubitus position statistically



decreased the procedure time and number of attempts for the thoracic epidural blockade. Although the reductions were statistically significant, they were clinically irrelevant.

The thoracic epidural blockade is difficult because of the anatomical features of the thoracic spine, and few available methods can facilitate access. Several recent studies have demonstrated that ipsilateral shoulder rotation increases the length of the PLL, which is a dimension of the acoustic target window in ultrasound, suggesting that this position may promote thoracic epidural access (14-16). As noted previously, the effect of shoulder rotation remains to be confirmed in actual patients in a clinical setting. In this study, we assessed the effect of shoulder rotation during thoracic epidural blockade by comparing the attempt time, total procedure time, and the number of attempts in the same patients who received repeated blockades with and without after shoulder rotation maneuver in the lateral decubitus position. In each patient, 2 thoracic epidural blockades were performed using the same method by the same physician with differences in whether it should be shoulder rotation or not. To the best of our knowledge, this is the first study to evaluate the effect of shoulder rotation during the thoracic epidural blockade.

In this study, the attempt time was defined as the amount of time spent only on successful attempts and did not consider the number of attempts even if multiple attempts were made. We postulated that the time spent on successive procedures would most effectively

Table 1. Demographic characteristics of all patients.

Characteristics	Data (n = 40)
Age (years)	67.5 ± 9.7
Men:Women	23:17
Height (cm)	162.8 ± 9.3
Weight (kg)	64.7 ± 11.1
BMI	24.3 ± 3.3
Etiology (PHN:Other)	23:17
Right:Left	24:16

BMI, body mass index; PHN, postherpetic neuritis. Data are presented as means ± standard deviations or numbers.

Table 2. Comparative profiles of thoracic epidural blockade between 2 positions.

	Conventional lateral decubitus position	Shoulder rotation position	P value
Attempt time (s)	138.8 (73.1)	132.5 (29.1)	0.004*
Total procedure time (s)	267.3 (134)	233.6 (57.5)	0.0001*
Attempt number	1 (1)	1 (0)	0.033*
Vertical interpedicular distance (mm)	16.1 (4.1)	16.5 (4.6)	0.0001*
Contrast spreading length (mm)	38.6 ± 8.7	39.3 ± 8.6	0.02*

SR, shoulder rotation. Data are presented as medians (interquartile ranges) or means ± standard deviations.

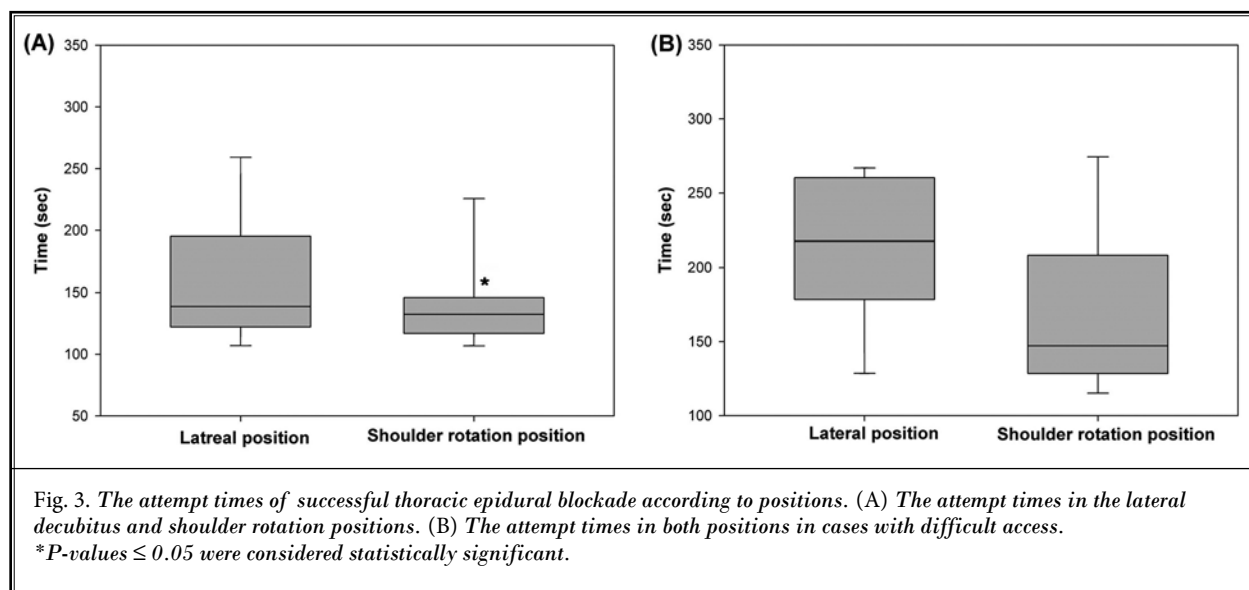


Table 3. Profile of thoracic epidural blockade with shoulder rotation according to the number of attempts.

	Lateral decubitus position	Shoulder rotation position	P value*	Difference	P value†
Easy access cases (number of attempts in the lateral decubitus position = 1)					
Attempt time (s)	132.9 (26.9)	127.2 (25)	0.28	-4.1 ± 11.1	
Total procedure time (s)	227.3 (60.8)	212.6 (50.1)	0.01	-13.1 ± 17.4	
Vertical interpedicular distance (mm)	16.3 (5.4)	16.8 (5.9)	0.0001	0.6 ± 0.3	
Contrast spreading length (mm)	40.2 ± 8.6	40.7 ± 8.5	0.208	0.5 ± 2.1	
Difficult access cases (number of attempts in the lateral decubitus position of ≥ 2)					
Attempt time (s)	217.3 (86.1)	154.8 (100.7)	0.096	-40.2 ± 75.2	0.009
Total procedure time (s)	372.9 (71.4)	258.9 (120.5)	0.022	-69.7 ± 95.6	0.004
Vertical interpedicular distance (mm)	14.9 (3.6)	15.3 (3.6)	0.01	0.5 ± 0.4	0.41
Contrast spreading length (mm)	35.5 ± 8.5	36.5 ± 8.4	0.003	1 ± 0.1	0.47

SR, shoulder rotation.

Data are presented as medians (interquartile ranges) or means ± standard deviations

represent the difficulty of thoracic epidural access. The attempt time was significantly reduced in the shoulder rotation position compared with that in the lateral decubitus position. As shown in Fig. 3A, this difference was caused by the differential distribution of data of the attempt time in the 2 positions. Indeed, the difference in the median attempt time was extremely small for a clinical significance. Overall, we speculate that the thoracic epidural blockade was performed with relative ease in 27 of the 40 patients examined. Moreover, a single expert physician performed all thoracic epidural blockade procedures under fluoroscopic guidance. However, the actual clinical situation may differ; therefore, future studies should assess other clinical situations, i.e., thoracic epidural blockade performed by a trainee or without fluoroscopic guidance. There is insufficient evidence to support the clinical advantage of improved thoracic epidural access with the shoulder rotation maneuver.

Compared with the lateral decubitus position, the shoulder rotation maneuver could statistically reduce not only the attempt time but also the total procedure time and the number of attempts. The reduction in the total procedure time (i.e., time spent on the entire procedure) was attributed to the time spent on the procedure and the reduced number of attempts after the shoulder rotation maneuver. This measure did not include the time required to adjust the fluoroscopic image because the needle insertion, which was used to measure the attempt time, was started after the best fluoroscopic view was established. Nevertheless, the difference between the 2 positions in the total procedure time and the number of attempts is also too small as in the attempt time data. These favorable results indicate the potential benefit of the shoulder rotation

maneuver to improve thoracic epidural access.

The vertical interpedicular distance increased significantly in the shoulder rotation position compared to the lateral decubitus position. Rotation of the ipsilateral shoulder in the lateral decubitus position causes a separation of the adjacent thoracic laminae and an outward movement of the spinous process from the midline, thus broadening the interlaminar space. This finding was consistent with those of previous studies that used ultrasound to evaluate the length of the PLL and reported the presence of an unobstructed path between the laminae by the bony structure (14-16). Shoulder rotation can alter the anatomical structure of the thoracic spine. Particularly, this position can increase the interlaminar space and thus enhance thoracic epidural access.

The contrast media spread distance was significantly longer in the shoulder rotation position than in the lateral decubitus position. In patients undergoing epidural block, the contrast media spread distance on epidurography can predict the analgesic block distribution (17). This increase in the contrast media spread distance could be attributed to an actual increase in the region affected by local anesthesia or to secondary changes resulting from an anatomical increase in the interlaminar space. During the thoracic epidural blockade, the shoulder rotation maneuver increases the distribution of contrast media. However, additional studies are needed to conclusively demonstrate that increased distribution of the anesthetic agent due to the shoulder rotation maneuver can improve the clinical effect of thoracic epidural blockade.

We additionally performed subgroup analysis according to the number of attempts in the conventional

lateral decubitus position. The procedure profiles were compared between the patients where the thoracic epidural blockade was successfully achieved with one attempt and those where more than one attempt was made in the conventional lateral position. This post-hoc analysis aimed to compare the procedural differences in thoracic epidural access to determine the effect of shoulder rotation depending on the level of difficulty. The differences in both the attempt time and total procedure time with and without shoulder rotation were clinically and statistically significant. These results show that the effect of shoulder rotation was greater in the difficult-to-access cases and that the clinical benefit of the shoulder rotation maneuver is more pronounced in patients where it is difficult to achieve thoracic epidural blockade.

In this study, we performed thoracic epidural blockade in the lateral decubitus position, which yielded a slightly lower success rate than that reported previously for the sitting position (18). Vagal reflex or hypotensive events can occur in thoracic epidural blockade (19). In such cases, it is dangerous for the patient to remain in the sitting position. Previous studies that used ultrasound to estimate the length of PLL reported no significant difference between the lateral and sit-

ting positions after shoulder rotation (16). Therefore, we selected the lateral decubitus position to ensure patient safety.

This study had some limitations. First, the operator in this study was not blinded to the patient groups. To overcome this bias, other researchers observed the operator's procedure and evaluated and recorded the data. In studies that evaluate the effects of this type of technique, it is difficult to completely avoid the bias caused by un-blinded operators. Second, an epidural blockade was performed at various levels (T3–11). The anatomical features vary among thoracic spine levels, and epidural access at the mid-thorax (T5–8) is particularly difficult. Third, the duration time for the procedure started after the established fluoroscopic view. Therefore, the total exposure time of radiation could not be obtained.

## CONCLUSION

In conclusion, compared to the conventional lateral decubitus position, the shoulder rotation maneuver provided several clinical benefits in patients undergoing thoracic epidural access, particularly in cases in which access was difficult.

## REFERENCES

- Hwang SM, Kang YC, Lee YB, Yoon KB, Ahn SK, Choi EH. The effects of epidural blockade on the acute pain in herpes zoster. *Arch Dermatol* 1999; 135:1359-1364.
- Royse C, Royse A, Soeding P, Blake D, Pang J. Prospective randomized trial of high thoracic epidural analgesia for coronary artery bypass surgery. *Ann Thorac Surg* 2003; 75:93-100.
- Liu S, Carpenter RL, Neal JM. Epidural anesthesia and analgesia. Their role in postoperative outcome. *Anesthesiology* 1995; 82:1474-1506.
- Freise H, Van Aken HK. Risks and benefits of thoracic epidural anaesthesia. *Br J Anaesth* 2011; 107:859-868.
- Podder S, Kumar N, Yaddanapudi LN, Chari P. Paramedian lumbar epidural catheter insertion with patients in the sitting position is equally successful in the flexed and unflexed spine. *Anesth Analg* 2004; 99:1829-1832.
- Wantman A, Hancox N, Howell PR. Techniques for identifying the epidural space: A survey of practice amongst anaesthetists in the UK. *Anaesthesia* 2006; 61:370-375.
- Ready LB. Acute pain: Lessons learned from 25,000 patients. *Reg Anesth Pain Med* 1999; 24:499-505.
- Motamed C, Farhat F, Rémérand F, Stéphanazzi J, Laplanche A, Jayr C. An analysis of postoperative epidural analgesia failure by computed tomography epidurography. *Anesth Analg* 2006; 103:1026-1032.
- Grau T, Leipold RW, Delorme S, Martin E, Motsch J. Ultrasound imaging of the thoracic epidural space. *Reg Anesth Pain Med* 2002; 27:200-206.
- Chin KJ, Karmakar MK, Peng P. Ultrasonography of the adult thoracic and lumbar spine for central neuraxial blockade. *Anesthesiology* 2011; 114:1459-1485.
- Gil NS, Lee JH, Yoon SZ, Jeon Y, Lim YJ, Bahk JH. Comparison of thoracic epidural pressure in the sitting and lateral decubitus positions. *Anesthesiology* 2008; 109:67-71.
- Weed JT, Taenzer AH, Finkel KJ, Sites BD. Evaluation of pre-procedure ultrasound examination as a screening tool for difficult spinal anaesthesia. *Anaesthesia* 2011; 66:925-930.
- Chin KJ. Recent developments in ultrasound imaging for neuraxial blockade. *Curr Opin Anaesthesiol* 2018; 31:608-613.
- Ramsay N, Walker J, Tang R, Vaghadia H, Sawka A. Flexion-rotation manoeuvre increases dimension of the acoustic target window for paramedian thoracic epidural access. *Br J Anaesth* 2014; 112:556-562.
- Byon HJ, Song JH, Song KC, Lim H, Kim H. The effects of shoulder rotation on the acoustic window for thoracic paramedian epidural approach in the lateral decubitus position. *Reg Anesth Pain Med* 2016; 41:572-575.
- Byon HJ, Hong SJ, Kim DY, et al. Comparison of the acoustic windows for the thoracic paramedian epidural approach after shoulder rotation: The lateral decubitus versus the sitting position. *Anaesth Crit Care Pain Med* 2019; 38:53-56.
- Yokoyama M, Hanazaki M, Fujii H, et al. Correlation between the distribution of contrast medium and the extent of blockade during epidural anesthesia. *Anesthesiology* 2004; 100:1504-1510.

18. Nishi M, Usukaura A, Kidani Y, Tsubokawa T, Yamamoto K. Which is a better position for insertion of a high thoracic epidural catheter: Sitting or lateral decubitus? *J Cardiothorac Vasc Anesth* 2006; 20:656-658.
19. Reese CA. *Clinical Techniques of Regional Anesthesia: Spinal and Epidural Blocks*. American Association of Nurse Anesthetists, Park Ridge, IL, 2007.