

Technical Note

Two-Needle Technique for Lumbar Radiofrequency Medial Branch Denervation: A Technical Note

Kenneth B. Chapman, MD^{1,3}, Frank Schirripa, DO⁴, Thomas Oud, BS^{1,5}, Pauline S. Groenen, BS^{1,5}, Ryan R. Ramscook, MD¹, and Noud van Helmond, MD^{1,6}

From: ¹Spine and Pain Institute of New York, New York, NY, USA; ²Department of Anesthesiology, New York University Langone Medical Center, New York, NY, USA; ³Department of Anesthesiology, Zucker School of Medicine at Hofstra/Northwell, Manhasset, NY, USA; ⁴Department of Rehabilitation and Regenerative Medicine, New York Presbyterian Hospital, New York, NY, USA; ⁵Radboud University College of Medicine, Radboud University Nijmegen Medical Center, Nijmegen, the Netherlands; ⁶Department of Anesthesiology, Cooper University Medical School of Rowan University, Cooper University Health Care, Camden, NJ, USA

Address Correspondence:
Kenneth Chapman, MD
860 Fifth Ave.
New York, NY 10065
E-mail:
chapmanken@spinepainny.com

Disclaimer: There was no external funding in the preparation of this manuscript.

Conflict of interest: Each author certifies that he or she, or a member of his or her immediate family, has no commercial association (i.e., consultancies, stock ownership, equity interest, patent/licensing arrangements, etc.) that might pose a conflict of interest in connection with the submitted manuscript.

Manuscript received: 12-31-2019
Revised manuscript received:
02-11-2020
Accepted for publication:
04-08-2020

Free full manuscript:
www.painphysicianjournal.com

Background: Radiofrequency ablation (RFA) of the medial branches of the dorsal rami has been reported to relieve facet joint-related back pain for 6 months to 1 year in 60% of patients. Although providing benefit in a significant proportion of patients, there remains a group of patients who do not experience any pain relief from RFA or experience only benefit from the ablation for a short period. Failure of RFA has been attributed to technical failure of coagulating the nerve or coagulation of a minimal section of the nerve, allowing for early reinnervation. Increasing the success rate and duration of relief may require techniques that increase the likelihood of successful nerve ablation over a relevant distance by maximizing lesion size.

Objectives: The aim of this technical note is to detail a modification to the current commonly used lumbar medial branch radiofrequency (RF) denervation approach to increase lesion size.

Study Design: This is a technical report describing a novel two-needle approach to lumbar RF medial branch denervation.

Setting: Large private interventional pain management institute.

Methods: A dual needle placement of two 10-mm active tip RF cannulas separated by 6 mm is used to optimally contact the superior articular process (SAP) from its ventral to dorsal borders, which encompasses the anticipated course of the medial branch nerves.

Results: The described technique creates a lesion that we estimate to be 11.0-mm wide and 11.6-mm long along the course of the medial branch adjacent to the SAP ensuring adequate coverage and treatment.

Limitations: This report does not encompass a systematic evaluation of the clinical safety and efficacy of the two-needle RFA approach. Future studies will have to assess the long-term efficacy and safety of the approach.

Conclusions: The detailed two-needle approach to lumbar RF medial branch denervation appears to be promising in terms of projected treatment success by coagulating a large volume of tissue, in a cost- and time-efficient manner.

Key words: Radiofrequency ablation, RFA, lumbar, medial branch, facet joint, pain, rhizotomy

Pain Physician 2020; 23:E507-E516

Low back pain is the second most common cause of disability in United States (U.S.) adults (1) and a common reason for lost work days (2). It is estimated that an average of 149 million days of work per year are lost due to low back pain (3). Low back pain is associated with an estimated total cost of \$100

to \$200 billion annually, two-thirds of which are due to decreased wages and productivity (4).

Low back pain can arise from multiple anatomic locations: the intervertebral discs that are positioned between the vertebral bodies of the spine, the facet joint, but also nonbony structures such as the paravertebral muscles, ligaments, and fascia (5,6). Postmortem studies have revealed that intervertebral discs and facet joints exhibit the greatest degree of degeneration within the spine, thus indicating the potential role of these structures in causing low back pain (7). In patients with a structural cause of low back pain, up to 40% of cases likely arise from the lumbar facet joints (8,9). The etiology of lumbar facet-joint pain is thought to be stress and trauma to the joint, which subsequently leads to inflammation of the joint capsule (9). Treatment options for facet arthropathy range from conservative management with medications and physical therapy to interventional management, including facet-joint injections and radiofrequency ablation (RFA) of the medial branches of the posterior rami to the facet joints (9-11).

RFA of the medial branches of the dorsal rami is thought to be the most effective interventional treatment for facet joint pain and has been reported to relieve pain for 6 months to 1 year in 60% of patients (12). Although providing benefit in a significant proportion of patients, there remains a group of patients who do not experience any pain relief from RFA or experience only benefit from the ablation for a short period (13-16). Failure of RFA has been attributed to technical failure of coagulating the nerve or coagulation of a minimal section of the nerve, allowing for early reinnervation (12-16). Consequently, increasing the success rate and duration of relief may require techniques that increase the likelihood of successful nerve ablation over a relevant distance by maximizing lesion size (12). The aim of this technical note is to detail a two-needle approach to lumbar medial branch RF denervation to maximize lesion size along the course of the medial branch nerve.

METHODS

Relevant Anatomy

The lumbar facet joints are formed by the articulations of the superior and inferior articular facets of adjacent vertebrae. The capsule of the facet joint is highly innervated, which makes it a possible source of pain (17-20). Damage to the joint occurs through arthritic changes and trauma caused by flexion-extension and torsion injuries. Such damage results in pain second-

ary to synovial joint inflammation and adhesions (17). After the spinal nerve exits the intervertebral foramen, it divides into the meningeal branch, communicating branch, ventral and dorsal ramus. The dorsal ramus divides into the lateral and medial branches. Each facet joint is innervated by medial branch nerves that arise from the spinal nerve roots above and below the target facet joint. For example, the L4-5 facet joint is targeted at the L5 vertebral level but is innervated not only by the L5 medial branch nerve and the caudad branches of the L4 medial branch nerve. This necessitates the treatment of 2 medial branch nerves for optimal neural interruption from signals arising from one facet joint.

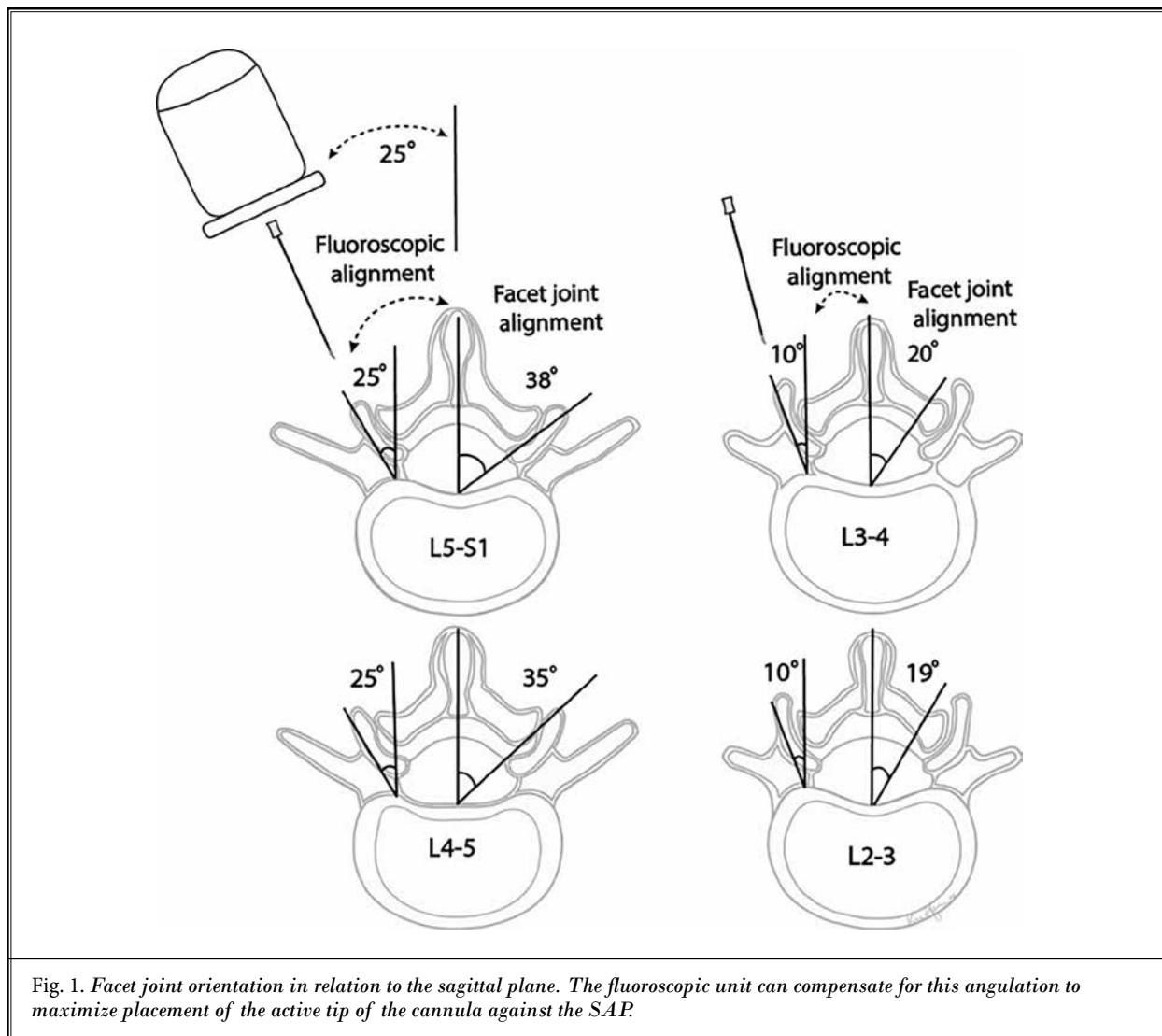
Bony Structures

On a macroscopic level, location and orientation of the medial branch nerve in the lumbar spine vary significantly from level to level. At the L1-L5 vertebral levels, the distance between the junction of the superior articular process (SAP) and transverse process (TP) from the spinous process is 24 to 33 mm on average at a needle depth of 31 to 46 mm (21). At the different L1-L5 levels, the midpoint of the fibro-osseous canal is roughly 21 to 29 mm lateral to the spinous process at a needle depth of 22 to 40 mm. The average distance of the bifurcation of the dorsal ramus into the medial and lateral branch nerves and the superior border of the TP root is 1.9 to 3.6 mm in the lumbar vertebral levels (21). These variations in distances at the different vertebral levels are secondary to multiple factors including vertebral body size, lordosis, and facet orientation.

The dimensions of the SAP in the lumbar spine range from 13.4 mm width x 14.8 mm height at L5 to 10.3 mm width x 11.6 mm height at L1. Facet joint orientation of L1-2 to L5-S1 rotates from the sagittal to oblique planes increasing from 18° to 38° oblique. Lumbar lordosis is responsible for craniocaudal angulation of the vertebral bodies and ranges from roughly an average of 5 to -5° at the L2-3 level to an average of 10° to 15° at the L5-S1 level (22,23). Figures 1, 2, and 3 illustrate these dimensions.

Medial Branch Nerve Location

The L1-L4 medial branch nerves consistently cross the root of the SAP and the TP and are fixed at this location by the intertransverse ligament. The medial branch nerve then travels caudally and dorsally and travels under the mamillo-accessory ligament with minimal variation. The L5 dorsal primary rami travel along the sacral ala and S1 SAP root and run into fibrous tissue,



which is analogous to the mamillo-accessory ligament at this level (24). Eventually the medial branch nerves will enter the fibro-osseous canal that is formed by the mamillo-accessory ligament, mammillary process, and accessory process. When the medial branch exits this canal, it innervates the facet joint by giving rise to small articular branches (21,24-27).

Approach

Conventional Approach

Several approaches to medial branch ablation have been detailed, and the nerve has traditionally been targeted either along its course from the point where

the nerve emerges under the mamillo-accessory ligament with a single needle along the bone, or a "gun barrel" approach at the colloquial "eye of the Scotty dog" (28-30). Because RF lesioning is maximal near the midportion of the active tip, with little coagulation at or distal to the tip of the needle (31), the "Scotty dog," "bullseye" approach appears illogical from an anatomic standpoint, but is still widely practiced. Although other single needle techniques have proved to be effective, malpositioning of a needle by several millimeters may lead to an inadequate lesion (32).

The technique we developed focuses on maximizing RF lesion size on the desired target by separating our needles by 6 mm, with one needle placed 2 mm below the junction of the SAP and TP and one 5 to 6

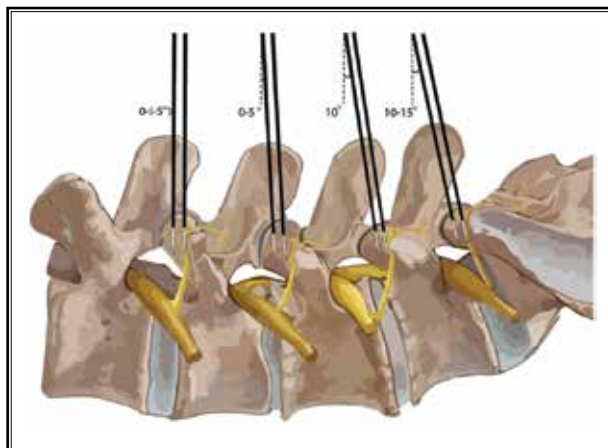


Fig. 2. Orientation of facet joint alignment in the cephalocaudal axis required to compensate for lumbar lordosis.

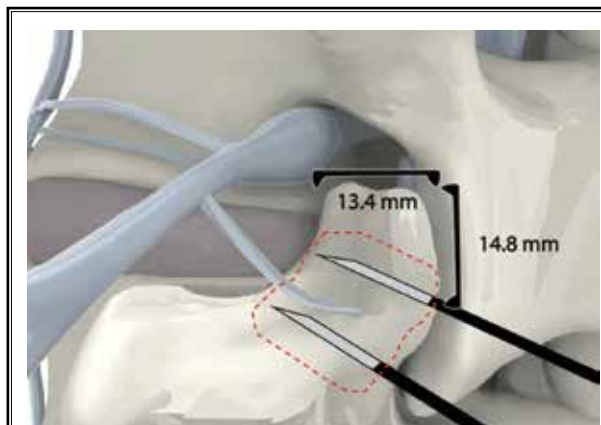


Fig. 3. The height and width of the SAP with two-needle RF cannula placement and potential lesion size (red dashed line).

mm rostral to this point with the active tip in the plane of the nerve. We include a review of the normal angles and orientations of the lumbar spine, which is required to have the appropriate starting point for needle entry for this technique. The objective is to have the 10-mm active tip contacting the SAP from its ventral to dorsal borders creating an 11 x 11 mm lesion, which encompasses the anticipated course of the medial branch nerves.

Two-Needle Technique

The patient is placed in the prone position and prepped and draped in the normal sterile fashion. Anatomic variations, such as postsurgical changes, spondylolisthesis, sacralized vertebrae, and scoliosis, should be evaluated prior to initiation of the procedure. As previously mentioned, the normal lumbar lordosis and rotation of the facet joints requires special consideration per level.

Initial fluoroscopic positioning for needle placement requires alignment of the superior endplate of the vertebral level of the target SAP. An oblique rotation of the fluoroscopic unit to the ipsilateral side of approximately 25° is used to compensate for lordosis at the L4-5 and L5-S1 levels, a cephalad angulation of the fluoroscopic unit of approximately 10° is required (Fig. 2). After the skin is prepared with chlorhexidine solution (3M Infection Prevention Division, London, Ontario, Canada), a skin wheal of local anesthetic is raised. A 20-gauge, curved-tip RF needle with a 10-mm active tip is then inserted at an entry point 2 mm below the junction of the TP and the SAP. Using a gun bar-

rel approach, the bevel is rotated with small succinct movements with the endpoint of the needle at the superior margin of the TP at the junction of the SAP of the facet. The skin entry point of the second needle is 6 mm cephalad to the initial needle along the lateral border of the SAP and should be approximately at the rostrocaudal midpoint of the border of the SAP. The RF needle hub can be used to approximate the second needle placement as it measures 5 mm in diameter. Again, using a gun barrel technique, the lateral border of the SAP is contacted. At this point the oblique angle of the fluoroscopic unit is increased to approximately 35° to optimize the view of the "face" of the SAP and the ventral border of the SAP. Utilizing the hub of the curved-tip cannula, the bevel is rotated away from the SAP, advanced, and rotated back to contact the SAP with the endpoint of the needle being slightly dorsal to its ventral border. The caudad needle will likely need to be maneuvered slightly rostrally to lie in the groove of the neck of the SAP. If the appropriate oblique angle on skin entry is not taken, it may not be possible to rotate the bevel back onto the SAP. With a firm endpoint of the needle dorsal to the ventral border of the SAP, the risk of nerve root injury is minimal (Fig. 3).

To establish the required view for the needle entry point at the L4 vertebral level, for the L3 medial branch nerve, the fluoroscopy unit will typically require a 5° cephalad tilt in combination with a 10° oblique rotation to the ipsilateral side. Given the difference in cephalocaudal tilt at the L2-3 and L3-4 levels, these levels are typically performed individually. The L2 medial branch nerve at the L3 vertebral level requires approximately

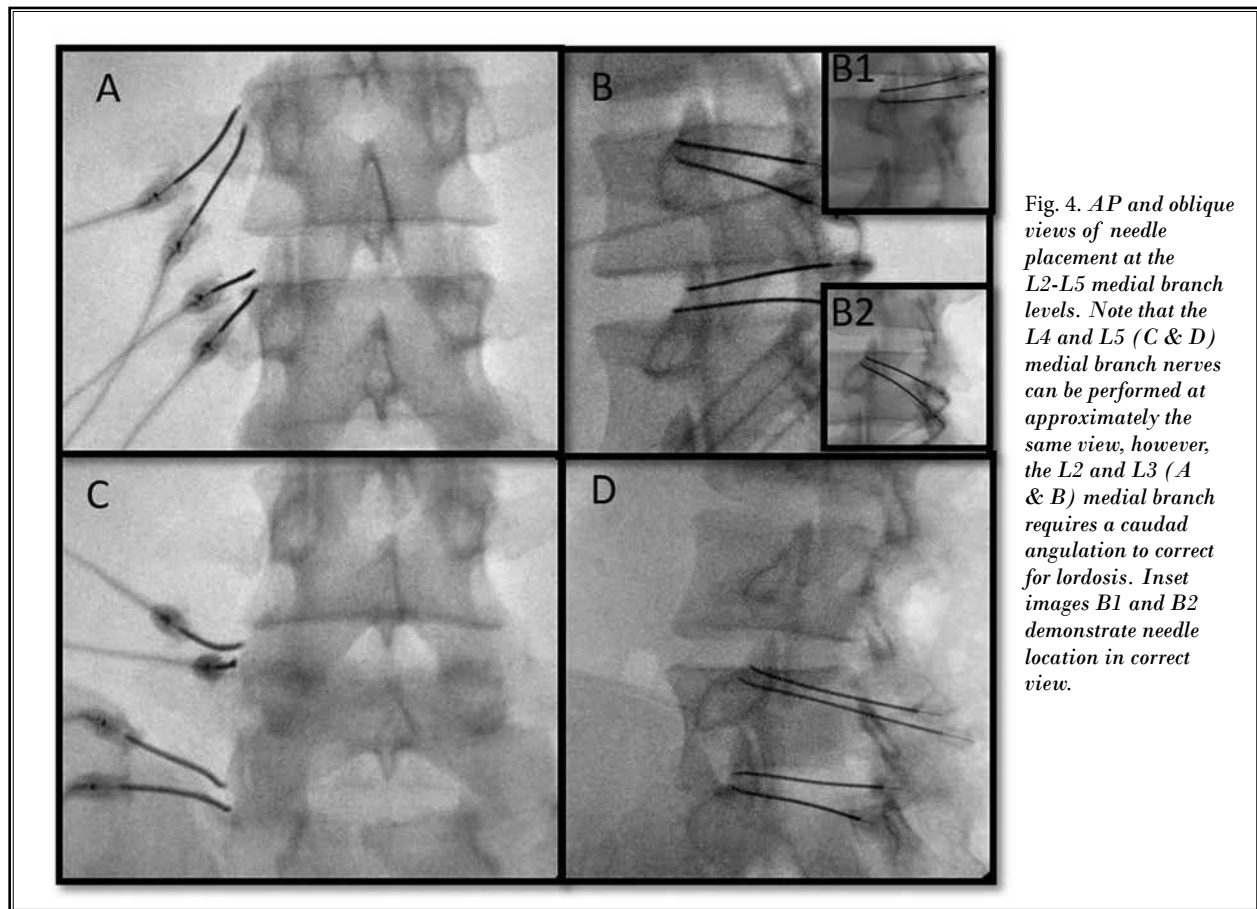


Fig. 4. AP and oblique views of needle placement at the L2-L5 medial branch levels. Note that the L4 and L5 (C & D) medial branch nerves can be performed at approximately the same view, however, the L2 and L3 (A & B) medial branch requires a caudad angulation to correct for lordosis. Inset images B1 and B2 demonstrate needle location in correct view.

a 0° to 5° cephalad tilt and an oblique rotation of between 5° and 10° (33-35).

Using a 4-lesion generator, the 2 facet joint levels can be ablated simultaneously. Once final needle positions are achieved and are confirmed in the anteroposterior (AP), oblique, and lateral fluoroscopic views, motor stimulation is performed at each needle individually at 2 Hz and 1.5 V. The motor stimulation is performed to rule out that an exiting nerve root falls within the electrical field of the RF needles. A motor stimulation pattern suggests improper needle placement in proximity to the segmental spinal nerve. Stimulation of the L2 and occasionally L3 medial branch nerves at the L3 and L4 vertebral levels may result in fasciculation of the multifidus muscle, without motor stimulation in the lower extremities. The medial branch of the dorsal ramus innervates the multifidus attaching to the same spinal level spinous process. Multifidus muscle stimulation does not require needle repositioning; however, close attention must be paid to not overlook motor

stimulation of the segmental nerves. After negative motor testing, each level is then anesthetized with 0.5 mL of 2% lidocaine and lesions are created at 80°C for 90 seconds. After ablation is performed, 0.5 mL of 0.5% bupivacaine and 2.5 mg dexamethasone is injected at each vertebral level. The cannulae are then removed. Final needle positioning can be seen in Fig. 4.

DISCUSSION

Medial branch neurotomy is an effective treatment for patients with a confirmed etiology of facet joint pain (36-38). However, in a subset of patients, ablation provides no relief or only a reduced time-limited alleviation of pain, which has been attributed to incomplete coagulation and early regrowth of the nerves (13-15,39). The aim of this report was to describe a technique to heat a wider volume of tissue to minimize technical failure due to incomplete coagulation. More complete coagulation may ultimately also increase the duration of relief.

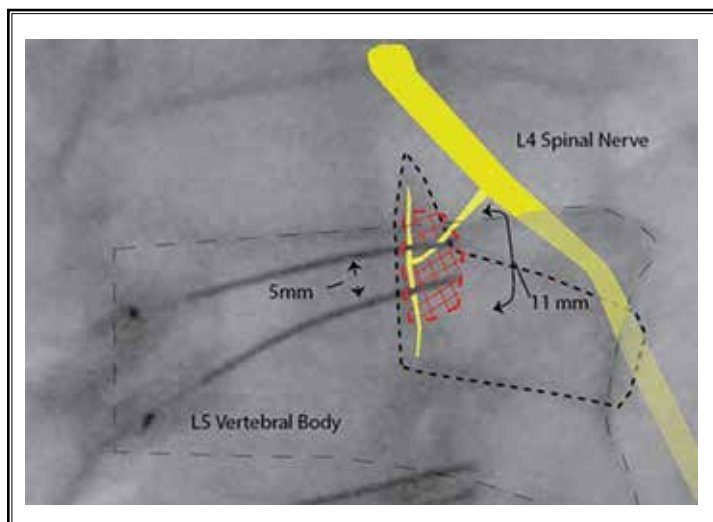


Fig. 5. Needle placement on the SAP of L5 for the L4 medial branch with superimposed nerve and lesion size. Fluoroscopy in the 35° oblique view with needle tips posterior to the anterior border of the SAP creating a 10- x 10-mm lesion against the base of the SAP and TP.

Factors for Ablation Success

There are multiple factors that need to be considered to increase the likelihood of a successful ablation. First, the coagulation caused by the electrical contact is in a radial direction, with a 1-mm lesion distal to the tip of the electrode (16,31,40). Moreover, the coagulation occurs in an ovoid shape parallel to the cannula (Fig. 5), thus placement of the active tip of the needle parallel to the nerve would be the most effective way to cause coagulation of the nerve (40,41). This is the main limitation pertaining to the conventional bullseye or Scotty dog approach when performing RFA. Previous techniques applied coagulation more than once, which enhances the success of the procedure (24,40,42). Lord et al (40) used percutaneous RFA of the medial branches with repeated lesioning in the cervical region resulting in long-lasting pain relief. In their study, small 22-gauge needles were used; a smaller gauge in turn creates a smaller lesion radius necessitating accurate placement close to the nerve (40,43,44). Applying multiple lesions (40) increases the chance that the nerve is ablated and likely increases the length of nerve that is ablated. However, a current trend in practice is to replace repeated application with extending the duration of a single ablation (31,45). Third, the course of the medial branch can be variable and can be affected by osteoarthritis (20,21,25), which makes it uncertain if the coagulation procedure was actually performed in the correct location and caused sufficient coagulation of the medial branch nerve.

Prior Two-Needle Studies

Derby and Lee (39) used two 20-gauge needles with a 10-mm active tip at 80°C for 70 seconds with a separation of 6 mm to assess success of ablation at that distance. In the ex vivo experiment in chicken tissue, the simultaneous heating of 2 monopolar needles resulted in a temperature of 66°C at the midpoint of the 2 needles. With the same needles and configuration, consecutive rather than simultaneous monopolar ablation of tissue around each active tip, however, resulted in heating at the midpoint of the 2 needles not elevated above 40°C, which led the authors to conclude there is an “additive effect” when heat is coming from both directions (39). This evidence underscores that using a single needle repositioning technique may be less effective than a simultaneous 2 needle technique.

In another ex vivo study Cosman et al showed that the use of 2 monopolar needles in the configuration we used results in a tissue lesion that is 11.0-mm wide and 11.6-mm long, considering a single monopolar needle produces a width of 5.3 to 5.5 mm and 11.3 to 11.6 in length (45,46). Because the 6-mm needle separation we employed is measured from the medial aspect of each needle and each needle is 0.91 mm in diameter, a 2.2-mm lesion is created medially from both needles equaling 4.5 mm (Fig. 5). With the additive effect of simultaneous heating as mentioned earlier, the 1.5-mm “gap” that remains with 6-mm needle separation still undergoes significant heating as explained by Derby and Lee (39). This implies that by using 2 cannulas compared with 1, we are able to get a tissue lesion slightly more than double in size needed to coagulate the medial branch (Fig. 6) (41,46). A thorough lesion along the course of the medial branch adjacent to the SAP ensures adequate coverage.

Alternatives to Present Two-Needle Technique

Variations in needle diameter, tip shape, duration of lesioning, temperature, changes in RF mode, (using monopolar vs. bipolar), and cooled RF have been used in hopes of improving outcomes.

Bipolar RFA

We decided to use a two-needle technique with monopolar RF energy. With bipolar RFA, electrical current is passed from one needle to the other, which has the advantage of a contained electrical current. This is an obvious benefit if there are concerns of electrical interference with implantable devices. With the electrical current passing between the 2 active tips, less heat will be generated lateral to the probes resulting in a smaller lesion size laterally when compared with monopolar lesioning, and the length of the lesion size at the midpoint of the cannulas will also be smaller when using the same lesioning parameters (46). Achieving an equivalent lesion size using bipolar RF typically requires an ablation duration of up to 3 minutes or greater. An even longer ablation time is required to compensate for misalignment of the active tips because needle placement is rarely exactly equidistant, and the alignment of the active tips of the cannulas may be off in the vertical and/or horizontal planes (46). The bony structures that are used for positioning are typically uneven in nature, leading to the potential for poor conductance, and thus a smaller, uneven lesion.

Cooled RFA

Cooled RFA electrodes include a thermocouple at the active electrode tip to provide temperature-controlled lesion formation. Water-cooling of the active electrode tip during ablation prevents tissue charring at the electrode tip (the local temperature is usually 60°C for cooled RFA, compared with 80°C to 90°C for conventional/monopolar RFA). Typical cooled RFA cannulas are 18 gauge with a 4-mm active tip. Cooled RF ablative lesion size is

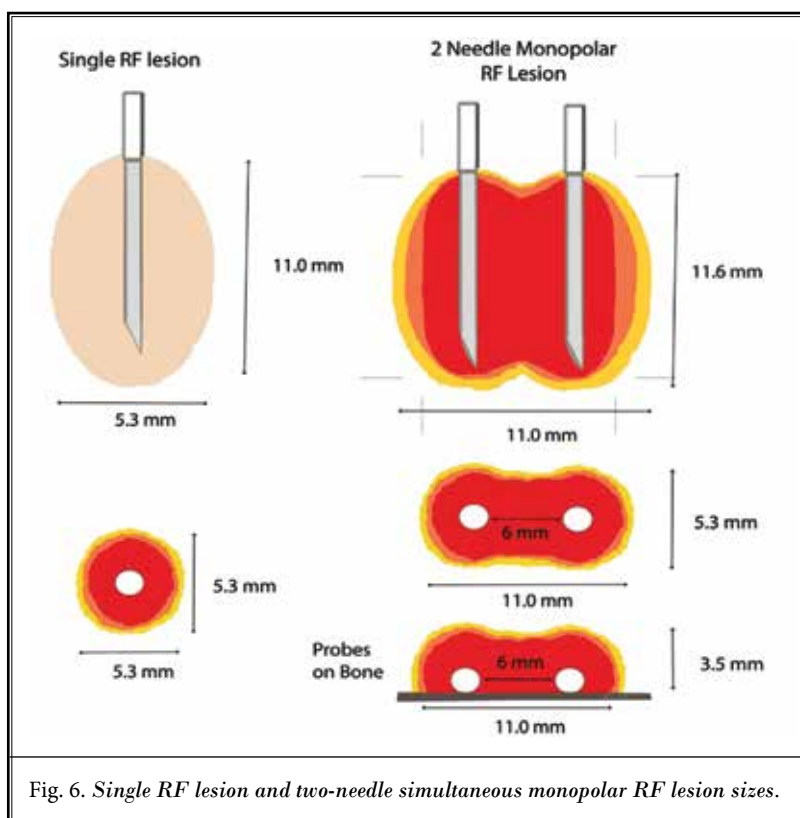


Fig. 6. Single RF lesion and two-needle simultaneous monopolar RF lesion sizes.

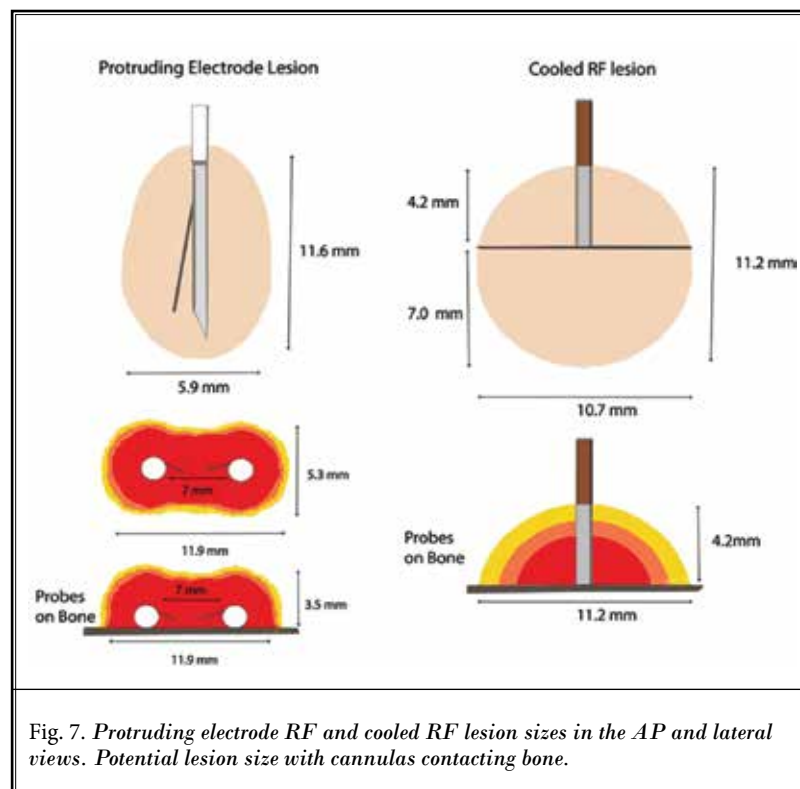


Fig. 7. Protruding electrode RF and cooled RF lesion sizes in the AP and lateral views. Potential lesion size with cannulas contacting bone.

focused anterior to the active tip, with greater than half of the volume of the lesion distal to the active tip. Cooled RFA for lumbar facet joint denervation is typically applied using the Scotty dog, bullseye approach, with the active tip placed against the junction of the TP and the SAP. Because of the large needle size and connected tubing, continued manual pressure is often necessary to maintain position throughout the 150 to 180 second ablation. Considering the 4-mm active tip is held against the bony structure, more than half of the active lesion area is directed into the TP, in turn potentially decreasing the lesion size by half. Thus the diameter of the lesion at the level of the active tip would be expected to be approximately the same dimension as with our two-needle technique, 10 to 11 mm. Compared with the two-needle technique, the coagulation of tissue away from the bone at the maximal radius of the "dome" of ablation is 4.2 mm. Given these dimensions, cooled RF would provide approximately the same width and only a marginal increase at the dome of the ablative field. A summary of these points is presented in Fig. 7.

Protruding Electrode Needle

A protruding electrode needle (Venom; Stryker, Kalamazoo, MI) is an RFA needle in which the electrode forks off from the active tip and creates a V shape whose purpose is to create a larger lesion size. As demonstrated by Cedeño et al (31), using equivalent settings when compared with standard RFA needles, the lesion created by a protruding 20-gauge needle with a 10-mm active tip at 80°C for 90 seconds is 11.6 x 5.9 mm, which provides an additional 0.6 x 0.6 mm lesion size when compared with standard RFA needles. A more significant lesion size of 6.3 mm with the 20-gauge protruding needle was demonstrated at 150-second lesion time (31). A technical limitation is that to get the maximum lesion generated at the target location, the protruding electrode needs to be placed in the correct plane horizontal to the bone.

Pharmaceutical "Excipients" for RFA

The most common side effect of RFA of the medial branch is transient neuritis (47). Local dexamethasone injection after RFA has been investigated in a retrospective study for its potential to prevent neuritis with inconclusive findings (48). A large ongoing randomized clinical trial is aiming to address the question if dexamethasone administration is helpful in preventing neuritis (49). In the absence of conclusive evidence on

its efficacy, concerns of low bone density and risk of vertebral fractures associated with repeated steroid injections would seem to argue against consistently administering local dexamethasone after medial branch RFA (50).

Additionally, recent works have demonstrated the possible benefit of 8% hypertonic saline (51), however, given the lack of definitive data on clinical efficacy and safety at this time, it is beyond the scope of the present discussion.

Limitations of Two-Needle Technique

A limitation of the described two-needle technique is the time for the operator to place the needles accurately. Other limitations are similar to that of a conventional one-needle technique. As with any approach to RF medial branch denervation, the proximity to the spinal cord and the exiting nerve roots makes technical precision imperative. As described by Gupta et al (52), bifurcation of the dorsal ramus in the medial and lateral branch occurs at a 3-mm distance of the ventral border of the TP. The dorsal ramus travels with its blood vessel and it is important that the RF heat not approach this bifurcation point or the dorsal ramus because it may cause bleeding or damage to the dorsal ramus or even ventral root, which is positioned approximately 1 cm from of the dorsal ramus (21). Improper needle placement may lead to permanent lower extremity weakness, persistent neuritis, including the genitofemoral nerve, and potentially permanent sensory deficit. Although the presented technique increases lesion size, these complications may be avoided if the aforementioned description is followed. Sensory testing can be used to confirm proximity to the medial branch nerve (53) and has also been (unsuccessfully) explored as a predictor of medial branch RFA efficacy (54). Sensory testing can be added to the described technique dependent on the physician's comfort level with the anatomy involved. However, considering the lesion size of the described technique in this report and the lack of demonstrated benefit of sensory testing, we chose not to perform sensory testing. Additionally, foregoing sensory testing may improve patient comfort and reduce procedural time.

CONCLUSIONS

We detailed a two-needle approach to lumbar RF medial branch denervation that appears to be promising in terms of projected treatment success by coagulating a large volume of tissue, in a cost- and time-efficient

manner. Future studies need to clarify whether this approach can increase treatment success rate and duration of relief from facet joint pain.

Author Contributions

KBC managed the literature searches and sum-

maries of previous related work, created illustrations, and wrote the first draft of the manuscript. FS, TO, PSG, RRR, and NVH provided revision for intellectual content and final approval of the manuscript.

REFERENCES

- McNeil JM, Binette J. Prevalence of disabilities and associated health conditions among adults-United States, 1999. *JAMA* 2001; 285:1571-1572.
- Stewart WF, Ricci JA, Chee E, Morganstein D, Lipton R. Lost productive time and cost due to common pain conditions in the US workforce. *JAMA* 2003; 290:2443-2454.
- Ricci JA, Stewart WF, Chee E, Leotta C, Foley K, Hochberg MC. Back pain exacerbations and lost productive time costs in United States workers. *Spine (Phila Pa 1976)* 2006; 31:3052-3060.
- Katz J. Lumbar disc disorders and low-back pain: Socioeconomic factors and consequences. *J Bone Jt Surg Am* 2006; 88(suppl 2):21-24.
- Manusov E. Evaluation and diagnosis of low back pain. *Prim Care* 2012; 39:471-479.
- Bogduk N. Low back pain. In: *Clinical and Radiological Anatomy of the Lumbar Spine*. 5th ed. London, Elsevier, 2012: pp. 183-216.
- Schwarzer A, Aprill C, Derby R, Fortin J, Kine G, Bogduk N. The relative contributions of the disc and zygapophyseal joint in chronic low back pain. *Spine (Phila Pa 1976)* 1994; 19:801-806.
- Dreyer SJ, Dreyfuss PH. Low back pain and the zygapophysial (facet) joints. *Arch Phys Med Rehabil* 1996; 77:290-300.
- van Kleef M, Vanelderden P, Cohen SP, Lataster A, Van Zundert J, Mekhail N. Pain originating from the lumbar facet joints. *Pain Pract* 2010; 10:459-469.
- Andersson GB, Lucente T, Davis AM, Kappler RE, Lipton JA, Leurgans S. A comparison of osteopathic spinal manipulation with standard care for patients with low back pain. *New Engl J Med* 1999; 341:1426-1431.
- Schnitzer TJ, Ferraro A, Hunsche E, Kong SX. A comprehensive review of clinical trials on the efficacy and safety of drugs for the treatment of low back pain. *J Pain Symptom Manage* 2004; 28:72-95.
- Cohen SP, Huang JH, Brummett C. Facet joint pain-Advances in patient selection and treatment. *Nat Rev Rheumatol* 2013; 9:101-116.
- Schofferman J, Kine G. Effectiveness of repeated radiofrequency neurotomy for lumbar facet pain. 2004; 29:2471-2473.
- McDonald GJ, Lord SM, Bogduk N. Long-term follow-up of patients treated with cervical radiofrequency neurotomy for chronic neck pain. *Neurosurgery* 1999; 45:61-67; discussion 7-8.
- Heavner JE, Boswell MV, Racz GB. A comparison of pulsed radiofrequency and continuous radiofrequency on thermocoagulation of egg white in vitro. *Pain Physician* 2006; 9:135-137.
- Lee CH, Derby R, Choi HS, Lee SH, Kim SH, Kang YK. The efficacy of two electrodes radiofrequency technique: Comparison study using a cadaveric interspinous ligament and temperature measurement using egg white. *Pain Physician* 2010; 13:43-49.
- Jaumard N, Welch W, Winkelstein B. Spinal facet joint biomechanics and mechanotransduction in normal, injury and degenerative conditions. *J Biomech Eng* 2011; 133:071010.
- Giles L, Taylor J. Human zygapophyseal joint capsule and synovial fold innervation. *Br J Rheumatol* 1987; 26:93-98.
- Ashton IK, Ashton BA, Gibson SJ, Polak JM, Jaffray DC, Eisenstein SM. Morphological basis for back pain: The demonstration of nerve fibers and neuropeptides in the lumbar facet joint capsule but not in ligamentum flavum. *J Orthop Res* 1992; 10:72-78.
- Jacobson RE, Palea O, Granville M. Bipolar radiofrequency facet ablation of the lumbar facet capsule: An adjunct to conventional radiofrequency ablation for pain management. *Cureus* 2017; 9:e1635.
- Shuang F, Hou SX, Zhu JL, et al. Clinical anatomy and measurement of the medial branch of the spinal dorsal ramus. *Medicine (Baltimore)* 2015; 94:e2367.
- Damasceno LHF, Catarin SR, Campos GAD, Delfino HLA. Lumbar lordosis: A study of angle values and of vertebral bodies and intervertebral discs role. *Acta Ortop Bras* 2006; 14:193-198.
- Satoskar SR, Goel AA, Mehta PH, Goel A. Quantitative morphometric analysis of the lumbar vertebral facets and evaluation of feasibility of lumbar spinal nerve root and spinal canal decompression using the Goel intraarticular facet spacer distraction technique: A lumbar/cervical facet comparis. *J Craniovertebr Junction Spine* 2014; 5:157-162.
- Lau P, Mercer S, Govind J, Bogduk N. The surgical anatomy of lumbar medial branch neurotomy (facet denervation). *Pain Med* 2004; 5:289-298.
- Bogduk N, Long DM. The anatomy of the so-called "articular nerves" and their relationship to facet denervation in the treatment of low-back pain. *J Neurosurg* 1979; 51:172-177.
- Kozera K, Ciszek B. Posterior branches of lumbar spinal nerves-Part I: Anatomy and functional importance. *Ortop Traumatol Rehabil* 2016; 18:1-10.
- Demondion X, Vidal C, Glaude E, Subocz L, Francke JP, Cotten A. The posterior lumbar ramus: CT-anatomic correlation and propositions of new sites of infiltration. *AJNR Am J Neuroradiol* 2005; 26:706-710.
- Bogduk N, Dreyfuss P, Govind J. A narrative review of lumbar medial branch neurotomy for the treatment of back pain. *Pain Med* 2009; 10:1035-1045.
- International Spine Intervention Society. *Practice Guidelines for Spinal Diagnostic and Treatment Procedures*. 2nd ed. San Rafael (CA), International Spine

- Intervention Society, 2013.
30. Gofeld M, Faclier G. Radiofrequency denervation of the lumbar zygapophysial joints—Targeting the best practice. *Pain Med* 2008; 9:204-211.
 31. Cedeño DL, Vallejo A, Kelley CA, Tilley DM, Kumar N. Comparisons of lesion volumes and shapes produced by a radiofrequency system with a cooled, a protruding, or a monopolar probe. *Pain Physician* 2017; 20:E915-E922.
 32. Loh JT, Nicol AL, Elashoff D, Ferrante FM. Efficacy of needle-placement technique in radiofrequency ablation for treatment of lumbar facet arthropathy. *J Pain Res* 2015; 8:687-694.
 33. Evcik D, Yücel A. Lumbar lordosis in acute and chronic low back pain patients. *Rheumatol Int* 2003; 23:163-165.
 34. Abitbol MM. Evolution of the lumbosacral angle. *Am J Phys Anthropol* 1987; 72:361-372.
 35. Jha AK, Ravi C. A study of normal variation in lumbosacral angle in asymptomatic patients attending orthopaedic out-patient department of a medical college hospital, Telangana. *Indian J Orthop Surg* 2018; 4:16-20.
 36. Dreyfuss P, Schwarzer AC, Lau P, Bogduk N. Specificity of lumbar medial branch and L5 dorsal ramus blocks: A computed tomography study. *Spine (Phila Pa 1976)* 1997; 22:895-902.
 37. Kaplan M, Dreyfuss P, Halbrook B, Bogduk N. The ability of lumbar medial branch blocks to anesthetize the zygapophysial joint: A physiologic challenge. *Spine (Phila Pa 1976)* 1998; 23:1847-1852.
 38. Dreyfuss PH, Dreyer SJ; NASS. Lumbar zygapophysial (facet) joint injections. *Spine J* 2003; 3(3 suppl):50S-59S.
 39. Derby R, Lee CH. The efficacy of a two needle electrode technique in percutaneous radiofrequency rhizotomy: An investigational laboratory study in an animal model. *Pain Physician* 2006; 9:207-214.
 40. Lord S, Barnsley L, Wallis B, McDonald G, Bogduk N. Percutaneous radiofrequency neurotomy for chronic cervical zygapophyseal-joint pain. *N Engl J Med* 1996; 335:1721-1726.
 41. Bogduk N, Macintosh J, Marsland A. Technical limitations to the efficacy of radiofrequency neurotomy for spinal pain. *Neurosurgery* 1987; 20:529-535.
 42. Govind J, King W, Bailey B, Bogduk N. Radiofrequency neurotomy for the treatment of third occipital headache. *J Neurol Neurosurg Psychiatry* 2003; 74:88-93.
 43. Nath S, Nath C, Pettersson K. Percutaneous lumbar zygapophysial (facet) joint neurotomy using radiofrequency current, in the management of chronic low back pain: A randomized double-blind trial. *Spine (Phila Pa 1976)* 2008; 33:1291-1297; discussion 8.
 44. Manchikanti L, Derby R, Wolfer L, Singh V, Datta S, Hirsch JA. Evidence-based medicine, systematic reviews, and guidelines in interventional pain management: Part 7: Systematic reviews and meta-analyses of diagnostic accuracy studies. *Pain Physician* 2009; 12:929-963.
 45. Cosman ER, Dolensky JR, Hoffman RA. Factors that affect radiofrequency heat lesion size. *Pain Med* 2014; 15:2020-2036.
 46. Cosman ER, Gonzalez CD. Bipolar radiofrequency lesion geometry: Implications for palisade treatment of sacroiliac joint pain. *Pain Pract* 2011; 11:3-22.
 47. Kornick C, Kramarich SS, Lamer TJ, Todd Sitzman B. Complications of lumbar facet radiofrequency denervation. *Spine (Phila Pa 1976)* 2004; 29:1352-1354.
 48. Singh JR, Miccio VFJ, Modi DJ, Sein MT. The impact of local steroid administration on the incidence of neuritis following lumbar facet radiofrequency neurotomy. *Pain Physician* 2019; 22:69-74.
 49. Chhatre A. Post-lesion administration of dexamethasone to prevent the development of neuritis after radiofrequency ablation - NCT03247413 [Internet]. *Clinicaltrials.gov* 2017 [cited 2020 Nov 2]. Available from: <https://clinicaltrials.gov/ct2/show/NCT03247413>. Accessed 11-31-2019.
 50. Kerezoudis P, Rinaldo L, Alvi MA, et al. The effect of epidural steroid injections on bone mineral density and vertebral fracture risk: A systematic review and critical appraisal of current literature. *Pain Med* 2018; 19:569-579.
 51. Provenzano DA, Cosman ER, Wilsey JT. Hypertonic sodium chloride preinjectate increases in vivo radiofrequency ablation size: Histological and magnetic resonance imaging findings. *Reg Anesth Pain Med* 2018; 43:776-788.
 52. Gupta R, Singla R, Agnihotri G, Kumari R, Goyal D. Morphometric and morphological study of articular facets of the thoracolumbar vertebral column in North-Indian population. *Int J Anat Res* 2015; 3:1354-1361.
 53. McCormick ZL, Marshall B, Walker J, McCarthy R, Walega DR. Long-term function, pain and medication use outcomes of radiofrequency ablation for lumbar facet syndrome. *Int J Anesth Anesth* 2015; 2:028.
 54. Cohen SP, Strassels SA, Kurihara C, et al. Does sensory stimulation threshold affect lumbar facet radiofrequency denervation outcomes? A prospective clinical correlational study. *Anesth Analg* 2011; 113:1233-1241.