

## Prospective Evaluation


**Evaluation of Sensory Mapping of Erector Spinae Plane Block**

Andrés Barrios, MD<sup>1,2</sup>, Julio Camelo, MD<sup>1,2</sup>, Jorge Gómez, MD<sup>2</sup>, Mauricio Forero, MD<sup>3</sup>, Philip W.H. Peng MBBS, FRCPC<sup>4</sup>, Kevin Visbal, MD<sup>5</sup>, and Adriana Cadavid, MD<sup>1,2</sup>

From: <sup>1</sup>Pain Medicine Unit Hospital Universitario San Vicente Fundación, Medellín, Colombia; <sup>2</sup>Department of Anesthesia-Pain Medicine Fellowship Program, University of Antioquia, Medellín, Colombia; <sup>3</sup>Department of Anesthesia, McMaster University, Hamilton, Ontario, Canada; <sup>4</sup>Department of Anesthesia, Toronto Western Hospital; and University Health Network, University of Toronto, Toronto, Ontario, Canada; <sup>5</sup>Department of Anesthesiology, resident of anesthesiology, University of Antioquia, Medellín, Colombia

Address Correspondence:  
Adriana Cadavid, MD  
Department of Anesthesia,  
University of Antioquia, Cl. 64 #154,  
Medellín, Antioquia, Colombia  
E-mail:  
adriana.cadavid@udea.edu.co

Disclaimer: This study was funded by the Anesthesia Department Funds, University of Antioquia, Medellín, Colombia.

Conflict of interest: Each author certifies that he or she, or a member of his or her immediate family, has no commercial association (i.e., consultancies, stock ownership, equity interest, patent/licensing arrangements, etc.) that might pose a conflict of interest in connection with the submitted manuscript.

Manuscript received:  
09-01-2019  
Accepted for publication:  
10-28-2019

Free full manuscript:  
www.painphysicianjournal.com

**Background:** Erector spinae plane (ESP) block is an effective regional analgesic technique for thoracic and abdominal pain. The volume of local anesthetic (LA) needed to produce sensory block in the spinal segment is unknown.

**Objectives:** The aim of the present study was to examine the extent of dermatomal spread following ultrasound-guided administration of ESP block, with a fixed-volume dose of a LA at the midthoracic area for analgesia in acute thoracic pain patients. Secondary objectives were postprocedure analgesia and patient satisfaction.

**Study Design:** This research used a prospective unicentric exploratory cohort design.

**Setting:** The study was conducted at an academic university hospital.

**Methods:** A total of 18 patients with acute severe chest pain including rib fractures, thoracic postoperative rescue analgesia, zoster herpetic neuritis, and myofascial pain syndrome received ESP block under ultrasound guidance at the T5-T7 levels. Twenty mL of 0.5% plain bupivacaine was injected. Evaluation of the sensory block was carried out 60 minutes following the completion of the ESP block via a change in sensation to pinprick and cold methods. The Visual Analog Scale (VAS) for pain was recorded one hour after the procedure. Patient satisfaction was reported using a 4-point Likert scale. This study was registered with the clinicaltrials.gov database (identifier: NCT03831581).

**Results:** Sixteen patients had a successful ESP block; 2 patients were excluded for a failed block. The mean dermatomal spread was 9 (range, 8-11). VAS scores improved by at least 50% from baseline ( $P < .05$ ), one hour after the ESP block. The degree of satisfaction reported by all patients on the Likert scale was 4 points. No major complications were observed.

**Limitations:** This study was limited by its sample size.

**Conclusions:** An ultrasound-guided ESP block with a single injection at the midthoracic level with 20 mL of 0.5% plain bupivacaine provides a mean dermatomal spread of 9 dermatomes (range, 8-11) with a high rate of analgesic efficacy and low incidence of adverse effects.

**Key words:** Acute pain, dermatomal spread, erector spine plane nerve block, thoracic pain, thoracic postoperative analgesia

**Pain Physician 2020; 23:E289-E295**

**T**he erector spinae plane (ESP) block was first described in 2016 by Forero et al as an interfascial block for the treatment of chest pain (1). Following its initial publication, the ESP block has been performed in patients with acute postoperative pain, chronic pain, and moreover, as a rescue technique

for managing severe, uncontrolled pain, especially in the thoracic and abdominal cavity (2-4). The ESP block allows the insertion of a catheter for the continuous administration of the local anesthetic (LA) to prolong the analgesic effect (5).

The original description of the ESP block technique

involves obtaining a view of the tip of the transverse process with a parasagittal view on ultrasound. The needle is then inserted in-plane, in a cranial-to-caudal direction, into the interfascial plane between the erector spinae muscle and the tip of the transverse process (1).

Cadaveric studies examining the spread of the LA with methylene blue and computed tomography showed its distribution along the interfascial plane, preferentially in the caudal direction (1). Other imaging studies showed distribution in both the cephalic and caudal directions (6). It is believed that the extent of spread of the LA in live patients may be greater than that reported in cadaveric models. A recent review found that sensory block was objectively evaluated only in 34.7% of reported patients receiving ESP block (7). Because of the heterogeneity in the technique and volume of anesthetic administered, the extent of the spread is unclear in published studies.

Understanding the pattern and extent of injectate spread, clinically, in terms of sensory blockade, is important for safe clinical practice. The objective of this study was to examine the extent of dermatomal blockade following a standardized, ultrasound-guided injection of ESP block, a fixed-volume dose (20 mL of 0.5% plain bupivacaine), injected in the midthoracic area.

## METHODS

Eighteen patients who received ESP block from April 2018 to November 2018 at the Hospital San Vicente Fundación in Medellín, Colombia were included in this prospective exploratory study. The study protocol was approved by the institutional medical ethics committee. Informed consent was obtained from all patients.

### Study Population

The patients included in the study were older than 18 years of age, presenting with thoracic pain due to various etiologies (acute multiple rib fractures, thoracic herpetic neuritis, rescue of postoperative chest pain, and myofascial syndrome) and with clinical indication for an ESP block as part of a multimodal analgesic strategy. Exclusion criteria were infection at the puncture site, sepsis, hemodynamic instability, refusal of the procedure, or pregnancy.

### ESP Block Technique

Prior to the procedure, the patients completed a Visual Analog Scale (VAS) for the assessment of pain (scores ranging between 0-10) and their demographic

data was collected. The ESP block was performed by 2 anesthesiologists with expertise in regional anesthesia from the pain service of the Hospital San Vicente Fundación in Medellín, Colombia. The patient received standard monitoring (pulse oximetry, blood pressure, electrocardiogram) and intravenous access. Sedation was achieved with a titrated dose of fentanyl and midazolam to keep the patient comfortable.

The block was performed based on the original description by Forero et al (1). The patient was positioned in either sitting or lateral decubitus position. Maintaining strict sterility, a high-frequency linear transducer (Philips CX30 ultrasound system, Netherlands) was placed in the parasagittal plane to identify the transverse process of the midthoracic spine (T5-T7) based on the dermatome of the area experiencing pain. Following infiltration of 3 mL of 2% lidocaine into the skin, an 18-gauge (G) Tuohy needle was inserted in-plane from the cranial-to-caudal direction until it reached the tip of the transverse process, deep inside the erector muscles. After hydrolocation to confirm the spread of the injectate in the interfascial plane, 20 mL of 0.5% bupivacaine was injected.

### Assessment

Dermatomal spread was assessed with pinprick and cold methods, using the sharp end of a wooden stick and ice cubes, respectively, by an independent observer over different dermatomes along the midclavicular line, 60 minutes after the administration of the ESP block. The contralateral side was also evaluated for sensory changes. A successful blockade was defined as a decrease in sensation to both temperature and touch. On the contrary, a failed block was defined as the absence of demonstrable sensory block 20 minutes after the procedure was performed. The VAS score was recorded at 60 minutes after the block. The degree of satisfaction of the patients was measured with a 4-point Likert scale (1, dissatisfied; 2, slightly dissatisfied; 3, slightly satisfied; 4, satisfied). Possible adverse events associated with the ESP block (hypotension, pneumothorax, neurological deficit, and bradycardia) were recorded.

### Statistical Analyses

The variables were summarized as means (standard deviations) for continuous variables and frequencies (percentages) for categorical variables. Results are reported in tables and charts. Normality of the variables was assessed by the Shapiro-Wilk test and homogeneity of the variables (homoscedasticity) was assessed using

the Levene test. The mean is reported with its respective standard deviation and the median with its respective interquartile interval (quartile 3 [Q3] minus quartile 1 [Q1]). In addition, as an exploratory objective, a nonparametric repeated measures analysis of variance was performed at baseline VAS and at 60 minutes post blockade. All data were collected in Microsoft Excel® and analyzed with SPSS Version 24 (IBM Corporation, Armonk, NY). The type I error (alpha) was 5% for all tests, and therefore,  $P < .05$  was considered statistically significant.

## RESULTS

Eighteen patients received an ESP block. Two patients were excluded from the analysis of dermatome spread due to absence of pain relief and sensory blockade and required rescue analgesia with another technique (epidural). Sixteen cases were included in the analysis for dermatomal spread (Table 1): 10 women (62.5%) and 6 men (37.5%).

The mean age was  $47 \pm 12$  years, and the diagnoses included anterior, lateral, and/or posterior rib fractures

Table 1. Demographic variables.

Variables	Value (%)
Women	10 (62.5)
Men	6 (37.5)
Age, mean (SD), yrs	47 (12)
Height, mean (SD), cm	164 (9)
Weight, mean (SD), kg	64.5 (11.2)
Median baseline VAS score	8

Abbreviations: SD, Standard Deviation; VAS, Visual Analog Scale

(50%); herpetic neuritis in the entire extension of the right T6 dermatome (6.25%); thoracic myofascial syndrome (31.25%); postoperative flap of the pectoral muscle (6.25%); and thoracostomy (6.25%) (Tables 1 and 2).

The mean dermatomal spread was 9.0 (range, 8-11), within the 25th percentile of 8.25 and 75th percentile of 10 (Table 2). None of the patients had a bilateral sensory block. Exploratory data examining the range in volume of LA required to block one dermatome showed a range of 1.81 to 2.5 mL (mean, 2.2 mL).

Table 2. Number of blocked dermatomes measured with pinprick and cold temperature.

Diagnosis	Puncture Level	Decrease in Sensitivity at the Midclavicular Line	# Blocked Dermatomes
Multiple rib fractures (posterior fractures of the 3rd, 6th, 7th, 8th and 9th; laterals of the 2nd, 4th and 5th costal arch)	T5	T2-T10	9
Multiple rib fractures (posterolateral fractures of the 3rd to 8th costal arch)	T5	T1-T10	10
Thoracic herpetic neuritis	T6	T2-T11	10
Postoperative thoracostomy pain	T5	C8-T10	11
Postoperative flap of pectoral muscle pain	T5	T1-T8	8
Multiple rib fractures (anterior fractures of the 4th to 5th costal arch) and scapula	T5	T1-T8	8
Multiple rib fractures (lateral fractures of the 7th to 9th costal arch) – vertebral fractures	T5	T2-T10	9
Multiple rib fractures (lateral fractures of the 7th to 9th costal arch) – vertebral fractures	T5	T2-T10	9
Myofascial syndrome	T5	T1-T11	11
Myofascial syndrome	T5	C8-T7	8
Multiple rib fractures (anterior costochondral fractures of 3°, anterior costochondral and lateral fractures of 4° and 5°, lateral of 7° and posterior of 10° costal arch)	T5	T1-T9	9
Multiple rib fractures (anterior fractures from 1st to 9th and posterior from 6th to 8th) and spinous processes from T5 to T8	T7	T1-T10	10
Myofascial syndrome	T5	T1-T9	9
Myofascial syndrome	T5	T1-T8	8
Multiple rib fractures (posterolateral fractures of the 3rd, anterolateral and posterolateral of the 4th, posterolateral and anterior of the 5th, posterolateral of the 6th and 7th costal arch) and scapula	T5	T1-T9	9
Myofascial syndrome	T5	C8-T8	9

We observed a mean of 4 dermatomes (range, 3-6) in the cranial direction and 6 dermatomes (range, 2-6) in the caudal direction (Fig. 1).

In 16 patients, the blockade was performed at the T5 level, and at the T6 and T7 levels in one patient each, corresponding to the level of the referred pain area. In the 16 cases of successful ESP blocking, the VAS score improved by at least 50% from baseline ( $P < .05$ ) one hour after the ESP block (Fig. 2). Our success rate was 88%. The degree of satisfaction reported by all patients on the Likert scale was 4 points. No major complications were noted.

## DISCUSSION

This study shows that the ESP block produces an extensive somatic block, with a mean number of dermatomal involvements of 9 (range, 8-11) after a single injection of 20 mL of 0.5% bupivacaine.

This finding is similar to some previous case reports published on ESP block, in which dermatomal spread was reported after injection of a fixed 20 mL of bupivacaine (1,8,9).

ESP block is an evolving technique because the actual pattern of distribution of LA is still under investigation. We are not aware of any previous study evaluating the extent of dermatomal spread of the ESP block in a prospective manner, when using a fixed-volume dose of LA. In this exploratory study, important variables were controlled in all 18 cases, such as constant concentration, volume of the LA injected, level of puncture, experience of the anesthesiologist, and direction of needle bevel.

To assess the dispersion of the LA and understand its mechanism of action, studies on anatomical dissections and cadaveric tomographic images have been carried out, including imaging the dispersion of the LA

in live humans (10-13). The analgesic mechanism proposed for the ESP block is the axonal block of the dorsal and ventral branches of the spinal thoracic roots and the sympathetic nerve fibers by diffusion of the LA to the paravertebral space in the dermatomes corresponding to the site of pain (1,14,15). Anatomical studies have shown foraminal and epidural dispersion (1,16), occasionally reaching the epidural contralateral space from the injection site (17). In other studies, the injectate does not manage to enter the paravertebral space, although it reaches the ventral branch (12). Other investigations have reported preferable spread to the dorsal branch (1).

Our study included several cases in which the pain was mediated by the anterior branch of the spinal nerve, such as the 8 cases of anterior rib fractures and one case of acute thoracic herpetic neuritis with anterior involvement of the chest (Table 2). We observed a large anterior decrease in pain and satisfactory analgesia in this group of patients, confirming that the LA had spread to the anterior branches of the ventral rami when performing a midthoracic ESP block. The blockade of the anterior branch of the spinal nerve observed in our study may be the result of the relatively high dose of anesthetic (0.5% bupivacaine) injected. In a previous case report by Elkondi et al, a 15-mL fixed bolus of bupivacaine 0.5% was administered with an ESP block with a relative volume/dermatomal spread comparable to that of our results (18).

There are more conventional techniques such as epidural or paravertebral blocks (PVB) used in thoracic analgesia, where a dermatomal distribution of the sensory block has been studied, finding different

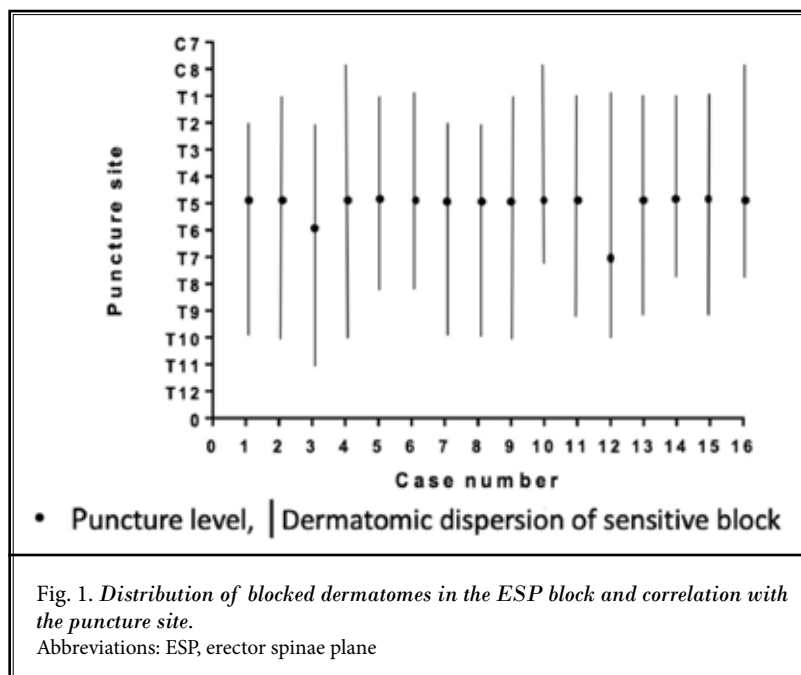


Fig. 1. Distribution of blocked dermatomes in the ESP block and correlation with the puncture site.

Abbreviations: ESP, erector spinae plane

patterns of dispersion and the number of dermatomes with sensitive alteration (19,20). Regarding ultrasound-guided PVB in several studies with volunteers and patients, a volume of 20 mL of LA was administered at anesthetic concentrations, with observations of objective sensory block by pinprick and/or cold assessed from 4 to 6 dermatomes, with an average of 5 dermatomes. However, Marhofer et al described a more extensive dermatomal spread for PVB in volunteers with 20 mL of 1% mepivacaine at the T6 level, with a median number of 9.8 dermatomes affected, a value comparable to our ESP study results (21). This variable dermatomal involvement described may also be the result of dose, i.e., concentration and type of LA injected. We found in our ESP study a slight downward trend to dispersion, probably associated with the cranial-to-caudal direction of the needle within an interfascial plane.

Previously published cases of objective measurement of sensory blockade after ESP block with pinprick and/or cold show variable results with respect to the volume necessary to block each dermatome (range of 1.66-6 mL) (Appendix 1). In our study, an exploratory analysis of data examining the volume of LA required per dermatome was in the range of 1.81-2.5 mL (mean 2.2 mL). Cassai et al (8) posed the same question and, following a review of different studies, found that 3.4 mL (range, 2.5-6.6 mL) of the anesthetic was required to block a dermatome. Our exploratory calculation of volume needed per dermatome is lower than that reported by this author and may be explained by the higher concentration used in our study, 0.5% bupivacaine compared with the one described in the previous case series, i.e., 0.35% or lower. However, in the Cassai et al (8) study, a volume/dermatome relation was suspected (or thought) to be a result of grouping case reports with methodological differences and dosing of LA, whereas the variables with the potential for modifying the anatomical dispersion of the blockade were not prospectively controlled.

Since its first description in 2016 by Forero et al (1), the ESP block has been used as an interfascial plane block and sufficient clinical efficacy has been reported for performing a neural block at any spinal level, resembling the neuroaxial block techniques (2,3,5,6). If we consider the increasing effectiveness of the ESP block reported in severe postoperative pain models (Appendix 1), we believe that future application of the ESP block can decrease the incidence of adverse effects related to alternatives such as the thoracic epidural (motor block [13.4%], dura mater puncture [1.2%],

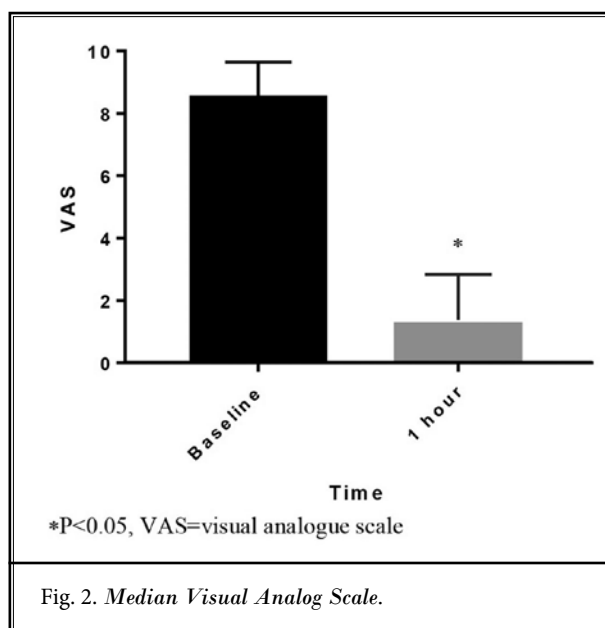


Fig. 2. Median Visual Analog Scale.

epidural hematoma [0.02%], postpuncture headache [0.14%], and postoperative neurological deficit [1.2%]) (22). The ESP block may be associated with a lower risk of major complications, since it is performed in an interfascial plane, easily identifiable on the bony surface and far from neurovascular structures and having the advantage of not having to invade the neuraxis. Another important aspect highlighting the relative safety of the technique is that in 2 of our cases, the ESP block was performed in patients on anticoagulants.

There are limitations to the present study. Small sample size may be a consideration; however, for this initial exploratory study, we have found comparable research for PVB describing dermatomal spread in 10 healthy volunteers with similar findings (21). The study design does not allow the evaluation of the dose-effect relationship of the LA in order to assess the analgesic or the anesthetic result of the ESP block at different concentrations. Other factors can theoretically modify the dispersion of the LA during an ESP block such as the position of the patient, injection speed, consistency of the muscle, ligament tissues, needle gauge, viscosity of the mixture, and ventilatory pattern, which could be evaluated in future investigations. No clinical-imaging correlation was performed.

In our study, there were no major complications related to the procedure. However, this initial exploratory cohort study is limited in terms of safety, for example pneumothorax frequency, due to a small sample size.

This investigation is of clinical significance for patients with indication for ESP block, since it provides important information on dose and analgesic efficacy in different scenarios of severe chest pain.

## CONCLUSION

Ultrasound-guided ESP block via a single injection produces a mean dermatomal spread of 9.0 (range, 8-11), after a fixed volume of 20 mL of 0.5% bupivacaine performed at the midthoracic level, with a high rate of analgesic efficacy. A dose/effect study is needed in order to evaluate complete sensory loss or analgesic block.

## Author Contributions

AC, JC, and AB contributed to the design of the study. AB, JC, JG, AC, and KV collected the data. JG, AC, AB, JC, MF, and PP contributed to drafting and revision of the manuscript.

## Acknowledgments

The authors thank Professor Jorge Botero at Antioquia University for his assistance in statistics and methodology design in this study, and the nurses of the pain unit at the Hospital San Vicente Fundación for their help with clinical management of patients.

## REFERENCES

- Forero M, Adhikary SD, Lopez H, Tsui C, Chin KJ. The erector spinae plane block: A novel analgesic technique in thoracic neuropathic pain. *Reg Anesth Pain Med* 2016; 41:621-627.
- Tulgar S, Senturk O. Ultrasound guided erector spinae plane block at L-4 transverse process level provides effective postoperative analgesia for total hip arthroplasty. *J Clin Anesth* 2018; 44:68.
- Tulgar S, Senturk O. Ultrasound guided low thoracic erector spinae plane block for postoperative analgesia in radical retroperic prostatectomy, a new indication. *J Clin Anesth* 2018; 47:4. www.ncbi.nlm.nih.gov/pubmed/29518667. Date Accessed 10/13/2018.
- Ueshima H, Otake H. Blocking of multiple posterior branches of cervical nerves using an erector spinae plane block. *J Clin Anesth* 2018; 46:44.
- Forero M, Rajarathinam M, Adhikary S, Chin KJ. Continuous erector spinae plane block for rescue analgesia in thoracotomy after epidural failure: A case report. *A A Case Rep* 2017; 8:254-256.
- Chin KJ, Adhikary S, Sarwani N, Forero M. The analgesic efficacy of pre-operative bilateral erector spinae plane (ESP) blocks in patients having ventral hernia repair. *Anaesthesia* 2017; 72:452-460.
- Tsui BCH, Fonseca A, Munshey F, McFadyen G, Caruso TJ. The erector spinae plane (ESP) block: A pooled review of 242 cases. *J Clin Anesth* 2019; 53:29-34.
- De Cassai A, Tonetti T. Local anesthetic spread during erector spinae plane block. *J Clin Anesth* 2018; 48:60-61.
- Jones MR, Urits I, Shnider MR, Matyal R. Confirmation of erector spinae plane block analgesia for 3 distinct scenarios. *A A Pract* 2019; 12:141-144. www.ncbi.nlm.nih.gov/pubmed/30130282. Date Accessed 09/01/2019.
- Ivanusic J, Konishi Y, Barrington MJ. A cadaveric study investigating the mechanism of action of erector spinae blockade. *Reg Anesth Pain Med* 2018; 43:567-571.
- Yang H-M, Choi YJ, Kwon H-J, O J, Cho TH, Kim SH. Comparison of injectate spread and nerve involvement between retrolaminar and erector spinae plane blocks in the thoracic region: A cadaveric study. *Anaesthesia* 2018; 73:1244-1250. www.ncbi.nlm.nih.gov/pubmed/30113699. Date Accessed 01/10/2019.
- Vidal E, Giménez H, Forero M, Fajardo M. Bloqueo del plano del músculo erector espinal: Estudio anatómico-cadavérico para determinar su mecanismo de acción. *Rev Esp Anesthesiol Reanim* 2018; 65:514-519.
- Forero M, Rajarathinam M, Adhikary SD, Chin KJ. Erector spinae plane block for the management of chronic shoulder pain: A case report. *Can J Anesth* 2017; 65:288-293.
- Ueshima H, Otake H. Erector spinae plane block provides effective pain management during pneumothorax surgery. *J Clin Anesth* 2017; 40:74. www.ncbi.nlm.nih.gov/pubmed/28625453. Date Accessed 10/13/2018.
- Costache I, Pawa A, Abdallah FW. Paravertebral by proxy - time to redefine the paravertebral block. *Anaesthesia* 2018; 73:1185-1188. d
- Adhikary SD, Bernard S, Lopez H, Chin KJ. Erector spinae plane block versus retrolaminar block: A magnetic resonance imaging and anatomical study. *Reg Anesth Pain Med* 2018; 43:756-762.
- Schwartzmann A, Peng P, Maciel MA, Forero M. Mechanism of the erector spinae plane block: Insights from a magnetic resonance imaging study. *Can J Anesth* 2018; 65:1165-1166. http://link.springer.com/10.1007/s12630-018-1187-y. Date Accessed 02/14/2019.
- Elkoundi A, Eloukkal Z, Bensghir M, Belyamani L, Lalaoui SJ. Erector spinae plane block for hyperalgesic acute pancreatitis. *Pain Med* 2019; 20:1055-1056. https://academic.oup.com/painmedicine/article/20/5/1055/5199357. Date Accessed 09/01/2019.
- Uppal V, Sondekoppam RV, Sodhi P, Johnston D, Ganapathy S. Single-injection versus multiple-injection technique of ultrasound-guided paravertebral blocks. *Reg Anesth Pain Med* 2017; 42:575-581.
- Higuchi H, Adachi Y, Kazama T. Factors affecting the spread and duration of epidural anesthesia with ropivacaine. *Anesthesiology* 2004; 101:451-460.
- Marhofer D, Marhofer P, Kettner SC, et al. Magnetic resonance imaging analysis of the spread of local anesthetic solution after ultrasound-guided lateral thoracic paravertebral blockade: A volunteer

study. *Anesthesiology* 2013; 118:1106-1112. <http://insights.ovid.com/crossref?an=00000542-201305000-00021>. Date Accessed 09/01/2019.

22. Shafiq F, Hamid M, Samad K. Complications and interventions associated with epidural analgesia for postoperative pain relief in a tertiary

care hospital. *Middle East J Anaesthesiol* 2010; 20:827-832. [www.ncbi.nlm.nih.gov/pubmed/21526668](http://www.ncbi.nlm.nih.gov/pubmed/21526668). Date Accessed 10/12/2018.

