

Retrospective Study

## Percutaneous Endoscopic Lumbar Discectomy as an Emergent Surgery for Cauda Equina Syndrome Caused by Lumbar Disc Herniation

Changhong Chen, MD<sup>1-3</sup>, Pan Fan, PhD<sup>1</sup>, Lei Huang, MS<sup>2</sup>, Huaqin Zhen, MS<sup>2</sup>, Lin Liu, MS<sup>2</sup>, and Yuntao Wang, PhD<sup>1</sup>

From: <sup>1</sup>Department of Orthopedics, Affiliated Zhongda Hospital of Southeast University, Nanjing Jiangsu, P.R. China; <sup>2</sup>Department of Orthopedics, Jiangyin Affiliated Hospital of Nanjing Chinese Medicine University, Wuxi City, Jiangsu Province, P.R. China; <sup>3</sup>Department of Orthopaedic Surgery, New York University Medical Center, New York, NY, USA

Address Correspondence:  
Yuntao Wang, PhD  
Department of Orthopedics,  
Affiliated Zhongda Hospital of  
Southeast University,  
No. 87 Dingjiaqiao  
Nanjing Jiangsu, P.R. China  
E-mail: Wangyttod@aliyun.com

Disclaimer: There was no external funding in the preparation of this manuscript.

Conflict of interest: Each author certifies that he or she, or a member of his or her immediate family, has no commercial association (i.e., consultancies, stock ownership, equity interest, patent/licensing arrangements, etc.) that might pose a conflict of interest in connection with the submitted manuscript.

Manuscript received: 06-20-2019  
Revised manuscript received: 09-13-2019  
Accepted for publication: 11-19-2019

Free full manuscript:  
[www.painphysicianjournal.com](http://www.painphysicianjournal.com)

**Background:** Cauda equina syndrome (CES) is a rare and serious syndrome that requires urgent surgery to improve neurological symptoms. CES can be caused by lumbar disc herniation (LDH) and accounts for about 1% to 3% of all cases of disc herniation.

**Objectives:** The purpose of this study was to analyze the characteristics and outcomes of the cases of patients with CES caused by LDH and treated by percutaneous endoscopic lumbar discectomy (PELD).

**Study Design:** This study used a retrospective design.

**Setting:** Research took place at the Jiangyin Hospital affiliated with Nanjing University of Chinese Medicine, Jiangsu, China.

**Methods:** This was a retrospective study of patients treated for CES due to LDH with PELD as an emergent surgery at a single institutional department between January 2015 and March 2018. The following variables were analyzed: age, gender, the level of disc prolapse, time interval between diagnosis and surgery, lower extremity pain or weakness, perianal sensation, voluntary anal contraction, presence of bladder dysfunction, and the reversal of these deficits in follow-up.

**Results:** After the emergent surgery with PELD, the lower extremity symptoms were all completely recovered or partly decreased. Only one patient had weakness with plantar flexion of the left foot at the one-year time point. The decreased perianal sensations were partly recovered after surgery, and 9 cases had complete recovery and 2 cases had partial recovery at the one-year follow-up. No patients had anal contraction and bladder problems after the one-year follow-up.

**Limitations:** The number of cases reported here is limited, so we will expand the study by including an increased number of patients and a longer follow-up duration.

**Conclusion:** Taken together, these observations show that PELD, used as a minimally invasive choice of emergent surgery, can provide enough decompression of disc prolapse and a satisfactory outcome for patients with CES caused by LDH.

**Key words:** Cauda equina syndrome, lumbar disc herniation, outcomes, percutaneous endoscopic lumbar discectomy

**Pain Physician 2020; 23:E259-E264**

**C**auda equina syndrome (CES) is a rare and serious syndrome that requires urgent surgery to improve neurological symptoms. CES can be

caused by lumbar disc herniation (LDH) and accounts for about 1% to 3% of all cases of disc herniation (1,2).

Clinically, signs and symptoms of CES may differ

among patients. CES can manifest as bowel or bladder incontinence, saddle anesthesia, sexual dysfunction, dermatomal numbness, low back pain, motor weakness, and paraplegia (3,4). CES results from severe lumbar canal stenosis secondary to any space-occupying lesion, but is most commonly associated with compression of the sacral nerve roots by a lumbar disc herniation. The diagnosis of CES is usually suspected; however, associated signs can only be recognized by the person experiencing them and confirmed by medical imaging.

The cauda equina compression can be described in different forms as upper level (L2/L3/L4 nerve roots), middle level (L5/S1 nerve roots), and lower level (S2/S3/S4/S5 nerve roots) (5).

It is widely acknowledged that a prompt diagnosis and urgent intervention are crucial to prevent the progression of the disease and to improve outcomes. Although there is no standard procedure for curing this urgent dysfunctional disease, open surgical decompression, traditionally using the posterior approach, is widely accepted to treat CES (6).

Minimally invasive techniques are gaining influence in the field of spinal surgery, especially the percutaneous endoscopic lumbar discectomy (PELD) techniques. The PELD approach is becoming a preferred choice to treat LDH or LDH-associated CES. Existing data indicate no significant difference between PELD and open decompression for the treatment of LDH in terms of functional outcome, complication rate, and reoperation rate, but PELD can achieve shorter operation time and hospital stay than open lumbar discectomy (7,8).

Given that the treatment of CES requires urgent surgical intervention, lumbar discectomy and PELD methods are 2 minimally invasive intervention methods used for the treatment of LDH-associated CES with favorable clinical outcomes. However, there is no study comparing surgical outcomes of PELD and discectomy. In this article, we discuss the outcomes of using PELD to cure CES secondary to LDH.

## **METHODS**

The clinical study was approved by the ethics committee of the Jiangyin Hospital affiliated with Nanjing University of Chinese Medicine (No. 2019036). A retrospective records review of 11 patients who had LDH accompanied with CES and who underwent PELD between January 2015 and March 2018 was completed. All patients attended clinical follow-up appointments for a period exceeding one year. Patient's age, gender, computed tomography (CT) and magnetic resonance

imaging (MRI) scans, syndromes and body signs, and time interval between diagnosis and surgery were collected (9). All patients included in this review met the following requirements: (a) LDH accompanied with CES, (b) no bony canal stenosis, (c) CT and MRI demonstrate nerve root compression by a herniated lumbar disc, and (d) patient has at least one year of follow-up data. Patients without CES symptoms, patients with lumbar spondylolisthesis or segmental instability, and patients with CES caused by other spinal diseases were all excluded.

## **Surgical Techniques**

A standard PELD procedure was performed by the orthopedist. All patients were placed in the lateral or prone position and used local anesthesia. The surgeon could communicate with the patients during the entire procedure. The procedure was performed under lateral and anteroposterior fluoroscopic guidance. Percutaneous endoscopic transforaminal discectomy (PETD) or percutaneous endoscopic interlaminar discectomy (PEID) was chosen depending on the size and position of the herniated disc.

For transforaminal discectomy, the skin entry point was generally 10 to 14 cm from the midline. Under lateral and anteroposterior fluoroscopic guidance, a guidewire with a craniocaudal inclinatory 20° to 30° angle was located on the superior vertebral notch of the lower vertebra and a serial guide rod was docked between the lower vertebral body and the ventral surface of the superior facet. Then a reamer was used to remove the superior facet and widen the intervertebral foramen. At this step, the surgeon must pay attention to control the reamer carefully. After that, the working cannula was located at a correct place. When the yellow ligament was removed, the traversing nerve root and the dural sac were exposed. The traversing nerve root and the dural sac were gently retracted, and the disc fragment was identified and removed. After removal of the fragment, the traversing nerve root and the dural sac were beating with the pulse of the artery. For interlaminar discectomy, the skin entry was generally 2 cm from the midline angle. But the cannula angle was quite different depending on the migration of the herniated disc. With up-migration of L5-S1, the caudocranial direction and shoulder approach of the S1 nerve root can facilitate access to the up-migrated fragment below the axilla of the L5 nerve root or the lateral margin of the thecal sac parallel to the upper lamina. With down-migration of L5-S1, the craniocaudal direc-

tion and axilla approach can provide direct vision above the mid-S1 pedicle level. High-grade inferior migration required partial removal of the upper S1 lamina (7). To remove the herniated disc, the same steps were followed as for the transforaminal discectomy (Fig. 1).

**Statistical Analysis**

SPSS Version 20.0 (IBM Corporation, Armonk, NY) was used for statistical analysis. Descriptive statistics were generated for the demographic and clinical characteristics. Continuous variables were expressed as mean ± standard deviation and categorical variables were expressed as counts and percentages. A statistically significant difference was indicated when the *P* value < .05.

**RESULTS**

A total of 11 patients with a mean age of 41 years (range, 30-56 years) were included in this study. The characteristics of all patients are summarized in Table

1 and Fig. 2. There were 4 (36.36%) male patients and 7 (63.64%) female patients with an average follow-up of 14 months (range, 12-20 months). A higher proportion (72.73%) of patients had a herniated segment of the disc at the L5/S1 level compared to the L4/5 level (27.27%). All patients had sensory and motor deficits in the lower extremities and decreased or absent perianal sensation. Three cases had symptoms of acute uroschisis and urethral catheterization was performed. Eight cases had incomplete CES (CES-I, incomplete urinary retention) and 3 cases had complete CES (CES-R, complete urinary retention).

Patients were taken to the operating room as early as possible. The time intervals between diagnosis and surgery were all less than 24 hours (16 ± 5.5 hours). After the surgery, the lower extremity symptoms of all patients were completely recovered or partly decreased, and one patient still had a bit of left leg limp at the one-year time point. All of them still had

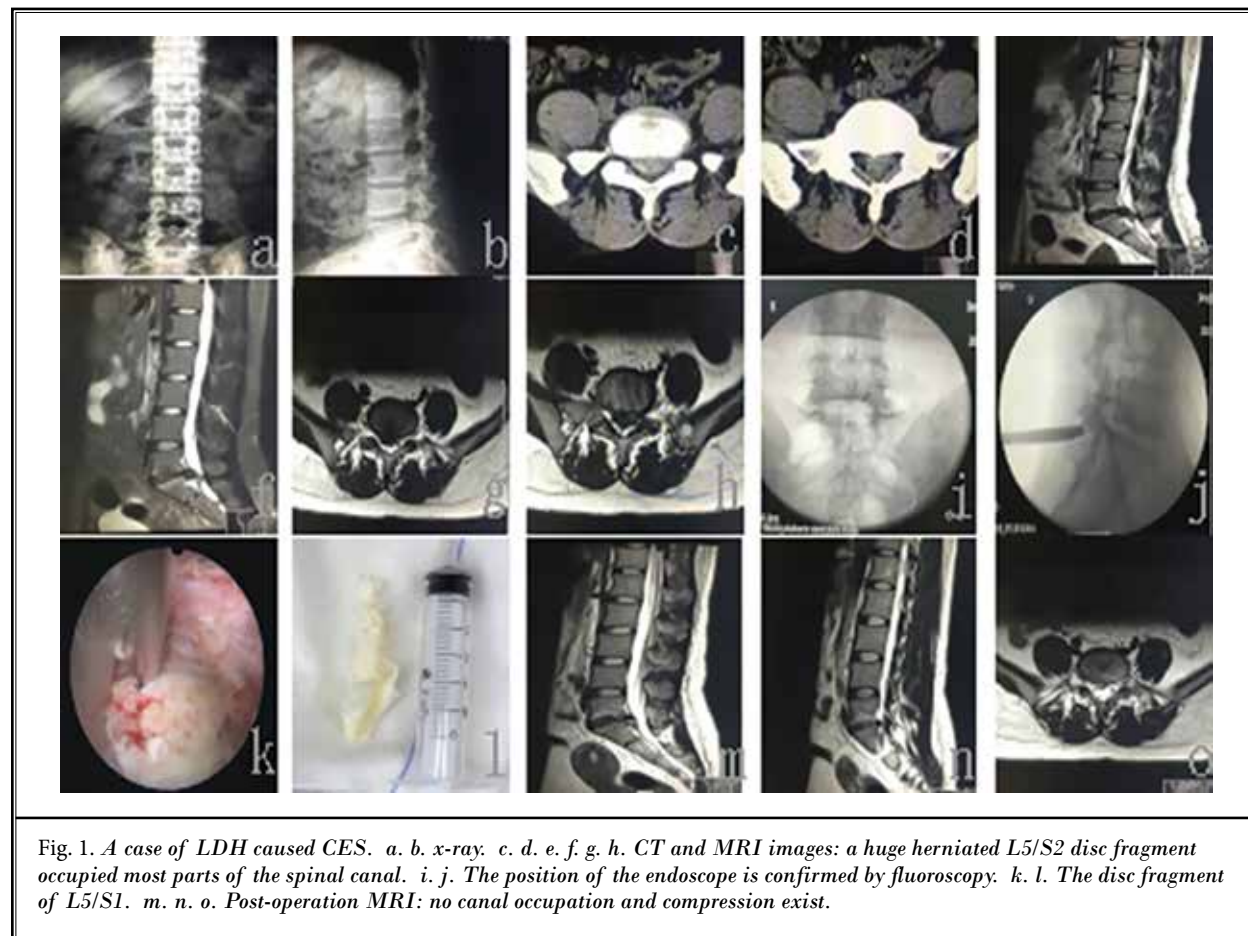
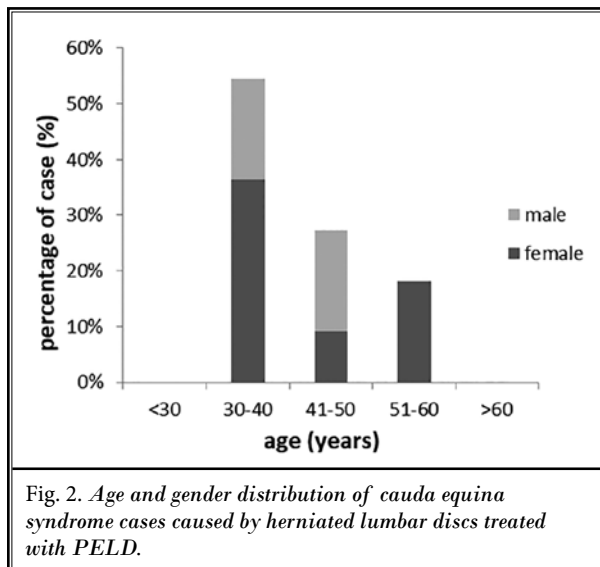


Table 1. Baseline characteristics of all patients (mean ± SD)..

Patient	Age (y)	Gender	Level	LEPW	PAS	VAC	AU	TI(h)
1	42	Male	L4/5	yes	decrease	weak	yes	12
2	56	Female	L5/S1	yes	decrease	normal	no	23
3	40	Female	L5/S1	yes	decrease	weak	no	17
4	52	Female	L4/5	yes	decrease	normal	no	22
5	30	Male	L5/S1	yes	decrease	normal	no	12
6	31	Male	L5/S1	yes	absent	absent	yes	4
7	37	Male	L4/5	yes	decrease	weak	no	15
8	40	Female	L5/S1	yes	absent	absent	yes	14
9	45	Female	L5/S1	yes	decrease	normal	no	23
10	38	Female	L5/S1	yes	decrease	normal	no	18
11	35	Female	L5/S1	yes	decrease	weak	no	12

LEPW, lower extremity pain or weakness; PAS, perianal sensation; VAC, voluntary anal contraction; AU, acute uroschesis; TI, time intervals between diagnosis and surgery



decreased perianal sensation after surgery, but 9 cases were completely recovered, and 2 cases had partial recovery at the one-year follow up. No patients had anal contraction or bladder problems when they followed up at one year (Table 2).

### DISCUSSION

CES is a severe and urgent situation. There are many causes of CES, but LDH is the most common reason for this disease (10). It is rare but can cause life-changing consequences if not acted upon immediately when suspected. In the United Kingdom, red-flag warnings and strict guidance are used for the treatment of this emergent disease (11). The CES warning signs include 5 aspects: bilateral neurogenic sciatica, reduced perineal sensation, altered bladder function ultimately to painless urinary retention, loss of anal tone, and sexual dysfunction (12). Patients and doctors must pay attention to each of these 5 signs to allow early diagnosis of CES and urgent surgical decompression (13).

There are many methods used for the treatment of CES, but the most common method is surgical decompression (14-17). Minimally invasive decompression is an effective approach for LDH with fewer complications compared to conventional laminectomy.

For the last 5 years, and due to its rapid recovery, PELD has been accepted as one of the minimally invasive methods effective for the treatment of LDH (18). PELD has also been reported as one of the most common and minimally invasive surgical approaches under local anesthesia (19).

Table 2. Patient's sense, motor function before and after surgery.

Time point	Lower Extremity Pain or Weakness	Perianal Sensation	Voluntary Anal Contraction	Acute Uroschesis
Before surgery	11	11 (2 absent/9 decrease)	6 (2 absent/4 decrease)	2
1 week after surgery	8	11 decrease	6 decrease	no
1 year follow-up	1	2 decrease	normal	no

Another important component is the timing of decompression surgery from the appearance of signs and symptoms. It is widely accepted that a proven CES requires an urgent and appropriate surgical intervention as early as possible, usually within 48 hours from the time of onset of symptoms (20-22). Despite the performance of the urgent surgery, there are still about one-fifth of patients who will have incomplete outcomes and need ongoing treatment for bladder, bowel, and sexual dysfunction, along with significant psychosocial consequences (23). On the contrary, some researchers have indicated that no statistically significant relationships were found between the timing of surgical decompression and recovery of bladder function (24). In this study, the timing of surgery from the onset of signs and symptoms was less than 24 hours, resulting in complete recovery

of the saddle-type sensory loss, bladder dysfunction, and muscular weakness in the legs at different degrees.

## CONCLUSION

From this retrospective study, we have confirmed that PELD, as a minimally invasive surgical technique, can provide sufficient decompression of disc prolapse and satisfactory outcomes for patients with LDH-associated CES. Although there is currently no consensus regarding the criteria for selecting the best surgical approach to cope with LDH in an urgent situation, we put forward PELD as an optimal choice for surgery for LDH-associated CES disease. We acknowledge the relatively low number of cases reported here. We plan to expand the study in the future by including a larger number of patients and increasing the duration of follow-up.

## REFERENCES

1. Tamburrelli FC, Genitiempo M, Bochicchio M, Donisi L, Ratto C. Cauda equina syndrome: Evaluation of the clinical outcome. *Eur Rev Med Pharmacol Sci* 2014; 18:1098-1105.
2. Bednar DA. Cauda equina syndrome from lumbar disc herniation. *CMAJ* 2016; 188:284.
3. Spector LR, Madigan L, Rhyne A, Darden B, Kim D. Cauda equine syndrome. *J Am Acad Orthop Surg* 2008; 16:471-479.
4. Fraser S, Roberts L, Murphy E. Cauda equina syndrome: A literature review of its definition and clinical presentation. *Arch Phys Med Rehabil* 2009; 90:1964-1968.
5. Orendacova J, Cizkova D, Kafka J, et al. Cauda equina syndrome. *Prog Neurobiol* 2001; 64:613-637.
6. Chau AM, Xu LL, Pelzer NR, Gragnaniello C. Timing of surgical intervention in cauda equina syndrome—a systematic critical review. *World Neurosurg* 2014; 81:640-650.
7. Ruan W, Feng F, Liu Z, Xie J, Cai L, Ping A. Comparison of percutaneous endoscopic lumbar discectomy versus open lumbar microdiscectomy for lumbar disc herniation: A meta analysis. *Int J Surg* 2016; 31:86-92.
8. Choi K, Lee DC, Shim H, Shin S, Park C. A strategy of percutaneous endoscopic lumbar discectomy for migrated disc herniation. *World Neurosurg* 2017; 99:259-266.
9. Reddy AP, Mahajan R, Rustagi T, Chhabra HS. Bladder recovery patterns in patients with complete cauda equina syndrome: A single center study. *Asian Spine J* 2018; 12:981-986.
10. Fuso FAF, Dias ALN, Letaif OB, Cristante AF, Marcon RM, Barros Filho TEP. Epidemiological study of cauda equina syndrome. *Acta Ortop Bras* 2013; 21:159-162.
11. Greenhalgh S, Finucane L, Mercer C, Selfe J. Assessment and management of cauda equina syndrome. *Musculoskelet Sci Pract* 2018; 37:69-74.
12. Todd NV, Dickson RA. Standards of care in cauda equina syndrome. *Br J Neurosurg* 2016; 30:518-522.
13. Germon T, Ahuja S, Casey A, Rai A. British Association of Spine Surgeons standards of care for cauda equina syndrome. *Spine J* 2015; 15:S2-S4.
14. Srikandarajah N, Boissaud-Cooke MA, Clark S, Wilby MJ. Does early surgical decompression in cauda equina syndrome improve bladder outcome? *Spine* 2015; 40:580-583.
15. Li X, Dou Q, Hu S, et al. Treatment of cauda equine syndrome caused by lumbar disc herniation with percutaneous endoscopic lumbar discectomy. *Acta Neurol Belg* 2016; 116:185-190.
16. Balasubramanian K, Kalsi P, Greenough CG, Kuskoor Seetharam MP. Reliability of clinical assessment in diagnosing cauda equina syndrome. *Br J Neurosurg* 2010; 24:383-386.
17. Shen L, Fang L, Qiu Y, et al. Study on different surgical approaches for acute lumbar disk protrusion combined with cauda equina syndrome. *Int J Clin Exp Pathol* 2014; 7:8875-8880.
18. Choi K, Kim J, Park C. Percutaneous endoscopic lumbar discectomy as an alternative to open lumbar microdiscectomy for large lumbar disc herniation. *Pain Physician* 2016; 19:E291-E300.
19. Kapetanakis S, Chaniotakis C, Kazakos C, Papatheanasiou JV. Cauda equina syndrome due to lumbar disc herniation: A review of literature. *Folia Med* 2017; 59: 377-386.
20. Glennie RA, Urquhart JC, Staudt MD. The relationship between the duration of acute cauda equina compression and functional outcomes in a rat model. *Spine* 2014; 39:e1123-e1131.
21. Petr O, Glodny B, Brawanski K, et al. Immediate versus delayed surgical treatment of lumbar disc herniation

- for acute motor deficits. *Spine* 2019; 44:454-463.
22. DeLong WB, Polissar N, Neradilek B. Timing of surgery in cauda equina syndrome with urinary retention: Meta-analysis of observational studies. *J Neurosurg Spine* 2008; 8:305-320.
23. Gardner A, Gardener E, Morley T. Cauda equina syndrome: A review of the current clinical and medical legal position. *Eur Spine* 2011; 20:690-697.
24. Kaiser R, Nasto LA, Murali Venkatesan M, et al. Time factor and disc herniation size: Are they really predictive for outcome of urinary dysfunction in patients with cauda equina syndrome? *Neurosurgery* 2018; 83:1193-1200.