

Retrospective Study

## Effectiveness of Superior Hypogastric Plexus Neurolysis for Pelvic Cancer Pain

Andrés Rocha, MD, Ricardo Plancarte, MD, Reyna Guadalupe Ramos Natarén, MD, Ivan Hamiyd Salazar Carrera, MD, Víctor Alfonso De Los Reyes Pacheco, MD, and Berenice Carolina Hernández-Porras, MD

From: Instituto Nacional de Cancerología, Pain Clinic, Mexico City, Mexico

Address Correspondence:  
Berenice Carolina Hernandez-Porras, MD  
Instituto Nacional de Cancerología, Pain Clinic  
Av San Fernando 22 Col Seccion XVI, Tlalpan, Mexico City, DF 14080, Mexico  
E-mail: plankyzb@yahoo.com.mx

Disclaimer: There was no external funding in the preparation of this manuscript.  
Conflict of interest: Each author certifies that he or she, or a member of his or her immediate family, has no commercial association (i.e., consultancies, stock ownership, equity interest, patent/licensing arrangements, etc.) that might pose a conflict of interest in connection with the submitted manuscript.

Manuscript received: 02-28-2019  
Revised manuscript received: 05-11-2019; 09-09-2019  
Accepted for publication: 09-13-2019

Free full manuscript:  
[www.painphysicianjournal.com](http://www.painphysicianjournal.com)

**Background:** The superior hypogastric plexus block has been indicated for visceral pelvic pain treatment associated with malignancy. The first international report of this technique was published by Plancarte et al, in which a posterior percutaneous approach guided by fluoroscopy was described by applying neurolytic agents. The considerable variability in the data reported gave rise to 2 clinical approaches to those who performed the blockade early and those who executed it at a later stage of cancer.

**Objectives:** The present study aims to provide more evidence regarding the effectiveness of this procedure.

**Study Design:** This is a retrospective, longitudinal, descriptive study.

**Setting:** The study was held at the pain unit service of the National Cancer Institute, Mexico City.

**Methods:** A nonprobabilistic sample was selected; the data collection took place from January 2006 to December 2016 with patients diagnosed with pelvic pain, confirmed by imaging and biopsy studies. Patients who received any other type of intervention of the sympathetic axis, patients with a different approach than the classic or paravertebral technique, and patients with low survival rate were excluded. The Student t test was used to measure the significant difference between Visual Analog Scale (VAS) and morphine equivalent daily dose. The Cochran–Mantel–Haenszel test and the Gamma test were used to measure the association between the initial Karnofsky and blockade success.

**Results:** The study included a total of 180 patients. The success rate was 59.4% at 1 month, 55.5% at 3 months, and 48.8% at 6 months. There was a sustained and significant VAS reduction that was 49.55% at 3 months. A significant reduction in opioid consumption of 12.55% was found at 3 months. There was no significant statistical evidence related to either opioid consumption or the functionality of the patient before the blockade as an influential variable in the success of the procedure.

**Limitations:** Retrospective study, developed in a single center.

**Conclusions:** Although opioids remain the cornerstone of cancer pain treatment, they produce many deleterious side effects. The superior hypogastric plexus neurolysis represents a reproducible and effective alternative in the management of pain in this group of patients.

**Key words:** Pelvic pain, neoplasms, chemical neurolysis, pain management, cancer pain, palliative care, analgesia, nerve block

**Pain Physician 2020; 23:203-208**

**T**he prevalence of pain in patients with cancer and metastatic disease is estimated to be 64%, patients under treatment 59%, and patients after curative treatment reach up to 33%. This medical condition affects the quality of life and has been associated with functional impairment, dependence, family problems, and financial burdens (1).

Abdominopelvic pain in patients with cancer has a prevalence of 35% to 45% and can be presented as a syndrome with somatic, visceral, and neuropathic mechanisms (2,3).

After the proposal of the pain ladder, treatments have evolved to offer a multimodal approach and management. Approximately 80% of patients respond well to this pharmacologic scheme (4,5). Currently, several American and European cancer guidelines endorse the use of interventional techniques for treating cancer pain (1,6,7).

Analgesic blocks can be practiced in sympathetic and somatic structures (8,9). A growing trend is to use minimally invasive and modulating techniques, but in patients with cancer pain, neurolytic agents still play an essential role (10,11).

The superior hypogastric plexus block (SHPB) has been indicated for the visceral pelvic pain associated with cancer; however, its indications have been expanded to treat endometriosis, pelvic inflammatory disease, and adhesions, among other conditions (10-12).

The superior hypogastric plexus (SHP) is a retroperitoneal structure, localized at the level of the sacral promontory between L5 and S1, close to the bifurcation of the iliac vessels. The relief of visceral pain is feasible because the afferent tracts that innervate the organs at the pelvic level run along the sympathetic nerves allowing their inhibition with neurolytic agents (11,13,14).

The most common approaches are the transdiscal, the posterior paravertebral, and the anterior one (14,15). Our technical approach was described by Plancarte et al (12) in which a 7-inch, 22-G needle was inserted after infiltration with local anesthetic. The x-ray is turned 30-degrees caudal and 45-degrees medial direction with the bevel toward the midline until the anterolateral portion the vertebral body of L5 is reached, when the needle crosses the fascia of the ipsilateral psoas muscle to the retroperitoneum, loss of resistance can be presented. The depth of the needle's tip is verified in lateral view, and the contralateral needle is inserted in a similar manner. Injection of 3 to 4 mL of contrast medium through each needle confirms the correct placement of the needle to the paramedian

region, and finally 8 to 10 mL of 10% phenol is injected to produce SHP lysis (11).

## **METHODS**

This is a retrospective, longitudinal, descriptive study held at the National Cancer Institute in Mexico City, where data collection of patients with pelvic pain secondary to cancer diagnosis was carried out, with computed tomography/magnetic resonance imaging and histopathological studies in the period of January 1, 2006 to December 30, 2016, in which SHP neurolysis was performed using the Plancarte et al (12,13) approach mentioned earlier. Patients treated with a different approach or any other type of procedure performed on the sympathetic axis, and those whose lifetime survival was less than 6 months were excluded. Results of the Visual Analog Scale (VAS), morphine equivalent daily dose (MEDD), and Karnofsky were reported. The follow-up was up to 3 years or until the patient interrupted the treatment due to several reasons.

The VAS was categorized as mild (1-3), moderate (4-6), and severe (7-10). All the patients had concomitant use of several opioids, so the MEDD was determined.

## **Statistical Analyses**

For the statistical analysis, the Student t test was performed to verify a significant difference in the mean of the VAS, Karnofsky, and MEDD variables recorded in the screening visit. The Cochran-Mantel-Haenszel test assessed any association, and the Gamma test was used to measure the correlation between variables and blockade success. A confidence level of 95% was used.

## **RESULTS**

The study comprised 180 patients who underwent SHP lysis, their main characteristics were related to age and body mass index, which are described in Table 1. The most prevalent type of cancer found was cervical cancer (55%), followed by ovarian cancer.

A second neurolytic block was required in 9 patients (5.5%): 3 in the third month, 2 at 6 months, and 4 at 1 year of follow-up. One month after the block was performed, 59.4% of the patients reported more than 50% of pain reduction. At 3 and 6 months, 55.5% and 48.8% of the patients, respectively, had significantly improved VAS scores. Figure 1 shows outcomes at 1, 3, and 6 months after the procedure.

No major complications or procedure-related morbidity occurred, 92.8% of the population did not present any adverse effect. Only 5.6% exhibited transitory hypoten-

Table 1. Characteristics of patients.

Patients	180
Age	52 ±14
BMI	23.41 ±4.14
Female	81.67%
Male	18,3%
<b>Cancer types</b>	<b>Percentage</b>
Appendix	0.56%
Colon	5.56%
Cervical	55.00%
Endometrium	1.11%
Stomach	1.11%
Intestine	0.56%
Lipo sarcoma	1.67%
Breast	1.67%
Bone marrow	0.56%
Ovarian	11.11%
Pancreas	3.89%
Prostate	2.22%
Lung	0.56%
Rectum	7.78%
Testicles	5.00%
Vagina	0.56%
Bladder	0.56%
Gallbladder	0.56%

BMI, body mass index

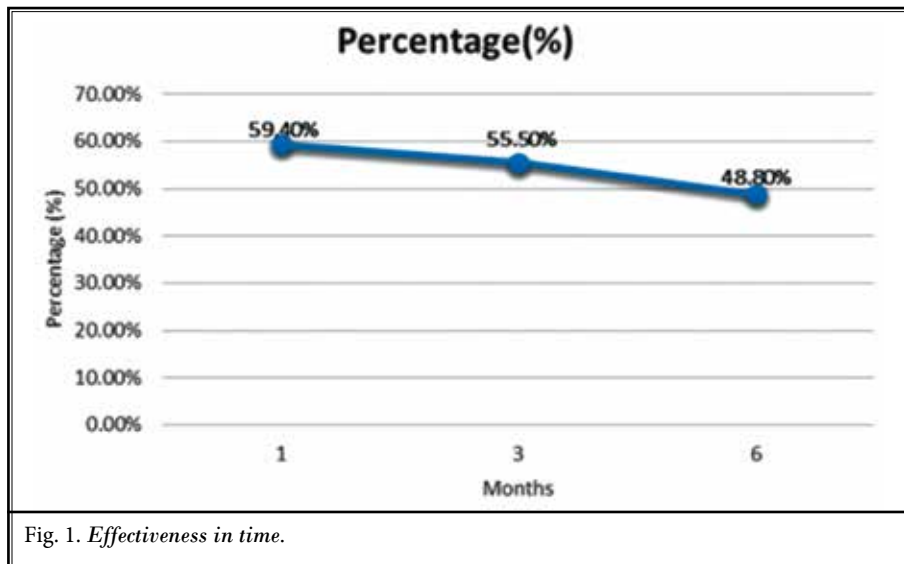


Table 2. Adverse effects secondary to procedure.

	Patients	Percentage
Hypertension	1	0.56%
Transient hypotension	10	5.56%
Transient urinary incontinence	1	0.56%
Iliac artery puncture	1	0.56%
None	167	92.78%
Total	180	100.00%

sion, one patient presented hypertension, one puncture of the iliac vessel, and one more transient urinary incontinence that remitted in < 24 hours (Table 2). In addition to the use of opioids, some patients used other prescriptions before the procedure; 25.5% of patients were using 2 or more medications for pain management, that percentage was reduced to 8.1% at 6 months but increased again after that.

The average VAS score recorded was 5.7 (preprocedural), pain rating was significantly reduced to 0.9 at 24 hours. At 3 and 6 months, the mean in VAS score was 2.88 and 3.02, respectively, the pain relief persisted through time up to 6 months in 88 (48.8%) patients. Parallel to VAS score decrease, a MEDD reduction was observed. Before the procedure, the average opioid consumption was 77.28 mg. During the first 7 days, consumption decreased to 41%, reaching an average consumption of 53.36 mg. Three months later, the reduction remained (Table 3). A steady decrease in functionality was observed even after the procedure.

The most prevalent symptom was constipation (52.2%), followed by nausea in 16.7%, and 8.9% of the patients presented both symptoms. One month after the blockade was performed, the number of patients with opioid-induced constipation decreased significantly to 12.2% (Table 4).

After identifying the conditional probability of the Karnofsky Performance Status, the tendency to better results in patients in the early stage according to Karnofsky is lost at 6 months. The rank of correlation demonstrated no tendency for better results in patients with higher Karnofsky scores, even at 3 months (Table 3).

## DISCUSSION

Despite a multitude of issues related to opioids (15-18) and emerging evidence in relation to effectiveness of various interventional modalities, multiple types of nerve blocks, including celiac plexus and hypogastric plexus use, has been declining due to various issues related to payment rates. The reimbursement rates

Table 3. Mean reduction.

Mean before procedure	VAS			MEDD			Karnofsky		
	5.7			77.3			72.4		
Time	Mean	P-value	CI %	Mean	P-value	CI%	Mean	P-value	CI%
24 hours	0.9	0.0000	78.97-88.04	54.6	0.0000	19.09-39.65	64.3	0.0000	7.47-15.08
7 days	2.1	0.0000	56.12-68.65	53.4	0.0000	20.68-41.23	56.8	0.0000	17.28-26.01
1 month	2.7	0.0000	45.13-56.48	61.2	0.0002	9.86-31.69	57.3	0.0000	15.57-26.17
3 months	2.9	0.0000	42.87-53.06	67.6	0.0286	1.32-23.78	-	-	-
6 months	3.0	0.0000	38.9-52.16	78.5	0.8135	"-15.28-12.01	-	-	-

VAS, visual analogue scale; MEDD, morphine equivalent daily dose; CI, confidence interval;% , percentage

Table 4. Opioid induced adverse effects

	Preprocedure			1 Month			3 Months			6 Months			
	Patients	%	CI%	Patients	%	CI %	P-value	CI %	%	Patients	%	CI %	P-value
Constipation	94	52.2%	48.5-55.9	22	12.2%	9.8-14.7	0.00000	12.4-17.8	15.1%	27	15.1%	12.4-17.8	0.00000
Nausea	30	16.7%	13.9-19.4	0	0.0%	0-0	0.00000	0-0	0.0%	0	0.0%	0-0	0.00005
Constipation/ Nausea	16	8.9%	6.8-11	0	0.0%	0-0	0.00004	0-0	0.0%	0	0.0%	0-0	0.00431
Drowsiness	1	0.6%	0-1.1	0	0.0%	0-0	0.29797	0-0	0.0%	0	0.0%	0-0	0.47165
None	39	21.7%	18.6-24.7	158	87.8%	85.3-90.2	0.00000	82.2-87.6	84.9%	64	74.4%	71.2-77.7	0.00000

CI, confidence interval; %,percentage

continue to be inadequate since 2016, even with the use of fluoroscopy, ultrasound, or a facility setting, despite multiple efforts by the American Society of Interventional Pain Physicians (ASIPP) (19,20).

This is likely resulting in reductions in use of interventional techniques. Opioid prescriptions are down but deaths continue to increase concurrent with a decline in interventional techniques.

According to Van Zundert (21), the evidence for the SHPB is 2C+ the efficacy has been demonstrated in observational studies. In the literature on SHPB 4 case reports (22-25), 4 case series (13,26-28) and 2 prospective randomized trials are described (29,30).

Many confounding factors can occur when analyzing the efficacy of the procedure, which has generated so much variability in the report of data (10).

In our study, the procedure demonstrated an efficacy of 55.5% at 3 months in terms of pain relief; similar findings have been reported before by our group in a different cohort of patients (12). A third cohort of patients (13) showed not only efficacy but also a significant opioid-spare effect. A separate study by another research group (29) found similar efficacy outcomes. We could not identify in the medical literature negative studies about the efficacy of this intervention.

Several approaches have been described, computed tomography-guided, such as the anterior, posteromedian, and transdiscal, and the anterior approach guided by ultrasound (31-33), also the combination of techniques, such as SHPB with ganglion impar block (34). Transdiscal approach has shown a shorter procedure time but has consistently failed to demonstrate a significant difference in terms of efficacy or opioid consumption (30).

Although there is a significant reduction in opioid consumption up to 3 months of 12.55%, this trend reverses after the sixth month. Although constipation reduction could be explained by MEDD decrease at the beginning, it could be associated with a sympathetic block. It is important to mention that some patients received a second block mostly at 1 year of follow-up, and many patients presented other painful syndromes over time related to cancer therapy that we did not record.

The limited presence of adverse effects of the procedure reflects its safety when it is carried out by experienced personnel. The most frequent was transient hypotension, which occurred in the elderly population and can be explained as a side effect of the anesthetic technique.

De Oliveira (29) hypothesized that neurolytic blocks in early stages of cancer could result in better outcomes. Although a tendency toward bet-

ter results in earlier stages, no statistically significant improvement was found. According to the rank of correlation, there was no tendency for better results in patients with higher Karnofsky for our study.

Neurolysis is the selective destruction of neural tissue to provide pain relief by interrupting pain transmission. Phenol acts by protein coagulation causing nonselective tissue destruction and initiates Wallerian degeneration in nerves (35). Phenol 10% was selected because it is the standardized concentration originally described and by its local anesthetic-like effect, which results in less procedural-related pain compared with alcohol. Due to a very long waiting list and the vast experience of our group, the protocol in our pain service considers the performance of direct neurolytic blocks in cancer patients, as was described originally by Plancarte et al (12).

We found no studies comparing specifically the duration of local anesthetic nerve blocks versus phenol, probably because the first description was used for cancer pain patients in palliative care in whom a previous diagnostic block was not performed (12), subsequent studies only added local anesthetics as a prognostic tool. Of note, Kroll et al (36) described factors associated with SHP neurolysis in cancer patients, and diagnostic nerve blocks failed to demonstrate any long-term difference in the primary outcomes. The effectiveness of alcohol versus phenol has been described for splanchnic nerve neurolysis for the treatment of intraabdominal cancer pain, but there was no difference in pain score or complications (37).

It is essential to mention that not only phenol but the needle can also lead to damage. We recommend the use of blunt needles, as previously described by

Akins et al (38). The effect of phenol on vascular structures is greater than that of neurophospholipids on nerve tissue. Injury to the L5 nerve root, inadvertent puncture of iliac vessels (as in our report), and pelvic viscera are some complications that can only be avoided with a good knowledge of anatomy and proper application of contrast nonionic agent and anteroposterior and lateral views (39).

### Limitations

Survival of the oncological patient represents a critical limitation, especially if the study is a follow-up like this. To reduce the confounding factors, all patients who had received any other type of intervention on the sympathetic axis were eliminated from the sample. In the records, only VAS and MEDD scores were described as markers of efficacy, functional outcome data were barely reported in the follow-ups. Moreover, the clinical stage of each type of cancer was not quantified because it would have added variables by subgroup that would not be significant because of the low representation of some types of cancer. It was decided to consider the patient's functionality when assessing them by the Karnofsky performance, which is suitable for all oncological subgroups.

### CONCLUSIONS

Opioids remain as the cornerstone of cancer pain treatment, but long-term use can generate considerable adverse effects. The findings of the present study support the use of SHP neurolysis as a reproducible and effective adjunct in the management of pain relief in this group of patients. Prospective randomized studies are needed to better understand the role of SHP neurolysis in this and other cancer-related pain.

### REFERENCES

- Allende S, Acosta A, Aguilar S, et al. Consenso Mexicano de manejo de dolor por cáncer. *Gaceta Mexicana de Oncología* 2016; 15(Suppl 1):3-34.
- Sindt JE, Brogan SE. Interventional treatments of cancer pain. *Anesthesiol Clin* 2016; 34:317-339.
- Rigor BM Sr. Pelvic cancer pain. *J Surg Oncol* 2000; 75:280-300.
- van den Beuken-van Everdingen MH, Hochstenbach LM, Joosten EA, Tjan-Heijnen VC, Janssen DJ. Update on prevalence of pain in patients with cancer: Systematic review and meta-analysis. *J Pain Symptom Manage* 2016; 51:1070-1090.e9.
- Torres LM, Calderón E, Pernia A, et al. De la escalera al ascensor. *Rev Soc Esp Dolor* 2002; 9:289-290.
- National Comprehensive Cancer Network. *Clinical Practice Guidelines in Oncology for Adult Cancer Pain*. Vol. 1. Fort Washington, PA, National Comprehensive Cancer Network, 2019.
- Fallon M, Giusti R, Aielli F, et al. Management of cancer pain in adult patients: ESMO Clinical Practice Guidelines. *Ann Oncol* 2018; 29(Suppl 4):iv166-iv191.
- Plancarte RS, Velázquez SR, Patt RB. Dolor pélvico. In: Torres ML, Masson SA (eds). *Medicina del Dolor*. Barcelona, España, 1997: pp. 679-688.
- Mercadante S, Klepstad P, Kurita GP, Sjögren P, Giarratano A. Sympathetic blocks for visceral cancer pain management: A systematic review and EAPC recommendations. *Crit Rev Oncol Hematol* 2015; 96:577-583.
- Manchikanti L, Kaye A, Falco F, Hirsch J. Essentials of interventional techniques in managing chronic pain. Cham,

- Switzerland, Springer International Publishing, 2018: pp. 573-594.
11. Plancarte-Sánchez R, Guajardo-Rosas J, Guillen-Núñez R. Superior hypogastric plexus block and ganglion impar. *Tech Reg Anesth Pain Manag* 2005; 9:86-90.
  12. Plancarte R, Amescua C, Patt RB. Superior hypogastric plexus block for pelvic cancer pain. *Anesthesiology* 1990; 73:236-239.
  13. Plancarte R, de Leon-Casasola OA, El-Helaly M, Allende S, Lema MJ. Neurolytic superior hypogastric plexus block for chronic pelvic pain associated with cancer. *Reg Anesth* 1997; 22:562-568.
  14. Gupta A. *Interventional Pain Medicine*. New York, Oxford University Press, 2012: pp. 225-232.
  15. Manchikanti L, Manchikanti KN, Kaye AD, Kaye AM, Hirsch JA. Challenges and concerns of persistent opioid use in cancer patients. *Expert Rev Anticancer Ther* 2018; 18:705-718.
  16. Manchikanti L, Kaye AM, Knezevic NN, et al. Responsible, safe, and effective prescription of opioids for chronic non-cancer pain: American Society of Interventional Pain Physicians (ASIPP) guidelines. *Pain Physician* 2017; 20:S3-S92.
  17. Manchikanti L, Sanapati J, Benyamin RM, Atluri S, Kaye AD, Hirsch JA. Reframing the prevention strategies of the opioid crisis: Focusing on prescription opioids, fentanyl, and heroin epidemic. *Pain Physician* 2018; 21:309-326.
  18. Chakravarthy K, Manchikanti L, Kaye AD, Christo PJ. Reframing the role of neuromodulation therapy in the chronic pain treatment paradigm. *Pain Physician* 2018; 21:507-513.
  19. Manchikanti L, Singh V, Benyamin RM, Kaye AD, Pampati V, Hirsch JA. Reframing Medicare physician payment policy for 2019: A look at proposed policy. *Pain Physician* 2018; 21:415-432.
  20. Manchikanti L, Soin A, Mann DP, Bakshi S, Pampati V, Hirsch JA. Reversal of growth of utilization of interventional techniques in managing chronic pain in Medicare population post Affordable Care Act. *Pain Physician* 2017; 20:551-567.
  21. Van Zundert J. *Evidence-Based Interventional Pain Medicine*. 1st ed. Oxford, Wiley- Blackwell, 2012: pp. 173-190.
  22. Baik J, Choi E, Lee P, Nahm F. Unilateral, single needle approach using an epidural catheter for bilateral superior hypogastric plexus block. *Korean J Pain* 2012; 25:43-46.
  23. Kanazi G, Perkins F, Thakur R, Dotson E. New technique for superior hypogastric plexus block. *Reg Anesth Pain Med* 1999; 24:473-476.
  24. Michalek P, Dutka J. Computed tomography-guided anterior approach to the superior hypogastric plexus for noncancer pelvic pain: A report of two cases. *Clin J Pain* 2005; 21:553-556.
  25. Rosenberg S, Tewari R, Boswell M, Thompson G, Seftel A. Superior hypogastric plexus block successfully treats severe penile pain after transurethral resection of the prostate. *Reg Anesth Pain Med* 1998; 23:618-620.
  26. Erdine S, Yucel A, Celik M, Talu G. Transdiscal approach for hypogastric plexus block. *Reg Anesth Pain Med* 2003; 28:304-308.
  27. De Leon-Casasola O, Kent E, Lema M. Neurolytic superior hypogastric plexus block for chronic pelvic pain associated with cancer. *Pain* 1993; 54:145-151.
  28. Wechsler R, Maurer P, Halpern E, Frank E. Superior hypogastric plexus block for chronic pelvic pain in the presence of endometriosis: CT techniques and results. *Radiology* 1995; 196:103-106.
  29. De Oliveira R, dos Reis M, Prado W. The effects of early or late neurolytic sympathetic plexus block on the management of abdominal or pelvic cancer pain. *Pain* 2004; 110:400-408.
  30. Gamal G, Helaly M, Labib Y. Superior hypogastric block: Transdiscal versus classic posterior approach in pelvic cancer pain. *Clin J Pain* 2006; 22:544-547.
  31. Cariati M, De Martini G, Pretolesi F, Roy MT. CT-guided superior hypogastric plexus block. *J Comput Assist Tomogr* 2002; 26:428-431.
  32. Nabil D, Eissa AA. Evaluation of posteromedial transdiscal superior hypogastric block after failure of the classic approach. *Clin J Pain* 2010; 26:694-697.
  33. Mishra S, Bhatnagar S, Rana SP, Khurana D, Thulkar S. Efficacy of the anterior ultrasound-guided superior hypogastric plexus neurolysis in pelvic cancer pain in advanced gynecological cancer patients. *Pain Med* 2013; 14:837-842.
  34. Ahmed DG, Mohamed MF, Mohamed SA-E. Superior hypogastric plexus combined with ganglion impar neurolytic blocks for pelvic and/or perineal cancer pain relief. *Pain Physician* 2015; 18:E49-E56.
  35. Gulati A. *Essentials of Interventional Cancer Pain Management*. Cham, Switzerland, Springer, 2019: pp. 141-144.
  36. Kroll CE, Schartz B, Gonzalez-Fernandez M, et al. Factors associated with outcome after superior hypogastric plexus neurolysis in cancer patients. *Clin J Pain* 2014; 30:55-62.
  37. Koyalagunta D, Engle MP, Yu J, Feng L. The effectiveness of alcohol versus phenol based splanchnic nerve neurolysis for the treatment of intra-abdominal cancer pain. *Pain Physician* 2016; 19:281-292.
  38. Akins EW, Hawkins IF Jr, Mladinich C, Tupler R, Siragusa RJ, Pry R. The blunt needle: A new percutaneous access device. *AJR Am J Roentgenol* 1989; 152:181-182.
  39. Raj P, Erdine SV (eds). *Pain-Relieving Procedures. The Illustrated Guide*. 1st ed. Chichester, UK, Wiley-Blackwell, 2012: pp. 365-371.