

Retrospective Study

# Hydraulic Distension with Pumping Technique for Treating Frozen Shoulder: A Case-Controlled, Retrospective, Comparative Study with 6-Month Follow-Up

Yong Wook Kim, MD, PhD<sup>1</sup>, Sanghoon Shin, MD<sup>1</sup>, Won Hyuk Chang, MD, PhD<sup>2</sup>, and Sang Chul Lee, MD, PhD<sup>1</sup>

From: <sup>1</sup>Department of Research Institute of Rehabilitation Medicine, Yonsei University College of Medicine, Seoul, Republic of Korea; <sup>2</sup>Department of Physical and Rehabilitation Medicine, Center for Prevention and Rehabilitation, Heart Vascular Stroke Institute, Samsung Medical Center, Sungkyunkwan University School of Medicine, Seoul, Republic of Korea

Address Correspondence: Sang Chul Lee, MD, PhD  
Department of Rehabilitation Medicine  
Severance Hospital, Yonsei University College of Medicine  
50-1 Yonsei-ro, Seodaemun-gu, Seoul 03722, Republic of Korea  
E-mail: bettertomo@yuhs.ac

Disclaimer: This study was supported by a research grant of the Research Institute of Rehabilitation Medicine, Yonsei University College of Medicine for 2018.

Conflict of interest: Each author certifies that he or she, or a member of his or her immediate family, has no commercial association (i.e., consultancies, stock ownership, equity interest, patent/licensing arrangements, etc.) that might pose a conflict of interest in connection with the submitted manuscript.

Manuscript received: 03-01-2019  
Revised manuscript received: 04-24-2019  
Accepted for publication: 04-26-2019

Free full manuscript:  
[www.painphysicianjournal.com](http://www.painphysicianjournal.com)

**Background:** We have applied a new method called “the pumping technique” to the capsule-preserving hydraulic distension for frozen shoulder. With this technique, the stretching effect can be directly applied to the joint capsule of the affected shoulder.

**Objectives:** We attempted to evaluate the effect of capsule-preserving hydraulic distension using the pumping technique by comparing capsule-preserving hydraulic distension without it.

**Study Design:** A case-controlled, retrospective, comparative study.

**Setting:** Outpatient clinic of department of rehabilitation medicine in a single university hospital.

**Methods:** Patients (n = 47) with frozen shoulder who were treated with hydraulic distension were assigned into the pumping group (n = 24) and the nonpumping group (n = 23). Range of motion (ROM), Shoulder Pain and Disability Index (SPADI), and Visual Analog Scale (VAS) scores were assessed.

**Results:** Significant improvement of VAS, ROM, and SPADI scores was observed after the second injection in each group ( $P < 0.05$ ). There were significant differences in total passive ROM, abduction, and flexion after the fifth injection between the 2 groups ( $P < 0.05$ ). There was a significant difference in the disability domain of SPADI after the second injection between the 2 groups ( $P < 0.05$ ). However, there was no significant interaction between time and group with respect to VAS scores. There were no serious complications after procedures.

**Limitations:** This was a retrospective study. There might be some limitations in gathering comprehensive records of outcome measurements. In addition, because the objective of this study was to determine the effect of the new pumping technique, included patients range was very narrow. This study only included patients who were treated 5 times with capsule-preserving hydraulic distensions with or without the pumping technique.

**Conclusions:** Although the effect on pain was excellent in both groups, the superiority of the new pumping technique was demonstrated by reduction of SPADI disability subscale score and improvement of ROM of the shoulder compared with the nonpumping technique.

**Key words:** Shoulder pain, injections, stretch, exercise, ultrasonography, joint capsule, steroids, range of motion

**Pain Physician 2019; 22:E563-E572**

**F**rozen shoulder is a common shoulder disease that causes shoulder pain and progressive limitation of shoulder motion. It affects 2% to 5% of the general population (1). It is known that 40% of patients with frozen shoulder not receiving suitable treatment suffer from continuous pain and limited range of motion (ROM), whereas 11% of these patients are known to suffer from permanent shoulder dysfunction (2). Although main treatment options for frozen shoulder include physical therapy, nonsteroidal antiinflammatory drugs, and intraarticular corticosteroid injection (3), the use of invasive approaches such as hydraulic distension is considered when a patient does not show improvement despite long-term conservative treatments (4).

Hydraulic distension for patients with frozen shoulder is known to expand a contracted and stiff glenohumeral joint capsule by infusing a large volume of injection fluid (5). It is one of the most commonly used procedures for frozen shoulder. It has been demonstrated to be more effective than physiotherapy or manipulation under anesthesia (6,7). In general, intraarticular capsule rupture is used as a common form of hydraulic distension. When hydraulic distension is performed to preserve capsules at the maximum volume, greater improvement in shoulder ROM and pain relief can be achieved than those seen after capsular rupture (8). In addition, most injection fluids of hydraulic distension are mixed with corticosteroids to enhance its effectiveness by quickly decreasing capsule inflammation (9,10).

One study has shown that stretching exercise can lead to fibrolytic process and release fibrous shoulder capsule (11). Although stretching exercise is one of the major treatments for frozen shoulder, its effects remain unclear. A recent review article has reported that a combination of manual therapy and exercise may not be as effective as glucocorticoid injection in the aspect of short-term effect for frozen shoulder (12). The reason why exercise is ineffective for frozen shoulder might be because it is difficult for patients with severe pain and limitation of shoulder motion to exercise enough to give direct mechanical load on the pathologic capsule of the shoulder joint. For this reason, we applied a new method called "the pumping technique" to capsule-preserving hydraulic distension. This new technique is simple and safe. Its stretching effect can be directly applied to joint capsule of the affected shoulder. The total number of hydraulic distensions has been set to be 5 for the purpose of maximizing the stretching effect of the pumping technique. Therefore, the objective of this study was to compare the effect of capsule-preserving

hydraulic distension using the pumping technique with capsule-preserving hydraulic distension without the pumping technique on frozen shoulder.

## **METHODS**

### **Study Patients**

This was a case-controlled, retrospective, comparative study. Before starting this study, the study protocol was approved by human subjects' review committee and our institutional review board (4-2018-0873). Patients' clinical charts were retrospectively reviewed. Informed consent for hydraulic distension procedure was obtained from each study patient in the department of rehabilitation medicine just before the procedure after explanation of the procedure, its probable complications, and available other therapies.

### **Patients**

This study included outpatients with frozen shoulder who underwent hydraulic distension in the outpatient clinic of department of rehabilitation medicine of a single university hospital between March 2013 and October 2018. Frozen shoulder was diagnosed by medical physical examination, radiologic image, and medical interview. Patients aged over 18 years and diagnosed with idiopathic frozen shoulder who had normal axillary and anteroposterior radiographs were included if they had symptoms that persisted at least 3 months, a 0 to 10 range Visual Analog Scale (VAS) score over 5, passive motion limitation  $> 30^\circ$  in  $\geq 2$  planes of movement (13), and a failure of physiotherapy course. To be eligible for this study, patient should also meet the following inclusion criteria: (1) underwent capsule-preserving hydraulic distension for a total of 5 times at intervals of 2 weeks; (2) underwent follow-up for 6 months after the last hydraulic distension; and (3) had not received any other treatment besides hydraulic distension.

Patients were excluded if they met the following criteria: (1) structural or systemic disorders, inflammatory arthritis disease, and radiographically proven osteoarthritis that led to ROM limitation or pain; (2) full thickness rotator cuff tendon tear in magnetic resonance imaging or ultrasonography; and (3) major trauma or history of surgery in shoulder. Patients were also excluded from this study if they had secondary frozen shoulder (secondary to other causes, including metabolic disorders, stroke, or cancer) or previous hydraulic distension. Flowchart of the selection process of study patients is presented in Fig. 1.

### Hydraulic Distension Procedure

Capsule-preserving intraarticular hydraulic distension was performed on the affected shoulders for all patients with or without the pumping technique. Ultrasound (US)-guided capsule-preserving intraarticular hydraulic distension methods have been previously reported (8,9). They were modified to be suitable for the pumping technique.

A physiatrist (S.C.L) with more than 10 years of experience in musculoskeletal ultrasonography performed US-guided hydraulic distension with a posterolateral approach. US equipment was an ACCUVIX V10 system (Medison Company Ltd., Gyeonggi-do, Republic of Korea) interfaced with a 5- to 12-MHz linear array transducer. Patient was in a lying position on the unaffected side with shoulder internally rotated, elbow flexed, wrist pronated, and hand on the opposite shoulder. Needle insertion under US-guidance was performed using both in-plane and out of plane methods depending on the situation.

Using aseptic technique, a 6-cm, 23-gauge needle was placed in the glenohumeral joint with verification of intraarticular position through ultrasonographic image. A mixture of 1 mL of triamcinolone (40 mg), 10 mL of local anesthetic (1% lidocaine), and 19 mL (0.9% NaCl) of normal saline solution (30 mL total) was prepared. The mixture solution was divided into 3 10-mL syringes. For the first syringe, 40 mg triamcinolone was added before the injection. The mixture of 30 mL was injected into the joint slowly with pressure while monitoring by ultrasonography to preserve the glenohumeral joint capsule and maximize the injected volume. When performing capsule-preserving hydraulic distension without the pumping technique, the injection was stopped at the point where no further expansion of the capsule was observed through ultrasonography (Fig. 2). The needle was then pulled out of the capsule, and the procedure was terminated. With the pumping technique, preservation of the joint capsule was the

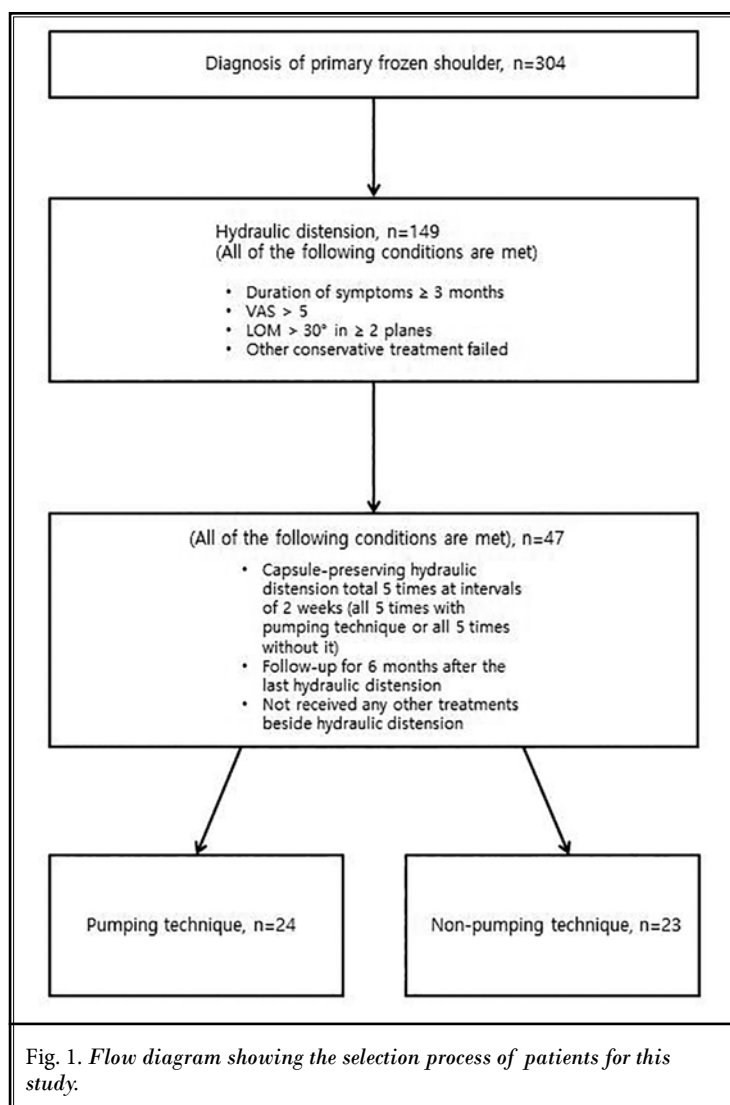
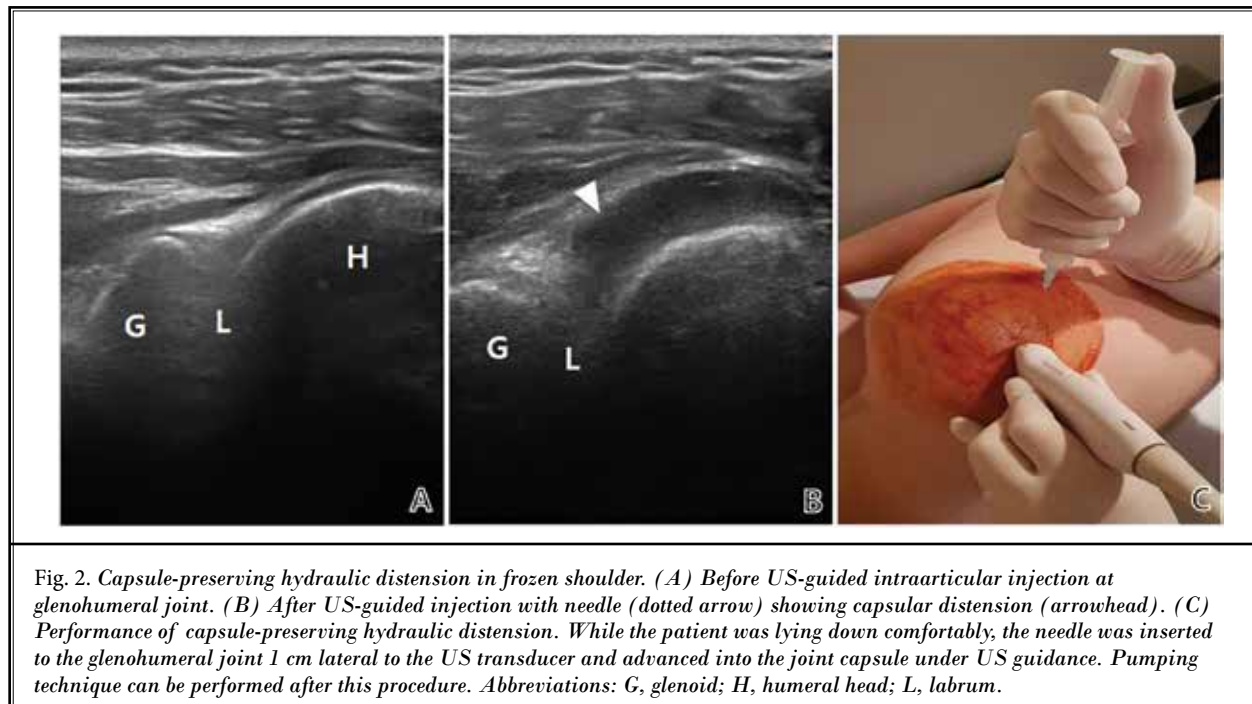


Fig. 1. Flow diagram showing the selection process of patients for this study.

same as the conventional method. When regurgitation occurred into the syringe as a result of increased intraarticular pressure during the procedure, the back flowed solution was pushed into the joint and the syringe was held for 10 seconds using the investigator's thumb (Video 1). In the next step, the investigator loosened the thumb and observed that the solution was refluxed into the syringe for about 10 seconds. The investigator repeated the same procedure 10 times. This pumping technique took approximately 5 minutes longer than the conventional method. During the procedure, suitable needle position in the articular space and distended capsule were monitored using US.

These injections were repeated a total of 5 times in 2-week intervals. Patients who had other treatments during hydraulic distension and follow-up period were excluded from this study.



However, self-exercise and behavior correction were allowed. Patients were instructed to perform exercise consisting of ROM and stretching exercise by themselves.

### Outcome Measurements

To evaluate treatment outcomes, passive ROM of shoulder in 3 directions (forward flexion, abduction, and external rotation), VAS score, and Shoulder Pain and Disability Index (SPADI) were measured. The same investigator (S.H.S) evaluated all outcome measurements.

Passive ROMs were measured while the patient was sitting upright. We used a goniometer to evaluate ROMs. Abduction, flexion, and external rotation ROMs were measured (8). VAS was used to measure the most severe ROM-associated shoulder pain in the past several days. VAS scores ranged from 0 ("no pain") to 10 ("the worst imaginable pain"). SPADI for patients with shoulder pain was a self-reporting questionnaire comprising 13 questions in 2 domains: pain domain (5 items) and disability domain (8 items) (13). Each domain score was evenly assessed and added to obtain a total percentage score from 0 (best) to 100 (worst).

Outcome measures were evaluated on the day of

the intervention, at 3 months, and at 6 months after the last intervention. On the day of hydraulic distension procedure, evaluation was performed just before the procedure. Total number of evaluations on the day of the procedures was 7. Occurrence of complications was checked on the same day. Using medical records, side effects were also assessed throughout the study period.

### Statistical Analyses

SPSS Version 24.0 software (IBM Corporation, Armonk, NY) was used for all statistical analyses. The Shapiro–Wilk test was used to analyze all continuous variables to determine whether the distribution was normal. All results showed normal distribution. Independent t test and repeated measures analysis of variance (ANOVA) were used to compare and analyze general characteristics of patients. Effects of hydraulic distension were evaluated using repeated measures ANOVA with time as a within-patients factor, and group (the pumping group and the nonpumping group) as a between-patients factor. Whenever the time or interaction was significant, a post hoc test with Bonferroni correction was performed. Statistical significance was recognized when  $P$  value was  $< 0.05$ .

## RESULTS

### Baseline Characteristics of Patients

All 47 patients were compatible with this study. There was no significant difference in general characteristics, passive ROMs, SPADI, or VAS scores between the 2 groups (Table 1).

### Changes in Passive ROM

In each group, passive total ROMs, abduction, flexion, and external rotation were significantly dependent on time by repeated measures ANOVA ( $P < 0.05$ ). In addition, significant improvement of passive total ROMs, abduction, flexion, and external rotation were observed from the time point of the second injection in each group ( $P < 0.05$ ). Repeated measures ANOVA showed a meaningful interaction of time with passive total ROMs, abduction, flexion, and external rotation in the pumping group and the nonpumping group ( $F(6,40) = 14.299$ ,  $P < 0.001$ ;  $F(6,40) = 6.245$ ,  $P = 0.001$ ;  $F(6,40) = 7.175$ ,  $P = 0.001$ ; and  $F(6,40) = 10.549$ ,  $P < 0.001$ , respectively). Post hoc test with Bonferroni correction showed significant difference in total passive ROMs, abduction, and flexion at the fifth injection, 3 months, and 6 months postprocedure between the 2 groups (all  $P < 0.05$ ). In addition, external rotation at

each time point from the third injection to 6 months postprocedure was significantly higher in the pumping group than that in the nonpumping group ( $P < 0.05$ ; Table 2, Fig. 3).

### Changes in SPADI

In each group, total score, pain domain, and disability domain of SPADI were significantly dependent on time by repeated measures ANOVA ( $P < 0.05$ ). Significant improvements in total score, pain domain, and disability domain of SPADI were observed from the time point of the second injection in each group ( $P < 0.05$ ). Repeated measure ANOVA showed no significant interaction between time and group with respect to total score and pain domain of SPADI. However, in disability domain of SPADI, repeated measure ANOVA showed a significant interaction between time and group ( $F(6,40) = 8.665$ ;  $P < 0.001$ ). Post hoc test with Bonferroni correction showed significant difference in the disability domain of SPADI at each time point from the second injection to 6 months postprocedure between the 2 groups ( $P < 0.05$ ; Table 2, Fig. 3).

### Changes in Shoulder Pain

In each group, VAS was significantly dependent on time by repeated measures ANOVA ( $P < 0.05$ ). Sig-

Table 1. Baseline characteristics of patients.

	Pumping Group (n = 24)	Nonpumping Group (n = 23)	P Value
Age	56.5 ± 6.6	55.4 ± 7.1	0.583
Gender (Male : Female)	6 : 18	7 : 16	0.752
Shoulder side (dominant : nondominant)	7 : 17	8 : 15	0.760
Duration of pain (months)	5.6 ± 1.1	6.1 ± 1.8	0.348
Body mass index	26.7 ± 3.3	27.2 ± 3.2	0.567
<b>Passive ROM</b>			
Sum of ROMs (°)	242.7 ± 31.3	244.8 ± 23.8	0.799
Flexion (°)	113.5 ± 14.6	115.7 ± 11.1	0.579
Abduction (°)	80.6 ± 19.1	80.2 ± 18.7	0.942
External rotation (°)	48.5 ± 6.7	48.9 ± 6.2	0.844
<b>SPADI</b>			
Total score	68.8 ± 10.3	70.2 ± 9.5	0.646
Shoulder pain	36.0 ± 8.3	36.5 ± 7.5	0.808
Shoulder disability	32.9 ± 3.2	33.7 ± 2.5	0.358
VAS	7.3 ± 1.1	7.3 ± 0.9	0.856

Table 2. Change of outcome measures.

	Group	Baseline (First Injection)	Second Injection	Third Injection	Fourth Injection	Fifth Injection	3 months	6 months
Passive range of motion (PROM)								
Sum of PROM	Pumping	242.7 ± 31.3	287.3 ± 41.6*	325.4 ± 31.3*	350.6 ± 38.7*	378.3 ± 39.7*	401.5 ± 35.6*	418.8 ± 18.6*
	NonPumping	244.8 ± 23.8	266.5 ± 31.3*	297.0 ± 42.3*	319.6 ± 41.2*	338.7 ± 35.9*	362.6 ± 28.6*	384.1 ± 21.0*
Flexion	Pumping	113.5 ± 14.6	134.0 ± 14.1*	148.8 ± 17.3*	157.9 ± 16.6*	166.3 ± 12.7*	172.3 ± 12.8*	176.5 ± 5.2*
	NonPumping	115.7 ± 11.1	125.2 ± 17.3*	140.9 ± 15.1*	149.3 ± 12.8*	154.3 ± 10.1*	161.1 ± 6.6*	167.8 ± 5.6*
Abduction	Pumping	80.6 ± 19.1	95.2 ± 24.1*	109.0 ± 21.2*	120.2 ± 22.9*	135.2 ± 23.5*	148.3 ± 20.6*	157.3 ± 13.6*
	NonPumping	80.2 ± 18.7	88.9 ± 21.2*	97.6 ± 25.0*	107.6 ± 25.7*	116.7 ± 23.4*	130.4 ± 19.0*	142.6 ± 12.7*
External rotation	Pumping	48.5 ± 6.7	58.1 ± 8.6*	67.7 ± 5.4*	72.5 ± 6.3*	76.9 ± 7.2*	80.8 ± 6.7*	85.0 ± 4.4*
	NonPumping	48.9 ± 6.2	52.4 ± 5.4*	58.5 ± 9.1*	62.6 ± 8.5*	67.6 ± 7.9*	71.1 ± 6.5*	73.7 ± 6.3*
SPADI								
Total score	Pumping	68.8 ± 10.3	49.7 ± 13.0*	39.0 ± 9.2*	30.6 ± 8.2*	24.3 ± 7.2*	23.5 ± 7.1*	22.9 ± 8.1*
	NonPumping	70.2 ± 9.5	53.5 ± 9.2*	43.9 ± 10.3*	34.9 ± 8.4*	29.7 ± 7.2*	28.5 ± 7.8*	27.8 ± 7.3*
Shoulder disability	Pumping	36.0 ± 8.3	21.6 ± 9.5*	14.8 ± 7.5*	12.0 ± 5.8*	8.5 ± 4.8*	9.9 ± 4.3*	11.0 ± 6.6*
	NonPumping	36.5 ± 7.5	21.9 ± 7.5*	15.4 ± 7.0*	12.7 ± 5.1*	8.8 ± 4.0*	10.6 ± 5.4*	11.8 ± 6.2*
Shoulder disability	Pumping	32.9 ± 3.2	28.1 ± 4.2*	24.3 ± 3.1*	18.6 ± 3.8*	15.8 ± 3.9*	13.6 ± 3.5*	11.9 ± 1.9*
	NonPumping	33.7 ± 2.5	31.6 ± 3.1*	28.4 ± 4.3*	22.3 ± 4.2*	20.8 ± 3.6*	18.0 ± 2.9*	16.0 ± 1.7*
VAS	Pumping	7.3 ± 1.1	4.0 ± 1.9*	2.6 ± 1.5*	2.1 ± 1.0*	1.4 ± 0.9*	1.7 ± 0.9*	1.9 ± 1.3*
	NonPumping	7.3 ± 0.9	4.1 ± 1.5*	2.7 ± 1.4*	2.3 ± 1.0*	1.5 ± 0.8*	1.9 ± 1.2*	2.0 ± 1.1*

nificant improvements of VAS were observed from the time point of the second injection in each group ( $P < 0.05$ ). However, there was no significant interaction between time and group with respect to VAS scores by repeated measure ANOVA (Table 2, Fig. 3).

### Complications Related to Procedures

There were no serious complications such as loss of sensation, motor control in the affected arm, infection, or symptoms attributable to side effects of hydraulic distension. However, some patients reported some side effects such as facial flushing (total  $n = 4$ : the pumping group,  $n = 2$ ; the nonpumping group,  $n = 2$ ), local depigmentation of the skin (the pumping group,  $n = 1$ ), and disturbance of the menstrual pattern (total  $n = 5$ : the pumping group,  $n = 2$ ; the nonpumping group,  $n = 3$ ).

### DISCUSSION

“The pumping technique” was designed to add the effect of stretching exercise on the joint capsule to conventional hydraulic distension. Therefore, the purpose of this study was to compare the effect of capsule-preserving hydraulic distension using the pumping tech-

nique with the effect of capsule-preserving hydraulic distension without using the pumping technique. Findings of this study indicated that hydraulic distension using the new pumping technique reduced SPADI disability subscale score after the second injection compared with the conventional capsule-preserving hydraulic distension. Such difference lasted up to 6 months after the last procedure. External rotation ROM of shoulder joints was further increased in the pumping group after the third injection compared with the nonpumping group. However, there was no significant difference in pain reduction between the 2 groups. Pain decreased in both groups after the second injection compared with that at baseline. Such pain-reduction effect was well maintained during the 6-month follow-up period.

SPADI consists of 13 items in 2 domains: pain (5 items) and disability (8 items). It has been validated in patients with frozen shoulder (14). There seems to be a statistically significant difference in SPADI disability subscale and ROMs of the shoulder between the pumping and nonpumping groups because there is a strong negative correlation between shoulder ROMs and SPADI disability subscale scores (15). It seems that SPADI disability score reflects the interaction of pain and

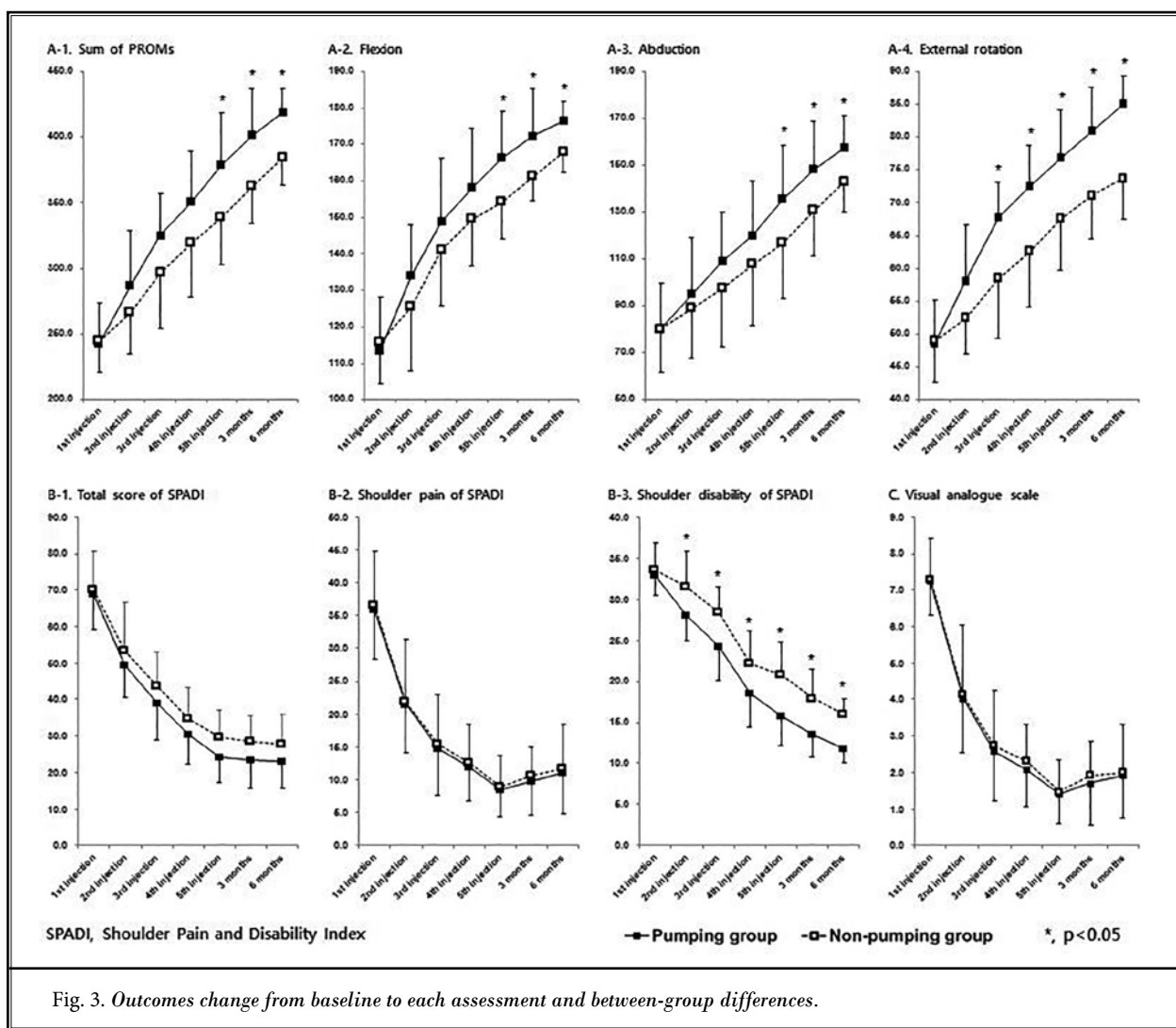


Fig. 3. Outcomes change from baseline to each assessment and between-group differences.

ROM. For pain intensity, no significant differences were found between the 2 groups because the nonpumping group also had sufficient pain reduction.

To apply the pumping technique to hydraulic distension, the joint capsule should not be ruptured during the procedure. Previous studies have shown that maintaining the maximum volume of the glenohumeral capsule through infusion of injection fluid is more effective than rupturing of the capsule in frozen shoulder patients (8,16). When the capsule is maintained rather than ruptured, it is possible to obtain an additional stretching effect of the old and fibrous soft tissue. In addition, steroid can remain in the intraarticular cavity due to capsule preservation. Moreover, most glenohumeral joint capsular ruptures during hydraulic disten-

sion occur in the subscapularis bursa, not in the actual pathologically fibrotic area (17-19).

The mechanism of the frozen shoulder remains unclear. However, it has been reported that maintaining normal joint capsule remodeling requires balance between matrix metalloproteinases (MMPs) and tissue inhibitors of matrix metalloproteinases (TIMPs), whereas MMP/TIMP balance disorder preferred by TIMP may cause fibroproliferative disease such as frozen shoulder (20,21). The increased MMP/TIMP ratio after intensive stretching exercise can facilitate fibrolytic process and lead to the release of fibrous shoulder capsule (22). It has been shown that stretching exercise can meaningfully reduce TIMP-1 and TIMP-2 levels and increase MMP-1 and MMP-2 levels (22). These results may sug-

gest that intensive stretching exercise can soften joint capsule fibrosis in patients with frozen shoulder by controlling MMP and TIMP balance. Stretching exercises consisting of forward elevation, external rotation, horizontal adduction, and internal rotation with each posture maintaining for 10 seconds within a tolerable pain range can maximize the stretching effect (23). However, it is difficult for a patient with frozen shoulder who has severe pain to perform stretching exercise effectively. Moreover, stretching exercise requires direct mechanical load on the pathological capsule of the shoulder joint to induce fibrolytic process and release the fibrotic shoulder capsule. It is practically impossible for patients with motion limitation and severe pain to exercise with such intensity (11). The pumping technique can effectively stretch the joint capsule by adding simple procedure to hydraulic distension. The extra time it takes to use the pumping technique is approximately 5 minutes. The total number of hydraulic distensions was set to be 5 for the purpose of maximizing the stretching effect of the pumping technique. Although the ideal number of hydraulic distensions with the pumping technique should be studied further, the use of corticosteroids in the same way as in the present study would limit the total number of hydraulic distensions.

In this study, hydraulic distension was performed 5 times per patient. Therefore, 40 mg of triamcinolone was also administered 5 times every 2 weeks. The true effect of hydraulic distension is uncertain because hydraulic distension is mostly combined with corticosteroid (24). Considering that little has been reported about therapeutic effect and side effects of steroids in hydraulic distension, the description of steroid efficacy and side effects in frozen shoulder can be found primarily in the literature on intraarticular corticosteroid injection. A higher dose of corticosteroids may increase the incidence of local and general complications. However, in a systemic review regarding effectiveness of corticosteroid injections in frozen shoulder, no serious steroid-related complications have been reported in patients receiving high doses (25). In our study, there were no critical complications such as infections other than facial flushing, local depigmentation of the skin, and disturbance of the menstrual pattern, although patients with endocrine abnormalities or other serious systemic diseases were excluded. A previous systematic review has shown that although corticosteroid injection can deliver rapid short-term pain relief and improve function (in the first 6 weeks), it is not superior to placebo in the aspect of long-term treatment (26).

A recent study has indicated that increased prevalence of myofibroblast staining in patients with frozen shoulder might mean activation of the myofibroblast in the pathophysiology of capsular contracture, and that intraarticular corticosteroid injection can decrease the presence or amount of fibromatosis, fibrosis, vascular hyperplasia, and fibroblasts (27). This supports that the use of corticosteroid injections may change the course of the disease by reducing pathological changes found in frozen shoulder capsules. A clear conclusion about the long-term effect of corticosteroid injection is difficult to make due to diverse findings of related studies. However, corticosteroid dose used in previous studies is likely to be insufficient to alter the disease process (25,28,29). It is worthwhile to administer a sufficient amount of corticosteroid at the same time when performing hydraulic distension if corticosteroid injections may help normalize pathologically thickened capsule. Corticosteroid is effective in patients with severe joint limitation, as well as in the initial state of frozen shoulder. However, this should be preceded by a study on the appropriate number of hydraulic distensions and steroid dose to minimize side effects and maximize the effectiveness of hydraulic distension.

Some limitations should be pointed out when interpreting our findings. First, this was a retrospective study. Despite authors' efforts, there might be some limitations in gathering comprehensive records of outcome measurements. Nevertheless, we used sufficient follow-up period (6 months) to analyze effects of hydraulic distension with comparable baseline characteristics (gender, age, duration of symptoms, and so on) between the 2 groups. Second, unrecognized confounders might have affected outcomes because this study was an unmatched case-controlled study. Third, the impact of the pumping technique on the capsule of the shoulder joint was not confirmed by imaging or histological examination. Finally, because the objective of this study was to determine the effect of the new pumping technique, included patients range was very narrow. Only idiopathic frozen shoulder patients were included in this study. Results were not obtained for various patients. This study only included patients who were treated 5 times with capsule-preserving hydraulic distensions with or without the pumping technique. In the future, prospective studies should be carried out on appropriate number of hydraulic distensions, corticosteroid dose, and the number of pumping in a large number of patients with frozen shoulders. In particular, it is necessary to compare effects of new hydraulic dis-



tension method with conventional hydraulic distension and stretching exercise.

## CONCLUSIONS

Although the effect on pain reduction was excellent in both groups, the superiority of the new pumping technique was demonstrated by better reduction in SPADI disability subscale score, and better improvement of ROM of the shoulder compared with the non-pumping technique. A new pumping technique that strengthens the stretching effect on existing hydraulic distension is safe. However, prospective randomized controlled trials are needed to further demonstrate the effect of this new "pumping technique," and overcome limitations of this study mentioned in the discussion.

## Acknowledgments

Author contributions: Yong Wook Kim: study concept and design, analysis and interpretation of data, statistical analysis, drafting of the manuscript; Sanghoon Shin: study concept and design, analysis and interpretation of data, statistical analysis, drafting of the manuscript; Won Hyuk Chang: acquisition of data, analysis and interpretation of the method results; and Sang Chul Lee: study concept and design, study supervision, critical revision of the manuscript for important intellectual content. All the authors have read the manuscript.

## REFERENCES

- Zuckerman JD, Rokito A. Frozen shoulder: A consensus definition. *J Shoulder Elbow Surg* 2011; 20:322-325.
- Alptekin HK, Aydin T, Iflazoglu ES, Alkan M. Evaluating the effectiveness of frozen shoulder treatment on the right and left sides. *J Phys Ther Sci* 2016; 28:207-212.
- Russell S, Jariwala A, Conlon R, Selfe J, Richards J, Walton M. A blinded, randomized, controlled trial assessing conservative management strategies for frozen shoulder. *J Shoulder Elbow Surg* 2014; 23:500-507.
- Park KD, Nam HS, Lee JK, Kim YJ, Park Y. Treatment effects of ultrasound-guided capsular distension with hyaluronic acid in adhesive capsulitis of the shoulder. *Arch Phys Med Rehabil* 2013; 94:264-270.
- Koh ES, Chung SG, Kim TU, Kim HC. Changes in biomechanical properties of glenohumeral joint capsules with adhesive capsulitis by repeated capsule-preserving hydraulic distensions with saline solution and corticosteroid. *PM R* 2012; 4:976-984.
- Buchbinder R, Green S, Youd JM. Corticosteroid injections for shoulder pain. *Cochrane Database Syst Rev* 2003; CD004016.
- Quraishi NA, Johnston P, Bayer J, Crowe M, Chakrabarti AJ. Thawing the frozen shoulder. A randomised trial comparing manipulation under anaesthesia with hydrodilatation. *J Bone Joint Surg Br* 2007; 89:1197-1200.
- Kim K, Lee KJ, Kim HC, Lee KJ, Kim DK, Chung SG. Capsule preservation improves short-term outcome of hydraulic distension in painful stiff shoulder. *J Orthop Res* 2011; 29:1688-1694.
- Lee JH, Kim SB, Lee KW, Lee SJ, Lee JU. Effect of hypertonic saline in intra-articular hydraulic distension for adhesive capsulitis. *PM R* 2015; 7:721-726.
- Tveita EK, Tariq R, Sesseng S, Juel NG, Bautz-Holter E. Hydrodilatation, corticosteroids and adhesive capsulitis: A randomized controlled trial. *BMC Musculoskelet Disord* 2008; 9:53.
- Blain EJ. Mechanical regulation of matrix metalloproteinases. *Front Biosci* 2007; 12:507-527.
- Page MJ, Green S, Kramer S, et al. Manual therapy and exercise for adhesive capsulitis (frozen shoulder). *Cochrane Database Syst Rev* 2014; CD011275.
- Buchbinder R, Green S, Forbes A, Hall S, Lawler G. Arthrographic joint distension with saline and steroid improves function and reduces pain in patients with painful stiff shoulder: Results of a randomised, double blind, placebo controlled trial. *Ann Rheum Dis* 2004; 63:302-309.
- MacDermid JC, Solomon P, Prkachin K. The shoulder pain and disability index demonstrates factor, construct and longitudinal validity. *BMC Musculoskelet Disord* 2006; 7:12.
- Hill CL, Lester S, Taylor AW, Shanahan ME, Gill TK. Factor structure and validity of the shoulder pain and disability index in a population-based study of people with shoulder symptoms. *BMC Musculoskelet Disord* 2011; 12:8.
- Lee SY, Lee KJ, Kim W, Chung SG. Relationships between capsular stiffness and clinical features in adhesive capsulitis of the shoulder. *PM R* 2015; 7:1226-1234.
- Ibrahim T, Rahbi H, Beiri A, Jeyapalan K, Taylor GJ. Adhesive capsulitis of the shoulder: The rate of manipulation following distension arthrogram. *Rheumatol Int* 2006; 27:7-9.
- Amoretti N, Grimaud A, Brocq O, et al. Shoulder distension arthrography in adhesive capsulitis. *Clin Imaging* 2006; 30:254-256.
- Rizk TE, Gavant ML, Pinals RS. Treatment of adhesive capsulitis (frozen shoulder) with arthrographic capsular distension and rupture. *Arch Phys Med Rehabil* 1994; 75:803-807.
- Mandal M, Mandal A, Das S, Chakraborti T, Sajal C. Clinical implications of matrix metalloproteinases. *Mol Cell Biochem* 2003; 252:305-329.
- Wynn TA. Common and unique mechanisms regulate fibrosis in various fibroproliferative diseases. *J Clin Invest* 2007; 117:524-529.
- Lubis AM, Lubis VK. Matrix metalloproteinase, tissue inhibitor of metalloproteinase and transforming growth factor-beta 1 in frozen shoulder, and

- their changes as response to intensive stretching and supervised neglect exercise. *J Orthop Sci* 2013; 18:519-527.
23. Griggs SM, Ahn A, Green A. Idiopathic adhesive capsulitis. A prospective functional outcome study of nonoperative treatment. *J Bone Joint Surg Am* 2000; 82:1398-1407.
24. Saltychev M, Laimi K, Virolainen P, Fredricson M. Effectiveness of hydrodilatation in adhesive capsulitis of shoulder: A systematic review and meta-analysis. *Scand J Surg* 2018; 107:285-293.
25. Noerdlinger MA, Fadale PD. The role of injectable corticosteroids in orthopedics. *Orthopedics* 2001; 24:400-405; quiz 406-407.
26. Sun Y, Zhang P, Liu S, et al. Intra-articular steroid injection for frozen shoulder: A systematic review and meta-analysis of randomized controlled trials with trial sequential analysis. *Am J Sports Med* 2017; 45:2171-2179.
27. Hettrich CM, DiCarlo EF, Faryniarz D, Vadasdi KB, Williams R, Hannafin JA. The effect of myofibroblasts and corticosteroid injections in adhesive capsulitis. *J Shoulder Elbow Surg* 2016; 25:1274-1279.
28. Skedros JG, Hunt KJ, Pitts TC. Variations in corticosteroid/anesthetic injections for painful shoulder conditions: Comparisons among orthopaedic surgeons, rheumatologists, and physical medicine and primary-care physicians. *BMC Musculoskelet Disord* 2007; 8:63.
29. Yoon SH, Lee HY, Lee HJ, Kwack KS. Optimal dose of intra-articular corticosteroids for adhesive capsulitis: A randomized, triple-blind, placebo-controlled trial. *Am J Sports Med* 2013; 41:1133-1139.