

## Retrospective Analysis

# e A Novel Method of Locating Foramen Ovale for Percutaneous Approaches to the Trigeminal Ganglion

Kang Sup Kim, MD, PhD<sup>1</sup>, Sung Hyun Lee, MD<sup>2</sup>, Seong Chul Lee, MD<sup>3</sup>,  
So Yeon Lee, MD, PhD<sup>3</sup>, Pyoung On Kim, MD<sup>2</sup>, Misuk Lee, MD<sup>2</sup>, and Kyoung-Ho Ryu, MD<sup>2</sup>

From: <sup>1</sup>Department of Urology, The Catholic University of Korea, Incheon St. Mary's Hospital, Incheon, Korea; <sup>2</sup>Department of Anesthesiology and Pain Medicine, Kangbuk Samsung Hospital, Sungkyunkwan University School of Medicine, Seoul, Korea; <sup>3</sup>Department of Radiology, Kangbuk Samsung Hospital, Sungkyunkwan University School of Medicine, Seoul, Korea

Address Correspondence:  
Sung Hyun Lee, MD  
Department of Anesthesiology and Pain Medicine, Kangbuk Samsung Hospital, Sungkyunkwan University School of Medicine  
29 Saemooan-ro, Gonro-gu Seoul 03181, Republic of Korea  
E-mail: 4321hoho@naver.com

Disclaimer: Sung Hyun Lee and Kang Sup Kim contributed equally to this study and should be considered co-first authors.  
Conflict of interest: Each author certifies that he or she, or a member of his or her immediate family, has no commercial association (i.e., consultancies, stock ownership, equity interest, patent/licensing arrangements, etc.) that might pose a conflict of interest in connection with the submitted manuscript.

Manuscript received: 08-12-2018  
Revised manuscript received: 12-21-2018  
Accepted for publication: 02-15-2019

Free full manuscript:  
[www.painphysicianjournal.com](http://www.painphysicianjournal.com)

**Background:** For patients with trigeminal neuralgia who do not respond to medication and for whom surgical approaches are too risky, percutaneous procedures targeting the trigeminal ganglion are the current standard treatment. Percutaneous procedures are performed via the transoval approach under radiologic guidance. Identification of the foramen ovale (FO) under fluoroscopic guidance is an important part of determining the success or failure of the procedures.

**Objectives:** Previous studies have described how to visualize the FO under fluoroscopic guidance, but those methods are limited by poor reproducibility. In this study, we have investigated how to visualize the FO clearly and easily under fluoroscopic guidance.

**Study Design:** Retrospective analysis.

**Setting:** University hospital in Korea.

**Methods:** Seventy-two 3-dimensional facial computed tomography scans without anatomic abnormalities of the skull base were analyzed for verifying the novel method. First, the mandibular angle and the occipital cortical line were overlapped and then turned by 15° oblique rotation using the software package. After these manipulations, the visualization of the FO was graded according to a 4-point scale (0: poor; 1: fair; 2: good; 3: excellent), and the inferior transfacial and oblique angles were measured.

**Results:** This enabled clear visualization of the FO. The mean visual grade of 54 right and 46 left FO (total 100) was 2.74 (0: poor; 1: fair; 2: good; 3: excellent). All recorded FOs had at least grade 2 visibility.

**Limitations:** This study is lacking application in clinical practice and comparative data to the submental view.

**Conclusions:** The mandible angle and the occipital cortex line are obvious anatomic landmarks and are visible even to nonexperienced practitioners. Therefore, our method using these anatomic landmarks can improve the reproducibility and accuracy of FO visualization.

**Key words:** Trigeminal neuralgia, foramen ovale, trigeminal ganglion, 3-dimensional (3D) facial computed tomography (CT) scans

**Pain Physician 2019; 22:E345-E350**

The most common cause of paroxysmal facial pain is trigeminal neuralgia (TN). Treatment of TN is multimodal, with medication as the first choice of treatment. Percutaneous treatments can be considered when medication must be discontinued because of unacceptable side effects or refractory pain. Percutaneous treatments are minimally invasive methods and include blocking the trigeminal

ganglion, destroying the trigeminal fibers via thermal radiofrequency ablation, microcompression with a Fogarty catheter, applying neurolytic substances (glycerol, alcohol), trigeminal ganglion balloon decompression, and pulsed radiofrequency treatment (1-5). Percutaneous techniques result in a relative high rate of short-term pain relief. The long-term effects are variable across studies. However, because of low morbidity and mortality, the procedures can be performed with relative ease. In particular, these procedures can be considered valuable treatment options for patients in whom a surgical approach is considered too risky (1,6). Percutaneous procedures are conducted through a puncture of the foramen ovale (FO). Taking into account the anatomic structure, it has been proposed that the FO can be identified by aligning the fluoroscope between the coronoid process of the lateral mandible and the medial maxilla just above the petrous ridge (7,8). The FO visualization with a fluoroscope is rarely described as being reproducible and accurate. Several studies suggest that the submental view can be aligned with the view used for FO visualization (9-11). However, the submental view actually refers to a modification of the submental-vertex view in the existing imaging techniques; this modification has not been described in the previous studies. The orbitomeatal line, presented as a baseline, is also ambiguous because of variability in patient positioning (12,13), because the literature reports a wide range of angles. The reason for which may be owing to the variability of head and neck retroflexion (14). The lack of reproducibility in fluoroscopic visualization of the FO means that the amount of radiation exposure is increased for the patient as well as the practitioner. For the success or failure of the procedure, FO visualization is critical. Considering the adjacent distances between the puncture site used for the percutaneous approach to the carotid artery and sinus cavernosus, more sophisticated adjustments are needed to find the puncture site. The accidental puncture of adjacent anatomic structures such as the carotid artery has been reported to potentially elicit fistula formation in the sinus cavernosus (15,16). The objective of this article is to provide reproducible and reliable anatomic landmarks for optimal FO visualization.

## METHODS

### Study Design

To determine anatomic-radiologic landmarks for

FO visualization, 3-dimensional (3D) facial computed tomography (CT) examinations were reviewed. The use of 3D facial CT scans was approved by the institutional review board of Kang Buk Samsung Hospital, Seoul, Korea (KBSMC-20180-07-017). Seventy-two 3D facial CT scans without skull base anatomic anomalies were included in the study. Instead of using the orbitomeatal line, which is the ambiguous line commonly proposed for fluoroscopic visualization of the FO, the occipital cortex line and the ipsilateral mandibular angle were aligned. Both landmarks are readily distinguishable from one another. Extended Brilliance Workspace Version 4.5.6.52040 software (Koninklijke Philips N.V., Amsterdam, Netherlands) was used to superimpose the 2 anatomic landmarks in the 3D facial CT scans. The images were rotated obliquely by 15° to the ipsilateral side (Fig. 1A, B). After performing these manipulations, the ease of the FO visualization was graded according to a 4-point scale in which 0: poor; 1: fair; 2: good; and 3: excellent (17). The inferior transfacial and oblique angles were then measured. The visualization of the FO was graded separately by one musculoskeletal radiologist having 10 years of experience and one pain physician having 6 years of experience. The axial images were reviewed to precisely identify the positions of the FO, the foramen rotundum, and the foramen spinosum because these structures are located in close proximity to one another. After marking the foramen identified as the FO, the marks were displayed in accordance with the foraminal location as identified on the axial CT view (Fig. 2).

### Statistics

The data are presented as the mean  $\pm$  standard error of the mean. The kappa statistic (or kappa coefficient) is most often used to assess the interobserver reliability. A kappa of 1 indicates perfect agreement, whereas a kappa of 0 indicates chance agreement.

## RESULTS

### Quality of Visualization of the FO

One hundred FO (54 right and 46 left) of 72 3D facial CT scans were analyzed. Considering that TN occurs mainly in patients aged  $>50$  years, only facial CT scans of patients in this age group were included. {AU: Please confirm edits in the previous sentence}The mean age of the analyzed patients was  $67.4 \pm 11.4$  years. Visibility of the FO was graded according to a 4-point scale discussed earlier. Seventy-two of the 100 scans were

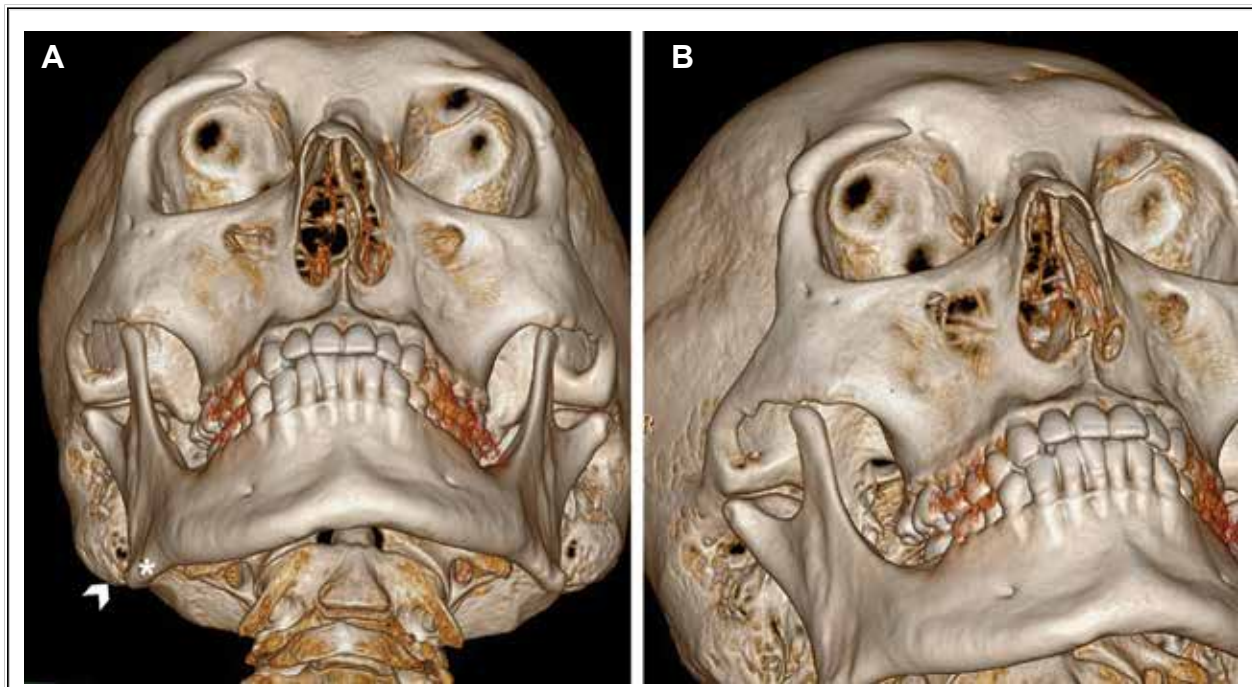


Fig. 1. (A) 3D facial CT scan with overlap of the mandibular angle (asterisk) and the occipital cortical line (arrowhead). (B) 3D facial CT image: The mandible angle and the occipital cortex line were overlapped and turned obliquely to achieve best view of the FO.

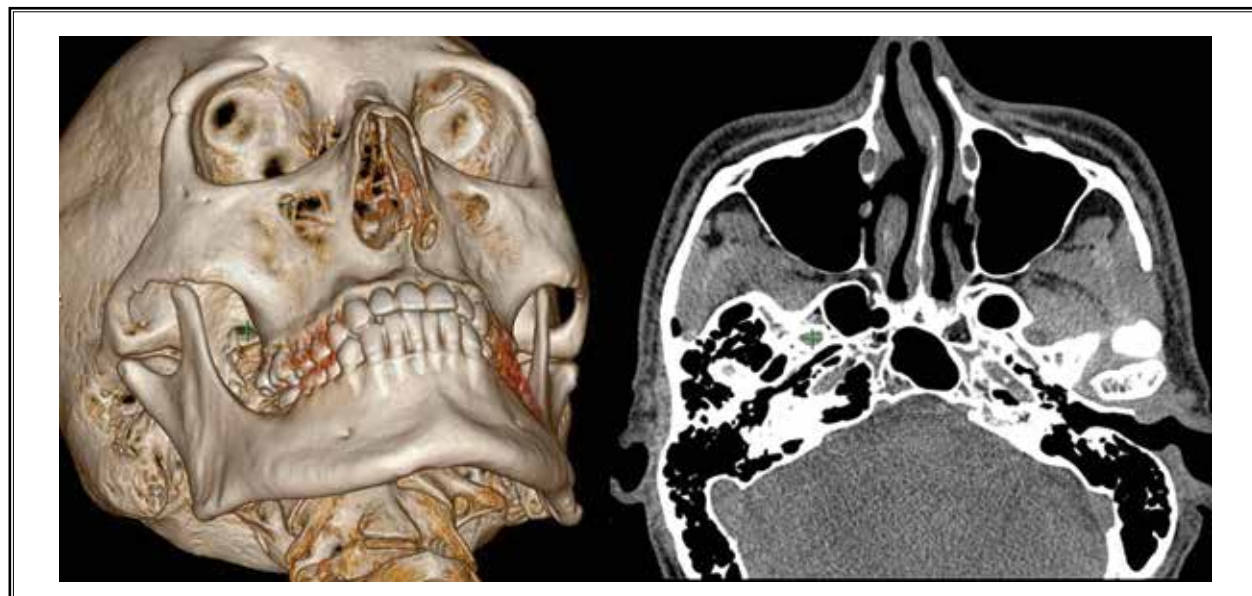

Fig. 2. After marking the hole identified as the FO with “+,” this mark is visualized in the axial view.

assessed as having grade 3 visibility, 28 scans were assessed as having grade 2 visibility according to observer 1. Seventy-five of the 100 scans were assessed as hav-

ing grade 3 visibility, 25 scans were assessed as having grade 2 visibility according to observer 2. No CT scan displayed grade 0 or grade 1 visibility. The mean visual

grade of the 2 observer's data was 2.74. The kappa was 0.83, which is in the "almost perfect" interobserver agreement range. Therefore, aligning the 2 anatomic landmarks of the occipital cortical line and mandibular angles is a useful method to consistently identify the FO.

### Measurement of the Inferior Transfacial and Oblique Angles

One hundred FO of 72 3D facial CT scans were analyzed. The inferior transfacial angle of the FO was within 37° and 55°. The mean of transfacial angle was  $45.76 \pm 5.19^\circ$ . The oblique angle of the FO was 15°, as intended.

### Clinical Application

Three patients with TN underwent pulsed radiofrequency treatment of the Gasserian ganglion using our new technique for localization of the FO. Two patients had right-sided TN and one patient had TN on the left side. The patients were positioned supine on the x-ray table with their head and neck comfortably lying straight without any retroflexion. The symptomatic FO side was fluoroscopically identified by rotating the x-ray tube in the sagittal plane until the mandibular angle and the ipsilateral occipital cortical line overlapped. The fluoroscope was then rotated in the coronal plane for better visualization of the FO (Fig. 3). The FO was

identified, and the needle entry site and trajectory were determined without the need for repetitive fluoroscopic imaging.

### DISCUSSION

Percutaneous interventional therapy targeting the trigeminal ganglion and its branches have proven to be effective management of TN. These procedures have been performed by accessing the FO under fluoroscopic guidance. Therefore, one key factor in determining the success of the procedure is the visualization of the FO. The most common fluoroscopic method for visualization of the FO uses the submental view. Although previous studies have described performing the procedure using the submental view, there has been no detailed description of how to obtain that view (9-11) apart from a rough description that the x-ray tube should be tilted in the caudocephalic direction. No accurate anatomic landmarks have been discussed, and the angles were not consistent between the studies. The inferior transfacial angle of the submental view varies between 15° and 70°. If the procedure is performed using the submental view, the patient is most likely positioned supine with their head and neck retroflexed to variable degrees. Additionally, the submental view only provides an approximate orientation of the FO, and the reproducibility is limited. The ability to visualize the FO can vary greatly depending on the experience of the

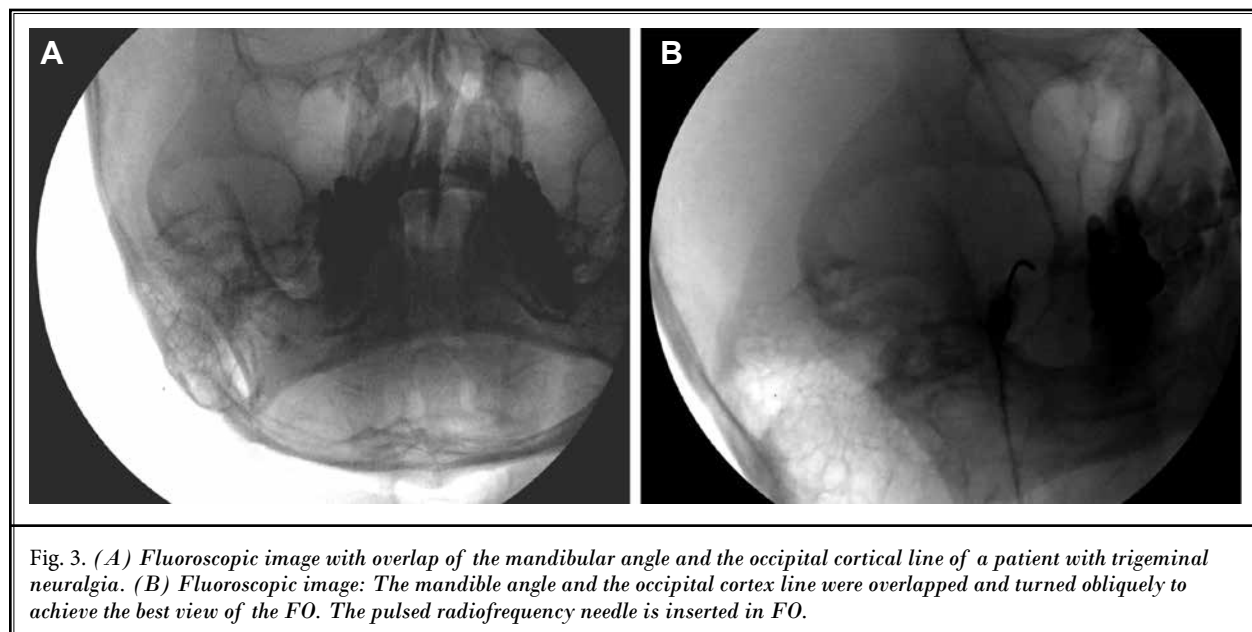


Fig. 3. (A) Fluoroscopic image with overlap of the mandibular angle and the occipital cortical line of a patient with trigeminal neuralgia. (B) Fluoroscopic image: The mandible angle and the occipital cortex line were overlapped and turned obliquely to achieve the best view of the FO. The pulsed radiofrequency needle is inserted in FO.

interventionalist. Alternative methods have been suggested using anatomic landmarks. Some studies have suggested using the orbitomeatal line, the mid-cranial fossa arc, and the petrous ridge line (18-20). However, the orbitomeatal line, the mid-cranial fossa arc, and the petrous ridge line are too difficult to identify to be used as reliable anatomic landmarks. The orbitomeatal line varies and depends on patient positioning. In this study, we propose a method to visualize the FO based on structures that are readily distinguishable: the mandibular angle and the occipital cortical line. Both landmarks are independent of the caudocephalic angle of the x-ray tube and the degree of head and neck flexion. The key is to simply overlap the occipital line with the mandibular angle. Following this, the x-ray tube should be obliquely rotated approximately 15° until the FO is clearly delineated. This method is simple for even the less experienced interventionalist. In addition, because the patient does not need to have their head and neck flexed, the procedure is more comfortable.

To determine the accuracy and clinical applicability of this method, we used 3D facial CT scans without skull base abnormalities that had been obtained previously. We did not subject our patients to additional radiation by repeating their CT examination. However, our confirmation with 3D facial CTs for this study does not imply a need for intraoperative or perioperative CT guidance. We used the patient's 3D facial CT for the study only to confirm the use and accuracy of our novel method. The superimposition of the mandibular angle and occipital cortical line with 15° rotation for visualization of the FO that we initially performed via CT using Extended Brilliance Workspace software, can be easily performed with fluoroscopy. Indeed, FO margins that were partially obscured with CT were better evaluated

under fluoroscopy due to direct beam targeting. Extended Brilliance Workspace software allows accurate axial view confirmation distinguishing the adjacent foramina like the foramen spinosum.

The limitations of this study are the lack of sufficient clinical data using this novel approach in the treatment of TN, and the lack of comparing the accuracy of our technique to that of the established approach using the submental view. These limitations may be addressed in the future considering that treatment of TN at our institution will be performed using our new technique.

## **CONCLUSIONS**

In this study, we described a novel method for identifying the FO during percutaneous procedures based on anatomic landmarks. High recognizability of these landmarks enables the high reproducibility of this approach.

## **Acknowledgments**

Author contributions: S.H.L was involved in the conception, literature search, study design, data collection, analysis and interpretation, editing and writing of the manuscript. K.S.K was involved in the conception, literature search, study design, data analysis and interpretation, editing and writing of the manuscripts. S.C.L was involved in manipulating the software, data collection, and analysis. S.Y.L was involved in analysis and interpretation. P.Y.K was involved in the literature search and editing of the manuscript. M.S.L was involved in the literature search, and data collection. K.H.R was involved in the conception, literature search. All authors discussed the results and commented on the manuscript and approved the version to be published.

## REFERENCES

- Missios S, Mohammadi AM, Barnett GH. Percutaneous treatments for trigeminal neuralgia. *Neurosurg Clin N Am* 2014; 25:751-762.
- Khan M, Nishi SE, Hassan SN, Islam MA, Gan SH. Trigeminal neuralgia, glossopharyngeal neuralgia, and myofascial pain dysfunction syndrome: An update. *Pain Res Manag* 2017; 2017:7438326.
- Maarbjerg S, Di Stefano G, Bendtsen L, Cruccu G. Trigeminal neuralgia: Diagnosis and treatment. *Cephalalgia* 2017; 37:648-657.
- Han KR, Chae YJ, Lee JD, Kim C. Trigeminal nerve block with alcohol for medically intractable classic trigeminal neuralgia: Long-term clinical effectiveness on pain. *Int J Med Sci* 2017; 14:29-36.
- Wang JY, Bender MT, Bettegowda C. Percutaneous procedures for the treatment of trigeminal neuralgia. *Neurosurg Clin N Am* 2016; 27:277-295.
- Tatli M, Satici O, Kanpolat Y, Sindou M. Various surgical modalities for trigeminal neuralgia: Literature study of respective long-term outcomes. *Acta Neurochir (Wien)* 2008; 150:243-255.
- Whisler WW, Hill BJ. A simplified technique for injection of the Gasserian ganglion, using the fluoroscope for localization. *Neurochirurgia (Stuttg)* 1972; 15:167-172.
- Gusmao S, Oliveira M, Tazinaffo U, Honey CR. Percutaneous trigeminal nerve radiofrequency rhizotomy guided by computerized tomography fluoroscopy. Technical note. *J Neurosurg* 2003; 99:785-786.
- Chua NH, Halim W, Beems T, Vissers KC. Pulsed radiofrequency treatment for trigeminal neuralgia. *Anesth Pain Med* 2012; 1:257-261.
- van Kleef M, van Genderen WE, Narouze S, Nurmikko TJ, van Zundert J, Geurts JW, Mekhail N; World Institute of Medicine. 1. Trigeminal neuralgia. *Pain Pract* 2009; 9:252-259.
- Vorenkamp KE. Interventional procedures for facial pain. *Curr Pain Headache Rep* 2013; 17:308.
- Gerber AM. Improved visualization of the foramen ovale for percutaneous approaches to the gasserian ganglion. Technical note. *J Neurosurg* 1994; 80:156-159.
- Nie F, Su D, Shi Y, Chen J, Wang H, Chen Y, Qin W, Wang S. A prospective study of x-ray imaging combined with skin stimulation potential-guided percutaneous radiofrequency thermocoagulation of the Gasserian ganglion for treatment of trigeminal neuralgia. *Pain Med* 2014; 15:1464-1469.
- Grunert P, Glaser M, Kockro R, Boor S, Oertel J. An alternative projection for fluoroscopic-guided needle insertion in the foramen ovale: Technical note. *Acta Neurochir (Wien)* 2010; 152:1785-1792.
- Gatto LAM, Tacla R, Koppe GL, Junior ZD. Carotid cavernous fistula after percutaneous balloon compression for trigeminal neuralgia: Endovascular treatment with coils. *Surg Neurol Int* 2017; 8:36.
- Langford P, Holt ME, Danks RA. Cavernous sinus fistula following percutaneous balloon compression of the trigeminal ganglion. Case report. *J Neurosurg* 2005; 103:176-178.
- Park HJ, Lee SY, Chung EC, Rho MH, Ahn JH, Kim MS, Park JY, Lee EJ. The usefulness of the oblique coronal plane in knee MRI on the evaluation of the posterior cruciate ligament. *Acta Radiol* 2014; 55:961-968.
- Tator CH, Rowed DW. Fluoroscopy of foramen ovale as an aid to thermocoagulation of the Gasserian ganglion; Technical note. *J Neurosurg* 1976; 44:254-257.
- He YQ, He S, Shen YX. Application of a new method of revealing foramen ovale under x-ray in radiofrequency ablation in the treatment of trigeminal neuralgia. *Br J Neurosurg* 2011; 25:674-676.
- Peris-Celda M, Graziano F, Russo V, Mericle RA, Ulm AJ. Foramen ovale puncture, lesioning accuracy, and avoiding complications: Microsurgical anatomy study with clinical implications. *J Neurosurg* 2013; 119:1176-1193.