

## Observational Study

# Transforaminal Endoscopic Lumbar Discectomy Versus Open Lumbar Microdiscectomy: A Comparative Cohort Study with a 5-Year Follow-Up

Yong Ahn, MD, PhD<sup>1</sup>, Sang Gu Lee, MD, PhD<sup>1</sup>, Seong Son, MD<sup>1</sup>,  
and Han Joong Keum, MD<sup>2</sup>

From: <sup>1</sup>Department of Neurosurgery, Gil Medical Center, Gachon University College of Medicine, Incheon, South Korea; <sup>2</sup>Department of Neurosurgery, Wooridul Spine Hospital, Seoul, South Korea

Address Correspondence:  
Yong Ahn, MD, PhD  
Department of Neurosurgery  
Gil Medical Center  
Gachon University College of  
Medicine  
21, Namdong-daero 774 beon-gil  
Namdong-gu, Incheon, 21565  
Republic of Korea  
E-mail: ns-ay@hanmail.net

Disclaimer: There was no external funding in the preparation of this manuscript.  
Conflict of interest: Each author certifies that he or she, or a member of his or her immediate family, has no commercial association (i.e., consultancies, stock ownership, equity interest, patent/licensing arrangements, etc.) that might pose a conflict of interest in connection with the submitted manuscript.

Manuscript received: 07-01-2018  
Revised manuscript received:  
10-31-2018  
Accepted for publication:  
11-05-2018

Free full manuscript:  
[www.painphysicianjournal.com](http://www.painphysicianjournal.com)

**Background:** Transforaminal endoscopic lumbar discectomy (TELD) is regarded as an effective treatment option for soft lumbar disc herniation (LDH). There have been few studies evaluating the long-term outcomes of endoscopic procedures compared with conventional surgery.

**Objectives:** The objective of this study was to demonstrate the clinical outcomes of TELD compared with those of open lumbar microdiscectomy.

**Study Design:** Between January 2009 and September 2011, 335 consecutive patients with symptomatic LDH were treated with decompressive discectomy, either TELD or open microdiscectomy. Patients were prospectively entered into the clinical database and their records were retrospectively reviewed.

**Setting:** Hospital and outpatient surgical center.

**Methods:** Data from 298 patients who were treated with decompressive discectomy, either TELD or open microdiscectomy, were evaluated with a minimum 5-year follow-up period. Among them, 146 patients were treated using TELD (TELD group), and the remaining 152 patients using open microdiscectomy (Open group). Perioperative data and clinical outcomes were evaluated using the visual analog scale (VAS), the Oswestry Disability Index (ODI), and the modified Macnab criteria.

**Results:** The VAS and ODI significantly improved in both groups. The rate of excellent or good outcomes was 88.36% and 87.5% in the TELD and Open group, respectively. The reoperation rate was 4.2% and 3.3% in the TELD and Open group, respectively. There were no significant differences in the clinical outcomes; however, operative time, hospital stay, and time to return to work were significantly shorter in the TELD group ( $P < 0.01$ ).

**Limitations:** First, the patient selection was not randomized; therefore, the risk of bias might be increased. Second, this study lacks analysis of the radiographic changes related to the degenerative change over the long-term follow-up period.

**Conclusions:** The long-term results of TELD for soft LDH are comparable to those of conventional open microdiscectomy. The selective endoscopic discectomy technique under local anesthesia provides the typical advantages of minimally invasive procedures such as a shorter operation time, hospital stay, and recovery time.

**Key words:** Endoscopic, discectomy, hospital stay, lumbar disc, microscopic, operative time, return to work, transforaminal

**Pain Physician 2019; 22:295-304**

Until now, open lumbar discectomy or microdiscectomy was regarded as the gold standard surgical technique for lumbar disc herniation (LDH) (1-7). Because of the great amount of tissue trauma incurred during open surgery, various minimally invasive spine surgeries (MISS) have been developed. Since Hijikata et al (8,9) and Kambin (10) first independently described the posterolateral percutaneous discectomy, the full-endoscopic lumbar discectomy technique has been developed to reduce tissue trauma and perioperative complications. The basic principle of transforaminal endoscopic lumbar discectomy (TELD) is direct access to the pathologic disc through a bypass route called the "safety working zone (Kambin's triangle)" in the intervertebral neuroforamen without musculoskeletal tissue damage such as a large skin incision, muscle retraction, laminectomy, and medical facetectomy (Fig. 1). From early on, the main concept of the transforaminal discectomy was a reduction in intradiscal pressure by removal of the central nucleus for contained disc herniation (9,11,12). Owing to the technical developments in endoscopy technology and surgical approaches, the current TELD technique enables a precise and selective endoscopic discectomy for noncontained, extruded disc herniation

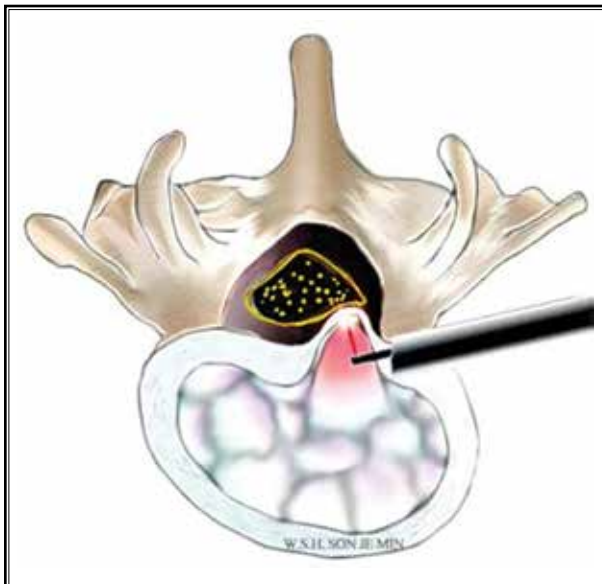


Fig. 1. The basic principle of TELD. A direct posterolateral endoscopic approach to the pathologic disc can be feasible through a bypass route in the intervertebral neuroforamen. A selective discectomy can be performed without open laminectomy and facetectomy under local anesthesia

(13,14). Some randomized trials have demonstrated the effectiveness of TELD for soft LDH (15-19). Recently, systematic reviews consisting of a meta-analysis on the effect of TELD were published (20-23). They concluded that the TELD technique is a good alternative option with a lower perioperative complication rate. However, studies on the long-term outcomes of TELD are few (24). Furthermore, there is a paucity of comparative cohort studies on the TELD technique and conventional open discectomy with a minimum 5-year follow-up period. It is also not clear if the endoscopic spinal technique has the typical benefits of MISS compared with open surgery. The objectives of this study were to describe the long-term outcomes of TELD compared with those of conventional open microdiscectomy, and to evaluate whether the endoscopic technique is less invasive for soft LDH.

## METHODS

### Patient Population

Between January 2009 and September 2011, 335 consecutive patients with symptomatic LDH were treated with decompressive discectomy, either TELD or open microdiscectomy. Patients were prospectively entered into the clinical database and their records were retrospectively reviewed. Thirty-seven patients (11%) were lost during the 5-year follow-up period. Therefore, retrospective data were collected from the remaining 298 patients. The study was approved by the institutional ethical committee, and written informed consent was obtained from the patients. The inclusion criteria for the decompressive discectomy were 1) soft LDH as demonstrated on both magnetic resonance imaging and computed tomography, 2) intractable lumbar radiculopathy consistent with the radiographic findings, and 3) failed nonoperative treatment of at least 6 weeks. The exclusion criteria were spinal stenosis, segmental instability, painless weakness, cauda equina syndrome, and other pathologic conditions such as tumor and infection. For the given criteria, the surgical technique was selected based on the preference of the surgeon on call. Of the 298 patients, 146 patients were treated with TELD by the surgeons who preferred endoscopic surgery (TELD group), whereas 152 patients were treated with open microdiscectomy by the surgeons with a preference for the conventional technique (Open group). The easiness or feasibility of the surgical technique did not play a role in the selection of surgery type.

### Outcome Measurements

Clinical data were obtained from regular outpatient visits or telephone interviews during the 5-year follow-up period. Clinical outcomes were evaluated using the visual analog scale (VAS) and the Oswestry Disability Index (ODI) (25). The patient global outcomes were categorized as excellent, good, fair, and poor based on the modified Macnab criteria (13,26) at the final follow-up. Perioperative data such as operative time, hospital stay, and time to return to work were evaluated. Return to work was defined as resuming work tasks/work hours after a period of sick leave (27,28). Surgical complications and recurrence were also documented.

### Operative Technique

The TELD was performed using the standard technique described earlier (Fig. 1) (13,29). A posterolateral transforaminal approach under conscious sedation was conducted. The approach angle and landing point can be adjusted according to the patient's body size, disc level, and zone of disc herniation. After insertion of a guiding needle, discography with indigo-carmin dye was performed to visualize the disc herniation. A gentle serial dilation technique should be performed to protect the exiting nerve root and to prevent access pain. After insertion of a working sheath, a rigid, rod-lens endoscope with working channel was introduced. The ideal working sheath placement is when both the epidural and intradiscal space are simultaneously visualized close to the herniated fragment. Selective discectomy and decompression are performed on both the intradiscal and epidural space, inside and outside the posterior longitudinal ligament. It also covers the ipsilateral side to the contralateral side, including the annular fissure. The surgical instruments used for decompression include grasping forceps, micropunches, flexible curved dissector, and a bipolar radiofrequency system. The decompression was conducted in a step-by-step manner. First, the herniated fragment was released from the tenacious annular anchorage before being removed. Second, the mobilized herniated fragment was then removed using various instruments. The entire herniated fragment in the epidural and intradiscal space should be completely removed. Finally, the end-point was confirmed by the adequate exposure of neural tissue and complete mobilization of the dural sac during the pulsation or Valsalva maneuver.

The conventional open lumbar discectomy was performed via posterior interlaminar or translaminar access. The operation started with a 1-inch long skin in-

cision under general anesthesia. A microscope-assisted lumbar laminotomy and partial facetectomy was then performed after adequate soft tissue retraction using a self-retractor. The following procedure was a resection of ligamentum flavum and exposure of the epidural space and herniated disc compressing the neural tissues. The herniated disc can be removed with careful nerve root dissection and retraction. The operation was finished with complete hemostasis and standard wound closure was performed with an epidural drain.

### Statistical Analysis

Statistical analysis was performed by an independent statistician using SPSS Version 14.0K (SPSS Inc., Chicago, IL). A comparison between the 2 groups was made using the independent 2-sample t test for continuous variables. The Fisher exact test was performed for categorical variables. A *P* value of < 0.05 was considered significant.

## RESULTS

### Demographics and Clinical Outcomes

The TELD group included 85 men and 61 women, with a mean age of 38.7 years (range, 14-77). The Open group included 94 men and 58 women, with a mean age of 40.4 years (range, 16-78). There was no significant difference between the groups regarding gender, age, body mass index, and operative level. The demographic data are summarized in Table 1.

The mean ( $\pm$  standard deviation) VAS score for back pain improved from  $5.07 \pm 2.00$  to  $1.91 \pm 1.01$  in the TELD group and from  $5.01 \pm 1.84$  to  $1.76 \pm 0.77$  in the Open group (Fig. 2A). The mean VAS score for radicular pain improved from  $6.57 \pm 2.31$  to  $1.44 \pm 1.02$  in the TELD group and from  $6.58 \pm 1.77$  to  $1.32 \pm 1.02$  in the Open group (Fig. 2B). The mean ODI improved from  $63.59\% \pm 15.57\%$  to  $13.88\% \pm 12.16\%$  in the TELD group and from  $66.58\% \pm 15.78\%$  to  $14.00\% \pm 11.06\%$  in the Open group (Fig. 3). Based on the modified Macnab criteria, the final outcome was found to be excellent or good in 129 of the 146 patients (88.36%) in the TELD group and in 133 of the 152 patients (87.5%) in the Open group (Fig. 4). There were no significant differences in clinical outcome between the groups.

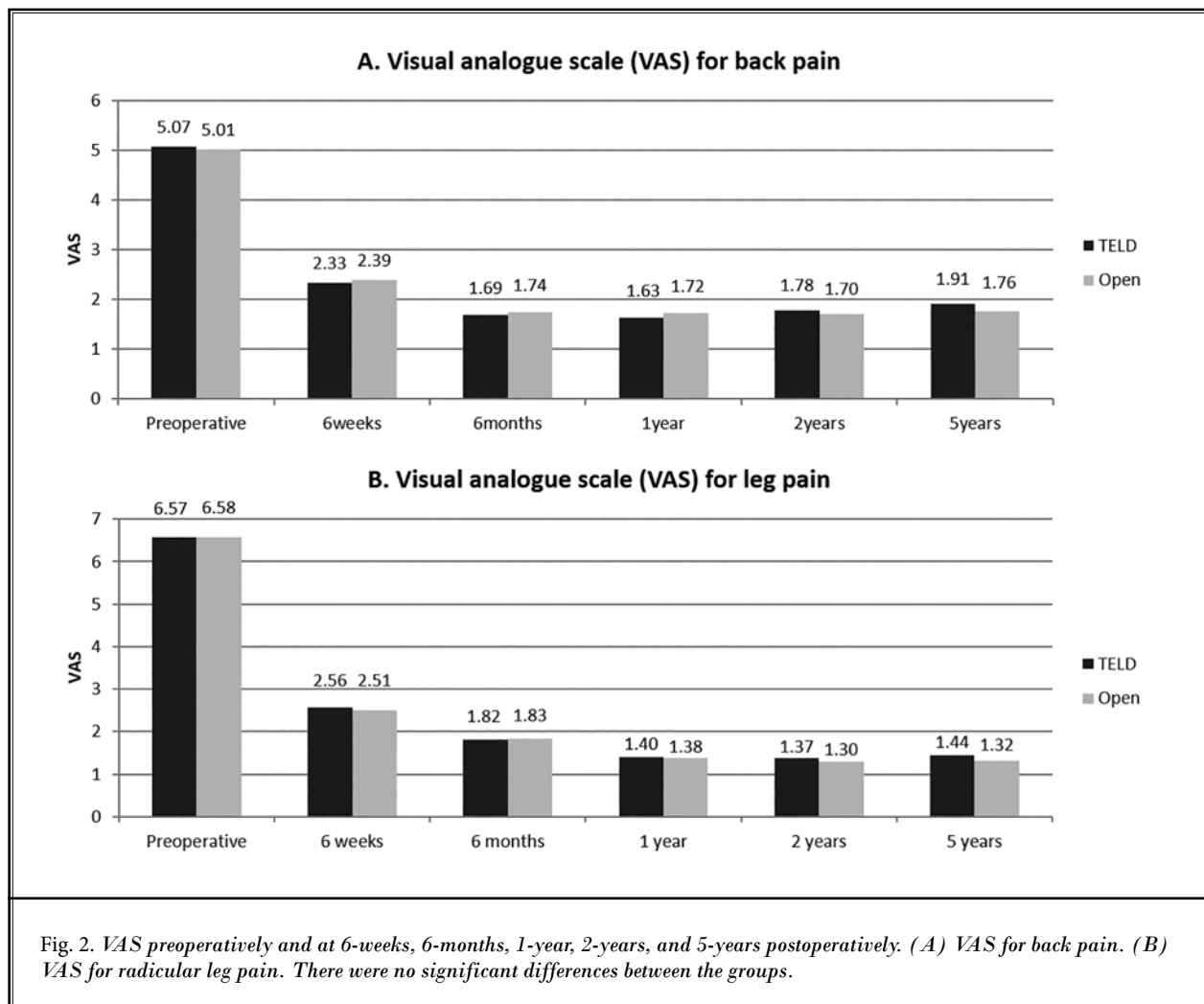
### Perioperative Data

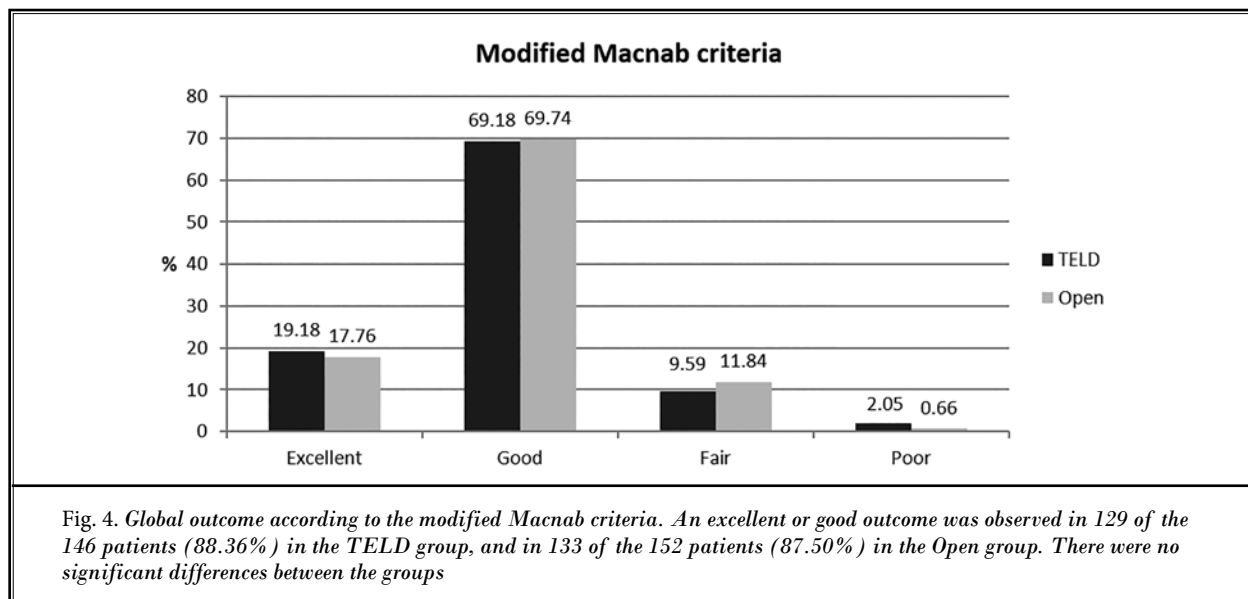
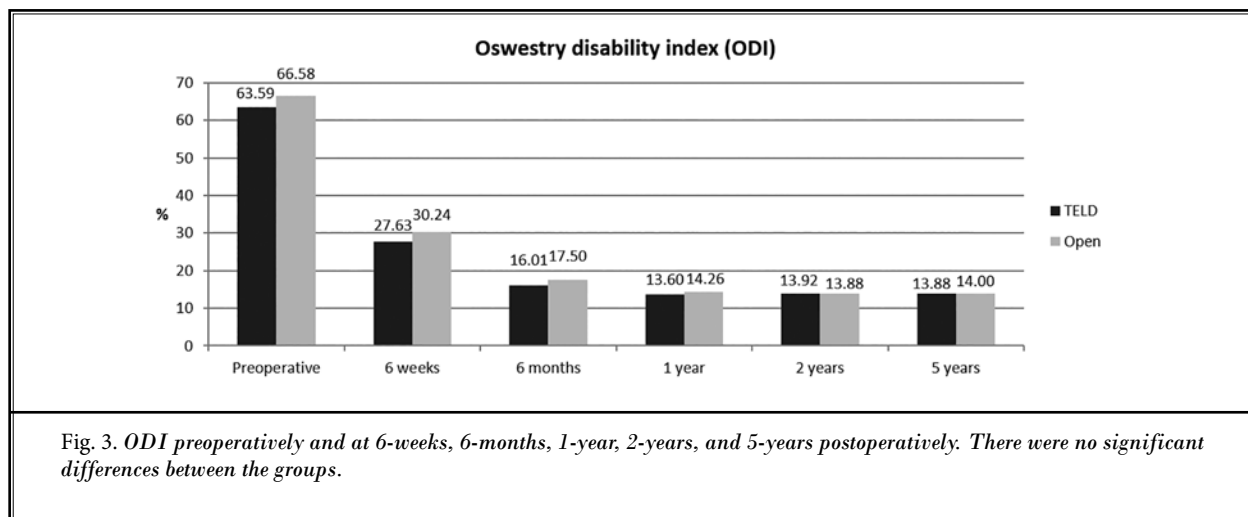
The TELD group had a significantly shorter operative time, hospital stay, and time to return to work. The mean operative time of the TELD group was  $49.38 \pm$

Table 1. Demographics.

	TELD	Open	P value
Number patients	146	152	
Gender ratio (M:F)	85:61	94:58	NS
Mean age (yrs)	32.7 (16-70)	35.4 (14-77)	NS
Mean BMI (kg/m <sup>2</sup> )	23.47	23.92	NS
Operative level			NS
L1-L2	1	1	
L2-L3	2	3	
L3-L4	11	13	
L4-L5	87	84	
L5-S1	45	51	

Abbreviations: BMI, body mass index; NS, not significant.





13.87 minutes and that of the Open group was 75.39 ± 23.70 minutes ( $P < 0.05$ ; Fig. 5A). The mean hospital stay of the TELD group was 2.1 ± 1.1 days and that of the Open group was 6.1 ± 2.6 days ( $P < 0.05$ ; Fig. 5B). The mean time to return to work of the TELD group was 3.84 ± 1.24 weeks and that of the Open group was 10.40 ± 5.32 weeks ( $P < 0.05$ ; Fig. 5C).

### Complications and Reoperations

With regard to complications, there were 7 events (4.8%) in the TELD group. The most common complica-

tion was postoperative dysesthesia. Four patients complained of postoperative dysesthesia with some degree of hypesthesia or transient weakness because of the irritation or tethering of the exiting nerve root. There was one case of epidural hematoma, one psoas muscle hematoma, and one dural tear requiring subsequent open surgery for dural repair. There were no cases of superficial or deep infection in the TELD group. There were 10 adverse events (6.6%) in the Open group; 3 cases of dural tears and cerebrospinal fluid leak that required intraoperative primary repair and postopera-

tive wound care, 2 superficial wound infections, 2 deep wound infections that required open debridement surgeries, 2 cases of postoperative epidural hematoma that required open explorations, and 1 case of transient

motor weakness in the ankle and big toe dorsiflexion, which recovered within 3 months.

The recurrent disc herniation rate was 4.2% in the TELD group and 3.3% in the Open group. Six of the 146 patients (4.2%) in TELD group experienced a symptomatic recurrent disc. Among them, 4 patients underwent open microdiscectomy and the remaining 2 underwent repeated TELD. There were 5 cases of recurrence of the 152 patients (3.3%) in the Open group. Repeated open microdiscectomy was performed in all recurrent cases in the Open group. Across both groups there were 5 recurrences that occurred within 6 weeks, 2 within 2 years, and 3 after 4 years. There was no difference in the recurrence rate between the groups (Fig. 6).

## DISCUSSION

### Differences Between the TELD and Open Groups

The TELD group showed a significantly shorter operative time, hospital stay, and time to return to work. Our results suggest that TELD provides the typical benefits of MISS in 3 ways. First, a shorter operative time can reduce the tissue trauma and the risk of potential complications such as infection, hematoma, and postoperative instability (22,30). Furthermore, there are no systemic effects of general anesthesia because all TELD procedures were performed under local anesthesia or conscious sedation. Second, a shorter duration of hospital stay means less early postoperative pain and discomfort after TELD. It can also attribute superiority in cost-effectiveness (31). Finally, early return to work can facilitate a better quality of life and improve the socioeconomic status of patients. Eventually, it may reduce the global cost of spinal treatment (30).

### Common Features of the TELD and Open Groups

Our data indicated that various clinical outcomes were statistically identical between the TELD group and Open group during the 5-year follow-up. The overall complication and recurrence rates were also similar. Our data also indicated some common patterns of postoperative clinical changes over the years. First, back pain and radicular pain scores continuously reduced for at least 1 year after surgery before a mild increase in the pain scores was observed. This phenomenon was more pronounced

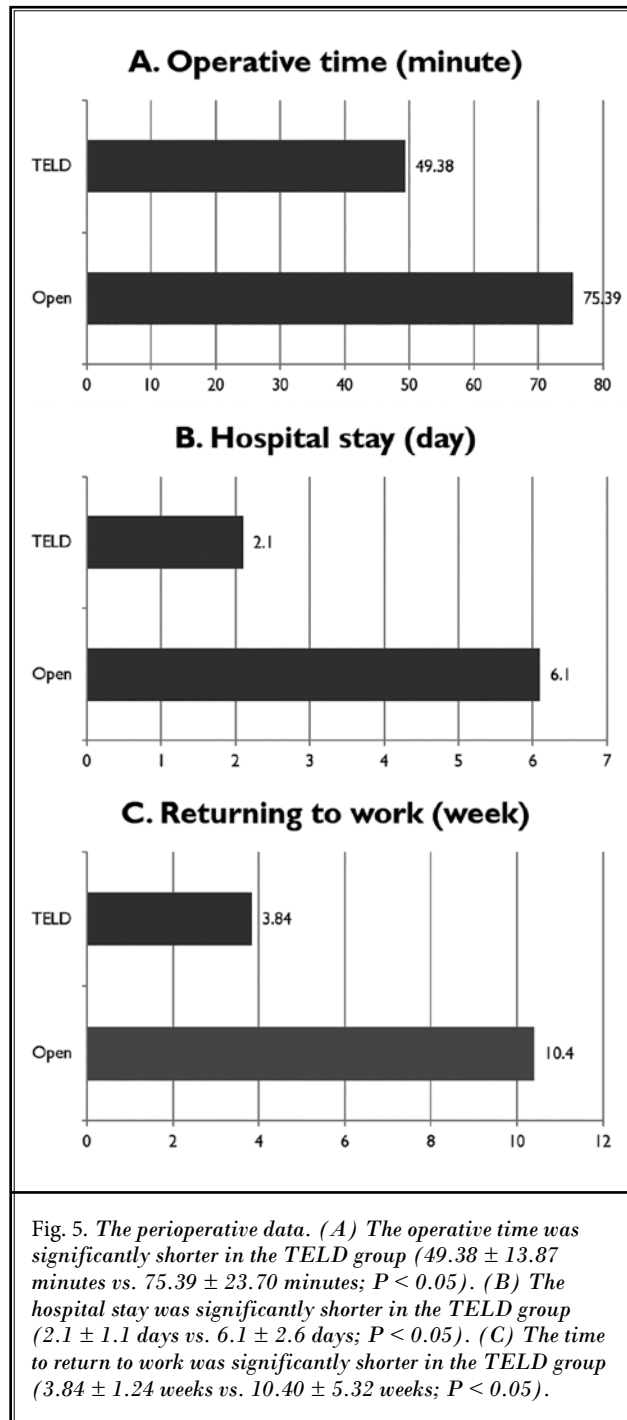
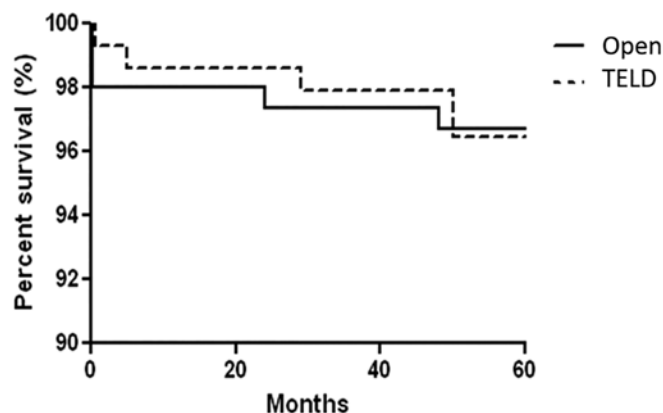


Fig. 6. The survival curve for recurrent disc herniation. The recurrence rate was 4.2% in the TELD group and 3.3% in the Open (open lumbar discectomy) group. Five recurrent cases occurred within 6 weeks, 2 cases within 2 years, and 3 cases after 4 years in both groups. There was no difference in the recurrence rate between the groups.



in back pain than radicular pain. Second, recurrent disc herniation occurred at any time interval, even after 4 years. We postulate that the degenerative process continues even after successful operations over the years. Casal-Moro et al (32) suggested that the postoperative degenerative changes may increase lumbar or radicular pain in some cases over the years.

### Pros and Cons of TELD

TELD aims to reduce iatrogenic tissue trauma and to preserve segmental motion and stability. Although some proof is still lacking, the distinctive advantages of TELD over open microdiscectomy can be summarized in 3 ways. First, the reduced tissue traumas such as small skin incision, no need for a wide bone resection or neuromuscular retraction, and minimal blood loss are obvious. Second, outpatient surgery is feasible due to local anesthesia combined with conscious sedation, a shorter operative time, and a shorter inpatient stay. Finally, a quicker recovery can be obtained because of less postoperative pain medication, less wound complications, and earlier return to work (15,17,18,33). In contrast, there are also disadvantages related to this technique. First, unique complications should be considered to establish the relevancy of TELD. Although the common postoperative complications such as epidural hematoma, dorsal dural tear, and infection are relatively rare, there may be some adverse effects of TELD such as ventral dural tear, retroperitoneal hematoma, exiting nerve root damage, and radiation exposure (34-39). Second, the learning curve is relatively flatter and longer to ensure clinical success without such obvious complications (40-43). Adequate training in endoscopic techniques and anatomic knowledge need to be ac-

quired before independently performing TELD in an actual situation. Finally, limited indications can make the procedure more complex. A hard disc, stenotic disc herniation, cauda equine syndrome, or painless profound weakness are the contraindications for TELD. Appropriate patient selection is another important key to success besides surgical technique. Therefore, we believe that surgeons experienced in both the TELD and open microdiscectomy will be able to appropriately decide which method is better for each individual case.

### Evidence of TELD

Several randomized trials have demonstrated the effectiveness of the current concept of TELD (15-18). Mayer and Brock (17) were the first to publish a randomized study comparing TELD and open microdiscectomy. They concluded that TELD can offer an alternative to microdiscectomy for patients with contained disc herniations. Hermantin et al (15) reported a comparable satisfaction rate with a shorter period of postoperative disability or narcotic use in the endoscopy group. Ruetten et al (18) demonstrated that the results of a full-endoscopic transforaminal discectomy were comparable to those of conventional open disc surgery. There are still some criticisms that the levels of evidence in the published data related to this technique are relatively low with high risk of bias (20). Moreover, the indication for TELD is confined to soft disc herniation; open surgery is still superior to the endoscopic technique for calcified or stenotic disc herniation. However, recent meta-analyses or systematic reviews have reported that the TELD is comparable or superior to the conventional discectomy in terms of the effectiveness and minimal invasiveness in selected cases (21-23). Cong et al (21)

concluded that endoscopic discectomy results in a better patient satisfaction rate in their meta-analysis. Li et al (22) concluded that the full-endoscopic procedure is as effective as a traditional discectomy and has the benefits of a lower complication rate and superior perioperative parameters. Our data support these findings during the long-term follow-up period.

### Technical Considerations

To obtain consistent and reproducible results, basic technical points should be considered across 3 aspects: proper transforaminal approach, complete disc decompression, and prevention of adverse events (44). A proper, target-oriented transforaminal approach avoiding exiting nerve root irritation is the first key to success. The landing on the disc should be as near to the target and as far from the exiting nerve root as possible. The landing point and approach angle can be adjusted according to the zone and level of disc herniation. Second, complete removal of the herniated fragment and proper confirmation of the end-point under endoscopic visualization is essential for the clinical success. The tenacious annular anchorage should be released before excision of the disc fragment. The released fragment, both epidural and intradiscal, should then be removed entirely. The surgeon should examine the entire epidural and intradiscal space, including the contralateral side, to see whether there is any fragment remaining before finishing the procedure. Finally, the appropriate prevention of intraoperative adverse events is essential for consistent clinical results. When considerable bleeding is present, it can disturb the operative field and may cause postoperative hematoma. Careful bipolar coagulation with cold saline solution irrigation should control most minor bleedings. In some cases,

compression using thrombin-soaked gelfoam with the obturator for several minutes can also be effective. To prevent dural injury, the anatomic structures should be carefully dissected with a blunt probe before excision of the disc or ligaments. In case of a minor dural tear, a simple tamponade technique using a patch and glue is usually effective. If the dural defect is large and the nerve root is popped out, open conversion and primary repair should be considered.

### Limitations

To our knowledge, this is the first comparative study on the long-term outcomes of TELD and conventional open discectomy. There may be some limitations to our study. First, the patient selection was not randomized; therefore the risk of bias might be increased. Second, this study lacks analysis of radiographic changes or other parameters related to the degenerative change over the long-term follow-up period. Therefore, our next study should be to investigate these radiographic changes and the relative cost-effectiveness of TELD and open microdiscectomy.

### CONCLUSIONS

The long-term outcomes of TELD for soft LDH are as favorable as those of open microdiscectomy. The complication and recurrence rate are also comparable to open microdiscectomy. Our data revealed that TELD can provide the typical benefits of MISS, including reduced operative time, hospital stay, and recovery time.

### Acknowledgments

The authors would like to thank Jin Ah Kim, Jae Min Son, and Sang Ho Lee for their valuable support and technical assistance.

### REFERENCES

1. Silvers HR. Microsurgical versus standard lumbar discectomy. *Neurosurgery* 1988; 22:837-841.
2. Kotilainen E, Valtonen S, Carlson CA. Microsurgical treatment of lumbar disc herniation: Follow-up of 237 patients. *Acta Neurochir (Wien)* 1993; 120:143-149.
3. Papavero L, Caspar W. The lumbar microdiscectomy. *Acta Orthop Scand Suppl* 1993; 251:34-37.
4. Moore AJ, Chilton JD, Uttley D. Long-term results of microlumbar discectomy. *Br J Neurosurg* 1994; 8:319-326.
5. Findlay GF, Hall BI, Musa BS, Oliveira MD, Fear SC. A 10-year follow-up of the outcome of lumbar microdiscectomy. *Spine (Phila Pa 1976)* 1998; 23:1168-1171.
6. Loupasis GA, Stamos K, Katonis PG, Sapkas G, Korres DS, Hartofilakidis G. Seven- to 20-year outcome of lumbar discectomy. *Spine (Phila Pa 1976)* 1999; 24:2313-2317.
7. Schoeggel A, Maier H, Saringer W, Reddy M, Matula C. Outcome after chronic sciatica as the only reason for lumbar microdiscectomy. *J Spinal Disord Tech* 2002; 15:415-419.
8. Hijikata S, Yamagishi M, Nakayama T. Percutaneous discectomy: A new treatment method for lumbar disc herniation. *J Toden Hosp* 1975; 5:5-13.
9. Hijikata S. Percutaneous nucleotomy. A new concept technique and 12 years'



- experience. *Clin Orthop Relat Res* 1989; 238:9-23.
10. Kambin P. *Arthroscopic Microdiscectomy: Minimal Intervention Spinal Surgery*. Kambin P (ed). Urban and Schwarzenburg, Baltimore, MD, 1991, pp 67-100.
  11. Schreiber A, Suezawa Y. Transdiscoscopic percutaneous nucleotomy in disk herniation. *Orthop Rev* 1986; 15:35-38.
  12. Onik G, Maroon J, Helms C, Schweigel J, Mooney V, Kahanovitz N, Day A, Morris J, McCulloch JA, Reicher M. Automated percutaneous discectomy: Initial patient experience. Work in progress. *Radiology* 1987; 162:129-132.
  13. Yeung AT, Tsou PM. Posterolateral endoscopic excision for lumbar disc herniation: Surgical technique, outcome, and complications in 307 consecutive cases. *Spine (Phila Pa 1976)* 2002; 27:722-731.
  14. Tsou PM, Yeung AT. Transforaminal endoscopic decompression for radiculopathy secondary to intracanal noncontained lumbar disc herniations: Outcome and technique. *Spine J* 2002; 2:41-48.
  15. Hermantin FU, Peters T, Quartararo L, Kambin P. A prospective, randomized study comparing the results of open discectomy with those of video-assisted arthroscopic microdiscectomy. *J Bone Joint Surg Am* 1999; 81:958-965.
  16. Hoogland T, Schubert M, Miklitz B, Ramirez A. Transforaminal posterolateral endoscopic discectomy with or without the combination of a low-dose chymopapain: A prospective randomized study in 280 consecutive cases. *Spine (Phila Pa 1976)* 2006; 31:E890-E897.
  17. Mayer HM, Brock M. Percutaneous endoscopic discectomy: Surgical technique and preliminary results compared to microsurgical discectomy. *J Neurosurg* 1993; 78:216-225.
  18. Ruetten S, Komp M, Merk H, Godolias G. Full-endoscopic interlaminar and transforaminal lumbar discectomy versus conventional microsurgical technique: A prospective, randomized, controlled study. *Spine (Phila Pa 1976)* 2008; 33:931-939.
  19. Ruetten S, Komp M, Merk H, Godolias G. Recurrent lumbar disc herniation after conventional discectomy: A prospective, randomized study comparing full-endoscopic interlaminar and transforaminal versus microsurgical revision. *J Spinal Disord Tech* 2009; 22:122-129.
  20. Nellensteijn J, Ostelo R, Bartels R, Peul W, van Royen B, van Tulder M. Transforaminal endoscopic surgery for symptomatic lumbar disc herniations: A systematic review of the literature. *Eur Spine J* 2010; 19:181-204.
  21. Cong L, Zhu Y, Tu G. A meta-analysis of endoscopic discectomy versus open discectomy for symptomatic lumbar disk herniation. *Eur Spine J* 2016; 25:134-143.
  22. Li XC, Zhong CF, Deng GB, Liang RW, Huang CM. Full-endoscopic procedures versus traditional discectomy surgery for discectomy: A systematic review and meta-analysis of current global clinical trials. *Pain Physician* 2016; 19:103-118.
  23. Ruan W, Feng F, Liu Z, Xie J, Cai L, Ping A. Comparison of percutaneous endoscopic lumbar discectomy versus open lumbar microdiscectomy for lumbar disc herniation: A meta-analysis. *Int J Surg* 2016; 31:86-92.
  24. Eun SS, Lee SH, Sabal LA. Long-term follow-up results of percutaneous endoscopic lumbar discectomy. *Pain Physician* 2016; 19:E1161-E1166.
  25. Kim DY, Lee SH, Lee HY, Lee HJ, Chang SB, Chung SK, Kim HJ. Validation of the Korean version of the Oswestry disability index. *Spine (Phila Pa 1976)* 2005; 30:E123-E127.
  26. Macnab I. Negative disc exploration. An analysis of the causes of nerve-root involvement in sixty-eight patients. *J Bone Joint Surg Am* 1971; 53:891-903.
  27. Hees HL, Nieuwenhuijsen K, Koeter MW, Bültmann U, Schene AH. Towards a new definition of return-to-work outcomes in common mental disorders from a multi-stakeholder perspective. *PLoS One* 2012; 7:e39947.
  28. Steenstra IA, Lee H, de Vroome EM, Busse JW, Hogg-Johnson SJ. Comparing current definitions of return to work: A measurement approach. *J Occup Rehabil* 2012; 22:394-400.
  29. Ahn Y, Lee SH, Park WM, Lee HY, Shin SW, Kang HY. Percutaneous endoscopic lumbar discectomy for recurrent disc herniation: Surgical technique, outcome, and prognostic factors of 43 consecutive cases. *Spine (Phila Pa 1976)* 2004; 29:E326-E332.
  30. Wu X, Zhuang S, Mao Z, Chen H. Microendoscopic discectomy for lumbar disc herniation: Surgical technique and outcome in 873 consecutive cases. *Spine (Phila Pa 1976)* 2006; 31:2689-2694.
  31. Pan Z, Ha Y, Yi S, Cao K. Efficacy of transforaminal endoscopic spine system (TESSYS) technique in treating lumbar disc herniation. *Med Sci Monit* 2016; 22:530-539.
  32. Casal-Moro R, Castro-Menéndez M, Hernández-Blanco M, Bravo-Ricoy JA, Jorge-Barreiro FJ. Long-term outcome after microendoscopic discectomy for lumbar disc herniation: A prospective clinical study with a 5-year follow-up. *Neurosurgery* 2011; 68:1568-1575.
  33. Birkenmaier C, Komp M, Leu HF, Wegener B, Ruetten S. The current state of endoscopic disc surgery: Review of controlled studies comparing full-endoscopic procedures for disc herniations to standard procedures. *Pain Physician* 2013; 16:335-344.
  34. Kim HS, Ju CI, Kim SW, Kim JG. Huge psoas muscle hematoma due to lumbar segmental vessel injury following percutaneous endoscopic lumbar discectomy. *J Korean Neurosurg Soc* 2009; 45:192-195.
  35. Ahn Y, Kim JU, Lee BH, Lee SH, Park JD, Hong DH, Lee JH. Postoperative retroperitoneal hematoma following transforaminal percutaneous endoscopic lumbar discectomy. *J Neurosurg Spine* 2009; 10:595-602.
  36. Ahn Y, Lee HY, Lee SH, Lee JH. Dural tears in percutaneous endoscopic lumbar discectomy. *Eur Spine J* 2011; 20:58-64.
  37. Cho JY, Lee SH, Lee HY. Prevention of development of postoperative dysesthesia in transforaminal percutaneous endoscopic lumbar discectomy for intracanalicular lumbar disc herniation: Floating retraction technique. *Minim Invasive Neurosurg* 2011; 54:214-218.
  38. Ahn Y, Kim CH, Lee JH, Lee SH, Kim JS. Radiation exposure to the surgeon during percutaneous endoscopic lumbar discectomy: A prospective study. *Spine (Phila Pa 1976)* 2013; 38:617-625.
  39. Choi I, Ahn JO, So WS, Lee SJ, Choi IJ, Kim H. Exiting root injury in transforaminal endoscopic discectomy: Preoperative image considerations for safety. *Eur Spine J* 2013; 22:2481-2487.
  40. Morgenstern R, Morgenstern C, Yeung AT. The learning curve in foraminal en-

- doscopy discectomy: Experience needed to achieve a 90% success rate. *SAS J* 2007; 1:100-107.
41. Lee DY, Lee SH. Learning curve for percutaneous endoscopic lumbar discectomy. *Neurol Med Chir (Tokyo)* 2008; 48:383-388.
42. Hsu HT, Chang SJ, Yang SS, Chai CL. Learning curve of full-endoscopic lumbar discectomy. *Eur Spine J* 2013; 22:727-733.
43. Fan G, Gu X, Liu Y, Wu X, Zhang H, Gu G, Guan X, He S. Lower learning difficulty and fluoroscopy reduction of transforaminal percutaneous endoscopic lumbar discectomy with an accurate preoperative location method. *Pain Physician* 2016; 19:E1123-E1134.
44. Ahn Y. Transforaminal percutaneous endoscopic lumbar discectomy: Technical tips to prevent complications. *Expert Rev Med Devices* 2012; 9:361-366.