

Randomized Trial

A Prospective Randomized Comparison of the Efficacy of Ultrasound- vs Fluoroscopy-Guided Genicular Nerve Block for Chronic Knee Osteoarthritis

Doo-Hwan Kim, MD¹, Myung-Su Lee, MD¹, Sookyung Lee, MD¹, Syn-Hae Yoon, MD², Jin-Woo Shin, MD, PhD¹, and Seong-Soo Choi, MD, PhD¹

From: ¹Department of Anesthesiology and Pain Medicine, Asan Medical Center, University of Ulsan College of Medicine, Seoul, Republic of Korea; ²Department of Anesthesiology and Pain Medicine, National Police Hospital, Seoul, Republic of Korea

Address Correspondence: Seong-Soo Choi, MD, PhD
Department of Anesthesiology and Pain Medicine
Asan Medical Center, University of Ulsan College of Medicine, 88, Olympic-ro 43-gil, Songpa-gu, Seoul, 05505, Republic of Korea
E-mail: choiss@amc.seoul.kr

Disclaimer: There was no external funding in the preparation of this manuscript. Conflict of interest: Each author certifies that he or she, or a member of his or her immediate family, has no commercial association (i.e., consultancies, stock ownership, equity interest, patent/licensing arrangements, etc.) that might pose a conflict of interest in connection with the submitted manuscript.

Manuscript received: 06-22-2018
Revised manuscript received: 08-09-2018
Accepted for publication: 08-13-2018

Free full manuscript:
www.painphysicianjournal.com

Background: Recently, genicular nerve block and radiofrequency ablation were introduced to alleviate knee pain in patients with chronic knee osteoarthritis. Both ultrasound- and fluoroscopy-guided genicular nerve blocks have been used. However, whether one is superior to the other remains unknown.

Objectives: The present study compares the efficacy of ultrasound- vs fluoroscopy-guided genicular nerve blocks.

Study Design: This research used a prospective randomized comparison design.

Setting: The study took place at a single pain clinic within a tertiary medical center in Seoul, Republic of Korea.

Methods: From July 2015 to September 2017, a randomized controlled study was performed to analyze the difference in the efficacy of ultrasound- vs fluoroscopy-guided genicular nerve blocks. The Numeric Rating Scale (NRS-11), Western Ontario and McMaster Universities Arthritis Index (WOMAC), Global Perceived Effect Scales (GPES), and complications were evaluated pre-procedure, and 1 and 3 months after genicular nerve block.

Results: A total of 80 patients were enrolled and randomly distributed to groups U (ultrasound-guided, n = 40) and F (fluoroscopy-guided, n = 40). Those who were lost to follow-up or had undergone other interventions were excluded, resulting in 31 and 30 patients in groups U and F, respectively. No differences in NRS-11 or WOMAC were observed between the 2 groups at baseline or during the follow-up period. GPES and complication rates were also similar between both groups.

Limitations: We were unable to perform double-blind randomization and did not evaluate patients' baseline emotional states.

Conclusions: Pain relief, functional improvement, and safety were similar between groups receiving ultrasound- and fluoroscopy-guided genicular nerve blocks. Therefore, either of the 2 imaging devices may be utilized during a genicular nerve block for chronic knee pain relief. However, considering radiation exposure, ultrasound guidance may be superior to fluoroscopic guidance.

The study protocol was approved by our institutional review board (2015-0369), and written informed consent was obtained from all patients. The trial was registered with the Clinical Research Information Service (KCT 0002846). This work was presented in part as D-H Kim's MS thesis at the University of Ulsan College of Medicine (2018).

Key words: Genicular nerve block, ultrasound, fluoroscopy, knee osteoarthritis, Numeric Rating Scale, The Western Ontario and McMaster Universities Osteoarthritis Index

Pain Physician 2019; 22:139-146

Knee osteoarthritis (OA), one of the most common joint diseases among elderly individuals, causes pain, joint mobility limitations, disability, and poor quality of life (1). Despite the availability of various conservative treatments, numerous patients with chronic knee OA suffer from unbearable knee pain prior to total knee joint arthroplasty (2). Ever since Choi et al introduced genicular nerve block (GNB) and radiofrequency ablation of genicular nerves (RFGN), several reports have demonstrated their effectiveness in alleviating pain and improving knee functionality in patients with chronic knee OA (3-7). These interventions have thus been considered a new option for alleviating chronic knee pain.

Two imaging methods (fluoroscopy and ultrasound) have been utilized to aid in landmark targeting and procedural accuracy. Given that fluoroscopy had traditionally been used for interventional pain medicine, GNB was initially performed using fluoroscopic guidance. Subsequently, the location of genicular nerves, their anatomical relationship with surrounding tissues, and their origin and termination became better understood through cadaveric studies (8-10). Interestingly, after identifying specific anatomical locations of genicular nerves, a number of studies began to conduct ultrasound-guided RFGN or GNB, thereby determining its efficiency during surgery (4,6,11).

Considering the advantages of using ultrasound over fluoroscopy, one of which is the visualization of genicular arteries and sometimes genicular nerves, we hypothesized that ultrasound guidance might be more accurate during GNB compared to fluoroscopic guidance. The present study therefore aimed to compare the efficacy of ultrasound- vs fluoroscopy-guided GNB.

METHODS

Patients

This study enrolled patients with chronic knee OA scheduled for GNB between April 2015 and September 2017. The present study was approved by the institutional review board of Asan Medical Center (approval number: 2015-0369) and written informed consent was obtained from all patients.

Patients were included only when they satisfied the following criteria: 1) chronic knee OA with more than 3 months of pain; 2) radiological OA grade greater than Kellgren–Lawrence grade 2; 3) 50–80 years of age; and 4) refractory knee OA pain not alleviated with analgesics, visco-supplementation, or physiotherapy.

Patients who had acute knee pain (less than 3 months), connective tissue diseases affecting the knee, serious neurological or psychiatric disorders, history of steroid injection therapy within the past 3 months, sciatic pain, prior knee surgery, and prior use of an anticoagulant were excluded.

Randomization

All patients were randomly assigned to 2 groups: Groups U and F receiving ultrasound- and fluoroscopy-guided GNB, respectively. Group distribution was accomplished using a computer-generated randomization schedule. All procedures were conducted by a single pain physician who was not blinded to the type of treatment administered. On the day of the procedure, the pain physician reviewed the electronic medical records and confirmed which guidance modality to use during GNB.

Fluoroscopy-Guided GNB (Group F)

No sedatives or analgesics were administered prior to the intervention. Patients were placed in the supine position on the operating table with a pillow beneath the popliteal fossa to minimize discomfort during the procedure. The operative area was draped in accordance with the sterile technique, while the anteroposterior (AP) fluoroscopic view of the knee joint was obtained using fluoroscopy. The view was then adjusted to ensure a true AP view, showing an open knee joint space with equal-width interspaces on both sides. Fluoroscopy-guided GNB consists of 3 target points, which include the medial and lateral areas connecting the shaft to the femoral epicondyle and the medial area connecting the shaft to the tibial epicondyle. After identifying the target points, a local anesthetic (1 mL of 1% lidocaine) was administered into the skin and soft tissues. Using the tunnel technique under fluoroscopic guidance, a 25-gauge Quincke-type spinal needle (TaeChang Industrial Co., Gongju-si, Korea) was advanced percutaneously toward areas connecting the shaft to the epicondyle until the needle tip made contact with the bone (Fig. 1A). The final location of the needle tip was confirmed using AP and lateral fluoroscopic views. We prepared 6 mL of total injectate comprising 2% lidocaine and 20 mg of triamcinolone. After a gentle aspiration was performed, 2 mL of injectate was administered at each nerve.

Ultrasound-Guided GNB (Group U)

Patients were also positioned supine on the oper-

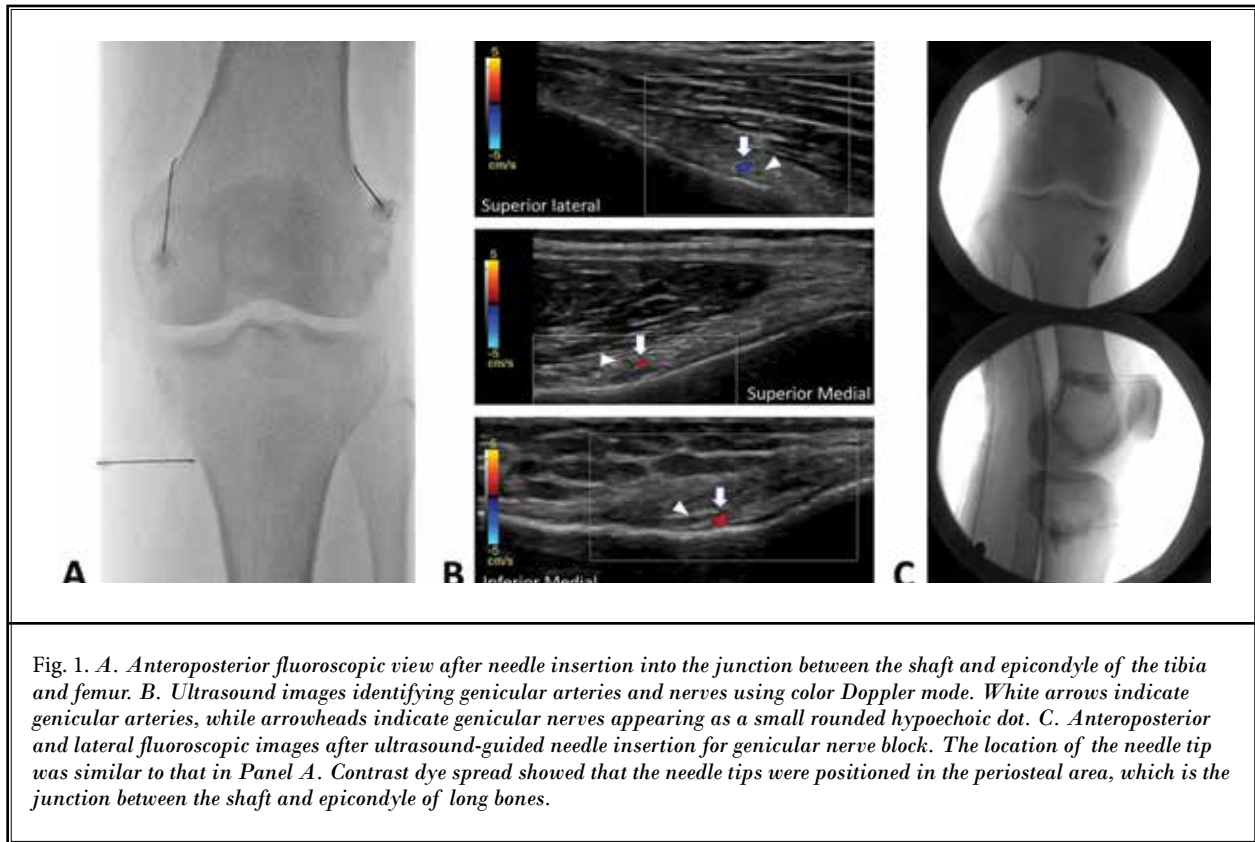


Fig. 1. *A. Anteroposterior fluoroscopic view after needle insertion into the junction between the shaft and epicondyle of the tibia and femur. B. Ultrasound images identifying genicular arteries and nerves using color Doppler mode. White arrows indicate genicular arteries, while arrowheads indicate genicular nerves appearing as a small rounded hypoechoic dot. C. Anteroposterior and lateral fluoroscopic images after ultrasound-guided needle insertion for genicular nerve block. The location of the needle tip was similar to that in Panel A. Contrast dye spread showed that the needle tips were positioned in the periosteal area, which is the junction between the shaft and epicondyle of long bones.*

ating table with a pillow under the popliteal fossa to reduce discomfort. After sterile preparation of the operative field and sterile cover wrapping of the 12-MHz linear transducer (XarioTM SSA-660A; Toshiba Medical Systems Corporation, Otawara-shi, Japan), the transducer was first placed on the junctions between the epicondyles and shafts of the femur and tibia. The transducer was then moved up or down to identify the genicular arteries, which were usually near the periosteal areas as confirmed by color Doppler ultrasound. Given that the superior lateral (12), superior medial (SM), and inferior medial (IM) genicular arteries travel along each genicular nerve (Fig. 1B), the location of the needle tip should be within the vicinity of each genicular artery. After identifying the genicular arteries, the skin and subcutaneous tissue were anesthetized with 1 mL of 1% lidocaine at each target point. The needle was inserted using the long-axis view of the ultrasound probe. After positioning the needle tip next to a genicular artery, a gentle aspiration was performed before administering 2 mL of the same injectate mentioned above at each nerve.

Measured Variables and Follow-up

All baseline values were assessed prior to the procedure, whereas postprocedure outcome measurements were evaluated after 4 and 12 weeks. Demographic data for all patients were collected through standard history-taking, as well as physical and radiological examinations. Pain intensity was assessed using the single 11-point Numeric Rating Scale (NRS-11) in which 0 = no pain and 10 = worst pain perceivable. To measure subjective knee functionality, the Western Ontario and McMaster's Universities Osteoarthritis Index (WOMAC) was used. The WOMAC consists of 5 questions measuring pain, 2 measuring joint stiffness, and 17 measuring functional limitation, with all questions scored on a scale of 0 to 4. The total scores for pain, stiffness, and physical function, which ranged from 0 to 20, 0 to 8, and 0 to 68, respectively, were then determined. Accordingly, higher scores on the WOMAC indicate worse pain, stiffness, and functional limitation (13). To obtain valid baseline values and outcome measurements, all patients were instructed on how to appropriately fill out the NRS-11 and

WOMAC prior to the procedure. Patient satisfaction with GNB was measured by assessing global perceived effects (GPES) on a 7-point scale (1 = worst and 7 = best) (14).

Outcome Measurements

The primary outcome included the mean difference in baseline pain intensity levels 4 and 8 weeks after GNB, as measured by the NRS-11. Secondary outcomes included knee functionality, patient satisfaction with treatment, incidence of adverse effects, and proportion of successful responders. According to prior study, the successful responder was defined as: 1) experiencing a reduction of at least 50% in mean NRS-11 score and no increase from baseline WOMAC, and ≥ 4 points on the GPES; 2) experiencing a reduction of at least 30% in mean NRS-11 and mean WOMAC scores, or > 5 points on the GPES (15,16). All adverse events including numbness, paresthesia, neuralgia, and motor weakness were documented. After the procedure, we requested cooperation in continuing analgesics previously prescribed to the patients for any type of degenerative disease. Moreover, patients were requested to make no changes to their medications during the 3-month follow-up period.

Sample Size and Statistical Analysis

The sample size was calculated based on our pilot study. Considering a difference of a mean of 1.9 with a SD of 2.2 in the NRS-11 value one month after the procedure at a significance level of .05 and power of .9, we determined that 29 patients per group would be needed. Subsequently, assuming a dropout rate of 25%, a total sample size of 80 patients would be required (40 in each group). SPSS Version 21.0 (IBM Corporation, Armonk, NY) was used to analyze obtained data. The Kolmogorov–Smirnov test was used to determine the normality of the data. Normally distributed demographic data were compared using t tests and presented as mean \pm standard deviation. Nonparametric data were evaluated using Mann-Whitney U tests and presented as median and interquartile range. Categorical data were presented as numbers and percentages and compared using the chi-square test or Fisher exact test as appropriate. NRS-11 and WOMAC scores of both groups at baseline and 1 and 3 months after the operation were compared using 2-way repeated measures analyses of variance with Bonferroni tests. Statistical significance was set at a *P* value of less than 0.05.

RESULTS

A total of 80 patients (40 in each group) were enrolled in the present study. Two patients in group U and 7 in group F did not receive the scheduled intervention. Moreover, 5 patients in group U were lost to follow-up, while 2 underwent intraarticular steroid injection after one month. In group F, one patient received genicular radiofrequency ablation, while 2 underwent intraarticular steroid injection after one month. Ultimately, 31 patients in group U and 30 in group F were analyzed (Fig. 2). Regardless of the guidance modality used, all patients underwent a successful GNB without any complications.

Clinical characteristics did not differ between groups (Table 1). As shown in Table 2, no significant difference was observed in NRS-11, subset scores, or total WOMAC scores between groups at baseline and 1 and 3 months after the procedure. Notably, NRS-11 and WOMAC scores at 1 and 3 months were significantly lower than those at baseline in both groups, except for WOMAC scores related to pain and stiffness at 3 months in group F. Moreover, the proportion of successful responders was also similar for both groups at 1 and 3 months (Fig. 3). No difference was found in patient satisfaction (*P* = .814, GPES at 1 month; *P* = .315, GPES at 3 months) during the follow-up period. No complications associated with the procedure were observed in either group.

DISCUSSION

Two main findings in the present study were noted. First, post-intervention outcomes were similar for both imaging modalities used during GNB. Second, although GNB with a steroid was effective, its effects lasted for only one month after the procedure in patients with chronic knee OA.

The use of imaging devices in the performance of nerve blocks can help increase procedural accuracy and reduce complications compared to a blind technique (17,18). Therefore, selecting the appropriate imaging device is imperative for increasing the success rate of a nerve block. For the first time since Choi et al introduced fluoroscopy-guided RFGN or GNB, we have been able to observe the wide use of both ultrasound and fluoroscopy as imaging modalities for the aforementioned procedures.

However, whether one imaging method is superior to the other remains unclear. Fluoroscopic guidance has a number of advantages for GNB. First, the SL, SM, and IM genicular nerves traverse along the periosteal areas

Comparison Between 2 Methods for Genicular Nerve Block

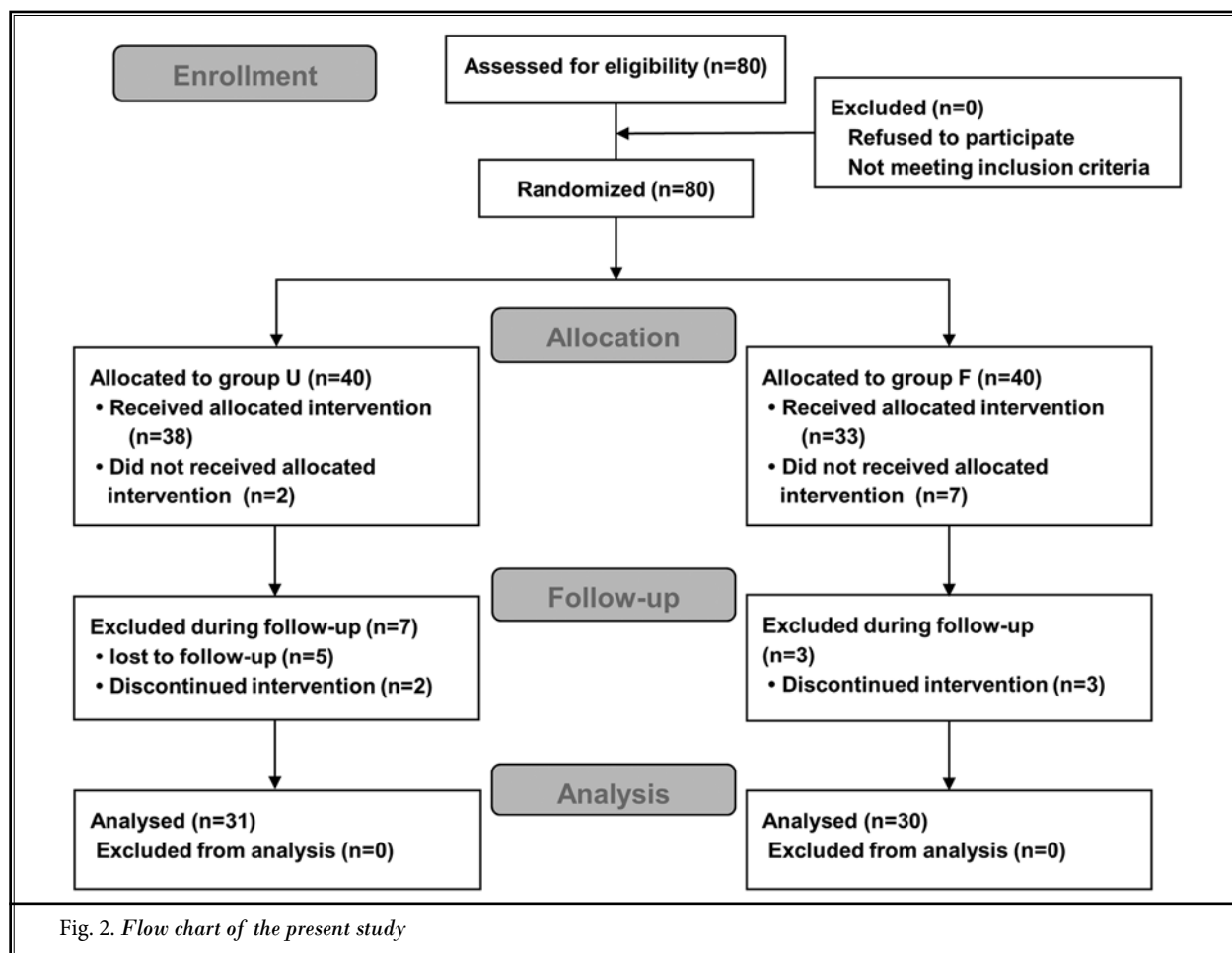


Table 1. Clinical characteristics

	Group U (n = 31)	Group F (n = 30)	P Value
Age (yrs)	65.2 ± 10.4	66.8 ± 9.3	0.544
BMI (kg/m ²)	25.8 ± 3.0	24.1 ± 3.9	0.071
Gender (Men/Women)	9 (29.0%)/22 (71.0%)	8 (26.7%)/22 (73.3%)	0.837
DM	4 (12.9%)	4 (13.3%)	0.960
K-L grade (2/3/4)	13 (43.3%)/13 (43.3%)/4 (13.3%)	18 (64.3%)/9 (32.1%)/1 (3.6%)	0.195
Affected Side (Left/Right/Both)	10 (32.3%)/10 (32.3%)/11 (35.5%)	11 (36.7%)/9 (30.0%)/10 (33.3%)	0.936
Duration of Pain (mos)	14.0 (4.0-60.0)	12.0 (5.0-27.0)	0.488
Baseline Morphine Equivalent Dose (mg)	0.0 (0.0-17.5)	0.0 (0.0-20.0)	0.631

Data are expressed as mean ± standard deviation, number (%), or median (interquartile range). BMI, body mass index; DM, diabetes mellitus; K-L grade, Kellgren-Lawrence grade

connecting the shaft to the epicondyle (3). Therefore, a fluoroscopic view of the knee joint can easily identify target points for RFGN. Second, ultrasound does not provide clear visualization of smaller-gauge needles at deep tissue levels, whereas fluoroscopic imaging

provides good needle visualization regardless of tissue depth and needle gauge. Third, the use of real-time contrast fluoroscopy and digital subtraction angiography can prevent unintentional intravascular injection (19).

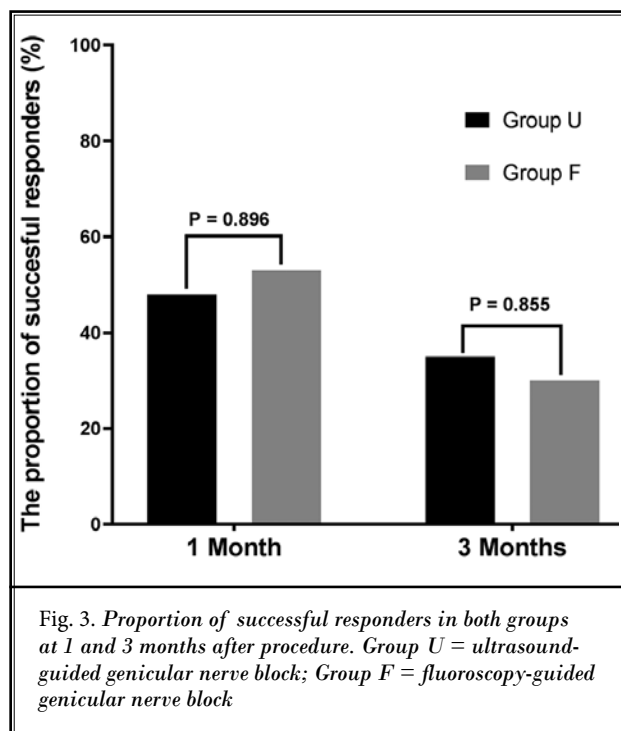
Table 2. Comparison of pain intensity and functional outcomes between both groups after genicular nerve block.

	Group U (n = 31)			Group F (n = 30)			P Value
	Baseline	1 mo	3 mos	Baseline	1 mo	3 mos	
NRS-11	6.3 ± 1.6	3.8 ± 2.1*	4.3 ± 2.1*	6.7 ± 1.6	3.9 ± 1.9*	4.9 ± 1.9*	0.637
WOMAC_Pain	10.8 ± 4.0	7.2 ± 4.0*	7.9 ± 4.2*	10.7 ± 4.5	6.9 ± 3.7*	9.3 ± 4.5	0.189
WOMAC_Stiffness	4.4 ± 2.3	2.7 ± 1.7*	2.9 ± 1.8*	4.0 ± 2.3	2.8 ± 1.9*	3.5 ± 2.0	0.153
WOMAC_Physical function	34.5 ± 16.6	23.3 ± 15.0*	25.0 ± 14.2*	34.3 ± 11.7	22.9 ± 11.5*	27.3 ± 13.0*	0.320
WOMAC_Total	50.0 ± 20.6	34.2 ± 19.6*	35.6 ± 18.5*	48.7 ± 16.5	32.1 ± 16.0*	39.6 ± 18.1*	0.179

Data are expressed as means ± standard deviations.

NRS-11, numeric rating scale; WOMAC, Western Ontario and McMaster Universities Osteoarthritis Index.

* $P < .05$ compared with baseline values in each group. P values comparing NRS-11 and WOMAC scores between both groups.



On the other hand, ultrasound guidance during GNB offers unique advantages over fluoroscopy. First, neither the patients nor clinicians are exposed to radiation during an ultrasound-guided procedure. This is deemed as the best advantage ultrasound has over fluoroscopy. Second, ultrasound can provide a real-time image of soft tissues (nerves, muscles, vessels, etc.), an image of needle tip advancement relevant to surrounding structures, and visualization of injectate spread (12). Third, it can both statically and dynamically guide diagnostic and therapeutic procedures. Another advantage of ultrasound-guided GNB includes the visualization of genicular arteries and even the occasional identification of genicular nerves,

which may increase GNB precision. This led us to speculate that using ultrasound may be more efficient than using fluoroscopy when performing GNB.

The present study found no difference in efficacy between these imaging methods for GNB. Several studies have compared the effectiveness of fluoroscopy- vs ultrasound-guided blocks for chronic pain management (20-23). Consistent with our results, such studies reported no significant difference in postprocedural outcomes between the 2 modalities for an image-guided block. This similarity between both image guidance methods for GNB may be due to the anatomical properties of genicular nerves. Genicular nerves travel along each genicular artery. Such genicular neurovascular bundles extend across the junctions between the epicondyles and shafts of the femur and tibia (3,9,24). To demonstrate that GNB targets locate similarly regardless of the imaging device used, fluoroscopic images of the knee were obtained after ultrasound-guided needle insertion (Fig. 1C). The results showed that needle tips were located at the junctions between the epicondyles and shafts of the femur and tibia. Consequently, given the similarity in target positions during GNB regardless of the imaging equipment used, we may surmise that the efficacy of both imaging devices might also be similar.

One previous report compared the efficacy of ultrasound- vs fluoroscopy-guided RFGN (25), and their results were similar to those found in this study. However, they failed to discuss why such similarity in efficacy existed between both imaging methods. As such, we believe that the current study may provide more valuable information compared to the previous study.

Considering the similar effects of both guidance modalities, we believe that ultrasound may be more

suitable for GNB. As mentioned previously, ultrasound has several advantages over fluoroscopy. Given that GNB or RFGN is usually repeated periodically due to its finite duration, cumulative doses of radiation may damage several other organs, including the skin, bones, thyroid glands, and lungs (26). Thus, the absence of radiation hazard with ultrasound-guided interventions is an excellent advantage for both patients and surgeons. Other reasons for choosing ultrasound include accessibility, convenience, and portability (27-30). Unlike fluoroscopy, disruptions in target view due to patient movement caused by interventional pain can be readily restored with ultrasound. Furthermore, given that genicular arteries are almost always easily identified using ultrasound, GNB can be performed more accurately. Other studies have also suggested that ultrasound may be more appropriate for nerve block compared to fluoroscopy due to the aforementioned reasons (20,21,31). However, differences in surgical proficiency and patient obesity may hinder the selection of ultrasound (32,33). Fluoroscopic guidance may be more appropriate for cooled RFGN or conventional RFGN given the need for the RF needle tip to be positioned parallel to the target nerve. Therefore, fluoroscopy-guided GNB may be the first choice depending on the situation.

Generally, a diagnostic GNB with a local anesthetic is conducted prior to RFGN to determine the need for one (5), whereas GNB with a corticosteroid can be used for therapeutic, but not diagnostic, purposes (34). In the present study, GNB with an adjuvant corticosteroid improved knee functionality and alleviated pain intensity until one month post procedure. Although significance differences in pain intensity and knee functionality were observed 3 months after GNB (mean NRS difference in group U = 2.0; mean NRS-11 difference in group F = 1.8; mean total WOMAC difference in group U = 14.4; and total WOMAC difference in group F = 9.1) (Table 2), no significant differences in outcomes were found after reassessing NRS-11 and WOMAC scores

according to the minimal clinically important changes with reference to previous studies (change in NRS-11 scores > 2; change in total WOMAC score > 15 points) (35,36). Therefore, the effects of a diagnostic GNB with an adjuvant corticosteroid seemed to last for only 1 month, a result consistent with our previous findings (37). In cases where GNB has shown to be effective, RFGN would be needed to manage chronic knee pain 1 month after GNB instead of repeating the same.

Some limitations in the present study need to be noted. First, we were unable to perform double-blind randomization because of budget and personnel limitations. Given that the only pain physician was one of investigators, he could not be blinded to the type of intervention, which may constitute a confounding bias. Second, we were unable to evaluate the patients' baseline emotional states. Subjective affect might have influenced the perception of pain severity and functional outcomes after the intervention. However, considering our exclusion of patients with neurological or psychiatric disorders during study enrollment, we believe that emotional factors had minimal effects on our results.

CONCLUSION

No significant differences in pain relief, improvements in knee functionality, or safety were observed between ultrasound- and fluoroscopy-guided GNB. Therefore, either ultrasound or fluoroscopic guidance may be selected for GNB in patients with chronic knee OA. However, considering radiation exposure, as well as other advantages, we believe that ultrasound might be a better option for GNB in patients with chronic knee OA.

Acknowledgment

The authors thank Dr. Jong-Min Kim (knee specialist) in the Department of Orthopedic Surgery, Asan Medical Center, for preparing this study.

REFERENCES

1. Peat G, McCarney R, Croft P. Knee pain and osteoarthritis in older adults: A review of community burden and current use of primary health care. *Ann Rheum Dis* 2001; 60:91-97.
2. Crawford DC, Miller LE, Block JE. Conservative management of symptomatic knee osteoarthritis: A flawed strategy? *Orthop Rev* 2013; 5:e2.
3. Choi WJ, Hwang SJ, Song JG, Leem JG, Kang YU, Park PH, Shin JW. Radiofrequency treatment relieves chronic knee osteoarthritis pain: A double-blind randomized controlled trial. *Pain* 2011; 152:481-487.
4. Kesikburun S, Yasar E, Uran A, Adiguzel E, Yilmaz B. Ultrasound-guided genicular nerve pulsed radiofrequency treatment for painful knee osteoarthritis: A preliminary report. *Pain Physician* 2016; 19:E751-E759.
5. McCormick ZL, Korn M, Reddy R, Marcolina A, Dayanim D, Mattie R, Cushman D, Bhavne M, McCarthy RJ, Khan D, Naggal G, Walega DR. Cooled radiofrequency ablation of the genicular nerves for chronic pain due to knee osteoarthritis.

- tis: Six-month outcomes. *Pain Med* 2017; 18:1631-1641.
6. Protzman NM, Gyi J, Malhotra AD, Kooch JE. Examining the feasibility of radiofrequency treatment for chronic knee pain after total knee arthroplasty. *PM R* 2014; 6:373-376.
 7. Sari S, Aydin ON, Turan Y, Ozlulderden P, Efe U, Kurt Omurlu I. Which one is more effective for the clinical treatment of chronic pain in knee osteoarthritis: Radiofrequency neurotomy of the genicular nerves or intra-articular injection? *Int J Rheum Dis* 2016; doi:10.1111/1756-185X.12925.
 8. Yasar E, Kesikburun S, Kilic C, Guzelkucuk U, Yazar F, Tan AK. Accuracy of ultrasound-guided genicular nerve block: A cadaveric study. *Pain Physician* 2015; 18:E899-E904.
 9. Franco CD, Buvanendran A, Petersohn JD, Menzies RD, Menzies LP. Innervation of the anterior capsule of the human knee: Implications for radiofrequency ablation. *Reg Anesth Pain Med* 2015; 40:363-368.
 10. Sutaria RG, Lee SW, Kim SY, Howe R, Downie SA. Localization of the lateral retinacular nerve for diagnostic and therapeutic nerve block for lateral knee pain: A cadaveric study. *PM R* 2017; 9:149-153.
 11. Demir Y, Guzelkucuk U, Tezel K, Aydemir K, Taskaynatan MA. A different approach to the management of osteoarthritis in the knee: Ultrasound guided genicular nerve block. *Pain Med* 2017; 18:181-183.
 12. Narouze SN, Vydyanathan A, Kapural L, Sessler DI, Mekhail N. Ultrasound-guided cervical selective nerve root block: A fluoroscopy-controlled feasibility study. *Reg Anesth Pain Med* 2009; 34:343-348.
 13. Bellamy N, Buchanan WW, Goldsmith CH, Campbell J, Stitt LW. Validation study of WOMAC: A health status instrument for measuring clinically important patient relevant outcomes to antirheumatic drug therapy in patients with osteoarthritis of the hip or knee. *J Rheumatol* 1988; 15:1833-1840.
 14. Yalcin I, Bump RC. Validation of two global impression questionnaires for incontinence. *Am J Obstet Gynecol* 2003; 189:98-101.
 15. Choi SS, Lee JH, Kim D, Kim HK, Lee S, Song KJ, Park JK, Shim JH. Effectiveness and factors associated with epidural decompression and adhesiolysis using a balloon-inflatable catheter in chronic lumbar spinal stenosis: 1-year follow-up. *Pain Med* 2015; 17:476-487.
 16. Geurts JW, van Wijk RM, Wynne HJ, Hammink E, Buskens E, Lousberg R, Knape JT, Groen GJ. Radiofrequency lesioning of dorsal root ganglia for chronic lumbosacral radicular pain: A randomised, double-blind, controlled trial. *Lancet* 2003; 361:21-26.
 17. Uuncu F, Capkin E, Karkucak M, Ozden G, Cakirbay H, Tosun M, Guler M. A comparison of the effectiveness of landmark-guided injections and ultrasonography guided injections for shoulder pain. *Clin J Pain* 2009; 25:786-789.
 18. Hoerber S, Aly AR, Ashworth N, Rajasekaran S. Ultrasound-guided hip joint injections are more accurate than landmark-guided injections: A systematic review and meta-analysis. *Br J Sports Med* 2016; 50:392-396.
 19. Baker R, Dreyfuss P, Mercer S, Bogduk N. Cervical transforaminal injection of corticosteroids into a radicular artery: A possible mechanism for spinal cord injury. *Pain* 2003; 103:211-215.
 20. Finlayson RJ, Etheridge JP, Tiyaprasertkul W, Nelems B, Tran DQ. A randomized comparison between ultrasound- and fluoroscopy-guided C7 medial branch block. *Reg Anesth Pain Med* 2015; 40:52-57.
 21. Finlayson RJ, Etheridge JP, Vieira L, Gupta G, Tran DQ. A randomized comparison between ultrasound- and fluoroscopy-guided third occipital nerve block. *Reg Anesth Pain Med* 2013; 38:212-217.
 22. Furtado RNV, Pereira DF, da Luz KR, dos Santos MF, Konai MS, Mitraud Sde A, Rosenfeld A, Fernandes Ada R, Natour J. Effectiveness of imaging-guided intra-articular injection: A comparison study between fluoroscopy and ultrasound. *Rev Bras Reumatol* 2013; 53:476-482.
 23. Soneji N, Bhatia A, Seib R, Tumber P, Disanayake M, Peng PW. Comparison of fluoroscopy and ultrasound guidance for sacroiliac joint injection in patients with chronic low back pain. *Pain Pract* 2016; 16:537-544.
 24. Hirasawa Y, Okajima S, Ohta M, Tokioka T. Nerve distribution to the human knee joint: Anatomical and immunohistochemical study. *Int Orthop* 2000; 24:1-4.
 25. Sari S, Aydin ON, Turan Y, Sen S, Ozlulderden P, Omurlu IK, Gulasti F. Which imaging method should be used for genicular nerve radio frequency thermocoagulation in chronic knee osteoarthritis? *J Clin Monit Comput* 2017; 31:797-803.
 26. Wagner LK, Eifel PJ, Geise RA. Potential biological effects following high X-ray dose interventional procedures. *J Vasc Interv Radiol* 1994; 5:71-84.
 27. Sofka CM, Collins AJ, Adler RS. Use of ultrasonographic guidance in interventional musculoskeletal procedures: A review from a single institution. *J Ultrasound Med* 2001; 20:21-26.
 28. Raza K, Lee CY, Pilling D, Heaton S, Situnayake RD, Carruthers DM, Buckley CD, Gordon C, Salmon M. Ultrasound guidance allows accurate needle placement and aspiration from small joints in patients with early inflammatory arthritis. *Rheumatology (Oxford)* 2003; 42:976-979.
 29. Weidner S, Kellner W, Kellner H. Interventional radiology and the musculoskeletal system. *Best Pract Res Clin Rheumatol* 2004; 18:945-956.
 30. Jeon YH. Easier and safer regional anesthesia and peripheral nerve block under ultrasound guidance. *Korean J Pain* 2016; 29:1-2.
 31. Amber KT, Landy DC, Amber I, Knopf D, Guerra J. Comparing the accuracy of ultrasound versus fluoroscopy in glenohumeral injections: A systematic review and meta-analysis. *J Clin Ultrasound* 2014; 42:411-416.
 32. Maarse W, Watts AC, Bain GI. Medium-term outcome following intra-articular corticosteroid injection in first CMC joint arthritis using fluoroscopy. *Hand Surg* 2009; 14:99-104.
 33. Handolin LE, Hiltunen OJ. Perioperative difficulties in fluoroscopy of the femoral head in massive obese patient: Enhanced visualization by intra-articular contrast agent. *Arch Orthop Trauma Surg* 2006; 126:498-499.
 34. Qudsi-Sinclair S, Borrás-Rubio E, Abellan-Guillen JF, Padilla Del Rey ML, Ruiz-Merino G. A comparison of genicular nerve treatment using either radiofrequency or analgesic block with corticosteroid for pain after a total knee arthroplasty: A double-blind, randomized clinical study. *Pain Pract* 2017; 17:578-588.
 35. Farrar JT, Young JP, Jr., LaMoreaux L, Werth JL, Poole RM. Clinical importance of changes in chronic pain intensity measured on an 11-point numerical pain rating scale. *Pain* 2001; 94:149-158.
 36. Escobar A, Quintana JM, Bilbao A, Arostegui I, Lafuente I, Vidaurreta I. Responsiveness and clinically important differences for the WOMAC and SF-36 after total knee replacement. *Osteoarthritis Cartilage* 2007; 15:273-280.
 37. Kim DH, Choi SS, Yoon SH, Lee SH, Seo DK, Lee IG, Choi WJ, Shin JW. Ultrasound-guided genicular nerve block for knee osteoarthritis: A double-blind, randomized controlled trial of local anesthetic alone or in combination with corticosteroid. *Pain Physician* 2018; 21:41-52.