

A CASE REPORT

CT GUIDED DIRECT TRANSORAL APPROACH TO C2 FOR PERCUTANEOUS VERTEBROPLASTY

Arra S. Reddy, MD, Mary Hochman, MD, Shaun Loh, BS, Jacob Rachlin MD, PhD, Joseph Li, MD, and Joshua A. Hirsch, MD

Background: Percutaneous vertebroplasty is a well-established procedure consisting of the percutaneous injection of a bio-material, usually Polymethyl methacrylate (PMMA), into a vertebral body. In most cases, this procedure affords significant pain relief and strengthens the bone. Vertebroplasty is most typically performed successfully with patients with acute compression fractures.

Objective: We report a case of percu-

taneous vertebroplasty via the transoral approach, performed with computed axial tomography (CT) scan guidance.

Methods: The procedure was performed in a 74-year-old male with a C2 vertebral body lytic lesion.

Results: This uncomplicated, minimally invasive procedure relieved the patient's pain. The transoral route is the most direct operative approach to the pathology in the

upper cervical spine.

Conclusion: When used with the CT scanner to facilitate accurate placement of the needle, the transoral approach provides a safe and precise operative approach to the upper cervical spine.

Keywords: Cervical spine, vertebroplasty, transoral

The transoral approach is a well-documented method of addressing the upper cervical spine. Specialists of various surgical disciplines have described this approach (1-10). Percutaneous vertebroplasty is a well-established and highly successful procedure, often performed to treat patients with acute compression fractures secondary to metastatic or osteoporotic compression fractures (11-15). We employed the transoral approach with percutaneous vertebroplasty to treat a lesion at the base of the dens, which extended into the C2 vertebral body. C2 vertebroplasty has been performed transorally with fluoroscopic guidance and is reported herein with CT guidance (16-21).

METHODS

Our institutional review board did not require approval for this type of report.

A 74-year-old male presented with a one-month history of neck pain without antecedent trauma. The patient sought help from his primary care physician who prescribed prescription analgesics, anti-inflammatory medication, muscle relaxants, and physical therapy. Despite four months of therapy, he had inadequate pain relief. He was referred to a rheumatologist who diagnosed cervical spondylosis and degenerative disc disease.

Cervical spine radiographs demonstrated a lytic lesion at the base of the dens, which extended into the body of the C2 vertebra (Figs. 1, 2). A magnetic resonance imaging (MRI) demonstrated a focal area of signal abnormality with a predominantly hypointense complex lesion on T1 weighted images, and hyperintense lesion on T2 weighted images. This MRI confirmed the presence of a lytic/complex cystic lesion at the base of dens with extension into the C2 vertebral body (Figs. 3, 4). A CT scan demonstrated a well-defined lytic lesion involving the base of the dens with extension to the C2 vertebral body. The patient was referred to a neurosurgeon who recommended biopsy and possible vertebroplasty.

The patient provided informed consent after an explanation of the risks/benefits and indications for the procedure. The patient received general anesthesia prior to being placed in a supine position in the CT scanner. The patient received one gram of intravenous cefazolin prior to the procedure. This antibiot-

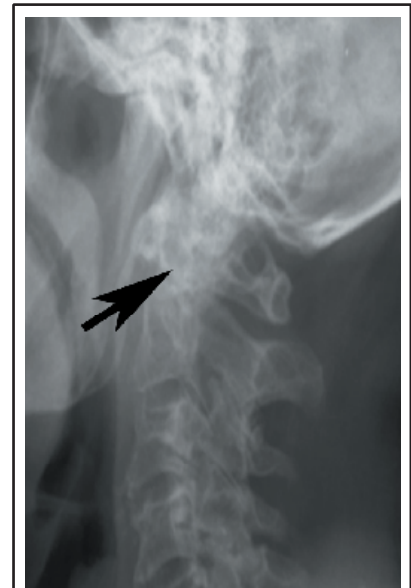


Fig. 1. Lateral radiograph demonstrates lytic lesion involving the dens

From: Departments of Radiology and Neurosurgery and Hospitals, Beth Israel Deaconess Medical Center/Harvard Medical School, Boston, MA; Department of Radiology, Massachusetts General Hospital / Harvard Medical School, Boston, MA

Address Correspondence:

Shaun Loh, BS, Beth Israel Deaconess Medical Center, Harvard Medical School, One Deaconess Rd., Suite 580, Boston, MA 02215

Disclaimer: There was no external funding in preparation of this manuscript.

Acknowledgement:

Manuscript received on 2/4/2005

Revision submitted on 2/28/2005

Accepted for publication on 3/5/2005

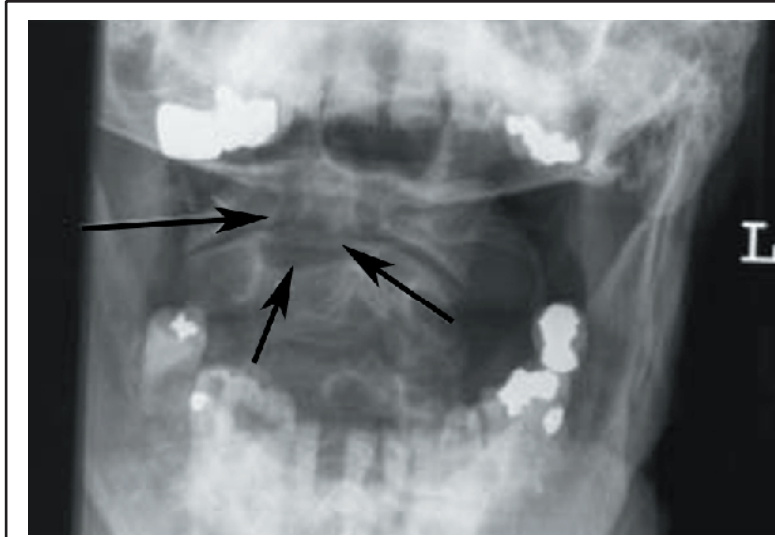


Fig. 2. Open mouth view demonstrates lytic lesion involving the dens

icwas continued for five days. A self-retaining retractor (Dingman, V Mueller, Cleveland, Ohio) was used to open the patient's mouth. Povidone iodine was used to cleanse the oropharyngeal cavity. A CT scan was performed to identify the lesion. One percent Lidocaine with epinephrine was used to anesthetize the pharynx and to provide local vasoconstriction. A 22-gauge needle was placed through the pharynx to guide the sub-

sequent placement of a 6-inch, 13-gauge Jamshidi needle (MD Tech, Northbrook, IL). A plastic cannula was placed over the 13-gauge needle in order to avoid injury to the tongue and uvula. Multiple biopsy specimens were obtained. Approximately 2 cc of PMMA mixture (mixed with 1gm of tobramycin) was introduced under CT guidance (Figs. 5-7).

RESULTS

The patient tolerated his CT-guided needle biopsy and vertebroplasty of C2 without complications. His airway was never compromised via the pharyngeal approach to the surgery. The patient did not experience dyspnea or headache and there was no evidence of a hematoma. Biopsy demonstrated non-specific inflammatory cells without evidence of neoplastic cells. The patient remained asymptomatic at his six-month follow-up.

DISCUSSION

To our knowledge, this is the first reported case of a CT guided, transoral vertebroplasty (16-21). Traditional anterolateral approach to access the upper cervical spine is limited by possible risk of damage to major neurovascular structures including several vital nerves, namely the vagus, hypoglossal, spinal accessory nerves and major vessels such as the carotid and vertebral arteries (15). This procedure provided substantial palliation in a minimally invasive fashion.

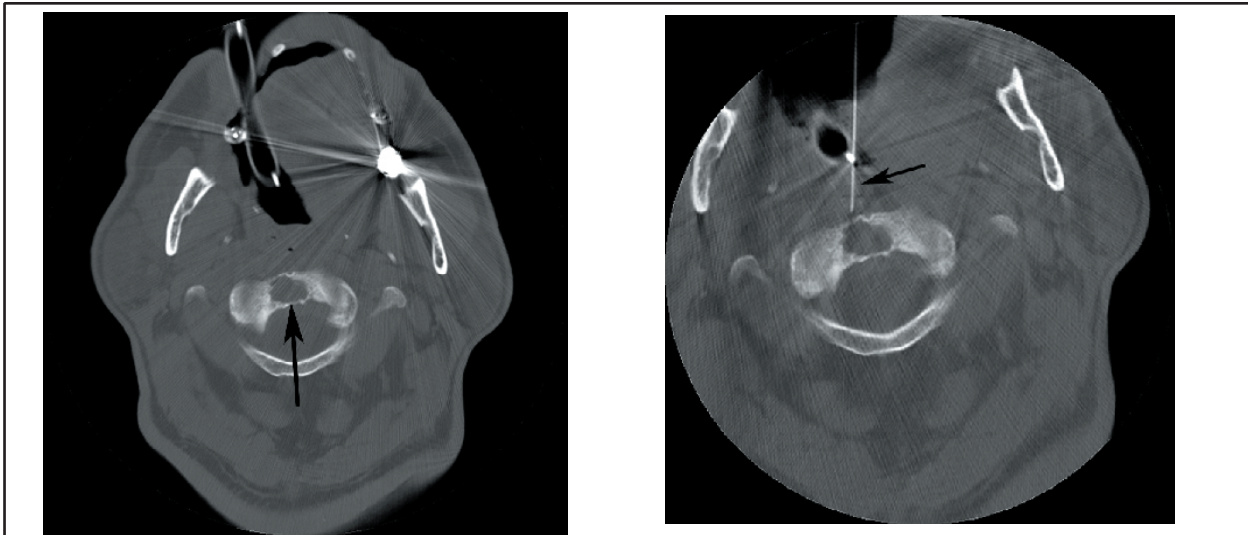
Otolaryngologists and neurosurgeons have extensively used the transoral approach to access the upper cervical spine. This is a well-established access route in the otolaryngological and neurosurgical literature. A thin layer of fascia and muscles separates the upper cer-

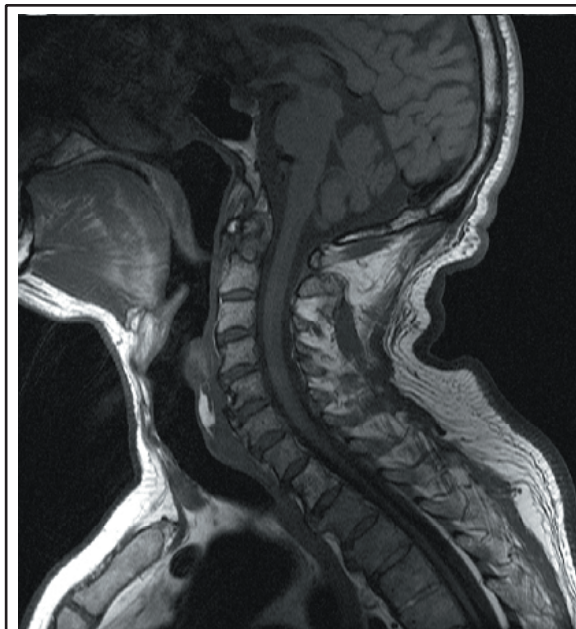

Fig. 3. Sagittal T1 weighted image demonstrates hypointense lesion involving the dens.

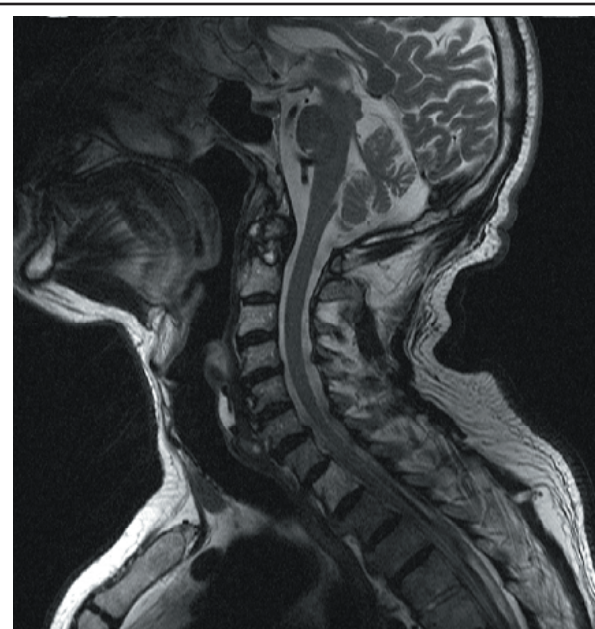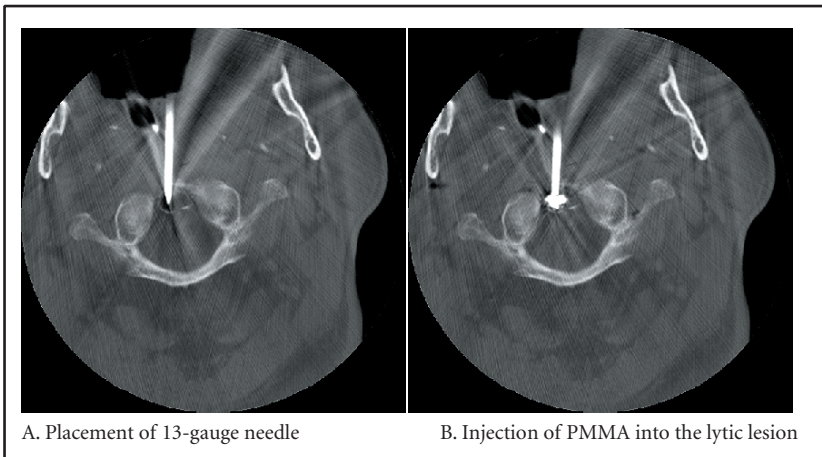


Fig. 4. Sagittal T2 weighted image demonstrates hyperintense lesion involving the dens.



A. Preprocedure CT demonstrates B. Initial placement of 22-gauge guide needle a lytic lesion in the dens

Fig. 5. CT images of C spine during treatment.



A. Placement of 13-gauge needle B. Injection of PMMA into the lytic lesion

Fig. 6. CT images of C spine during treatment.

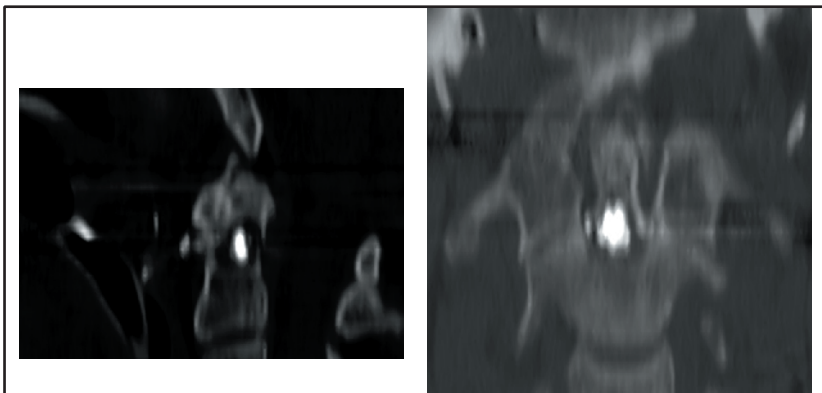


Fig. 7. Post procedure CT (left, sagittal and right, coronal reformats) demonstrate optimal placement of PMMA into the dens of the C2 vertebral body.

vical spine from the oral mucosa. Risk of infection is the primary concern about this technique. Extension of infection into fascial planes can cause a retropharyngeal abscess and invasion of the meningeal layers leading to meningitis and encephalitis (5-7). The rate of infection has dropped significantly in recent years, due to the improvement in aseptic techniques, perioperative antibiotics, and thorough cleansing of the surgical bed prior to the procedure. The risk of infection has also been significantly reduced secondary to thin needles used during the procedure and the short operative time. In addition, tobramycin added to the PMMA cement during the procedure has also significantly reduced the infection rate during vertebroplasty.

CONCLUSION

The transoral surgical approach has been established as an effective and safe method of treating upper cervical pathology. Vertebroplasty is a well-established procedure for pain control and stabilization of vertebral pathology including metastasis, hemangioma, and multiple myeloma. Precise placement of the needle under CT scan guidance makes this a reasonably safe procedure. In selected cases CT guided, transoral vertebroplasty can be performed for the alleviation of cervical pain.

AUTHOR AFFILIATION:**Arra S. Reddy, MD**

Chief, Interventional Neuroradiology
Department of Radiology
Beth Israel Deaconess Medical Center
Harvard Medical School
One Deaconess Rd., Suite 580
Boston, MA 02215

Mary Hochman, MD

Chief, Musculoskeletal Radiology
Department of Radiology
Beth Israel Deaconess Medical Center
Harvard Medical School
One Deaconess Rd., Suite 580
Boston, MA 02215

Shaun Loh, BS

Research Fellow
Department of Radiology
Beth Israel Deaconess Medical Center
Harvard Medical School
One Deaconess Rd., Suite 580
Boston, MA 02215
E-mail: sloh1@bidmc.harvard.edu

Jacob Rachlin, MD, PhD

Staff Physician
Department of Neurosurgery
Beth Israel Deaconess Medical Center
Harvard Medical School
One Deaconess Rd., Suite 580
Boston, MA 02215

Joseph Li, MD

Medical Director
Hospital Medicine Program
Beth Israel Deaconess Medical Center
Harvard Medical School
One Deaconess Rd., Suite 580
Boston, MA 02215

Joshua A. Hirsch, MD

Director, Interventional
Neuroradiology/Endovascular
Neurosurgery
Chief, Minimally Invasive Spine
Surgery
Massachusetts General Hospital
55 Blossom St., Gray 2891
Boston, MA 02114
E-mail: jahirsch@partners.org

REFERENCES

- Succo G, Solini A, Crosetti E, Gargiulo G, Sartoris A. Enlarged approach to the anterior cervical spine. *J Laryngol Otol* 2001; 115: 994-997.
- Sandor GK, Charles DA, Lawson VG, et al. Trans-oral approach to the nasopharynx and clivus using the Le Fort I osteotomy with midpalatal split. *Int J Oral Maxillofac Surg* 1990; 19: 352-355.
- Bonney G, Williams JP. Trans-oral approach to the upper cervical spine. A report of 16 cases. *J Bone Joint Surg Br* 1985; 67:691-698.
- Merwin GE, Post JC, Sybert GW. Transoral approach to the upper cervical spine. *Laryngoscope* 1991;101:780-784.
- Menezes AH, VanGilder JC. Transoral-transpharyngeal approach to the anterior craniocervical junction: Ten-year experience with 72 patients. *J Neurosurg* 1988; 69:895-903.
- Fang HS, Ong GB, Hodgson AR. Anterior spinal fusion: the operative approaches. *Clin Orthop* 1964; 35:16-33.
- Hadley MN, Spetzler RF, Sonntag VK. The transoral approach to the superior cervical spine: A review of 53 cases of extradural cervicomedullary compression. *J Neurosurg* 1989; 71:16-23.
- Kingdom TT, Nockels RP, Kaplan MJ. Transoral-transpharyngeal approach to the craniocervical junction. *Otolaryngol Head Neck Surg* 1995; 113:393-400.
- Spetzler RF, Hadley MN, Sonntag VK. The transoral approach to the anterior superior cervical spine. A review of 29 cases. *Acta Neurochir Suppl* 1988; 43:69-74.
- Blazier CJ, Hadley MN, Spetzler RF. The transoral surgical approach to craniovertebral pathology. *J Neurosci Nurs* 1986; 18: 57-62.
- Jensen ME, Evans AJ, Mathis JM, Kallmes DF, Cloft HJ, Dion JE. Percutaneous polymethylmethacrylate vertebroplasty in the treatment of osteoporotic vertebral body compression fractures: technical aspects. *AJNR Am J Neuroradiol* 1997; 18:1897-1904.
- Levine SA, Perin LA, Hayes D, Hayes WS. An evidence-based evaluation of percutaneous vertebroplasty. *Manag Care* 2000; 9:56-60, 63.
- Murphy KJ, Deramond H. Percutaneous vertebroplasty in benign and malignant disease. *Neuroimaging Clin N Am* 2000; 10:535-545.
- Cortet B, Cotten A, Boutry N, Dewatre F, Flipo RM, Duquesnoy B, Chastanet P, Delcambre B. Percutaneous vertebroplasty in patients with osteolytic metastases or multiple myeloma. *Rev Rhum Engl Ed* 1997; 64:177-183.
- Cotten A, Boutry N, Cortet B, Assaker R, Demondion X, Leblond D, Chastanet P, Duquesnoy B, Deramond H. Percutaneous vertebroplasty: state of the art. *RadioGraphics* 1998; 18:311-323.
- Martin JB, Gailloud P, Dietrich PY, Luciani ME, Somon T, Sappino PA, Rufenach DA. Direct transoral approach to C2 for percutaneous vertebroplasty. *Cardiovasc Intervent Radiol* 2002; 25:517-519.
- Gailloud P, Martin JB, Olivi A, Gailloud P, Martin JB. Transoral vertebroplasty for a fractured C2 aneurysmal bone cyst. *J Vasc Interv Radiol* 2002; 13:340-341.
- Tong FC, Cloft HJ, Joseph GJ, Rodts GR, Dion JE. Transoral approach to cervical vertebroplasty for multiple myeloma. *AJR Am J Roentgenol* 2000; 175:1322-1324.
- Dufresne AC, Brunet E, Sola-Martinez MT, Rose M, Chiras J. Percutaneous vertebroplasty of the cervico-thoracic junction using an anterior route. Technique and results. Report of nine cases. *J Neuroradiol* 1998; 25:123-128.
- Dousset V, Mousseledard H, de Monck d'User L, Bouvet R, Bernard P, Vital JM, Senegas J, Caille JM. Asymptomatic cervical haemangioma treated by percutaneous vertebroplasty. *Neuroradiology* 1996; 38:392-394.
- Feydy A, Cognard C, Miaux Y, Sola-Martinez MT, Weill A, Rose M, Chiras J. Acrylic vertebroplasty in symptomatic cervical vertebral hemangiomas: report of 2 cases. *Neuroradiology* 1996; 38:389-391.