

Prospective Study

Effectiveness Analysis of Percutaneous Kyphoplasty Combined with Zoledronic Acid in Treatment of Primary Osteoporotic Vertebral Compression Fractures

Zi-Feng Huang, MD, Shao-Xiong Xiao, MD, Kun Liu, MM, and Wei Xiong, BM

From: Department of Spine Surgery, Wuhan No. 1 Hospital, Wuhan, China

Address Correspondence:
Shao-Xiong Xiao, MD
Department of Spine Surgery,
Wuhan No. 1 Hospital
No. 215 Zhongshan Rd
Wuhan 430000, China
E-mail:
tomxiao225@hotmail.com

Disclaimer: This study was funded by the Development Center for Medical Science and Technology, National Health and Family Planning Commission of (Grant No. W2014ZT288).
Conflict of interest: Each author certifies that he or she, or a member of his or her immediate family, has no commercial association (i.e., consultancies, stock ownership, equity interest, patent/licensing arrangements, etc.) that might pose a conflict of interest in connection with the submitted manuscript.

Manuscript received: 06-01-2017
Revised manuscript received:
05-18-2018
Accepted for publication:
07-25-2018

Free full manuscript:
www.painphysicianjournal.com

Objective: To investigate the therapeutic effectiveness of percutaneous kyphoplasty (PKP) combined with zoledronic acid in treatment of primary osteoporotic vertebral compression fractures.

Study Design: A perspective cohort study was conducted at a single institution for patients, who received PKP operation due to primary osteoporotic vertebral compression fracture between January 2014 and January 2015.

Setting: According to whether they received postoperative zoledronic acid or not, patients were divided into treatment or control groups, with 30 randomly-selected cases per group.

Methods: The visual analogue scale (VAS), which was used to assess the degree of pain, and the bone mineral density, was analyzed at 1-, 6-, and 12-month follow-ups.

Results: In general, patients experienced marked pain relief after surgery. No significant difference in pain relief was observed in the control group between the 6 and 12-month follow-up. In contrast, the VAS score of the treatment group at 12-month follow-up was significantly lower than that at 6-month (P value = 0.03). Moreover, it was also significantly lower than the VAS score in the control group at the 12-month follow-up (P value = 0.0018). The bone mineral density of patients from the treatment group increased significantly and progressively after the surgery (pre-operation versus 6-month follow-up: P value = 0.01; 6-month versus 12-month follow-up: P value < 0.001), and it was also remarkably higher than that of the control group at the 12-month follow-up (P value < 0.0001).

Limitations: Patients were collected from a single hospital. The maximum postoperative follow-up time was 12 months. The sample size was relatively small. Thus, bias could occur in the selection of cases if they are not representative of the population.

Conclusion: The combined treatment of zoledronic acid with PKP for primary osteoporotic vertebral compression fractures safely and effectively relieved low back pain, significantly increased bone density, and improved the quality of life. The clinical effectiveness is promising and worthy of further study.

Key words: Kyphoplasty, zoledronic acid, primary osteoporotic vertebral compression fractures

Pain Physician 2019; 22:63-68

Osteoporosis is a bone disease marked by loss of bone density, thinning and/or loss of trabeculae, more porous cortical bone, and microarchitecture deterioration of bone tissues.

Osteoporosis makes bones weak and brittle, eventually leading to fractures (1,2). Osteoporotic vertebral compression fractures (OVCFs) are very common in elderly patients, who usually have poor physical

condition or systemic diseases. Those patients are prone to having complications during conservative treatment. Prolonged bed rest after surgery sometimes results in rapid bone loss, thereby aggravating the osteoporosis and increasing the morbidity and mortality rates. OVCF has become a serious threat to the elderly's physical and mental health, quality of life, and even life expectancy.

Percutaneous balloon kyphoplasty (PKP) is a medical spinal procedure that is used to restore the height and angle of kyphosis of a fractured vertebra. This is done by inflation of a balloon in the fractured vertebral body, followed by injection of bone cement. The viscous bone cement, named polymethylmethacrylate (PMMA), fixes and stabilizes intravertebral fractures. By restoring the vertebral strength and stiffness the PKP procedure rapidly and effectively relieves pain caused by OVCF and greatly improves the quality of life. PKP has been primarily performed in hospitals (3,4). The risks of PKP include leakage of cement, residual back pain, additional fractures, infection, pulmonary embolus, allergic reactions, spinal cord injury, and balloon rupture (3,5). Some studies have suggested the use of postoperative anti-osteoporotic therapy to prevent additional fractures. However, the effect is still controversial (6). In this study, we demonstrate that PKP combined with zoledronic acid infusion is efficacious in the treatment of OVCF, indicating that it is beneficial to public health.

METHODS

Inclusion and Exclusion Criteria

Inclusion Criteria

All patients presented with lower back pain, local spinous process tenderness, and/or vertebral body pain with percussion. The evidences of vertebral compression fractures were shown by x-ray, and confirmed by MRI. Middle and posterior columns were not affected as shown by CT scanning.

Exclusion Criteria

- 1) In this study we focused on primary osteoporotic vertebral fractures so that patients with secondary vertebral fractures or secondary osteoporosis were excluded;
- 2) Patients with breaks in the posterior vertebral body wall were excluded since a broken posterior wall is associated with a higher rate of cement leakage (7);
- 3) Patients with symptoms of spinal cord compression needing fragment excision, decompression, open

- reduction and internal fixation were excluded; and
- 4) Patients with severe cardiopulmonary dysfunction, liver failure or renal dysfunction who could not tolerate surgery and anesthesia were excluded.

The study was conducted in accordance with the Declaration of Helsinki and with the approval of the Ethics Committee of 1st Hospital of Wuhan.

One hundred thirty-eight patients received PKP for treatment of primary OVCF from January 2014 to January 2015 at a single hospital. Patients were divided into treatment or control groups according to whether or not they received postoperative zoledronic acid injection. Each group had 30 randomly-chosen patients.

Surgical Procedure and Zoledronic Acid Treatment

Patients were placed in the prone position with a pad under the chest and abdomen. Under local anesthesia, balloon kyphoplasty was performed. Briefly, working channels were created by using a drill at the 10 o'clock position of the pedicle on the left side and the 2 o'clock position on the right side, guided by both G-arm and C-arm fluoroscopy. The balloon was carefully inflated, increasing the anterior height of the vertebral body to near normal in efforts to correct the kyphosis as much as possible. The balloon was then deflated and withdrawn. Bone cement (Polymethylmethacrylate, PMMA) was slowly injected into the newly created cavity within the fractured vertebral body under fluoroscopic guidance. The injection was stopped when satisfactory filling was completed. The needles were withdrawn as the bone cement hardened. The skin incision was disinfected and closed with steristrips.

Patients from both control and treatment groups were placed on bed rest the first day after surgery and were given oral calcium (600 mg, twice daily). Patients were allowed to sit up by wearing a waist trainer, and were allowed to stand up, or ambulate after 48 h of bed rest. Patients in the treatment group were given 5 mg zoledronic acid (Zometa®, Novartis, 5 mg: 100 mL/bottle) by an intravenous (IV) infusion 3 days after the surgery. Radiographs were obtained following the kyphoplasty to demonstrate the vertebral body cement distribution.

Follow-up Pain Assessment

The visual analogue scale (VAS) was used to assess the degree of pain 1, 6, and 12 months post surgery. Scores were recorded from 0 to 10, with 0 indicating no pain and 10 indicating the worst pain. The bone min-

eral density of the proximal femoral neck was measured before surgery and at 6 and 12-months post surgery, using dual energy x-ray absorptiometry (HOLOG-IC, USA).

Statistical Analysis

All data were analyzed by SPSS 17.0. VAS scores were expressed as mean ± standard deviation ($\bar{x} \pm s$). For continuous variables, comparisons between the 2 groups were analyzed with student t test or paired t test as appropriate. For categorical data, a chi-square test was used for comparison between the 2 groups. $P < 0.05$ was considered statistically significant.

RESULTS

Both the treatment and control groups contained 30 randomly-chosen patients. The demographic and clinical information is summarized in Table 1. The treatment group (patients given i.v. zoledronic acid) was comprised of 7 males and 23 females with an average age of 76.11 ± 0.83 years (ranging from 54 to 93 years), whereas the control group (patients given oral calcium) included 10 males and 20 females with an average age of 74.36 ± 9.08 years (ranging from 58 to 90 years). Balloon kyphoplasty was successfully performed for all patients from both groups. To evaluate the long-term effectiveness of PKP combined with zoledronic acid treatment on relieving pain, patients were followed up at 1, 6, 12 and 24 months after the surgery. The mean follow-up time was 19.46 ± 2.51 and 19.46 ± 2.33 months for the control and treatment groups, respectively. In general, all patients from both groups experienced significant pain relief after the operation, and the majority of patients were satisfied with the surgery. In the control group, the VAS score at 6-month follow-up was significantly lower than that at 1-month follow-up (2.68 ± 0.72 versus 3.36 ± 0.73 , P value = 0.0002, Table 2). However, no further improvement in pain relief was observed at 12-months (VAS score: 2.57 ± 0.69 , P value = 0.55). In the treatment group, the VAS score at 6 months

was significantly lower than that at 1 month (2.39 ± 0.50 versus 3.14 ± 0.52 , P value < 0.0001). Moreover, patients experienced further pain relief at 12 months (VAS score of 2.11 ± 0.50 , P value = 0.03). Consistently, the average postoperative VAS score of the treatment group was significantly lower than that of the control group at 12 months (P value = 0.0018, Table 2).

The bone mineral density of patients from the control group did not significantly change at 6 and 12 months when compared to the preoperative density (preoperative versus 6 months postoperative: P value = 0.37; 6 months versus 12 months postoperative: P value = 0.91, Table 3). In contrast, the bone mineral density of patients from the treatment group significantly increased after surgery (preoperative versus 6 month postoperative: P value = 0.01; 6 versus 12 months: P value < 0.001, Table 3). Bone densities of patients from the treatment group were also significantly higher than those from the control group at 12 months (P value < 0.0001).

Table 1. Demographic information and clinical characteristics.

	Control (n = 30)	Treatment (n = 30)	P value
Age			
Mean (SD)	74.36 (9.08)	76.11 (8.30)	0.4391 ¹
Gender			
Male	7 (23.3%)	10 (33.3%)	0.3941 ²
Female	23 (76.7)	20 (66.7%)	
BMI			
Mean (SD)	18.38 (1.43)	18.39 (1.29)	0.9774 ¹
Location of fractures			
Thoracic spine	18 (60%)	17 (56.7%)	0.7934
Lumbar spine	12 (40%)	13 (43%)	
Duration of fracture (Days)			
Mean (SD)	5.89 (4.19)	6.25 (4.90)	0.7608 ¹

¹T-test; ²Chi-square test

Table 2. Comparison of VAS scores self-evaluated by patients at 1-, 6-, and 12- month follow-up after the PKP surgery ($x \pm s$).

	n	Pre-operation	Post-operation			t ₁	p ₁	t ₂	p ₂
			1-month	6-month	12-month				
Control	30	7.30 ± 0.84	3.36 ± 0.73	2.68 ± 0.72	2.57 ± 0.69	-3.63	0.00	0.60	0.55
Treatment	30	7.37 ± 0.76	3.14 ± 0.52	2.39 ± 0.50	2.11 ± 0.50	-5.70	0.00	-2.17	0.03
t		0.34	-1.34	-1.81	-2.96				
p		0.74	0.18	0.08	0.00				

Paired student t test was used to compare VAS scores within each group between 2 different time points. t₁ and p₁ were t statistic and P-value for comparison of VAS between 1 and 6 months post surgery, respectively. t₂ and p₂ were for comparison of VAS between 6 and 12 months post surgery, respectively. t and p are t statistic and P-value for comparison between control and treatment groups.

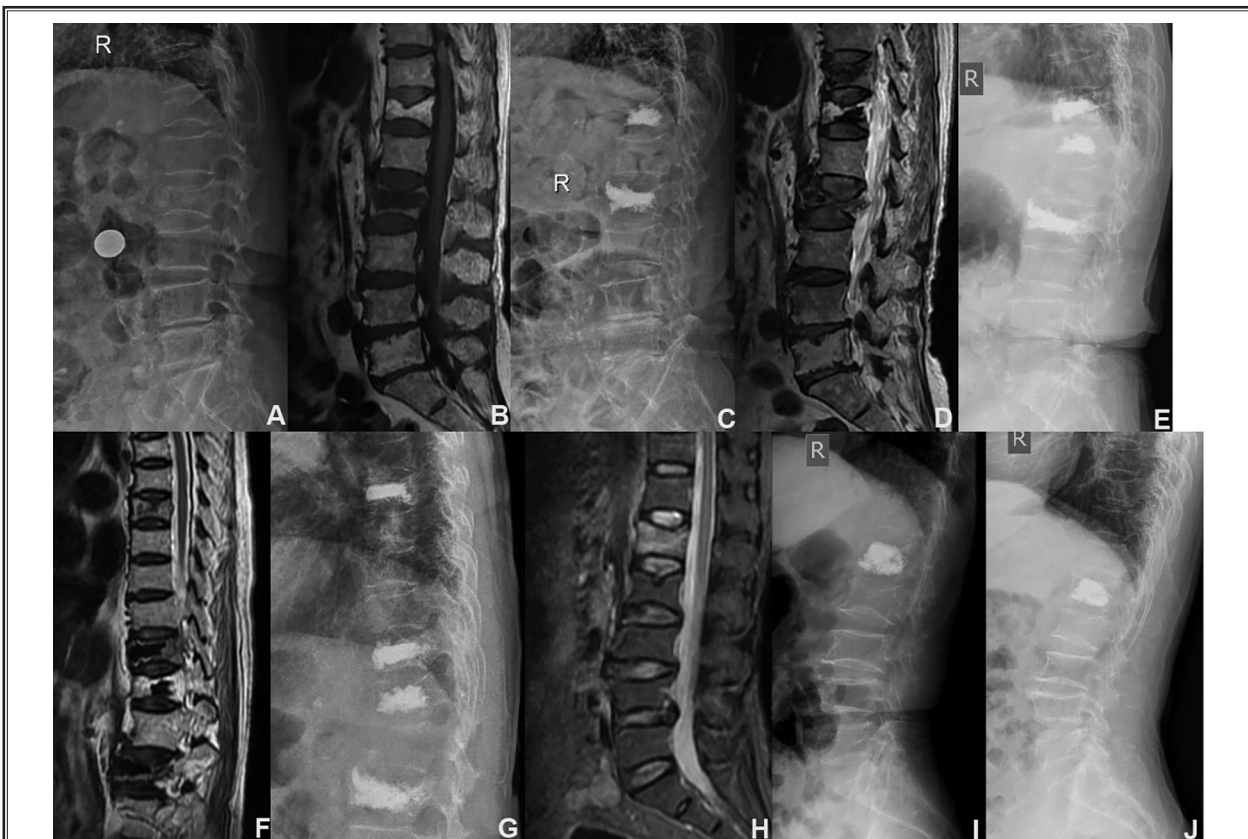
During the follow-up period, 6 subjects from the control group had additional vertebral body fractures. Among them, 1 had 2 additional vertebral body

fractures in 1 year (Fig. 1). Eight patients had bone cement leakage. Three patients had intertrochanteric femoral fractures. In the treatment group, 2 patients

Table 3. Comparison of bone mineral densities of patients at pre-operation, as well as at 6 and 12 months post surgery ($\bar{x} \pm s$).

	n	Preoperation	6 months postoperation	12 months postoperation	t ₁	p ₁	t ₂	p ₂
Control	30	-3.15 ± 0.41	-3.06 ± 0.36	-3.05 ± 0.33	0.90	0.37	0.11	0.91
Treatment	30	-3.14 ± 0.38	-2.91 ± 0.31	-2.61 ± 0.26	2.57	0.01	-4.06	0.00
t		0.10	1.73	5.74				
p		0.92	0.09	0.00				

Paired student t test was used to compare bone mineral densities within each group between two different time points. t₁ and p₁ were t statistic and P-value for comparison between preoperation and 6 months post surgery, respectively. t₂ and p₂ were t statistic and P-value for comparison between 6 and 12 months post surgery, respectively. t and p were t statistic and P-value for comparison between control and treatment groups.



Panel (A-G): Pre- and post-operative imaging of an 82 year-old female patient who had four vertebral body fractures in 14 months. The initial vertebral fractures involved L2 and T12 as shown by the admission x-ray (A) and MRI (B). PKP was performed and a postoperative x-ray was obtained (C). This patient had a new vertebral fracture at T11 twelve months later as seen on MRI (D). An additional PKP procedure was performed and a postoperative x-ray was obtained (E). The same patient experienced a 4th vertebral fracture at T7 two months later as demonstrated by MRI (F). A postoperative x-ray imaging was obtained (G). This patient was not treated with zoledronic acid after the PKP surgery. The pre- and post-operative bone mineral density was -3.3 and -3.2, respectively. Panel (H-I): Pre- and post-operative imaging of a 70 year-old female patient who was diagnosed with L1 wedge fracture. After the PKP surgery, the patient was given 5 mg zoledronic. (H) preoperative lumbar MRI. (I) Lateral lumbar x-ray 2 days after the surgery. (J) Lateral lumbar x-ray one year after the surgery. The preoperative bone mineral density was -3.2 and it was -2.7 one year after the surgery.

Fig. 1. X-ray and MRI images of patients who had PKP.

had additional vertebral fractures. One patient had an intertrochanteric femoral fracture. Two patients had bone cement leakage. For both groups, bone cement leakage did not cause clinical symptoms, thus these patients received no additional special treatment. The major side-effects of intravenous zoledronic acid were fever (10 cases) and fatigue along with facial flushing (4 cases). Patients were given 1000 mL normal saline before and after the infusion of zoledronic acid. Oral administration of celecoxib, loxoprofen or other non-steroidal anti-inflammatory drugs for 3 days postoperatively, remarkably reduced the side-effects.

DISCUSSION

Osteoporosis has become one of the most prevalent world-wide diseases. Gradual and progressive bone loss develops after 35 years of age, and women are at the greatest risk for osteoporosis after menopause. Vertebral body osteoporotic fracture is a serious complication of osteoporosis, especially in the elderly (2,8). Conservative management includes absolute bed rest for 3 months and oral administration of a non-steroidal anti-inflammatory drug. However, it has been reported that the nonsurgical management causes further loss of bone mass, aggravates osteoporosis, and leads to concurrent hypothyroidism, pressure ulcers, and cardiopulmonary complications. Cummings et al (9) reported that the mortality rate of conservative treatment for vertebral compression fractures is up to 20%, and about 50% of patients have sequelae. With the development of minimally invasive spine surgery, PKP has been extensively carried out in China since it was first introduced by Reiley et al (10) in 2001. In performing PKP, a needle is inserted through one or both pedicles, into the fractured vertebral body, through which a balloon is then inserted. This balloon is then inflated in attempts to restore vertebral body height and to create an intravertebral body cavity. Bone cement is then injected into this cavity. Before the cement hardens, the needle is removed. This procedure usually relieves pain rapidly, restores vertebral height, which as a result improves the kyphotic deformity, and increases vertebral body strength. Patients can ambulate and may be assisted by wearing a waist trainer 2 days after the surgery. PKP also significantly shortens a patient's hospital stay. Overall, PKP greatly improves the patient's quality of life.

One complications of PKP, additional vertebral body fractures, is controversial. Some scholars believe the injection of bone cement results in an increased

mechanical pressure, which eventually can cause a new fracture in an adjacent or removed vertebral body (11). However as patients continue to age, they commonly have a sedentary lifestyle and frequently are deficient in calcium and vitamin D. A study from Rho et al (12) indicates that the progression of osteoporosis as actually the major risk factor for additional vertebral body fractures following PKP surgery.

Zoledronic acid, a bisphosphonate, has been used as a prophylactic drug for preventing osteoporotic fractures. It is able to slow down the bone resorption by inhibiting osteoclastic activity and inducing osteoclast apoptosis (11). Zoledronic acid binds with a high affinity to hydroxyapatite on the surface of the bone and strongly inhibits the farnesyl pyrophosphate (FPP) synthase (an enzyme in the mevalonate pathway), which prevents protein prenylation in osteoclasts thereby inhibiting osteoclastic mediated bone resorption (13). Intravenous infusion of zoledronic acid is highly effective in reducing the risk of vertebral and non-vertebral fractures, especially in patients who cannot tolerate oral bisphosphonates (14-16). Spiegel et al (17) found that zoledronic acid is not only effective in treatment of osteoporosis for postmenopausal women, but also lowers the risk of vertebral fracture in male patients. Zoledronic acid has been approved by the United States and the European Union for the treatment of osteoporosis. It may be given as a 5 mg infusion once per year and has been shown to reduce the risk of osteoporotic fractures of the hip, vertebra and other non-vertebra osseous structures (such as wrist and ribs). Some common minor side effects of zoledronic acid are fever, flu-like symptoms, headache and joint pain that the majority of the patients can tolerate (18). In this study, 10 cases had fever and 4 had fatigue and facial flushing after the infusion of zoledronic acid. The side effects were alleviated over 3 days following the intravenous administration of fluids and oral administration of a nonsteroidal anti-inflammatory drug. We did not observe any serious complications of bisphosphonates such as osteonecrosis of the jaw (19), atrial fibrillation (20), severe intolerable myalgias (18), and glaucoma (21) in our patients treated with zoledronic acid.

CONCLUSION

In summary, our study shows that PKP surgery can rapidly relieve pain, improve or correct kyphosis, and improve the quality of life in patients with OVCF. Moreover, postoperative infusion of zoledronic acid

can significantly improve bone mineral density, relieve back pain and reduce the incidence of new fractures.

This combination procedure is worthy of further clinical evaluation in the treatment of patients with OVCF.

REFERENCES

- Gambacciani M, Levancini M. Management of postmenopausal osteoporosis and the prevention of fractures. *Panminerva Med* 2014; 56:115-131.
- Ballane G, Cauley JA, Luckey MM, El-Hajj Fuleihan G. Worldwide prevalence and incidence of osteoporotic vertebral fractures. *Osteoporos Int* 2017; 28:1531-1542.
- Bouza C, Lopez T, Magro A, Navalpotro L, Amate JM. Efficacy and safety of balloon kyphoplasty in the treatment of vertebral compression fractures: A systematic review. *Eur Spine J* 2006; 15:1050-1067.
- Denaro V, Longo UG, Maffulli N, Denaro L. Vertebroplasty and kyphoplasty. *Clin Cases Miner Bone Metab* 2009; 6:125-130.
- Li YX, Guo DQ, Zhang SC, Liang, Yuan K, Mo GY, Li DX, Guo HZ, Tang Y, Luo PJ. Risk factor analysis for re-collapse of cemented vertebrae after percutaneous vertebroplasty (PVP) or percutaneous kyphoplasty (PKP). *Int Orthop* 2018; 42:1-9.
- Knopp-Sihota JA, Newburn-Cook CV, Homik J, Cummings GG, Voaklander D. Calcitonin for treating acute and chronic pain of recent and remote osteoporotic vertebral compression fractures: A systematic review and meta-analysis. *Osteoporos Int* 2012; 23:17-38.
- Walter J, Hacıyakupoglu E, Waschke A, Kalff R, Ewald C. Cement leakage as a possible complication of balloon kyphoplasty--is there a difference between osteoporotic compression fractures (AO type A1) and incomplete burst fractures (AO type A3.1)? *Acta Neurochir (Wien)* 2012; 154:313-319.
- Gold DT. The clinical impact of vertebral fractures: Quality of life in women with osteoporosis. *Bone* 1996; 18:185S-189S.
- Cummings SR, Melton LJ. Epidemiology and outcomes of osteoporotic fractures. *Lancet* 2002; 359:1761-1767.
- Garfin SR, Yuan HA, Reiley MA. New technologies in spine: kyphoplasty and vertebroplasty for the treatment of painful osteoporotic compression fractures. *Spine (Phila Pa 1976)* 2001; 26:1511-1515.
- Berlemann U, Ferguson SJ, Nolte LP, Heini PF. Adjacent vertebral failure after vertebroplasty. A biomechanical investigation. *J Bone Joint Surg Br* 2002; 84:748-752.
- Rho YJ, Choe WJ, Chun YI. Risk factors predicting the new symptomatic vertebral compression fractures after percutaneous vertebroplasty or kyphoplasty. *Eur Spine J* 2012; 21:905-911.
- Dunford JE, Thompson K, Coxon FP, Luckman SP, Hahn FM, Poulter CD, Ebetino FH, Rogers MJ. Structure-activity relationships for inhibition of farnesyl diphosphate synthase in vitro and inhibition of bone resorption in vivo by nitrogen-containing bisphosphonates. *J Pharmacol Exp Ther* 2001; 296:235-242.
- Byun JH, Jang S, Lee S, Park S, Yoon HK, Yoon BH, Ha YC. The Efficacy of bisphosphonates for prevention of osteoporotic fracture: An update meta-analysis. *Journal of Bone Metabolism* 2017; 24:37-49.
- Nakamura T, Fukunaga M, Nakano T, Kishimoto H, Ito M, Hagino H, Sone T, Taguchi A, Tanaka S, Ohashi M, Ota Y, Shiraki M. Efficacy and safety of once-yearly zoledronic acid in Japanese patients with primary osteoporosis: Two-year results from a randomized placebo-controlled double-blind study (ZOledronicNate treatment in Efficacy to osteoporosis; ZONE study). *Osteoporos Int* 2017; 28:389-398.
- Yang BB, Chen YH, Zhang C, Shi CE, Hu KF, Zhou J, Xu DX, Chen X. Low vitamin D status is associated with advanced liver fibrosis in patients with nonalcoholic fatty liver disease. *Endocrine* 2016; 55:582-590.
- Spiegel R, Nawroth PP, Kasperk C. The effect of zoledronic acid on the fracture risk in men with osteoporosis. *J Endocrinol Invest* 2014; 37:229-232.
- Reid IR, Gamble GD, Mesenbrink P, Lakatos P, Black DM. Characterization of and risk factors for the acute-phase response after zoledronic acid. *J Clin Endocrinol Metab* 2010; 95:4380-4387.
- Bagan J, Peydro A, Calvo J, Leopoldo M, Jimenez Y, Bagan L. Medication-related osteonecrosis of the jaw associated with bisphosphonates and denosumab in osteoporosis. *Oral Dis* 2016; 22:324-329.
- Ilgezdi ZD, Aktas I, Dogan Metin F, Kepez A, Unlu Ozkan F, Silte AD, Yilmaz Kaysin M, Kivrak T, Cincin A, Erdogan O. Acute effect of zoledronic acid infusion on atrial fibrillation development in patients with osteoporosis. *Anatol J Cardiol* 2015; 15:320-324.
- Khan A, Lascaratos G, Rane-Malcolm T, Sanders R. A rare case of zoledronate infusion complication leading to glaucoma filtration surgery. *Clin Ophthalmol* 2011; 5:1147-1149.