

## A SYSTEMATIC REVIEW

## A SYSTEMATIC REVIEW OF DIAGNOSTIC UTILITY OF SELECTIVE NERVE ROOT BLOCKS

Clifford R. Everett, MD, Rinoo V. Shah, MD, Nalini Sehgal, MD, and Anne Marie McKenzie-Brown, MD

**Background:** Transforaminal epidural injections, or selective nerve root blocks, are used for a myriad of different spinal disorders. A clear consensus on the use of selective nerve root injections as a diagnostic tool does not currently exist. Additionally, the effectiveness of this procedure as a diagnostic tool is not clear.

**Objective:** The objective was to evaluate the accuracy of selective nerve root injections in diagnosing spinal disorders.

**Study Design:** The study involved a systematic review of diagnostic studies about selective nerve root blocks for the diagnosis of spinal pain.

**Methods:** A systematic review of the lit-

erature for clinical studies was performed to assess the accuracy of selective nerve root injections in diagnosing spinal disorders. Methodologic quality evaluation was performed utilizing AHRQ and QUADAS criteria. The methodology of the studies was graded and the evidence was classified into five levels: conclusive, strong, moderate, limited, or indeterminate.

**Results:** There is limited evidence on the effectiveness of selective nerve root injections as a diagnostic tool in spinal disorder. There is insufficient research into this area for strong support, but the available literature is supportive of selective nerve root injections as a diagnostic test in equivocal

radicular pain. The current analysis provides moderate evidence of transforaminal epidural injections in the preoperative evaluation of patients with negative or inconclusive imaging studies.

**Conclusions:** Selective nerve root injections may be helpful as a diagnostic addition in evaluating spinal disorders with radicular features, but the role of this diagnostic test needs to be further clarified by additional research and consensus on technique.

**Keywords:** Selective nerve root block, transforaminal epidural injection, spinal pain, discogenic pain, radiculopathy, nerve root pain

Pain that originates from the spine is frequently difficult to specifically diagnose as imaging abnormalities are frequently found in people without pain (1, 2). Excluding fractures, disorders of the human spine that produce pain, can be categorized as compressive, inflammatory, degenerative, or multifactorial combination.

For a structure to be painful it must have a nerve supply. It also must be capable of producing the pain described clinically. The structure must also be susceptible to disease or injury. For the structures that meet these criteria it is important to determine if this is the cause of the individuals' pain and treat it appropriately.

Methods have been developed to

test painful structures using fluoroscopic (x-ray) guided injections of anesthetics. If a structure is selectively anesthetized and the individual describes pain relief for the duration of the anesthetic medication, that structure is determined to be the source of pain (3). For compressive and inflammatory disorders of spinal nerve roots, the common area for this to occur is within the bony channel created between adjacent vertebrae named the neural foramen.

Spinal injections have received considerable study and interest in regards to therapeutic effect. Specifically, the use of epidural steroid injections in the treatment of spinal disorders has progressed as the procedures have become more exact with the aid of fluoroscopic or CT guidance. The indications have increased from radicular pain, to spinal stenosis, and lower back pain related to a discogenic cause (4-18). The use of specific foraminal and nerve root injections as a diagnostic tool does not have a consistent method of application or medication. In present literature, selective nerve root block (old nomenclature) or transforaminal epidural injection (modern nomenclature) consists of injection of contrast, local anesthetic, or other substances around spinal

nerves under fluoroscopy. Some injectionists use anesthetic alone; others use a smaller steroid dose, arguing that the steroid should not have an immediate response. The volumes used in the injection also vary by physician with some using a standard volume, and others using a volume consistent with the amount necessary to reach the lateral recess. Purists insist on describing them as two separate and distinct techniques. Over the years, authors have used them interchangeably. Despite the variance in practice, the technique holds promise as a diagnostic tool, but the reliability is unclear (17, 22-24).

The value of provocative and analgesic spinal injections was recognized in 1938 by Steindler and Luck (22). MacNab (23) in 1971 demonstrated the value of diagnostic, selective nerve root blocks in the preoperative evaluation of patients with negative or inconclusive imaging studies and clinical findings of nerve root irritation. Since then, nerve blocks have been used to diagnose the source of radicular pain when imaging studies suggested possible compression of several nerve roots (24-33). The relief of usual symptoms following the injection of local anesthetic (1 ml of 2% Xylocaine) is considered as the essential determinate for diag-

From: University of Rochester Medical Center, Rochester, NY; Texas Tech University, Lubbock, TX; University of Wisconsin Hospital & Clinics, Madison, WI; and Emory School of Medicine, Atlanta, GA  
Address Correspondence: Clifford Everett, MD, University of Rochester Medical Center, 601 Elmwood Avenue, Box 665, Rochester, NY 14642  
Disclaimer: Nothing of monetary value was received in the preparation of this manuscript.

Conflict of Interest: None

Acknowledgement:

Manuscript received on 12/06/2004

Revision submitted on 01/06/2005

Accepted for publication on 01/09/2005

nostic information. In 1992, Nachemson (34) analyzed the literature on low back pain and indicated that diagnostic, selective nerve root blocks provided important prognostic information about surgical outcomes. Van Akkerveeken (31) described the sensitivity, specificity, and predictive value for diagnostic, selective nerve root blocks. He also showed that for a block to be determined positive, it required concurrent symptom reproduction during root stimulation and full relief of pain following anesthetic infusion. However, transforaminal epidural or selective nerve root injection as a diagnostic entity is a controversial issue.

This systematic review was performed to determine if selective nerve root injections are an effective method for diagnosing spinal disorders..

**METHODS**

**Inclusion Criteria**

**Types of Studies**

Included in the analysis were controlled and uncontrolled clinical studies with diagnostic selective nerve root injections as a part of the study design.

**Types of Participants**

Subjects with pain of spinal origin

**Types of Interventions**

Selective nerve root injections performed under fluoroscopic guidance

**Types of Outcome Measures**

Pain relief, correlation with other diagnostic tests or therapeutic outcomes

**Exclusion Criteria**

**Types of Studies**

Non-clinical studies, expert opinion, or clear therapeutic studies

**Types of Interventions**

Non-selective nerve injections, with the route of administration not specifically described, were assumed to be interlaminar and for the purposes of this review, were rejected.

**Search Strategy**

Relevant clinical trials meeting the inclusion criteria for this review were identified in the following manner:

1. A computerized database search was performed of MEDLINE (1966-September 2004), CINAHL - Cumulative Index to Nursing & Allied Health Literature, EMBASE, EBM - Evidence Based Medicine Reviews (Cochrane Database and Cochrane Central Register of Controlled Trials). Specific search terms used to capture the greatest number of applicable studies were: Diagnostic techniques & procedures, nerve root block Injections, and Spine. Facet joints and zygapophyseal were specifically excluded from the search. Included

were English-only articles, or foreign language articles with an available English translation.

2. A review of the reference sections of the articles selected was also performed to identify potential additional studies for inclusion.

**Method of Review**

The computerized database search including the author, title, keywords, and abstract was printed and reviewed for exclusion criteria. If no clear exclusion criteria were identified within the abstract, the full journal article was obtained for review. The articles were reviewed by three physician reviewers. Articles were then abstracted for specific information on study design, number of patients, outcome studied, duration of study, and quality of study.

**Methodological Quality**

Quality of each individual article was evaluated by AHRQ (35) and QUADAS (36) criteria as shown in Tables 1 and 2.

**Strength of Evidence**

The level of evidence was evaluated as shown in Table 3.

**RESULTS**

**Literature Search**

The database search yielded 258 articles which were reviewed for inclusion or exclusion. For articles excluded, specific reasons were documented in the database article log. Of the 258 articles found during the search, seven were selected for review and abstracting.

**Methodological Quality**

Multiple articles were excluded as they were clinical outcome studies and not diagnostic studies (4-11, 13, 37-40). Reference lists for the selected articles were reviewed and yielded an additional eight articles. A total of 11 articles were selected for study (Fig. 1) The 11 available studies are outlined in (Table 4) (25-28, 31, 32, 41-45).

**Rationale**

In general, imaging studies can accurately demonstrate disc herniation or nerve root compression. However, it is necessary to differentiate symptomatic from asymptomatic levels of nerve compression in cases of multiple sites or levels of involvement, or in situations of confounding clinical features. The underlying

Table 1. Domains and elements for diagnostic studies developed by the Agency for Healthcare Research and Quality (AHRQ)

Domain*	Elements*
<i>Study Population</i>	<ul style="list-style-type: none"> <li>• <b>Subjects similar to populations in which the test would be used and with a similar spectrum of disease</b></li> </ul>
<i>Adequate Description of Test</i>	<ul style="list-style-type: none"> <li>• <b>Details of test and its administration sufficient to allow for replication of study</b></li> </ul>
<i>Appropriate Reference Standard</i>	<ul style="list-style-type: none"> <li>• <b>Appropriate reference standard ("gold standard") used for comparison</b></li> <li>• Reference standard reproducible</li> </ul>
<i>Blinded Comparison of Test and Reference</i>	<ul style="list-style-type: none"> <li>• Evaluation of test without knowledge of disease status, if possible</li> <li>• <b>Independent, blind interpretation of test and reference</b></li> </ul>
<i>Avoidance of Verification Bias</i>	<ul style="list-style-type: none"> <li>• <b>Decision to perform reference standard not dependent on results of test under study</b></li> </ul>

\*Key domains are in italics

\*Elements appearing in italics are those with an empirical basis. Elements appearing in bold are those considered essential to give a system a Yes rating for the domain.

Adapted from ref. 35

principle of selective nerve root local anesthetic injection is the premise that a local anesthetic will act only locally at the site of nerve root pain generation. Consequently it is presumed that any systematic effect of a local anesthetic diminishing specificity of such a block is minimal. In addition, it also has been reported that an anesthetic block distal to the site of nerve compression, as in a sciatic nerve block for nerve root compression, can, in fact, result in reduction of pain equal to nerve root

**Table 2. Items utilized for assessment of quality of individual articles of diagnostic studies by QUADAS tool**

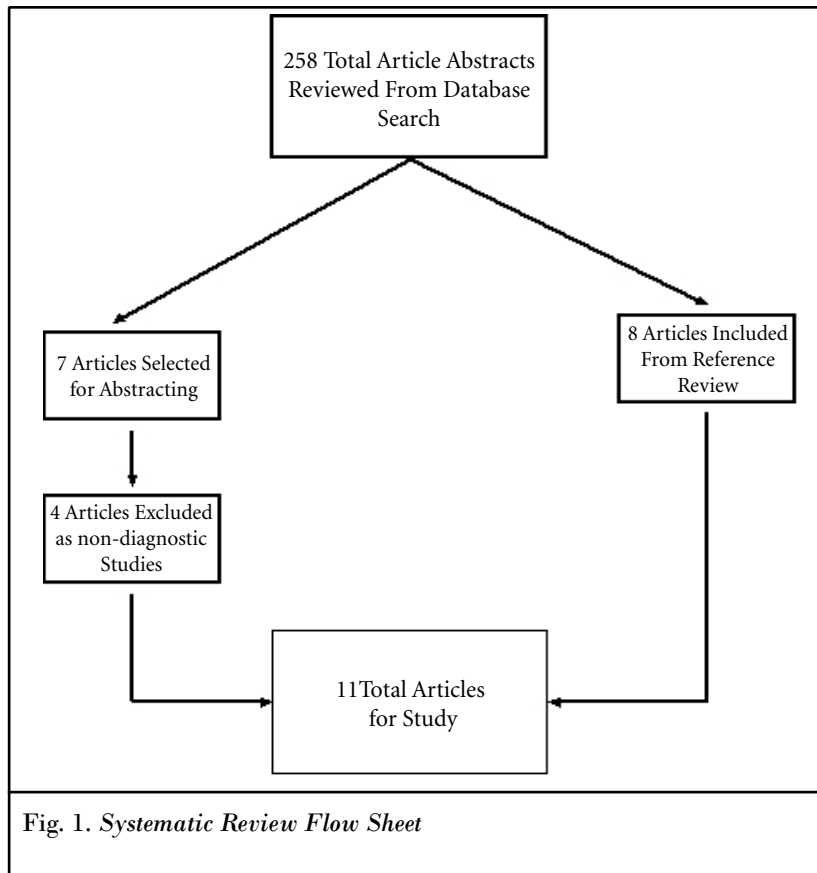
Item		Yes	No	Unclear
1.	Was the spectrum of patients representative of the patients who will receive the test in practice?	( )	( )	( )
2.	Were selection criteria clearly described?	( )	( )	( )
3.	Is the reference standard likely to correctly classify the target condition?	( )	( )	( )
4.	Is the time period between reference standard and index test short enough to be reasonably sure that the target condition did not change between the two tests?	( )	( )	( )
5.	Did the whole sample, or a random selection of the sample, receive verification using a reference standard of diagnosis?	( )	( )	( )
6.	Did patients receive the same reference standard regardless of the index test result?	( )	( )	( )
7.	Was the reference standard independent of the index test( <i>i.e.</i> , the index test did not form part of the reference standard)?	( )	( )	( )
8.	Was the execution of the index test described in sufficient detail to permit replication of the test?	( )	( )	( )
9.	Was the execution of the reference standard described in sufficient detail to permit its replication?	( )	( )	( )
10.	Were the index test results interpreted without knowledge of the results of the reference standard?	( )	( )	( )
11.	Were the reference standard results interpreted without knowledge of the results of the index test?	( )	( )	( )
12.	Were the same clinical data available when test results were interpreted as would be available when the test is used in practice?	( )	( )	( )
13.	Were uninterpretable/intermediate test results reported?	( )	( )	( )
14.	Were withdrawals from the study explained?	( )	( )	( )

Adapted from ref. 36

**Table 3. Designation of levels of evidence**

<b>Level I</b>	Conclusive: Research-based evidence with multiple relevant and high-quality scientific studies or consistent reviews of meta-analyses
<b>Level II</b>	Strong: Research-based evidence from at least one properly designed, randomized, controlled trial; or research-based evidence from multiple properly designed studies of smaller size; or multiple low quality trials.
<b>Level III</b>	Moderate: a) Evidence obtained from well-designed pseudorandomized controlled trials (alternate allocation or some other method); b) evidence obtained from comparative studies with concurrent controls and allocation not randomized (cohort studies, case-controlled studies, or interrupted time series with a control group); c) evidence obtained from comparative studies with historical control, two or more single-arm studies, or interrupted time series without a parallel control group.
<b>Level IV</b>	Limited: Evidence from well-designed nonexperimental studies from more than one center or research group; or conflicting evidence with inconsistent findings in multiple trials.
<b>Level V</b>	Indeterminate: Opinions of respected authorities, based on clinical evidence, descriptive studies, or reports of expert committees.

Adapted from ref. 16



blockade (41). Sensitivity of nerve root block was very high, compared with sciatic nerve block, posterior ramus block, or subcutaneous injection in a cohort of patients with sciatica (41). However, specificity was only moderate. The specificity of sciatic nerve block was equal to that of selective nerve root block (41). The selective nerve root block was considered as most helpful as a negative predictor for the presence of nerve compression if the block result was negative.

#### Study Characteristics

Salient features of included studies are shown in Table 4.

Slipman et al (42) examined the effects of mechanical stimulation on 87 patients and examined 134 cervical nerve roots. The patients then described to an independent observer the referred symptoms, (dynatome) on a pain diagram. This dynatomal map was compared to classic dermatomal maps. The dynatomal map distribution was similar to classic dermatomal maps, but frequently overlapped other dermatomes and had a larger distribution. This study emphasized the potential importance and advantage of a se-

lective nerve root block in evaluating patients with equivocal imaging and radicular pain.

Wolff et al (43) examined the hypesthetic response area following a lumbar selective nerve root block and compared this to classic dermatomal maps. They found that the hypesthetic area overlapped more than one classic dermatome. The addition of hypesthetic response to the paresthesias and blockade of pain provided a method of diagnosing clinically relevant spinal levels.

Dooley et al (28) performed a retrospective study on mechanical nerve stimulation followed by selective nerve root blocks, followed by surgical treatment. A single root involvement was confirmed in 85% of patients with concordant pain with mechanical nerve stimulation with needle placement and relief of pain with anesthetic along the nerve root. The evaluation was also helpful in separating patients without spinal problems and those with multiple levels of involvement.

Multiple authors (2, 4, 11, 13, 22-34, 44, 46-49) reported the value of selective nerve root blocks in the determination of the symptomatic levels in confound-

ing situations.

#### Principles

Transforaminal epidural steroid injections or selective nerve root blocks can be performed in order to test the hypothesis that a target nerve root is the source of a patient's pain. Selective nerve root block must be performed under fluoroscopic visualization utilizing a low volume local anesthetic of 0.5-1 ml. If the pain is not relieved, the nerve root cannot be considered as transmitting the pain. However, if the pain is completely relieved with a properly performed block without leakage into surrounding structures, the nerve root is considered as the source of the pain. As for facet joint block or sacroiliac joint blocks, and provocative discography, no standards have been established to eliminate false positive responses with transforaminal epidural injections (16, 17). However, true-positive responses may be secured by performing controlled blocks with placebo injections of normal saline. Comparative local anesthetic blocks which have been shown to be valid in the diagnosis of facet joint pain have not been studied for transforaminal usage.

#### Validity

Transforaminal epidurals or selective nerve root blocks have been shown to have face validity. Local anesthetic injected accurately onto the correct target point of the nerve root selectively infiltrates the target nerve, and may provide the validity. Thus, performing the procedure with low volume local anesthetic under fluoroscopic visualization and limiting the injection onto the target nerve will preserve the face validity. However, the construct validity of selective nerve root blocks has not been established. Thus, it is not known in every individual case, whether the response is a true positive or not. Significant false positive rates have been described with multiple other diagnostic interventional techniques (16).

In addition to the false positive result, multiple confounding factors of psychological issues and sedation have not been studied for selective nerve root blocks.

#### Criterion

Even though results of biopsy or autopsy are not available to confirm specificity and sensitivity of selective nerve root blocks, surgical confirmation and clini-

Table 4. Characteristics of articles included in systematic review

Study/Methods	Number	Intervention	Outcomes	Results	Conclusions
Anderberg et al (45) Prospective cohort  AHRQ Score - 4/5 QUADAS Score - 11/14	20	Nerve Block with MRI & surgical correlation in cervical radicular pain	VAS and surgical outcome	18/20 with good relief post block had surgery with none having radicular pain after surgery	Positive surgical response with positive SNRB
Slipman et al (42) Prospective Study  AHRQ Score - 4/5 QUADAS Score - 11/14	87	Cervical Nerve Root Mechanical Stimulation	Pain Mapping Diagram	Dermatomal maps differ from Dynatomal Maps	Referral Patterns may differ from classic dermatomal maps
Wolff et al (43) Prospective Study  AHRQ Score - 4/5 QUADAS Score = 10/14	29	Selective Nerve Root Injections	Sensory Testing after SNRB	Hypesthetic areas post block were variable and larger than paresthetic areas pre block	Nerve Root Block Patterns may differ from classic dermatomal maps
Kremphen and Smith (25) Prospective Study  AHRQ Score - 3/5 QUADAS Score - 11/14	22	Mechanical Stimulation and Selective Nerve Root Injections	Concordant pain response to injection and surgical outcome in 16 of the 22 patients	In the 16 patients that underwent surgery after positive response to the injection all improved with surgery and had corresponding lesions at the level suggested	SNRB is helpful diagnostically in surgical planning
Hauelsen et al (27) Retrospective Study  AHRQ Score - 3/5 QUADAS Score - 9/14	105	SNRB post laminectomy with surgical re-exploration	Comparison of Surgical findings with SNRB vs. Myelogram	In patients with positive SNRB positive surgical pathology	SNRB helpful diagnostically in patients post laminectomy
Herron (32) Retrospective Case Series  AHRQ Score - 3/5 QUADAS Score - 9/14	215 (78 underwent surgery)	SNRB prior to Surgery	Comparison of Surgical findings and outcome	In patients with positive SNRB mostly positive outcomes	SNRB helpful diagnostically in patients without prior surgery
Dooley et al (28) Retrospective Case Series  AHRQ Score - 4/5 QUADAS Score - 10/14	62	Mechanical Stimulation with needle and SNRB compared with surgical exploration	Comparison of Surgical outcome with SNRB response	In patients with positive SNRB positive surgical pathology	SNRB helpful diagnostically in patients when mechanical stimulation and SNRB concordant
Tajima et al (26) Prospective Case Series  AHRQ Score - 3/5 QUADAS Score - 9/14	106	Mechanical Stimulation with needle and SNRB compared with myelogram and surgical exploration	Comparison of SNRB response to imaging and surgical findings	In patients with positive SNRB imaging and surgical pathology were concordant	SNRB was helpful diagnostically in patients when mechanical stimulation and SNRB were concordant. Also the site of entrapment was consistent with surgical findings
Van Akkerveeken (31) Prospective Case Series  AHRQ Score - 3/5 QUADAS Score - 7/14	46	Mechanical Stimulation followed by SNRB with Marcaine.	Comparison of SNRB response to imaging and surgical pathology	Sensitivity 100% Specificity 90% Positive Predictive Value for good surgical result was excellent at 70-95% depending on statistics	SNRB was highly sensitive and specific with a high positive predictive value for surgical outcome.
North et al (41) Randomized Single Blind Prospective Trial  AHRQ Score - 4/5 QUADAS Score - 11/14	33	Spinal blocks of the facets, sciatic nerve, medial branch blocks, and trigger point blocks	Comparison of different blocks to selective nerve root blocks	Sensitivity 91% Specificity 24% Sciatic nerve block was also effective in relieving pain known to be proximal to the block.	SNRB may be helpful if negative but within this study was not specific.
Stanley et al (44) Prospective Consecutive Series  AHRQ Score - 4/5 QUADAS Score - 12/14	50	Selective nerve root blocks and radiculography with surgery	Comparison of SNRB and radiculography to surgical findings and outcome	Radiculography was not helpful in identifying the site of entrapment. SNRB were helpful in selecting patients with single level entrapment for surgery.	SNRB may be helpful in selecting patients for surgery with single level entrapment.

cal results provide a reliable gold standard (27, 32, 44, 46, 49).

Hauelsen et al (27) in an early study on patients with post-laminectomy radicular symptoms compared the diagnostic accuracy of spinal nerve root injections with Xylocaine to myelogram for surgical pathology and outcome. Of the 105 patients studied with selective nerve root injections, 55 underwent surgical re-exploration. Selective nerve root injections were accurate in making a diagnosis consistent with surgical pathology in 43 out of the 55 patients, or 93%; myelogram was accurate in 24%. The surgical outcome at an average of 20 months was improvement in 73% of the patients. They concluded that, in patients with surgically altered anatomy selective nerve root blocks are helpful in making an accurate diagnosis.

Herron (32) examined the response to selective nerve root blocks as a means to assure spinal origin for the pain complaint. The surgical outcomes were as expected with patients having the best outcome for lumbar disc herniation and spinal stenosis and doing poorly with a history of prior surgery. The response to injection was helpful in narrowing potential surgical patients from 215 to 71 patients who subsequently underwent surgical repair.

Tajima (26), in an early study of this technique, compared the response for 106 patients to mechanical stimulation and anesthetic response to myelogram and surgical outcome. Comparison to the normal dye patterns in reference patients and cadaveric dye patterns was also attempted to clarify the role of radiculograms as a diagnostic imaging tool. The disorders studied were diverse but selective nerve root block was helpful in determining the painful level in the majority of patients with corresponding abnormalities found on surgical repair. Additionally it was helpful in limiting the surgical decompression to the area of primary pain generation.

Anderberg et al (45) performed a prospective study on 20 patients with cervical selective nerve root blocks and a comparison of post surgical response. Of the 20 patients studied, 18 had a positive cervical selective nerve root block that corresponded to MRI findings, and complete post surgical pain relief.

#### Accuracy

Accuracy of any test is measured by

sensitivity and specificity. Specificity is a relative measure of the prevalence of false-positives, whereas sensitivity is the relative prevalence of false-negative results. There are multiple confounding factors with selective nerve root blocks that may lead to a false positive result in spite of precautions. There are also numerous structures in close proximity that could also affect a false-positive block. Consequently, selective nerve root blocks are considered to have an excessively high level of sensitivity with a moderate or low level of specificity. As compared with sciatic nerve, posterior ramus block, or subcutaneous injection, a selective nerve root block in patients with sciatica has been shown to have high sensitivity (41), however, the specificity was judged to be only moderate. In fact the specificity of sciatic nerve block was as good as or equal to a selective nerve root block (41).

The sensitivity and specificity of diagnostic selective nerve root block ranges from 45-100% (24, 25, 28, 31, 44). Schutz et al (24) reported finding a corroborative lesion at the time of surgery in 87% of patients with a positive diagnostic block. Krempen and Smith (25) reported 100% surgical confirmation following a positive block. Dooley et al (28) reported three out of 51 blocks to be false positive, providing a specificity of 94%. Stanley et al (44) reported a 95% specificity. VanAkkerveeken (31) attempted to establish the diagnostic value of selective nerve root injections. In 37 patients with confirmed lumbar radiculopathy, compared to nine patients with pain due to metastases, it was found that the sensitivity for determining pain of spinal neural origin was 100%. The specificity was studied by comparison to a normal level on imaging and exam with a selective nerve root block, and was 90%. Of the 37 patients with lumbar radiculopathy, some declined surgery. The predictive value for a good outcome was determined with, and without, the patients who did not want surgery. If all patients who declined surgery were included in the analysis as surgical failures, the positive predictive value of a good surgical outcome with a positive selective nerve root block was 70%. The positive predictive value was 95% when patients who had surgery were the only ones included in the analysis. Within this study, selective nerve root injections were a highly sensitive, specific test with high predictive value for surgical outcome.

Anderberg et al (45) reported 96% specificity. Hauelsen et al (27) reported 93% specificity. Dooley et al (28) reported 85% specificity.

However, these high levels of specificity and sensitivity have not been proven in controlled trials. It is imperative to compare these results in light of the evidence shown by North et al (41).

#### Diagnostic Validity

Diagnostic selective nerve root injection is typically performed in a patient with persistent pain when their history, examination, imaging and other precision diagnostic injections and electrophysiology testing do not clarify the pain generator. Kikuchi et al (30) estimated that 20% of patients presenting with radicular pain required diagnostic nerve root blocks. Derby et al (49) reported that patients who failed to obtain sustained radicular pain relief following the transforaminal blocks were less likely to benefit from subsequent surgical intervention. Manchikanti et al (3), in exploring the role of transforaminal epidural injections in the diagnosis of low back pain of undetermined origin, performed transforaminal epidural injections in 35 patients, in a cohort of 120 patients. Of the 35 patients undergoing transforaminal epidural injections, 16 responded with pain relief. Herron (32) found the procedure useful in identifying previously undocumented disc herniations, the symptomatic level in multi-disc herniation, the primary pain generator in the spine-hip syndrome, previously undocumented root irritation and spondylolisthesis, the symptomatic level in multi-level stenosis, and the symptomatic route in patients with documented post operative fibrosis. White (50) supported the use of diagnostic selective nerve root blocks as a pre-surgical test in patients with equivocal anatomic finds. Pang et al (51) utilizing application of spinal pain mapping in the diagnosis of low back pain in 104 cases, reported that lumbar nerve root involvement was noted in 44% of the patients.

#### Methodological Quality

Methodological Quality of these articles was judged by the criteria described by AHRQ (35) as well as QUADAS (36) as shown in Tables 1 and 2. The criteria and description of studies are shown in Table 4.

### Strength of Evidence

Based on the review of all available studies, there is strong evidence that nerve root pain may be relieved with an appropriately performed selective nerve root block. However, based on the review of all the evaluations, the current analysis provides limited evidence of transforaminal epidural injections as a diagnostic tool for spinal disorders. The current analysis also provides moderate evidence for transforaminal epidural injections in the preoperative evaluation of patients with negative or inconclusive imaging studies, but with clinical findings of nerve root irritation.

### DISCUSSION

This systematic review of the literature pertaining to selective nerve root blocks, or transforaminal epidural injections shows that the sensitivity and specificity of selective nerve root block ranges from 45-100%. Consequently, diagnostic selective nerve root block may be considered as an effective technique in evaluating patients with multilevel pathology to ascertain which level is the pain generator. Similarly, it may also be useful when the location of symptoms seems to conflict with abnormalities identified with imaging findings. Selective nerve root blocks also have been supported as a presurgical test in patients with equivocal anatomic findings. Further, they were found to be useful in identifying previous undocumented disc herniation. They are helpful in determining the symptomatic level in multilevel disc herniation, the primary pain generator in the spine-hip syndrome, previous undocumented root irritation and spondylolisthesis, the symptomatic level in multilevel stenosis, and the symptomatic route in patients with documented postoperative fibrosis. Prevalence of nerve root pain has been reported to be 44% in one study (51) in patients with low back pain of undetermined etiology after medical history, physical examination, radiographic examination, and electrophysiologic examination.

The severe limitations of our evaluation include the methodological quality of the studies available at present. The evaluation shows conflicting results, while proponents show good sensitivity and specificity. Others (41) indicate caution and also reveal that the sensitivity of nerve root block is very high whereas its specificity is only moderate. In fact the spec-

ificity of sciatic nerve block was as good as a selective nerve root block. However, the sensitivity of selective nerve root block was high when compared to sciatic nerve block, posterior ramus block, and subcutaneous injection in a cohort of patients with sciatica (41).

In contrast to facet joint blocks, the diagnostic selective nerve root blocks have been confirmed with surgical confirmation apart from clinical results. However, the specific limitations for interventional techniques also extend to transforaminal epidural injections. Further, transforaminal epidurals lack a proven methodology to avoid false positives. Utilizing the pain relief in a given patient as a standard can be neither confirmed nor denied. As a result, in terms of specificity and sensitivity, the true accuracy of transforaminal epidural steroid injections based on pain relieving phenomenon is uncertain. Further, transforaminal epidural injections are more similar to physical examination than most laboratory tests used in clinical medicine, which, because a diagnostic confirmation can be accomplished, can have an absolute gold standard for comparison to determine their true accuracy. Saal (17) described the general principles of diagnostic testing and appraised current diagnostic techniques as they relate to painful lumbar spine disorders. Rather than concluding that current diagnostic tests are invalid or should be used less, Saal suggested their results should be considered in the light of inaccuracies present in all diagnostic tests in medicine. Clinicians can use this perspective to appropriately prioritize the data from these tests along with the earlier clinical data gathered sequentially from history, physical examination, and noninterventional imaging studies. With this information in hand, the clinician and patient can choose appropriate therapies for the given painful spinal disorder (17, 52-55).

There have been no systematic reviews to compare our results of the past reviews. However, Manchikanti et al (16) in preparation of guidelines for interventional techniques, summarized the evidence for transforaminal epidurals as moderate in the preoperative evaluation of patients with negative or inconclusive imaging studies, but with clinical findings of nerve root irritation. In the present review we have utilized all the studies utilized by Manchikanti et al (16) and also further literature available since then.

The inability of the physician to provide appropriate and accurate diagnosis for a patient with chronic spinal pain is frustrating not only for the patient but also the physician. Without clearcut findings from physical examination, history, radiologic evaluation, electrophysiologic examination, and psychological evaluation, once facet joint pain and discogenic pain is ruled out, the diagnostic transforaminal epidural injection is the only alternative left. They are also helpful in multiple conditions as described earlier.

### CONCLUSION

There is moderate evidence as to the effectiveness of selective nerve root injections as a diagnostic tool in spinal disorders with radicular complaints. There is limited research into this area, but the available literature is supportive of selective nerve root injections as a diagnostic test in equivocal radicular pain. Additional research is necessary into the role of selective nerve root injections as a diagnostic tool in spinal disorders. Further research is necessary to determine the accuracy of selective nerve root blocks in determining surgical and non-surgical treatment outcomes compared to other established diagnostic imaging and electrodiagnostic tests.

### ACKNOWLEDGEMENTS

The authors wish to thank the editors of Pain Physician for peer review and constructive criticism.

**AUTHOR AFFILIATION:****Clifford R. Everett, MD**

Assistant Professor  
University of Rochester Medical Center  
601 Elmwood Avenue, Box 665  
Rochester, NY 14642  
E-mail: clifford\_everett@URMC.  
Rochester.edu

**Rinoo V. Shah, MD**

Assistant Professor  
Pain Fellowship Director  
Interventional Pain Institute  
Texas Tech University Health Sciences  
Center  
4430 South Loop 289  
Lubbock, TX 79414  
E-mail: rinoo\_shah@yahoo.com

**Nalini Sehgal, MD**

Medical Director  
UW Interventional Pain  
Program  
University of Wisconsin  
Medical School  
Dept, of Orthopedics and  
Rehabilitation  
600 Highland Avenue, #2424  
Madison, WI 53792  
E-mail: n.sehgal@hosp.wisc.edu

**Anne Marie McKenzie-Brown, MD**

Assistant Professor  
Division Chief, Pain Medicine  
Emory Department of Anesthesiology  
Emory School of Medicine  
550 Peachtree Street, NE  
Atlanta GA 30308  
E-mail: anne\_marie\_mckenzie-  
brown@emory.org

**REFERENCES**

- Boden SD, Davis DO, Dina TS, Patronas NJ, Wiesel SW. Abnormal magnetic-resonance scans of the lumbar spine in asymptomatic subjects: a prospective investigation. *J Bone Joint Surg Am* 1990; 72:403-408.
- Beattie PF, Meyers SP, Stratford P, Millard RW, Hollenberg GM. Associations between patient report of symptoms and anatomic impairment visible on lumbar magnetic resonance imaging. *Spine* 2000; 23:819-828.
- Manchikanti L, Singh V, Pampati VS, Damron KS, Barnhill RC, Beyer C, Cash KA. Evaluation of the relative contributions of various structures in chronic low back pain. *Pain Physician* 2001; 4:308-316.
- Riew KD, Yin Y, Gilula L, Bridwell KH, Lenke LG, Laurusen C, Goette K. The effect of nerve root injections on the need for operative treatment of lumbar radicular pain. *J Bone Joint Surg Am* 2000; 82A:1589-1593.
- Kraemer J, Ludwig J, Bickert U, Owczarek V, Traupe M. Lumbar perineural epidural injection: a new technique. *Eur Spine J* 1997; 6:357-361.
- Thomas E, Cyteval C, Abiad L, Picot MC, Taourel P, Blotman F. Efficacy of transforaminal versus interspinous corticosteroid injection distal radiculalgia – a prospective, randomized, double-blind study. *Clin Rheum* 2003; 22:299-304.
- Karppinen J, Malmivaara A, Kurunlahti M. Periradicular infiltration for sciatica. *Spine* 2001; 26:1059-1067.
- Vad VB, Bhat AL, Lutz GE, Cammisa F. Transforaminal epidural steroid injections in lumbosacral radiculopathy: a prospective randomized study. *Spine* 2002; 27:11-15.
- Lutz GE, Vad VB, Wisneski RJ. Fluoroscopic transforaminal epidural steroid injections: An outcome study. *Arch Phys Med Rehabil* 1998; 79:1362-1366.
- Bush K, Hillier S. Outcome of cervical radiculopathy treated with periradicular epidural corticosteroid injections: A prospective study with independent clinical review. *Eur Spine J* 1996; 5:319-325.
- Weiner BK, Fraser RD. Foraminal injection for lateral lumbar disc herniation. *J Bone Joint Surg Br* 1997; 79B:804-807.
- Manchikanti L, Pampati VS, Rivera JJ, Beyer C, Damron K, Barnhill R. Caudal epidural injections with sarapin steroids in chronic low back pain. *Pain Physician* 2001; 4:322-335.
- Rosenberg SK, Grabinsky A, Kooser A, Boswell M. Effectiveness of transforaminal epidural steroid injections in low back pain: a one year experience. *Pain Physician* 2002; 5:266-270.
- Wang JC, Lin E, Brodke DS, Youssef JA. Epidural injection for the treatment of symptomatic lumbar herniated discs. *J Spinal Disord Tech* 2002; 15:269-272.
- Botwin KP, Gruber RD, Bouchlas CG, Torres-Ramos FM, Sanelli JT, Freeman ED, Slaten WK, Rao S. Fluoroscopically guided lumbar transforaminal epidural steroid injections in degenerative lumbar stenosis: An outcome study. *Am J Phys Med Rehabil* 2002; 81:898-905.
- Manchikanti L, Staats P, Singh V, Schultz D, Vilims B, Jasper J, Kloth D, Trescot A, Hansen H, Falasca T, Racz G, Deer T, Burton A, Helm S, Lou L, Bakhit C, Dunbar E, Atluri S, Calodney A, Hassenbusch S, Feler C. Evidence-based practice guidelines for interventional techniques in the management of chronic spinal pain. *Pain Physician* 2003; 6:3-80.
- Manchikanti L. Transforaminal lumbar epidural steroid injections. *Pain Physician* 2000; 3:374-398.
- Manchikanti L, Cash K, Pampati VS, Damron K, McManus C. Evaluation of lumbar transforaminal epidural injections with needle placement and contrast flow patterns: A prospective, descriptive report. *Pain Physician* 2004; 7:217-223.
- Hogan QH, Abram SE. Neural blockade for diagnosis and prognosis a review. *Anesthesiology* 1997; 86:216-241.
- Saal JS. General principles of diagnostic testing as related to painful lumbar spine disorders: a critical appraisal of current diagnostic techniques. *Spine* 2002; 27:2538-2545.
- Hildebrandt J. Relevance of nerve blocks in treating and diagnosing low back pain – is the quality decisive? [German-translated] *Schmerz* 2001; 15:474-483.
- Steindler A, Luck JV. Differential diagnosis of pain in the low back: Allocation of the source of the pain by the procaine hydrochloride method. *JAMA* 1938; 110:106-113.
- MacNab I. Negative disc exploration: An analysis of the causes of nerve root involvement in sixty-eight patients. *J Bone Joint Surg [AM]* 1971; 53A(5):891-903.
- Schutz H, Loughheed WM, Wortzman G, Awerbuck BG. Intervertebral nerve-root in the investigation of chronic lumbar disc disease. *Can J Surg* 1973; 16:217-221.
- Krempen JF, Smith BS. Nerve root injection: A method for evaluating the etiology of sciatica. *J Bone Joint Surg [AM]* 1974; 56A:1435-1444.
- Tajima T, Furukawa K, Kuramochi E. Selective lumbosacral radiculography and block. *Spine* 1980; 1:68-77.
- Haueisen DC, Smith BS, Myers SR, Pryce ML. The diagnostic accuracy of spinal nerve injection studies. *Clin Orthop Rel Res* 1985; 198:179-183.
- Dooley JF, McBroom RJ, Taguchi T, Macnab I. Nerve root infiltration in the diagnosis of radicular pain. *Spine* 1988; 13:79-83.
- Castro WH, van Akkerveeken PF. Der diagnostische Wert der selektiven lumbalen Nervenwurzelblockade. *A orthop Ihre Grenzgeb* 1991; 129:376-379.
- Kikuchi S, Hasue M, Nishiyama K. Anatomic and clinical studies of radicular symptoms. *Spine* 1984; 9:23-30.
- Van Akkerveeken PF. The diagnostic value of nerve root sheath infiltration. *Acta Orthop Scand Supplementum* 1993; 251:61-63.
- Herron LD. Selective nerve root block in patient selection for lumbar surgery: Surgical results. *J Spinal Disord* 1989; 2:75-79.
- Hoppenstein R. A new approach to the failed back syndrome. *Spine* 1980; 5:371-379.
- Nachemson A. Newest knowledge of low back pain: A critical look. *Clin Orthop Rel Res* 1992; 279:8-20.
- West S, King V, Carey T, Lohr K, McKoy N, Sutton S, Lux L. Systems to rate the strength of scientific evidence. Evidence Report/Technology Assessment No. 47 University of North Carolina: Agency for



- Healthcare Research and Quality. AHRQ Publication No. 02-E016; April 2002.
36. Whiting P, Rutjes A, Reitsma J, Bossuyt P, Kleijnen J. The Development of QUADAS: A tools for the quality assessment of studies of diagnostic accuracy included in systematic reviews. *BMC Med Res Methodol* 2003; 3:25.
  37. Groenemeyer DH, Gevargez A, Schindler O, Schirp S, Braun M. CT guided periradicular injections of corticosteroids in the management of lumbar radiculopathy associated with disk herniation. *J Radiol* 2001; 1-12.
  38. Schmid G, Vetter S, Bottmann D, Streckler EP. CT-guided epidural/perineural injections in painful disorders of the lumbar spine: Short- and Extended-term results. *Cardiovasc Intervent Radiol* 1999; 22:493-498.
  39. Strobel K, Pfirrmann CW, Schmid M, Hodler J, Boos N, Zanetti M. Cervical nerve root blocks: indications and role of MR imaging. *Radiology* 2004; 233(1):87-92.
  40. Koning HM, Koning AJ. Prolonged pain relief following selective nerve root infiltration. *Pain Clinic* 2003; 15:225-233.
  41. North RB, Kidd DH, Zahurak M, Piantadosi S. Specificity of diagnostic nerve blocks: A prospective, randomized study of sciatica due to lumbosacral spine disease. *Pain* 1996; 65:77-85.
  42. Slipman CW, Plastaras CT, Palmitier RA, Huston CW, Sterenfeld EB. Symptom provocation of fluoroscopically guided cervical nerve root stimulation: are dynatomal maps identical to dermatomal maps? *Spine* 1998; 23:2235-2242.
  43. Wolff AP, Groen GJ, Crul BJ. Diagnostic lumbosacral segmental nerve blocks with local anesthetics: a prospective double-blind study on the variability and interpretation of segmental effects. *Regional Anesth Pain Med* 2001; 26:147-155.
  44. Stanley D, McLaren MI, Euinton HA, Getty CJ. A prospective study of nerve root infiltration in the diagnosis of sciatica: A comparison with radiculography, computed tomography, and operative findings. *Spine* 1990; 6:540-543.
  45. Anderberg L, Annertz M, Brandt L, Save-land H. Selective diagnostic cervical nerve root block – correlation with clinical symptoms and MRI-pathology. *Acta Neurochir* 2004; 146:559-565.
  46. North RB, Kidd DH, Campbell JN, Long DM. Dorsal root ganglionectomy for failed back surgery syndrome: A 5-year follow-up study. *J Neurosurg* 1991; 74:236-242.
  47. Porter D, Valentine A, Bradford R. A retrospective study to assess the results of CT-directed perineural root infiltration in a cohort of 56 patients with low back pain and sciatica. *Br J Neurosurg* 1999; 13:290-293.
  48. Slosar P, White A, Wetzel F. Controversy: The use of selective nerve root blocks: Diagnostic, therapeutic, or placebo? *Spine* 1998; 23:2253-2256.
  49. Derby R, Kine G, Saal JA, Reynolds J, Goldthwaite N, White AH, Hsu K, Zucherman J. Response to steroid and duration of radicular pain as predictors of surgical outcome. *Spine* 1992; 17 (Suppl):176-183.
  50. White A. Injection techniques for the diagnosis and treatment of low back pain. *Orthop Clin N Am* 1983; 14:553-567.
  51. Pang WW, Mok MS, Lin ML, Chang DP, Hwang MH. Application of spinal pain mapping in the diagnosis of low back pain – analysis of 104 cases. *Acta Anaesthesiol Sin* 1998; 36:71-74.
  52. Deyo R, Rainville J, Kent D. What can the history and physical examination tell us about low back pain? *JAMA* 1992; 268:760-765.
  53. Griner PF, Mayewski RJ, Mushlin AI, Greenland P. Selection and interpretation of diagnostic tests and procedures: Principles and applications. *Ann Intern Med* 1981; 94:553-597.
  54. Ito M, Incorvaia KM, Yu SF, Fredrickson BE, Yuan HA, Rosenbaum AE. Predictive signs of discogenic lumbar pain on magnetic resonance imaging with discography correlation. *Spine* 1998; 23:1252-1258.
  55. Nicoll D, Pignone M. Basic principles of diagnostic test use and interpretation. In Nicoll D et al (eds). *Pocket Guide to Diagnostic Tests*, 3rd ed. McGraw-Hill, New York 2001, pp 1-21.