

## A CASE REPORT

## VERTEBRAL AUGMENTATION COMPLICATED BY PERIOPERATIVE ADDISONIAN CRISIS

Alexander J. Nemeth, MD, Theresa J. Lie-Nemeth, MD, John J. A. Marota, MD, PhD, Johnny C. Pryor, MD, James D. Rabinov, MD, and Joshua A. Hirsch, MD

**Background:** We describe a case of perioperative Addisonian crisis induced by vertebral augmentation. While several complications of vertebral augmentation have been reported previously, related to the technical procedure, to our knowledge, perioperative Addisonian crisis from vertebral augmentation has not been reported in the literature.

**Objective:** To report an Addisonian crisis perioperative to vertebral augmentation.

**Design:** Case report.

**Method:** Retrospective case review.

**Results:** The patient had a history of adrenal insufficiency treated previously with steroids. He developed an L3 vertebral compression fracture, failed conservative therapy and was eventually referred for vertebral augmentation. Immediately after starting the procedure, the patient developed profound hypotension unresponsive to intravenous fluids and vasopressors, consistent with Addisonian crisis. After intravenous steroids had resolved the Addisonian crisis, he under-

went vertebral augmentation without further complication.

**Conclusion:** Addisonian crisis may be triggered by vertebral augmentation. Practitioners need to recognize immediately this potentially lethal disorder in patients with known or suspected adrenal insufficiency and treat with intravenous hydrocortisone.

**Key words:** Vertebral augmentation, Image-guided procedure, Vertebral compression fracture, Metabolic abnormality, Critical care

Several complications of vertebral augmentation have been reported previously (1-4). These include bleeding, infection, pain exacerbation, vertebral or rib fracture, paralysis, and leakage of polymethylmethacrylate (PMMA) cement into surrounding soft tissues or veins, possibly leading to pulmonary embolus. To our knowledge, the complication of perioperative Addisonian crisis induced by vertebral augmentation has not been reported previously in the literature.

Patients with a history of adrenal insufficiency are predisposed to developing Addisonian crisis perioperatively.

If a susceptible patient is subjected to a major stressor such as surgery, adrenal crisis, also known as Addisonian crisis, may occur on the basis of aldosterone deficiency and insufficient cortisol response to stress (5, 6). The most concerning consequence of Addisonian crisis is severe hypotension and shock refractory to the intravenous administration of fluids and pressors.

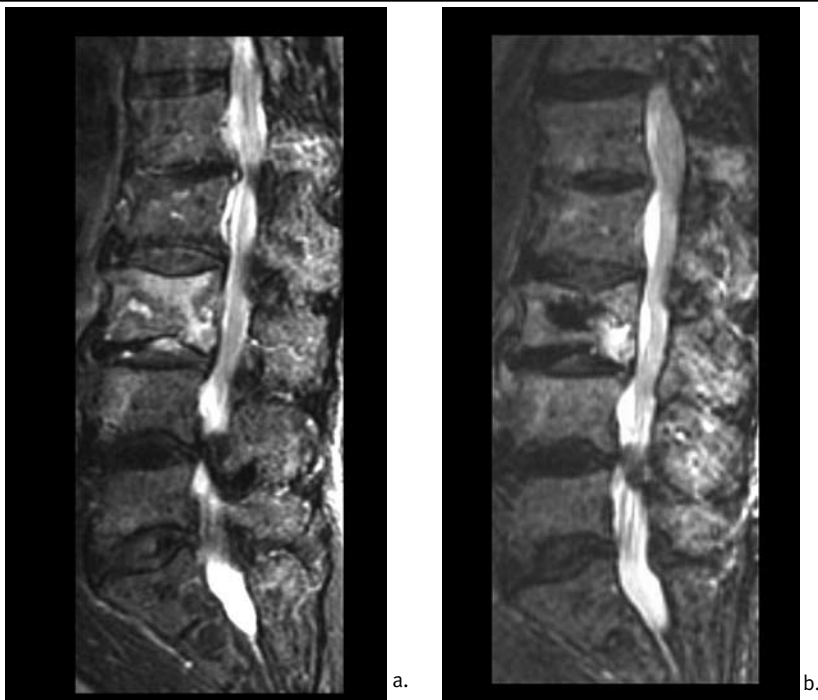The prevalence of adrenal insufficiency, the condition predisposing to Addisonian crisis, is 4 to 11 cases per 100,000 adults (6). Given the prevalence of adrenal insufficiency, Addisonian crisis should be considered as a cause of perioperative profound hypotension. In a study of 105 general surgical patients with perioperative hypotension, the hypotension was the result of acute adrenal insufficiency in 5 of the patients, equivalent to 5% of the study group (7). The number of affected patients in that study would indicate that familiarity with Addisonian crisis as a potential cause of perioperative hemodynamic compromise is necessary.

### CASE REPORT

An 87-year-old man with a history of adrenal insufficiency and chronic low back pain presented to the emergency room with worsened back pain. Lumbar spine magnetic resonance imaging demonstrated an acute L3 compression fracture (Fig 1a).

The patient's adrenal insufficiency was diagnosed 3 years earlier during evaluation for a presyncopal episode. At that time, he was found to have a low serum sodium level of 132 mmol/L (normal 135 to 145 mmol/L) and a high serum potassium level of 5.2 mmol/L (normal 3.4 to 4.8 mmol/L). These laboratory abnormalities led the patient's physician to obtain a cortisol level that was less than 1 mcg/dL (normal 5 to 25 mcg/dL from 8 a.m. to 12 p.m., 5 to 15 mcg/dL from 12 p.m. to 8 p.m., less than 10 mcg/dL from 8 p.m. to 8 a.m.) The patient was treated with prednisone and fludrocortisone acetate for approximately four months until his serum cortisol level normalized to 19.8

From: Department of Radiology, Massachusetts General Hospital, Boston, MA; Spaulding Rehabilitation Hospital, Boston, MA; and Harvard Medical School, Boston, MA  
Address Correspondence: Alexander J. Nemeth, MD, Massachusetts General Hospital Neuroradiology, Gray 2, Room B285, 55 Fruit St., Boston, MA 02114  
Email: anemeth@partners.org  
Disclaimer: There was no external funding in preparation of this manuscript.  
Conflict of interest: None  
Manuscript received on 4/22/06  
Revision submitted on 6/6/06  
Accepted for publication on 6/8/06



**Fig 1.** *a. Short tau inversion recovery (STIR) sequence performed at presentation of acute-on-chronic low back pain shows T2-weighted hyperintense signal in the L3 vertebra consistent with acute compression fracture. b. Sagittal STIR sequence performed after vertebral augmentation shows T2-weighted hypointense signal in L3 consistent with PMMA cement.*

mcg/dL. The steroids were discontinued thereafter. The patient denied any steroid supplementation for the 2 years prior to procedure. He had no previous history of hypotension of Addisonian crisis during this time.

The patient's pain and functional ability related to the L3 compression fracture did not improve despite extensive conservative management including narcotic pain medication and physical therapy. Subsequently, he was referred for vertebral augmentation. Because of the remote history of adrenal insufficiency, we did not feel that Addisonian crisis presented a substantial risk in this patient and therefore did not treat prophylactically with steroids. His normal serum sodium level of 136 mmol/L and normal serum potassium level of 4.6 mmol/L drawn the day prior to the procedure indicated that he was not overtly symptomatic from adrenal insufficiency and further confirmed our decision not to pre-treat with steroids. The patient was subsequently

brought to the interventional neuro-radiology department and placed prone on the procedure table.

Immediately after prepping and draping for the procedure and placement of the first trochar, the patient experienced an episode of brief hypertension with systolic blood pressure of approximately 210 mm Hg immediately followed by profound hypotension with systolic blood pressure of approximately 65 mm Hg. The patient's heart rate of approximately 115 beats per minute did not rise adequately to compensate for the profound hypotension. The hypotension was treated with intravenous fluids, repeated doses of ephedrine to a total of 50 mg and 720 mcg of phenylephrine, without clinical response. Based upon the lack of response to catecholaminergic vasopressors and known history of adrenal insufficiency, we suspected that this may represent an Addisonian crisis. The patient was then given 100 mg of intravenous hydrocortisone; blood pressure returned to nor-

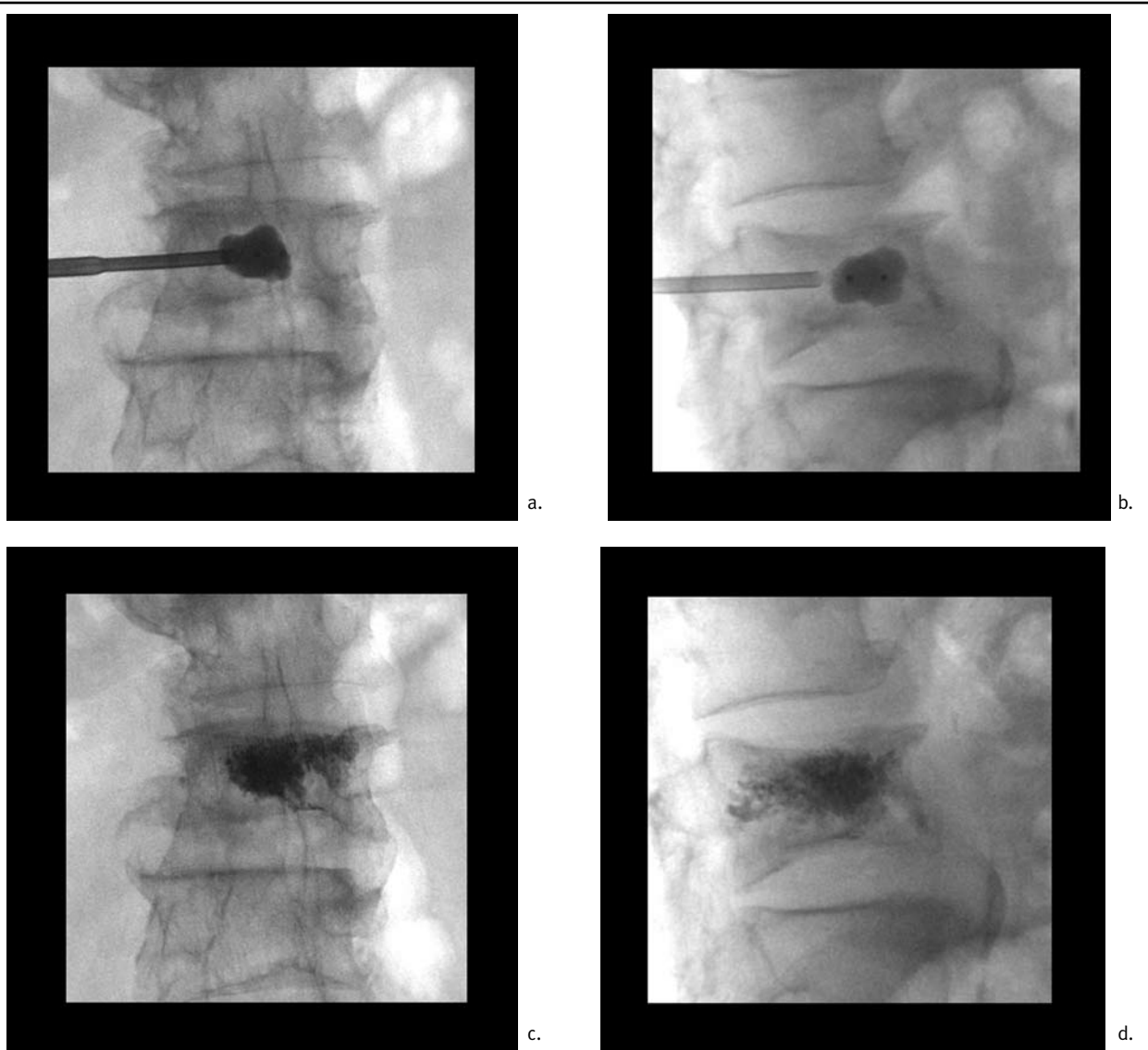
mal within 15 minutes without the use of pressors, and it was deemed acceptable to perform the procedure. The patient tolerated the procedure well without further complication (Fig 2a-d, 1b).

Following vertebral augmentation, the patient was given 2 additional doses of intravenous hydrocortisone 100 mg at 8-hour intervals. The patient did not experience any further episode of hypertension or hypotension. He recovered uneventfully and was eventually discharged for additional rehabilitation.

## DISCUSSION

This case exemplifies the potential medical complexity of the vertebral augmentation patient and that the stress of this procedure is sufficient to induce Addisonian crisis in a susceptible patient. The typical patient for vertebral augmentation is elderly and may have multiple medical problems; familiarity with possible complications is important for the physician performing the procedure. While concern for the patient's cardiorespiratory status is foremost, this case report points out that underlying adrenal insufficiency may be a potential cause of perioperative hemodynamic decompensation.

Adrenal insufficiency may result either primarily from adrenal disease, also known as Addison disease, or secondarily from adrenocorticotropic hormone (ACTH) deficiency related to pituitary or hypothalamic disorders (5). Addison disease is characterized by a deficiency of cortisol, a glucocorticoid, and aldosterone, a mineralocorticoid, with elevation of ACTH. Morbidity and mortality related to the disease is frequent, although the prevalence is only 4 to 11 cases per 100,000 adults (6). Diagnosis of this potentially lethal disease is difficult, particularly in its early stages, as signs and symptoms are nonspecific. These include generalized weakness, fatigue, skin and mucous membrane hyperpigmentation, weight loss, anorexia, nausea, vomiting, abdominal pain, fever, and hypotension with sys-



**Fig 2.** *a and b.* AP and lateral radiographs of L3 vertebra show vertebral augmentation using a balloon. *c and d.* AP and lateral radiographs show radiodense material within the L3 vertebra after injection of PMMA.

tolic blood pressure less than 110 mm Hg (5, 6, 8). Hyponatremia, hyperkalemia, and volume depletion may also be present as a result of aldosterone deficiency.

If a susceptible patient is subjected to a major stressor such as surgery, adrenal crisis, also known as Addisonian crisis, may occur on the basis of aldosterone deficiency and insufficient cortisol response to stress (6). In this case, the stress associated with initiation of the vertebral augmentation procedure was sufficient to induce Addisonian crisis. The most concerning consequence of

Addisonian crisis is severe hypotension, as occurred in our case, and shock. Exacerbation of symptoms may be seen in patients who have not been treated with maintenance corticosteroids. In those patients on maintenance doses of glucocorticoid therapy, hypotension may not occur until the patient is in crisis (5).

It is suggested that glucocorticoid replacement therapy be supplemented preoperatively for a patient with primary adrenal insufficiency, whether or not the patient is already on maintenance dosing. For moderately stressful procedures

such as vertebral augmentation, a single 100 mg intravenous dose of hydrocortisone should be given just before the procedure (6).

In the event that adrenal crisis with hypotension occurs, this requires immediate attention. Glucocorticoids need to be replaced promptly, along with sodium and water deficits. Treatment with intravenous hydrocortisone 50 to 100 mg every six to eight hours should be given with 0.9% saline and 5% dextrose (5, 8). An alternative treatment may be an intravenous bolus of 100 mg hydrocortisone followed by continuous infu-

sion of 10 mg / hour. Vasopressors may also be required to maintain blood pressure.

If bolus hydrocortisone is given emergently, the dose should be tapered rapidly over several days, decreasing by half per day with transition to oral maintenance therapy (5). Maintenance therapy includes oral glucocorticoid replacement, such as with prednisone, for cortisol deficiency. Those patients with primary adrenal insufficiency also require fludrocortisone (0.1 mg / day), a mineralocorticoid, for aldosterone deficiency once the patient is on lower doses of hydrocortisone. Mineralocorticoid supplementation is not required with larger doses of steroid, e.g. 100 to 200 mg hydrocortisone, as higher doses have mineralocorticoid effect (5).

#### CONCLUSION

It is important for the physician to be cognizant of Addisonian crisis in the differential diagnosis of perioperative acute hypotension. The standard treatment of hypotension with fluids and vasopressors is inadequate to restore blood pressure in a patient with adrenal insufficiency. Expert consultation may not be readily available given the emergent nature of this complication. The physician performing vertebral augmentation must recognize the patient's condition immediately and administer intravenous hydrocortisone to resolve the crisis.

#### ACKNOWLEDGMENTS

Dr. Hirsch is a consultant for Arthrocare, Cardinal Health and Disc-Orthopedic-Technology. He is on the steering committee for the KAVIAR study (sponsored by Kyphon) and is on the DSMB for the CEEP study.

#### AUTHOR AFFILIATION:

##### Alexander J. Nemeth, MD

Instructor in Radiology  
Harvard Medical School  
Division of Neuroradiology,  
Department of Radiology  
Massachusetts General Hospital  
Boston, MA  
anemeth@partners.org

##### Theresa J. Lie-Nemeth, MD

Instructor in Physical Medicine and Rehabilitation  
Harvard Medical School  
Department of Physical Medicine  
and Rehabilitation  
Spaulding Rehabilitation Hospital  
and Massachusetts General Hospital  
Boston, MA  
tlienemeth@partners.org

##### John J. A. Marota, MD, PhD

Assistant Professor of Anaesthesia  
Harvard Medical School  
Assistant Anesthetist  
Department of Anesthesiology and  
Critical Care  
Massachusetts General Hospital  
Boston, MA  
jmarota@partners.org

##### Johnny C. Pryor, MD

Instructor in Surgery (Neurosurgery)  
Harvard Medical School  
Department of Interventional  
Neuroradiology/Endovascular  
Neurosurgery  
Massachusetts General Hospital  
Boston, MA  
jpryor@partners.org

##### James D. Rabinov, MD

Assistant Professor of Radiology  
Harvard Medical School  
Department of Interventional  
Neuroradiology/Endovascular  
Neurosurgery  
Massachusetts General Hospital  
Boston, MA  
jrabinov@partners.org

##### Joshua A. Hirsch, MD

Chief of Minimally Invasive Spine  
Surgery  
Massachusetts General Hospital  
Asst. Professor of Radiology and  
Neurosurgery  
Harvard Medical School  
Boston, MA  
jahirsch@partners.org

#### REFERENCES

1. Anselmetti GC, Corgnier A, Debernardi F, Regge D. Treatment of painful compression vertebral fractures with vertebroplasty: results and complications. *Radiol Med* 2005; 110:262-272.
2. Laredo JD, Hamze B. Complications of percutaneous vertebroplasty and their prevention. *Semin Ultrasound CT MR* 2005; 26:65-80.
3. Mathis JM. Percutaneous vertebroplasty: Complication avoidance and technique optimization. *Am J Neuroradiol* 2003; 24:1697-1706.
4. Moreland DB, Landi MK, Grand W. Vertebroplasty: Techniques to avoid complications. *Spine J* 2001; 1:66-71.
5. Williams GH, Dluhy RG. Disorders of the Adrenal Cortex. In: Kasper DL, Braunwald E, Fauci AS, Hauser SL, Longo DL, Jameson JL, eds. *Harrison's Principles of Internal Medicine*. 16th ed. New York, NY: McGraw-Hill; 2005:2127-2148.
6. Stewart PM. The Adrenal Cortex. In: Larsen PR, Kronenberg HM, Melmed S, Polonsky KS, eds. *Williams Textbook of Endocrinology* 10th ed. Philadelphia, PA: Saunders; 2003:491-551.
7. Merry WH, Caplan RH, Wickus GG, Reynertson RH, Kiskan WA, Cogbill TH, Landercasper J. Postoperative acute adrenal failure caused by transient corticotropin deficiency. *Surgery* 1994; 116:1095-1100.
8. Clutter WE. Endocrine Diseases. In: Green GB, Harris IS, Lin GA, Moylan KC, eds. *The Washington Manual of Medical Therapeutics* 31st ed. Philadelphia, PA: Lippincott Williams & Wilkins; 2004:497-499.