

A LABORATORY INVESTIGATION

THE EFFICACY OF A TWO NEEDLE ELECTRODE TECHNIQUE IN PERCUTANEOUS RADIOFREQUENCY RHIZOTOMY: AN INVESTIGATIONAL LABORATORY STUDY IN AN ANIMAL MODEL

Richard Derby, MD, and Chang-Hyung Lee, MD

Background: Radiofrequency neurotomies are used to help reduce pain caused by structures innervated by the medial branch of the dorsal spinal nerve. The duration of effect may vary proportionally to the length of nerve coagulated. Techniques used to maximize the length of nerve within the radius of maximal heat include making multiple lesions, using larger needles, positioning the exposed needle parallel to the target nerve, and attempting more precise placement using 50 hertz test stimulation. A variation of the technique uses two needles that are simultaneously placed to lie parallel to one another and parallel to the probable area the target nerve is known to traverse. Heating both needles at the same time would be a faster method that theoretically might also include more tissue within the heating radius of the needle lengths.

Objective: The purpose of this study was to confirm that two parallel radiofrequency lesions increased the volume of tissue included within the heating radius of the exposed needle tips, to determine optimal heating parameters, and to establish how far apart the needles can be placed and still achieve temperatures between the

needles that will coagulate nerves.

Study Design: Investigational laboratory study in an animal model

Methods: Ex-vivo porcine spinal tissue samples were prepared following a standardized protocol and two needle electrodes were connected to the Stryker® rhizotomy device. A series of tissue samples were prepared with the needles placed 1, 1.5, 2, 3, 4, 5, 6, 7, 8, or 9 mm apart in respective samples. The needles were positioned parallel to the surface, and perpendicular to the tissue.

In one series of samples, two needle electrodes were heated sequentially for each needle placement. Temperature parameters ranged from 60 to 100°C and the time duration ranged from 60 to 90 seconds for each electrode. After each heating, all tissue was dissected and the size of the coagulated area measured. Temperatures at the midpoint between the two needle electrodes were monitored and measured with a Radionics® needle sensor. Using the same study protocol and evaluation, a second set of samples was studied but both needle electrodes were heated simultaneously.

Results: Maximal lesion size was ob-

served when the temperature of the electrode was higher than 70–80°C and maintained for longer than 70 seconds. When the needles were heated sequentially, the needles could be placed no further than 1.5 to 2 mm apart before areas of incomplete coagulation were visualized at the midpoint between the needles. When both needles were simultaneously heated the needles could be placed 4 mm apart before incomplete coagulation was visualized. With simultaneous heating, the highest peak temperature of the midpoint between two needles (6 mm apart) exceeded 66°C, compared to a temperature of 40°C achieved with sequential heating.

Conclusions: This research confirms the efficacy of utilizing two needle electrodes during lumbar facet rhizotomy in an experimental model. Heating the two electrodes sequentially appears to coagulate a wider area and thus would be more likely to include a longer length of the target nerve and thus potentially could achieve better results in less time.

Key words: Low back pain, facet joint, rhizotomy, radiofrequency, neurotomy, medial branch, two needle electrodes, zygapophysial joint

There is an extensive body of evidence supporting the existence of facet joint pain (1-12), although some still dispute the validity of the diagnosis (13-15). Research suggests that compromise of the facet (zygapophysial) joint may

be the cause of low back pain in 15%–45% of patients (16-21), based on criteria established by the International Association for the Study of Pain (22). Since there is little or no evidence that facet joint pain can be diagnosed on the basis of clinical examination or by medical imaging alone, there is a growing impression that diagnostic blocks are needed to confirm the facet joint as a source of the pain in a given patient (9, 10, 16-25). The above statistics on prevalence include data derived from analysis of placebo-controlled blocks or comparative local anesthetic blocks (6).

A clinical impression that the patient's pain is caused by the facet or zygapophysial joint is typically confirmed

by significant relief of pain following the intraarticular injections of local anesthetic within the joint or on the medial branches of the dorsal rami that innervate the joint (26). Once the primary pain source has been determined by diagnostic blocks, facet joint pain may be managed by intraarticular injections, medial branch blocks, or neurolysis of medial branch nerves (27-31).

Medial branch neurotomy is an effective although often time-limited approach to the management of facet joint pain (9, 29, 32). In particular, pain mediated by the medial branch of the lumbar or cervical dorsal ramus is reduced or relieved by coagulating the nerve to prevent the conduction of nociceptive im-

From: Spinal Diagnostics And Treatment Center
Daly City, CA; and Stanford University Medical
Center, Stanford, CA

Address Correspondence: Chang-Hyung Lee, MD,
Division of Physical Medicine and Rehabilitation,
Stanford University Medical Center, 300 Pasteur Dr.
Stanford, CA 94305

E-mail: changhyung@gmail.com

Disclaimer: There was no external funding in
preparation of this manuscript.

Conflict of interest: None

Manuscript received on 4/24/06

Revision submitted on 6/11/06

Accepted for publication on 6/12/06

pulses (1). The nerves will eventually re-grow, but the procedure can be successfully repeated (33)

Assuming the diagnosis was correct and the facet joints are the source of pain, the effectiveness and duration of pain relief is proportional to the length of nerve coagulated. Heating a wide volume of tissue will theoretically minimize technical failure due to incomplete coagulation and increase the duration of relief (1, 33-35).

Maximizing successful nerve coagulation depends on several considerations. First, the electrode does not reliably coagulate in a distal direction. Rather, coagulation occurs principally in a radial direction, perpendicular to the long axis of the electrode, i.e. sideways. Therefore, placing the needle parallel to the nerve is necessary to increase the potential for effective coagulation (1, 36, 37).

Second, multiple lesions may be needed to increase the likelihood that adequate coagulation occurs. The Lord et al (37) landmark double-blind study showed percutaneous radio-frequency neurotomy with multiple lesions of the cervical medial branches can provide lasting pain relief. Since the heating radius of a small needle is limited, the needle must be placed exactly on the nerve in order to guarantee its coagulation. With small gauge electrodes, a displacement of even one millimeter may fail to secure coagulation (1). To guarantee coagulation in the event the electrode is not placed precisely on the nerve, Lord et al made multiple parallel lesions to coagulate a volume of tissue that was more likely to include the nerve (1) and the authors spent on average 30 minutes per level to assure a technically adequate neurolysis.

Third, the location of the nerve varies. In the lumbar spine, the exact location of the medial branch is ambiguous when the superior articular process is elongated. The operator may not be certain whether the nerve lies low on the neck of the superior articular process (near the groove formed by its junction with the transverse process) or higher in the wall of the superior articular process. Even though the nerve may be located with 50 hertz stimulation,

such localization does not guarantee that the needle lies parallel to the nerve. To accommodate possible variations in the location of the nerve, a reasonable strategy would be to lesion all possible locations on the nerve. If the first lesion, or set of lesions, has been made close to the groove between these two processes, a second lesion can be placed along a parallel course, aligned with one electrode dorsally across the superior articular process. Conversely, if a lesion has initially been established "high" on the articular pillar, a second lesion should be placed closer to the groove (1).

Fourth, the size of the lesion is proportional to the needle diameter i.e. the wider the needle diameter, the wider the radius around the length of the exposed tip that is coagulated (1). In fact, many believe that the most effective needle for performing both lumbar and cervical neurotomies is the 16-gauge, Ray electrode (Radionics, Burlington, MA) with a 5-mm exposed, active tip (38).

Even though larger diameter needles will increase the volume of tissue coagulated, besides perhaps being more traumatic during insertion, the heat is dissipated in both the horizontal and vertical direction. Heat dissipation in the vertical direction may not be needed and just results in unproductive tissue damage.

Simultaneously placing two needles would have several advantages. One could use a commercially available smaller gauge needle, the needles could be validated to lie parallel to each other, the volume of horizontally heated tissue could be greater than that of one larger gauge needle, and heating could occur simultaneously. The purpose of this study was to determine the extent of heating achieved by using two parallel placed needles at variable distances from one another and compare the extent of coagulation when radiofrequency lesioning was performed either sequentially or simultaneously.

METHODS

Ex-vivo porcine tissue samples were obtained post-mortem from industrial processing and prepared according to standard protocol. Even though previous studies have utilized

various types of animal tissue (pork, liver, and egg white) (1, 2), egg white was not considered or used, because of albumin's soft texture, lack of stability following lesioning, and its different temperature thresholds compared to animal tissue (3).

Porcine tissue samples were kept at room temperature for more than 1 hour until they reached room temperature and were soaked in wet gauze to minimize evaporation. Procedures were performed using cross-sectional samples to observe the effects of needle placement and temperature parameters on tissue. For procedures involving two needles, electrodes were connected to a Stryker rhizotomy device (Stryker: REF 406-800, manufactured by Valley Forge Scientific Corp. Oaks, PA 19456).

Since larger gauge electrodes make larger lesions, the target nerve is more likely to be thoroughly coagulated if a large gauge electrode is used. Although some still use 22 gauge electrodes, clinical experience suggests that lesions and outcomes are optimized if an 18 or 20 gauge electrode is used (1). A commercially available 20 gauge Teflon coated needle with a 10 mm exposed tip and its companion electrode was utilized in this investigational study.

1. Sequential lesioning with two needle electrodes:

Two needles were placed sequentially in the porcine tissue sample. The needles were positioned parallel to the surface, and perpendicular to the tissue. The second needle was placed with reference to the first, an exact distance from the placement of the first needle. When the first needle is not available as a point of reference, subsequent lesions may totally overlap or be placed too far apart. Consequently, even after multiple coagulation procedures there may still be tissue between the needles that has not been lesioned.

A series of tissue samples were prepared with the needles placed 1, 1.5, 2, 3, 4, 5, 6, 7, 8, or 9 mm apart in respective samples. The needles were placed parallel to the surface, and perpendicular to the tissue. The needle placement was measured with an indicator, and the electrodes were heated in succes-

sion. Temperature parameters ranged from 60 to 100° C and time duration ranged from 60 to 90 seconds for each electrode. After each heating, about 1 or 2 minutes had been spent for the next heating. After each heating, all tissue was dissected and the size of coagulated area measured. The temperatures of tissue surrounding the electrodes were monitored and measured with a Radionics needle sensor (Radionics Model No. TCA-2, Ser. No: 716-544, manufactured by Radionics Inc. Burlington, Massachusetts 01803).

2. Simultaneous lesioning with two needle electrodes:

A second set of porcine spinal tis-

samples were prepared for the experiment, using the protocol described above. The two needle electrodes were heated simultaneously to 80° C for a total duration of 70 seconds for both electrodes. After each heating, the tissue was dissected, and the size of the coagulated area was measured.

3. Comparison of temperature at the midpoint—lesioning sequentially and simultaneously:

A third set of porcine tissue samples were prepared for the experiment, using the protocol described above. Two needles were placed 6 mm apart. The temperature applied was 80° C and the time duration was a total of 70 sec-

onds for both electrodes. Samples were heated either sequentially or simultaneously. Temperatures at the midpoint between the two needle electrodes were monitored and measured with a Radionics needle sensor.

RESULTS

Sequential Lesioning

1.1 Two electrodes inserted 1, 1.5, or 2 mm apart, heated sequentially:

All tissue between the two needles was coagulated and no tissue escaped treatment. We found that 1.5 to 2 mm is the optimal width between needles to secure coagulation—approximately 2 widths of a 20-gauge needle diameter.

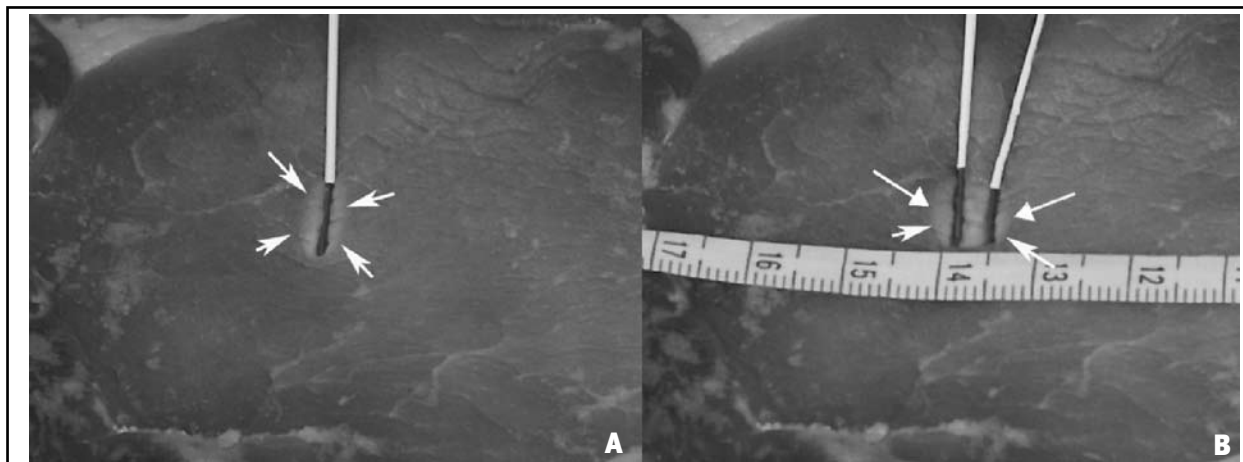


Fig 1. *A. One needle electrode: Electrical lesion created using a single needle electrode, parallel to the surface of the tissue. B. Two needle electrodes: Electrical lesion created using two needle electrodes placed 1.5 mm apart and heated sequentially. Tissue color change occurred in a radial direction perpendicular to the long axis of the electrode. All tissue between the two needles was completely coagulated. White arrows indicate area of color change.*

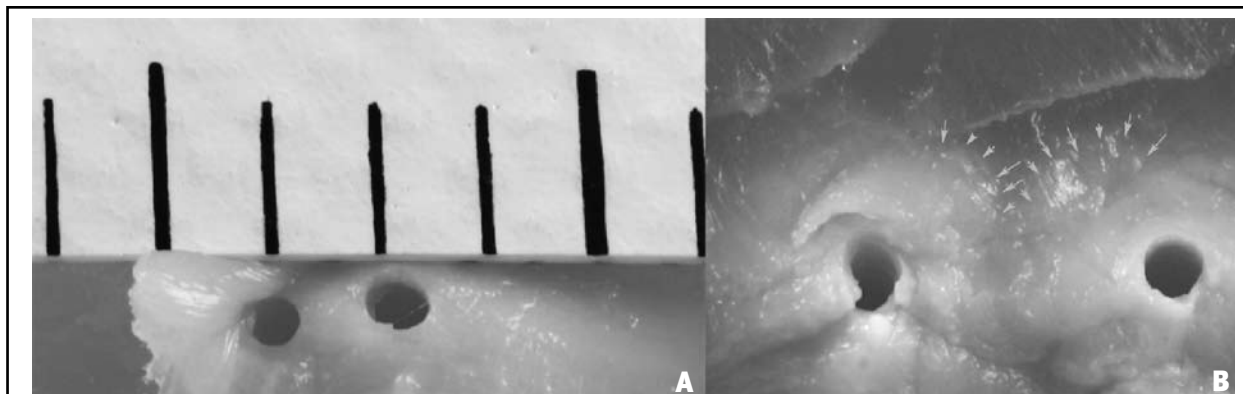


Fig 2. *Two needle electrodes heated sequentially. A. When needles were 1 mm apart, all tissue between the needles was found to be fully coagulated. (Each scale bar indicates 1 mm.) B. When the two needles were placed 4 mm apart, some tissue at the midpoint escaped coagulation (arrows show demarcation).*

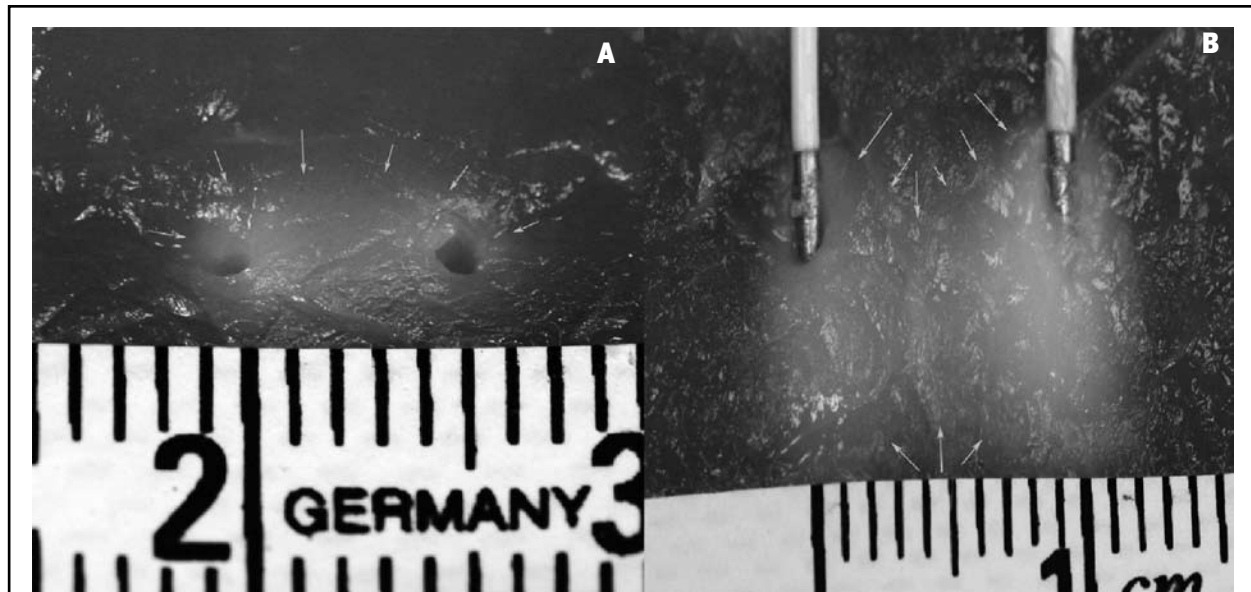


Fig 3. *A. Two needle electrodes 4 mm apart, perpendicular to the surface and heated simultaneously at 80° C for 70 seconds. All tissue between the two needles was fully coagulated (arrows). B. Two needles placed 9 mm apart parallel to the surface and heated simultaneously. The image shows some uncoagulated tissue between the two needle placements (arrows show demarcation).*




Fig 4. *A. Two needle electrodes 6 mm apart heated simultaneously at 80°C for 70 seconds. At the midpoint, temperatures were monitored and measured with Radionics® needle sensor (arrow). B. The highest peak temperature, observed at the end of the heating, exceeded 66°C.*

Using two needle electrodes, the placement to secure coagulation in our study was slightly wider than that of a previous study using a single needle electrode, which consistently achieved coagulation at 1 mm (1, 36).

When the temperature of the electrode was higher than 70-80° C and maintained for longer than 70 seconds, maximal lesion size was observed. With

longer durations and higher temperatures, slightly larger areas of tissue coagulation were evident, but differences were minimal and difficult to measure. Most of the results observed were similar to those of previous studies (36, 37). (Fig. 1)

1.2 Two electrodes inserted 3 mm apart or greater, heated sequentially:

When two electrodes were insert-

ed 3 mm apart or greater and heated in succession, some tissue at the outer margin of the midpoint was not fully coagulated. This finding was consistent in all electrode placements 3 mm or more apart (Fig 2).

Simultaneous Lesioning

Two electrodes inserted 1, 1.5, 2, 3, 4, 5, or 6 mm apart, heated simultaneously:

Our results also showed that when the two needles were heated simultaneously, the lesions created were more extensive, covering a wider area than those created by sequential needling (Fig 3). When simultaneous stimulation was applied, tissue was completely coagulated in all samples with the needles 4 mm apart or less.

Temperature Measurement

Two electrodes placed 6 mm apart, heated sequentially or simultaneously:

Temperatures were compared between samples with sequential and simultaneous stimulation, with the electrodes placed 6 mm apart. The midpoint temperature in sequentially lesioned samples was 40° C, but when lesioned simultaneously (1) was greater than 66° C (Fig 4).

DISCUSSION

We found that two parallel placed needle electrodes heated simultaneously coagulated a wider tissue area with no “escaped tissue” compared to using one needle or using two needles but heating the needles separately rather than at the same time.

Whether one uses single needle electrodes or bipolar electrodes, the chance of incorporating a maximal length of nerve will depend on the radial heating parameters of the needle. Larger diameter needles heat more tissue, but have the disadvantage of unavailability, increased tissue trauma, and perhaps the unnecessary heating in the vertical direction.

Another strategy to optimize success is to perform multiple lesions using side by side placement of two needles. One previous study used “strip” lesions created with two bipolar needles that were placed 6 mm apart (39), but whether the tissue between the needles was adequately heated or whether the needle were consistently 6 mm apart is unclear. Others have used two parallel bipolar placed electrodes to maximize chance of coagulating the sacral lateral branches and used the technique specifically because of the inconsistent loca-

tion of the nerves buried within the ligaments (40-42).

Regardless of the method or technique, if the coagulated tissue area between the two lesions does not completely overlap, nerve tissue within this area may still not be coagulated (1). In other words, even though a lesion is made close to the nerve if the electrodes are placed too far apart, intervening volumes of tissue may escape coagulation due to the circular, cross-sectional configuration of the lesioned area (1).

If one knows the heating parameters of the needle, one can place two needles parallel to one another at an optimal distance to assure coagulation of the intervening tissue. If one uses a single needle that is withdrawn after lesioning, even with fluoroscopy one may not consistently place the needle at the desired distance and parallel to the first placement. Although previous studies determined that secure coagulation (97.5% confidence) occurred only when the distance between the first insertion and the second is less than 1 mm (1, 36, 37), we found that complete coagulation using two 20 gauge electrodes occurred at up to 2mm or about 2 needle widths distance. When the needles were simultaneously heated the needle could be placed up to 4 needle widths apart consistent with an additive effect when heat was occurring simultaneously from both directions.

Coagulation of tissue using radiofrequency current depends on temperature (43,44). We found that heating beyond 70 seconds at 80 degrees centigrade did little to increase the volume of coagulated tissue. Heat produces tissue color change between 45–50° C in liver (43) and 65° C in egg albumin or animal tissue (1). If the temperature of the tissue is not sufficient, the color does not change and the tissue is regarded as uncoagulated ‘escaped tissue.’ However, this does not mean that the nerve is undamaged or is still capable of normal conduction. Previous research indicates that a “lethal temperature range” $\geq 45\text{--}50^\circ\text{C}$ for 20 seconds or more will destroy cell structures and biomolecules (3, 4). All such effects can occur at sub-cellular and molecular lev-

els without substantially elevated temperature (43).

CONCLUSION

This study provides data confirming the experimental efficacy of a two needle electrode technique for medial (or lateral) branch neurotomies in an ex-vivo porcine spinal model.

Parallel simultaneous placement and sequential lesioning of two needle electrodes coagulated a wider area of tissue more accurately than previous studies using only a single needle. More importantly, simultaneously heating two parallel needles for 70 seconds was the fastest and most effective method for incorporating a larger volume of coagulated tissue. Although this technique is currently used clinically, whether better outcomes can be achieved with this technique compared to other methods and techniques remains theoretical.

ACKNOWLEDGMENTS

Thanks to Nancy Faass, MPH, for editorial support.

AUTHOR AFFILIATION:

Richard Derby, MD,
Associate Clinical Professor
Division of Physical Medicine and
Rehabilitation
Stanford University
300 Pasteur Dr.
Stanford, CA 94305

Medical Director
Spinal Diagnostics and Treatment
Center
901 Campus Dr.
Daly City, CA 94015
richard@spinaldiagnostics.com

Chang-Hyung Lee, MD
Spinal Diagnostics and Treatment
Center
901 Campus Drive
Daly City, CA 94015
Division of Physical Medicine and
Rehabilitation
Stanford University Medical Center
300 Pasteur Dr.
Stanford, CA 94305
Email: changhyung@gmail.com

REFERENCES

1. Aprill C, Bogduk N, Dreyfuss P, Endres S, Govind J, Kraft M et al. Percutaneous radiofrequency lumbar medial branch neurotomy. In: Bogduk N, (ed). Practice guidelines: Spinal diagnostics and treatment procedures. *International Spine Intervention Society, San Francisco, 2004* pp 188-218.
2. Boswell MV, Singh V, Staats PS, Hirsch JA. Accuracy of precision diagnostic blocks in the diagnosis of chronic spinal pain of facet or zygapophyseal joint origin: A systemic Review. *Pain Physician* 2003; 6:449-456.
3. Manchikanti L, Staats PS, Singh V, Schultz DM, Vilims BD, Jasper JF, Kloth DS, Trescot AM, Hansen HC, Falasca TD, Racz GB, Deer T, Burton AW, Helm S, Lou L, Bakhit CE, Dunbar EE, Atluri SL, Calodney AK, Hassenbusch S, Feler CA. Evidence-based practice guidelines for interventional techniques in the management of chronic spinal pain. *Pain Physician* 2003; 6:3-80.
4. Fukui S, Ohseto K, Shiotani M, Ohno K, Karasawa H, Naganuma Y, Yuda Y. Referred pain distribution of the cervical zygapophyseal joints and cervical dorsal rami. *Pain* 1996; 68:79-83.
5. Zhang J, Tsuzuki N, Hirabayashi S, Saiki K, Fujita K. Surgical anatomy of the nerves and muscles in the posterior cervical spine: a guide for avoiding inadvertent nerve injuries during the posterior approach. *Spine* 2003; 28:1379-1384.
6. Boswell MV, Colson JD, Spillane WF. Therapeutic Facet Joint Interventions in Chronic Spinal Pain: A Systemic Review of Effectiveness and Complications. *Pain Physician* 2005; 8:101-114.
7. Suseki K, Takahashi Y, Takahashi K, Chiba T, Tanaka K, Morinaga T, Nakamura S, Moriya H. Innervation of the lumbar facet joints. Origins and functions. *Spine* 1997; 22:477-485.
8. Bogduk N. The innervation of the lumbar spine. *Spine* 1983; 8:286-293.
9. Dreyfuss P, Schwarzer AC, Lau P, Bogduk N. Specificity of lumbar medial branch and L5 dorsal ramus blocks. A computed tomography study. *Spine* 1997; 22:895-902.
10. Manchikanti L, Singh V, Pampati V, Damron KS, Barnhill RC, Beyer CD, Cash KA. Evaluation of the relative contributions of various structures in chronic low back pain. *Pain Physician* 2001; 4:308-316.
11. Windsor RE, King FJ, Roman SJ, Tata NS, Cone-Sullivan LA, Thampi S, Acebey M, Gilhool JJ, Rao R, Sugar R. Electrical stimulation induced lumbar medial branch referral patterns. *Pain Physician* 2002; 5:347-353.
12. Dwyer A, Aprill C, Bogduk N. Cervical zygapophyseal joint pain patterns. I: A study in normal volunteers. *Spine* 1990; 15:453-457.
13. Jackson RP, Jacobs RR, Montesano PX. 1988 Volvo award in clinical sciences. Facet joint injection in low-back pain. A prospective statistical study. *Spine* 1988; 13:966-971.
14. Jackson RP. The facet syndrome. Myth or reality? *Clin Orthop Relat Res* 1992; (279):110-121.
15. Deyo RA. Fads in the treatment of low back pain. *N Engl J Med* 1991; 325:1039-1040.
16. Schwarzer AC, Aprill CN, Derby R, Fortin J, Kine G, Bogduk N. Clinical features of patients with pain stemming from the lumbar zygapophysial joints. Is the lumbar facet syndrome a clinical entity? *Spine* 1994; 19:1132-1137.
17. Manchikanti L, Pampati V, Fellows B, Baha A. The inability of the clinical picture to characterize pain from facet joints. *Pain Physician* 2000; 3:158-166.
18. Manchikanti L, Pampati V, Fellows B, Pakanati R. Prevalence of lumbar facet joint pain in chronic low back pain. *Pain Physician* 1999; 2:59-64.
19. Manchikanti L, Pampati V, Fellows B, Bakhit CE. The diagnostic validity and therapeutic value of lumbar facet joint nerve blocks with or without adjuvant agents. *Curr Rev Pain* 2000; 4:337-344.
20. Schwarzer AC, Wang SC, Bogduk N, McNaught PJ, Laurent R. Prevalence and clinical features of lumbar zygapophysial joint pain: a study in an Australian population with chronic low back pain. *Ann Rheum Dis* 1995; 54:100-106.
21. Manchikanti L, Boswell MV, Singh V, Pampati V, Damron KS, Beyer CD. Prevalence of facet joint pain in chronic spinal pain of cervical, thoracic, and lumbar regions. *BMC Musculoskelet Disord* 2004; 5:15.
22. Merskey H, Bogduk N. Classification of chronic pain: Description of chronic pain syndrome and definition of pain terms. 2nd edition. *Seattle: IASP press, 1994.*
23. Barnsley L, Bogduk N. Medial branch blocks are specific for the diagnosis of cervical zygapophyseal joint pain. *Reg Anesth* 1993; 18:343-350.
24. Bogduk N, Holmes S. Controlled zygapophysial joint blocks: the travesty of cost-effectiveness. *Pain Med* 2000; 1:24-34.
25. Schwarzer AC, Wang SC, O'Driscoll D, Harrington T, Bogduk N, Laurent R. The ability of computed tomography to identify a painful zygapophysial joint in patients with chronic low back pain. *Spine* 1995; 20:907-912.
26. Boswell MV, Shah RV, Everett CR, Sehgal N, McKenzie-Brown AM, Abdi S, Bowman RC, Deer TR, Datta S, Colson JD, Spillane WF, Smith HS, Lucas-Levin LF, Burton AW, Chopra P, Staats PS, Wasserman RA, Manchikanti L. Interventional Techniques in the Management of Chronic Spinal Pain: Evidence-Based Practice Guidelines. *Pain Physician* 2005; 8:1-47.
27. Geurts JW, van Wijk RM, Stolker RJ, Groen GJ. Efficacy of radiofrequency procedures for the treatment of spinal pain: a systematic review of randomized clinical trials. *Reg Anesth Pain Med* 2001; 26:394-400.
28. Niemisto L, Kalso E, Malmivaara A, Seit-salo S, Hurri H. Radiofrequency denervation for neck and back pain: a systematic review within the framework of the cochrane collaboration back review group. *Spine* 2003; 28:1877-1888.
29. Dreyfuss PH, Dreyer SJ. Lumbar zygapophysial (facet) joint injections. *Spine J* 2003; 3:50S-59S.
30. Manchikanti L, Singh V, Vilims B, Hansen H, Schultz D, Kloth D. Medial branch neurotomy in management of chronic spinal pain: Systemic review of the evidence. *Pain Physician* 2002; 5:405-418.
31. Nelemans PJ, deBie RA, deVet HC, Sturmans F. Injection therapy for subacute and chronic benign low back pain. *Spine* 2001; 26:501-515.
32. Kaplan M, Dreyfuss P, Halbrook B, Bogduk N. The ability of lumbar medial branch blocks to anesthetize the zygapophysial joint. A physiologic challenge. *Spine* 1998; 23:1847-1852.
33. Schofferman J, Kine G. Effectiveness of repeated radiofrequency neurotomy for lumbar facet pain. *Spine* 2004; 29:2471-2473.
34. McDonald GJ, Lord SM, Bogduk N. Long-term follow-up of patients treated with cervical radiofrequency neurotomy for chronic neck pain. *Neurosurgery* 1999; 45:61-67.
35. Leclaire R, Fortin L, Lambert R, Bergeron YM, Rossignol M. Radiofrequency facet joint denervation in the treatment of low back pain: a placebo-controlled clinical trial to assess efficacy. *Spine* 2001; 26:1411-1416.
36. Bogduk N, Macintosh J, Marsland A. Technical limitations to the efficacy of radiofrequency neurotomy for spinal pain. *Neurosurgery* 1987; 20:529-535.
37. Lord SM, Barnsley L, Wallis BJ, McDonald GJ, Bogduk N. Percutaneous radiofrequency neurotomy for chronic cervical zygapophyseal-joint pain. *N Engl J Med* 1996; 335:1721-1726.
38. Dreyfuss P, Halbrook B, Pauza K, Joshi A, McLarty J, Bogduk N. Efficacy and

- validity of radiofrequency neurotomy for chronic lumbar zygapophysial joint pain. *Spine* 2000; 25:1270-1277.
39. Pino CA, Hoeft MA, Hofsess C, Rathmell JP. Morphologic analysis of bipolar radiofrequency lesions: implications for treatment of the sacroiliac joint. *Reg Anesth Pain Med* 2005; 30:335-338.
40. Ferrante FM, King LF, Roche EA, Kim PS, Aranda M, Delaney LR, Mardini IA, Mannes AJ. Radiofrequency sacroiliac joint denervation for sacroiliac syndrome. *Reg Anesth Pain Med* 2001; 26:137-142.
41. Gauci C. *Handbook of Clinical Techniques in the Management of Chronic Pain*. Chur, Switzerland: Harwood, 1994.
42. Ferrante F. Reply to Rathmell JP, Tarver JM, Memon Z. regarding performance of radiofrequency sacroiliac joint denervation [letter to the editor]. *Reg Anesth Pain Med* 2001; 26:592-593.
43. Cosman ER, Jr., Cosman ER, Sr. Electric and thermal field effects in tissue around radiofrequency electrodes. *Pain Med* 2005; 6:405-424.
44. Cosman ER, Nashold BS, Ovelman-Levitt J. Theoretical aspects of radiofrequency lesions in the dorsal root entry zone. *Neurosurgery* 1984; 15:945-950.

