

## A SCIENTIFIC INVESTIGATION

## INTRADISCAL PRESSURE MONITORING IN THE CERVICAL SPINE

Marc S. Menkowitz, MD, Jonathan R. Stieber, MD, Cornelia Wenokor, MD, Jason D. Cohen, MD, Gordon D. Donald, MD, and Charles Crescanti-Dakinis, MD

**Background :** Discography has been widely used in the lumbar and cervical spine as a diagnostic tool to identify sources of discogenic pain that may be amenable to surgical treatment. Discography in the cervical spine is currently performed without the benefit of pressure monitoring, and corresponding pressure parameters have not been determined.

**Objective:** The purpose of this study was to develop the framework for intradiscal pressure monitoring in the cervical spine and the basis for a pressure curve that will reflect clinically significant cervical internal disc disruption. We also sought to determine whether there is any pressure increase in adjacent discs during cervical discography that might result in false-positive diagnosis during in-vivo discography. An additional goal was to establish safe upper parameters for infusion volume and intradiscal pressure in the cervical spine.

**Design:** Investigation of fresh-frozen

discs in the cervical spine.

**Methods:** Investigated were 26 discs in 5 fresh-frozen cadaveric cervical spines aged 45 to 68 with no prior history of cervical spine disease. A T2 MRI was performed on each specimen and radiographically abnormal discs were noted. Pressure-controlled, fluoroscopically guided discography was performed on each level using a right lateral approach. Opening pressure, rupture pressure, volume infused, and location of rupture were recorded. Pressures were simultaneously recorded at each adjacent disc level using additional pressure monitors and identical needle placement. Immediately following discography, CT was performed on each specimen according to the discography protocol.

**Results:** Twenty-six discs C2-3 to C7-T1 were grossly intact for evaluation. The median opening pressure was 30 psi (range 14-101 psi). Two discs did not rupture and were pressurized to 367 psi. In 24 discs, the median intradiscal rupture pressure was 40 psi

(range 14-171 psi). The median volume infused at rupture was 0.5 ml (range 0.25-1.0 ml). When grouped, the median intradiscal rupture pressure in the C2-3, C3-4, and C7-T1 discs was 53 psi (range 16-171 psi) compared to 36.5 psi (range 14-150 psi) in the C4-5, C5-6, and C6-7 discs ( $p=0.18$ ). There was no measurable pressure change in any of the 30 adjacent disc levels evaluated.

**Conclusion:** In the cervical spine, iatrogenic disc injury may be caused at significantly lower pressures and volumes infused than in the lumbar spine. There was no measurable pressure change in any of the adjacent disc levels evaluated at maximum intradiscal pressurization. Further cadaveric testing will be necessary to develop parameters for intradiscal pressure monitoring in the cervical spine.

**Keywords:** Cervical spine, disc disease, cervical internal disc disruption, discography, intradiscal pressure, monitoring

Discography has been widely used in the lumbar and cervical spine as a diagnostic tool to identify sources of discogenic pain that may be amenable to surgical treatment (1). When used in conjunction with clinical exam and radiographic imaging, discography has the capacity to further localize the specific level or levels of disc disease (2-5). In the lumbar spine, intradiscal pressure monitoring as an ad-

junction to traditional provocative discography has aided the discographer in determining clinically significant internal disc disruption. The addition of pressure monitoring has increased the interobserver reliability and reproducibility, as well as the objectivity of the study. A pressure gradient of up to 80-90 psi is used to determine the high end of physiological pressure in the lumbar spine (1). Intradiscal pressure also provides an endpoint at which the disc may be graded normal in the absence of concordant pain. Minimum lumbar intradiscal rupture pressure has been determined to be 110-212 psi, and this has provided a safety parameter for lumbar discography (1).

Discography in the cervical spine is currently performed without the benefit of pressure monitoring, and corresponding pressure parameters have not been determined. The purpose of this study was to develop the framework for intradiscal

pressure monitoring in the cervical spine and the basis for a pressure curve that will reflect clinically significant cervical internal disc disruption. We also sought to determine whether any pressure increase occurs in adjacent discs during cervical discography that might result in a false-positive diagnosis during in-vivo discography. An additional goal was to establish safe upper parameters for infusion volume and intradiscal pressure in the cervical spine.

## METHODS

We investigated 26 discs in five fresh-frozen cadaveric cervical spines aged 45 to 68 with no prior history of cervical spine disease. T2 MRI was performed on each specimen and radiographically abnormal discs were not used. Pressure-controlled, fluoroscopically guided discography was performed on each level using a right lateral approach. A 25G spinal nee-

From: Departments of Orthopaedic Surgery and Spine & Pain Management, Monmouth Medical Center, Long Branch, NJ

Address Correspondence:

Marc S. Menkowitz, MD, Dept. of Orthopaedics, Monmouth Medical Center, 300 Second Ave., Long Branch, NJ 07740

Disclaimer: There was no external funding in preparation of this manuscript.

Conflict of Interest: None

Acknowledgement:

Manuscript received on 7/24/2004

Revision submitted on 12/25/2004

Accepted for publication on 1/12/2005

dle was placed into each disc and Omnipaque 300 (Nycomed, Princeton, NJ) contrast dye was infused utilizing a pressure-controlled inflation syringe with digital pressure monitor (Merit Universal Syringe, MeritMedical, South Jordan, UT) (Fig. 1). The operating pressure range of the monitor was 0-367 psi ( $\pm$  2.5%). Opening pressure, rupture pressure, volume infused, and location of rupture were recorded. Pressures were simultaneously recorded at each adjacent disc level using additional pressure monitors and identical needle placement. Immediately following discography, CT was performed on each specimen according to the discography protocol. All radiographic studies were read by a musculoskeletal radiologist who was blinded to the pressure and volume recordings (Fig. 2).

Statistical analysis was performed using commercially available software (XL Stat; Addinsoft, Brooklyn, NY). Non-parametric data were analyzed utilizing repeat measure Analysis of Variance (ANOVA) and parametric data were analyzed utilizing a student's T-test. A  $P$ -value  $\leq$  0.05 was considered statistically significant.

## RESULTS

Twenty-six discs, C2-3 to C7-T1, were grossly intact with no evidence of frank rupture. The median opening pressure was 30 psi [206.8 kPa] (range 14-101 psi) [96.5-696.4 kPa]. Two discs did not rupture and were pressurized to 367 psi [2530.4 kPa]. In 24 discs, the median intradiscal rupture pressure was 40 psi [275.8 kPa] (range 14-171 psi) [96.5-1179.0 kPa]. The median volume infused

at rupture was 0.5 ml (range 0.25 to 1.0 ml). When grouped, the median intradiscal rupture pressure in the C2-3, C3-4, and C7-T1 discs was 53 psi [365.4kPa] (range 16-171 psi)[110.3-1179 kPa] compared to 36.5 psi[251.7kPa] (range 14-150 psi) [96.5-1034 kPa] in the C4-5, C5-6, and C6-7 discs ( $p=0.18$ ) (Figures 3 & 4). While this difference was appreciable, it is not statistically significant. The average intradiscal rupture pressure for C2-3, C3-4, and C7-T1 was 66 psi [455.1 kPa] compared with 55 psi [379.2 kPa] in C4-5, C5-6, and C6-7 discs ( $p=0.156$ ). There was no measurable pressure change in any of the 30 adjacent disc levels evaluated.

## DISCUSSION

Investigation of intradiscal rupture pressure exhibited a bimodal distribution with higher intradiscal rupture pressures observed in the C2-3, C3-4, and C7-T1 discs compared with those of the C4-5, C5-6, and C6-7 discs. Despite maximum pressurization, there was no transmission of pressure to adjacent cervical discs. During in-vivo provocative discography, it is possible to observe a disc with normal appearance and dye distribution, but with a positive concordant pain response (6). In-vivo investigation has shown that there is no transmission of pressure to adjacent discs in the lumbar spine when a normal appearing disc with a concordant pain response is infused at 100 psi (7) [689.5 kPa]. Similar to findings in the lumbar spine, this finding suggests that pressure transmission to an adjacent symptomatic level does not explain such an observation (8).

A high rate of asymptomatic radio-

graphic changes have been seen in cervical spines of individuals of all ages, so discography may be the only test capable of localizing the specific painful disc (9). Discogenic pain during discography can be attributed to either mechanical irritation or chemical mediators. Derby et al (9) have defined discographic parameters in the lumbar spine for differentiating between these two etiologies. Chemical discogenic pain was determined to occur when less than 1 ml of contrast was visualized reaching the outer annulus or with pain elicited at less than 15 psi [103.4 kPa] above the opening pressure. Mechanical pain was implicated with symptoms occurring at pressures 15-50 psi [103.4-344.7kPa] above the opening pressure. In this study, chemical discogenic pain was determined to be predictive of a good surgical outcome, whereas mechanical pain could not be shown to be predictive and required further investigation. Eighty-nine percent of patients with chemically sensitive discogenic pain achieved relief with a lumbar interbody fusion (9). Examining lumbar discography as a predictor of surgical outcomes, Kikuchi et al (2) found good to excellent results in 39% of patients who did not undergo preoperative discography, compared with 79.7% of patients who were diagnosed by positive discography. Similarly, Simmons et al (10) reported 80.8% good to excellent results with fusion after positive preoperative discography. It is our ultimate goal to document the predictive value of cervical discography and to develop similar pressure parameters for diagnosis.

In the current study, minimum pressure for disc rupture was 14 psi with infu-

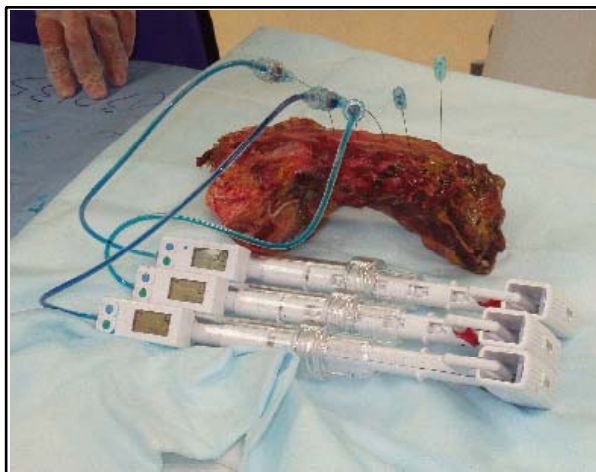


Fig. 1. Cadaveric discography

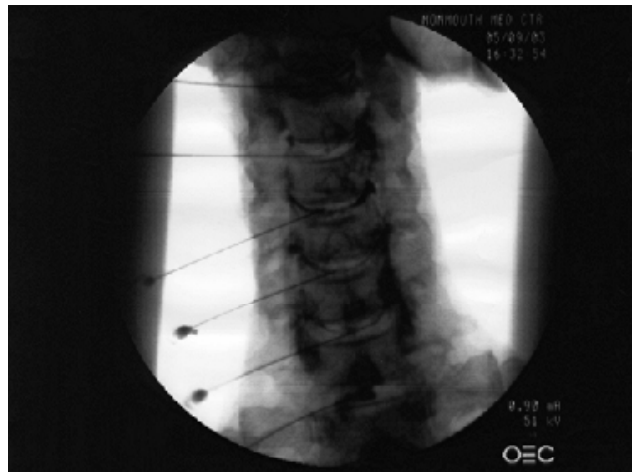

Fig. 2. CT following discography

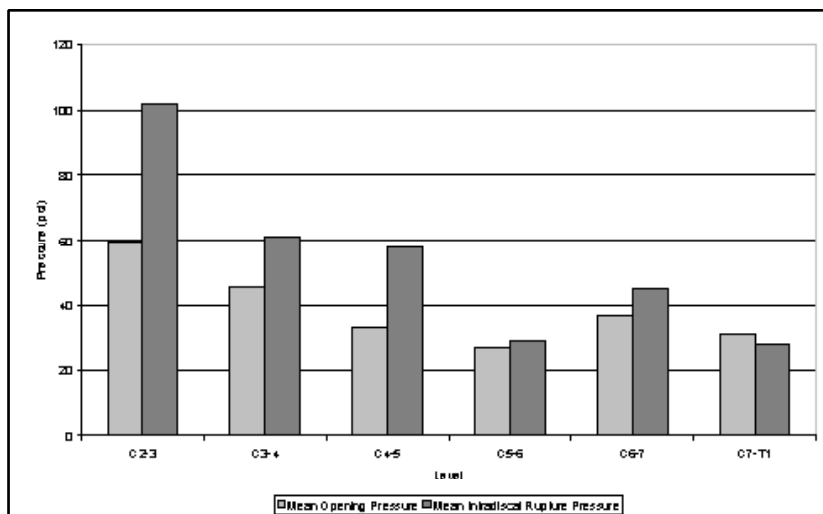


Fig. 3. Disc pressure measurements

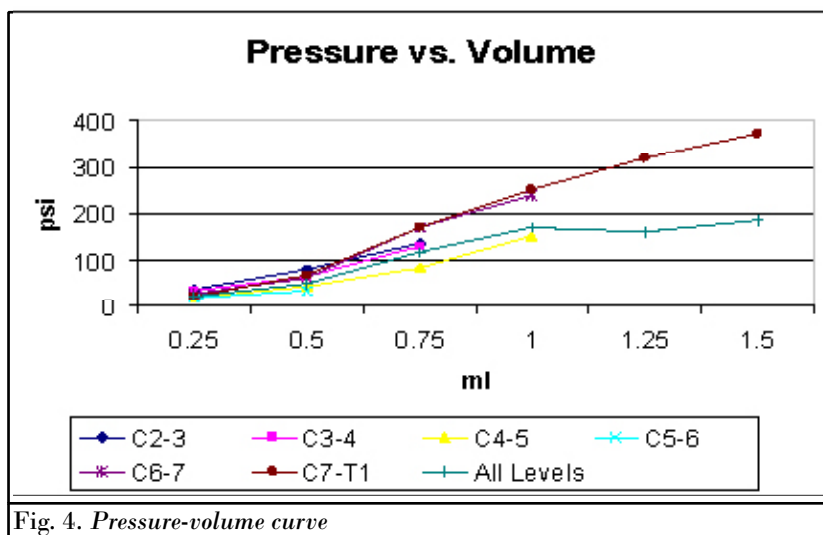


Fig. 4. Pressure-volume curve

sion of only 0.25 ml. These results indicate that cervical intervertebral discs may have appreciably lower pressure parameters than those of the lumbar spine and that the potential for iatrogenic disc injury may exist with low pressures and volumes. If pressure-controlled discography is to be safe and effective in the cervical spine, a specific cervical infuser may need to be developed with a capacity to administer smaller volumes and with a more sensitive gauge.

The cadaveric testing in this study was limited by sample size, but it begins to establish parameters for intradiscal pressure measurement as a component of provocative cervical discography. Further cadaveric testing is necessary to develop more robust parameters. Weaknesses of this study include the small sample size and the potential changes that may occur

in the composition of cadaveric discs even when employing fresh-frozen specimens; these changes include differences in rupture pressures at the same level on different specimens.

As surgeons seek to treat axial or predominant neck pain recalcitrant to conservative therapy, discography holds the promise of aiding in the localization of intradiscal pathology. In combination with zygapophyseal joint injections, discography will play an important role in preoperative planning. With the imminent introduction of cervical disc arthroplasty, the problem of adjacent level degeneration found after cervical fusion may be all but eliminated. Thus, cervical disc replacement may prove to be a superior option to cervical fusion in the not too distant future. Cervical discography is certain to be integral to the surgical

treatment algorithm whether arthroplasty or fusion is indicated. This study establishes a starting point for intradiscal pressure monitoring in the cervical spine, but further cadaveric testing will be necessary before it can be expanded to human trials and clinical applications.

**CONCLUSION**

Introgenic disc rupture may occur at lower pressures and volumes with cervical than lumbar discs. Further studies are needed to develop pressure infusion devices appropriate for the cervical spine.

**AUTHOR AFFILIATION:**

**Marc S. Menkowitz, MD**  
Resident  
Department of Orthopaedics  
Monmouth Medical Center  
300 Second Ave.  
Long Branch, NJ 07740  
E-mail: menkmd@hotmail.com

**Jonathan R. Stieber, MD**  
Resident  
Department of Orthopaedics  
Monmouth Medical Center  
300 Second Ave.  
Long Branch, NJ 07740

**Cornelia Wenokor, MD**  
Attending  
Department of Radiology  
Monmouth Medical Center  
300 Second Ave.  
Long Branch, NJ 07740

**Jason D. Cohen, MD**  
Attending  
Department of Orthopaedics  
Monmouth Medical Center  
300 Second Ave.  
Long Branch, NJ 07740

**Gordon D. Donald, MD**  
Attending  
Department of Orthopaedics  
Monmouth Medical Center  
300 Second Ave.  
Long Branch, NJ 07740

**Charles Crescanti-Dakinis, MD**  
Attending  
Department of Pain Management  
Monmouth Medical Center  
300 Second Ave.  
Long Branch, NJ 07740

## REFERENCES

1. Grubb SA, Kelly CK. Cervical discography: clinical implications from 12 years of experience. *Spine* 2000; 25:1382-1389.
2. Kikuchi S, Macnab I, Moreau P. Localization of the level of symptomatic cervical disc degeneration. *J Bone Joint Surg Br* 1981; 63-B:272-277.
3. Gossling H. Is cervical discography really worth it? *Complications Orthop* 1994; 35-38.
4. Schellhas KP, Smith MD, Gundry CR, Pollei SR. Cervical discogenic pain. Prospective correlation of magnetic resonance imaging and discography in asymptomatic subjects and pain sufferers. *Spine* 1996; 21:300-312.
5. Siebenrock KA, Aebi M. Cervical discography in discogenic pain syndrome and its predictive value for cervical fusion. *Arch Orthop Trauma Surg* 1994; 113:199-203.
6. Motimaya A, Arici M, George D, Ramsby G. Diagnostic value of cervical discography in the management of cervical discogenic pain. *Conn Med* 2000; 64:395-398.
7. Cooke P, Lutz G. Lumbar Disc Bursting Pressure Determined Pressure Controlled Discography. In *Proceedings of the The Meetings of The Americas II*, 2002.
8. Furman M, Lee T, Puttlitz K, Zgleszewski T, O'Brien E, Goodman B. Discography: Evaluation of possible adjacent disc pressurization. In *Proceedings of the Meetings of The Americas II*, 2002.
9. Derby R, Howard MW, Grant JM, Lettice JJ, Van Peteghem PK, Ryan DP. The ability of pressure-controlled discography to predict surgical and nonsurgical outcomes. *Spine* 1999; 24:364-372.
10. Simmons EH, Segil CM. An evaluation of discography in the localization of symptomatic levels in discogenic disease of the spine. *Clin Orthop Related Res* 1975; 108:57-69.