

## Technical Note

## Fluoroscopically-Guided Superior Hypogastric Plexus Neurolysis Using a Single Needle: A Modified Technique for a Posterolateral Transdiscal Approach

Po-Chou Liliang, MD, Chao-Ming Hung, MD, Kang Lu, MD, PhD, and Han-Jung Chen, MD, PhD

From: E-Da Cancer Hospital,  
Kaohsiung, Taiwan

Address Correspondence:  
Po-Chou Liliang, MD  
E-Da Cancer Hospital  
I-Shou University  
Department of Neurosurgery  
No 1, Yi-da Rd, Yan-Chau  
District, Kaohsiung, 824  
Kaohsiung, Taiwan  
E-mail: liliangns@gmail.com

Disclaimer: There was no external funding in the preparation of this manuscript.  
Conflict of interest: Each author certifies that he or she, or a member of his or her immediate family, has no commercial association (i.e., consultancies, stock ownership, equity interest, patent/licensing arrangements, etc.) that might pose a conflict of interest in connection with the submitted manuscript.

Manuscript received: 09-13-2017  
Revised manuscript received:  
01-03-2018  
Accepted for publication:  
01-05-2018

Free full manuscript:  
[www.painphysicianjournal.com](http://www.painphysicianjournal.com)

**Background:** A superior hypogastric plexus block is difficult to perform and hampered by bony structures of the iliac crest and transverse process of L5.

**Objective:** We report on a fluoroscopically guided posterolateral transdiscal technique for superior hypogastric plexus neurolysis using a single needle.

**Study Design:** A technical note describing interventional procedures.

**Setting:** The neurosurgery department of a cancer hospital.

**Methods:** The patient was placed in the prone position with a pillow beneath the iliac crest to facilitate opening of the intervertebral disc. The entry point for the needle was 7–8 cm to the left of the midline of the L45 level. The spinal needle was slightly advanced caudally toward the L5-S1 disc and at a 40° angle from the vertical plane. Using lateral fluoroscopic control, the needle was advanced beneath the inferior aspect of the facet joint. After entering the disc, the needle was then advanced until it passed the anterior annulus fibrosus of the L5S1 disc. After verifying adequate position using contrast, 3 mL of 75% ethanol was injected for neurolysis.

**Results:** During the follow-up, the patient reported reduction of pain in the lower abdomen and quality of life was significantly improved.

**Limitations:** Sample size; no placebo control.

**Conclusion:** Although different approaches exist, we prefer the posterolateral transdiscal approach for superior hypogastric plexus block and neurolysis using a single needle. This technique is a valuable alternative.

**Key words:** Superior hypogastric plexus neurolysis, transdiscal approach, cancer pain

**Pain Physician 2018; 21:E341-E345**

**T**he superior hypogastric plexus contains afferent pain fibers from most of the pelvic structures: the bladder, urethra, uterus, perineum, prostate, rectum, and descending colon (1-3). A superior hypogastric plexus block (SHBP) can potentially alleviate pain originating from the above-mentioned regions (1-3). Plancarte et al. first

described the technique of SHPB for intractable pelvic cancer pain (3).

The technique is sometimes difficult to perform and is hampered by bony structures (4,5). The iliac crest and transverse process of L5 are potential anatomical barriers to needle passage because the superior hypogastric plexus lies deep in the

retroperitoneal space anterior to L5 and S1 vertebral bodies.

We report on a fluoroscopically guided posterolateral transdiscal approach for superior hypogastric plexus neurolysis using a single needle. We report this technique for its convenience and safety.

## METHODS

### Patient

A 73-year-old woman complained of increasing low abdominal pain over the previous 3 months. She described the pain as sharp, stabbing, and localized to the lower abdomen and radiating to the bilateral inguinal areas and anus. The pain was intractable to tramadol and fentanyl transdermal patches. She had right kidney infiltrative urothelial carcinoma with pelvic and lung metastatic spread (T4N2M1). Her VAS score was 9 (VAS scores range from 0, no pain to 10, extremely severe pain). She underwent superior hypogastric plexus neurolysis for intractable abdominal pain.

### Surgical Technique

The patient received 1 g cefazolin 30 min before the procedure as a prophylactic antibiotic to prevent discitis. The procedure was performed in the operating room with fluoroscopic guidance under sterile conditions. The patient was placed in the prone position with a pillow beneath the iliac crest to facilitate opening the intervertebral disc.

The patient received intravascular sedation with 0.1 mg/kg midazolam and 0.1 ug/kg fentanyl. Continuous cardiac, pulse oximetry, and clinical monitoring were performed throughout the procedure. The L5S1 intervertebral disc was identified under anteroposterior and lateral views of a fluoroscope. The entry point was 7–8 cm to the left from the midline of the L4-5 level (Fig 1). After local anesthetic infiltration of the skin and subcutaneous tissues, a 20-gauge, 15 cm spinal needle was slightly advanced caudally (parallel to the iliac crest) toward the L5-S1 disc (Fig. 2). The needle was at a 40° angle from the vertical plane. By lateral fluoroscopic control, the needle was advanced beneath the inferior aspect of the facet joint. After entering the disc, the needle was advanced until the needle had passed the anterior annulus fibrosus of the L5-S1 disc (Fig. 3). The position of needle tip was monitored under lateral and anteroposterior fluoroscopic radiographs. When the needle was outside the L5-S1 disc, 1 mL of iohexol was administered to verify its final position (Fig. 4). After verifying adequate positioning with contrast, 3 mL of 75% ethanol was injected for neurolysis.

## RESULTS

Postoperatively, the patient was instructed to complete 2 h of bed rest in supine position, following which she was allowed unlimited sitting, standing, and walking. Because no immediate complications were observed, the patient was discharged the next day. During the follow-up, she reported that the reduction in lower

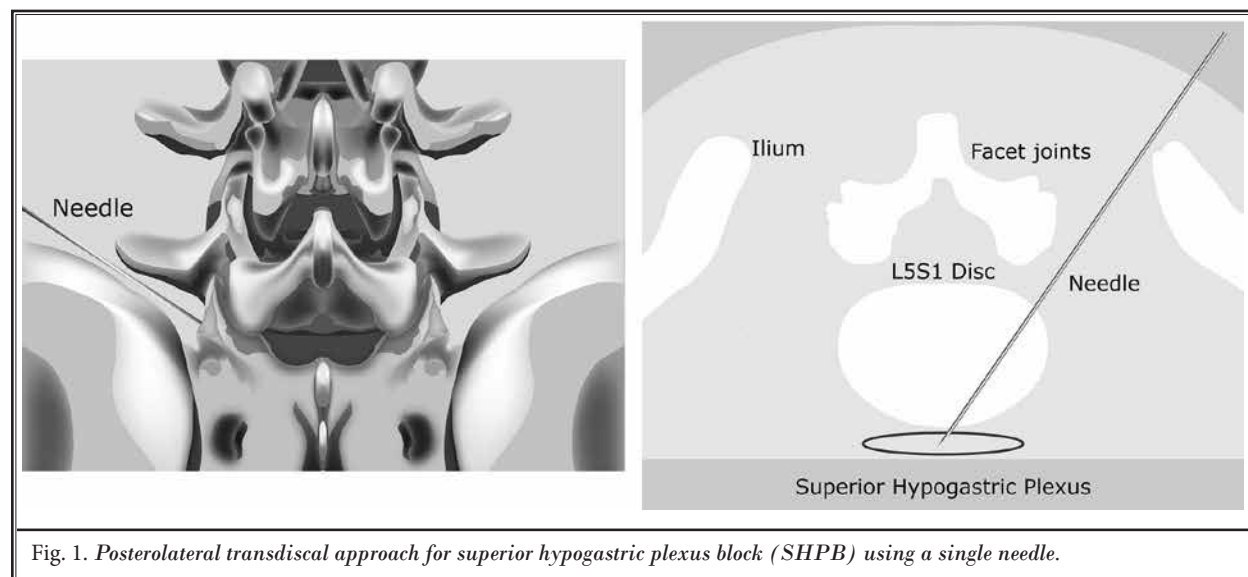


Fig. 1. Posterolateral transdiscal approach for superior hypogastric plexus block (SHPB) using a single needle.

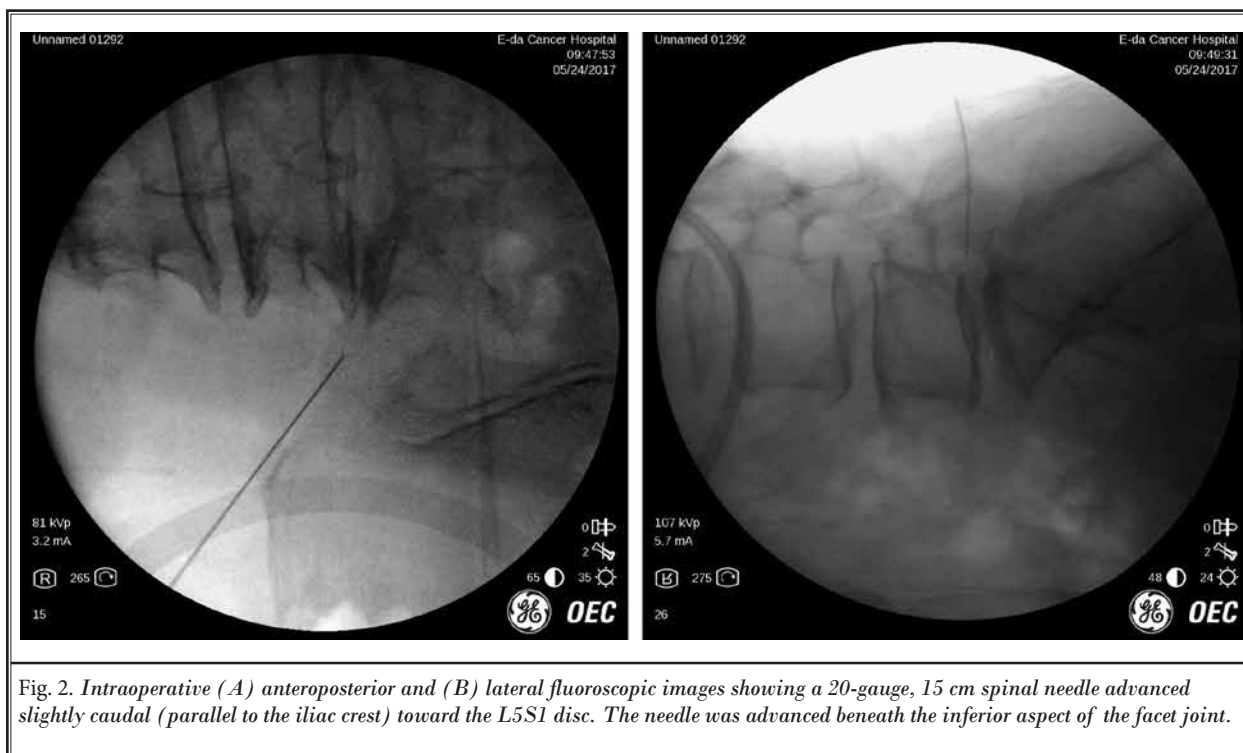


Fig. 2. Intraoperative (A) anteroposterior and (B) lateral fluoroscopic images showing a 20-gauge, 15 cm spinal needle advanced slightly caudal (parallel to the iliac crest) toward the L5S1 disc. The needle was advanced beneath the inferior aspect of the facet joint.

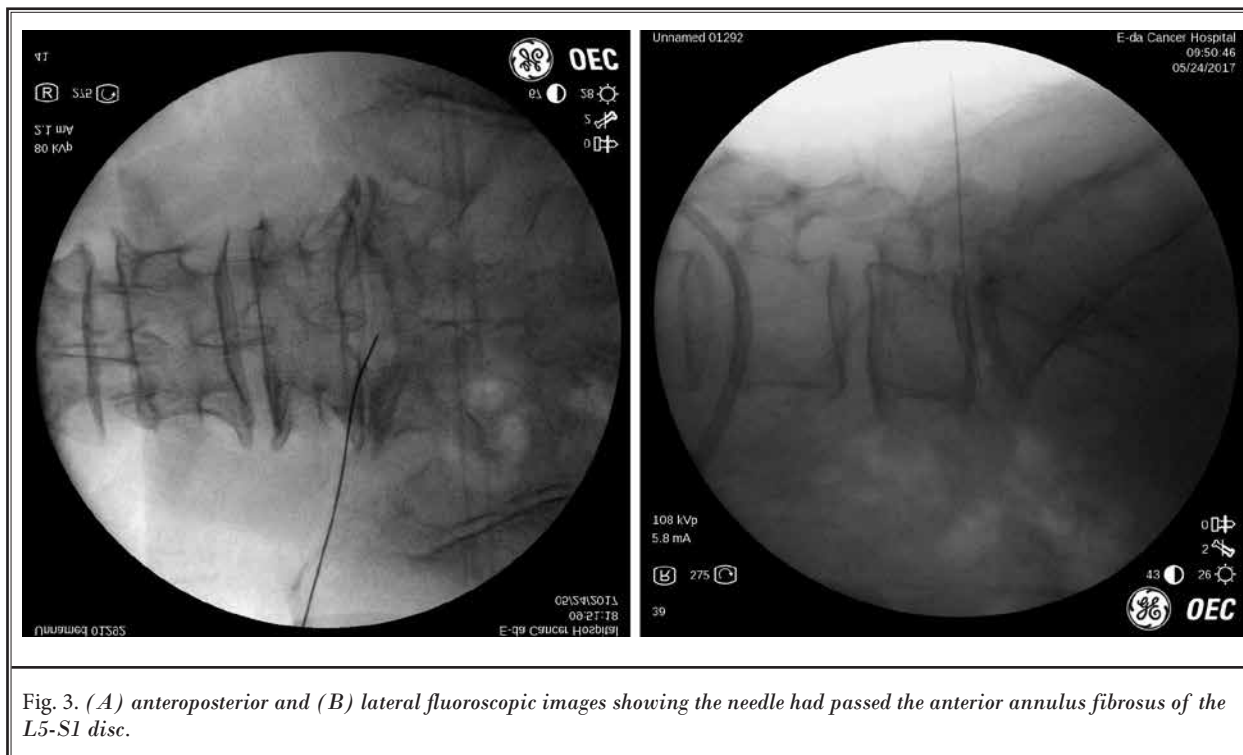


Fig. 3. (A) anteroposterior and (B) lateral fluoroscopic images showing the needle had passed the anterior annulus fibrosus of the L5-S1 disc.

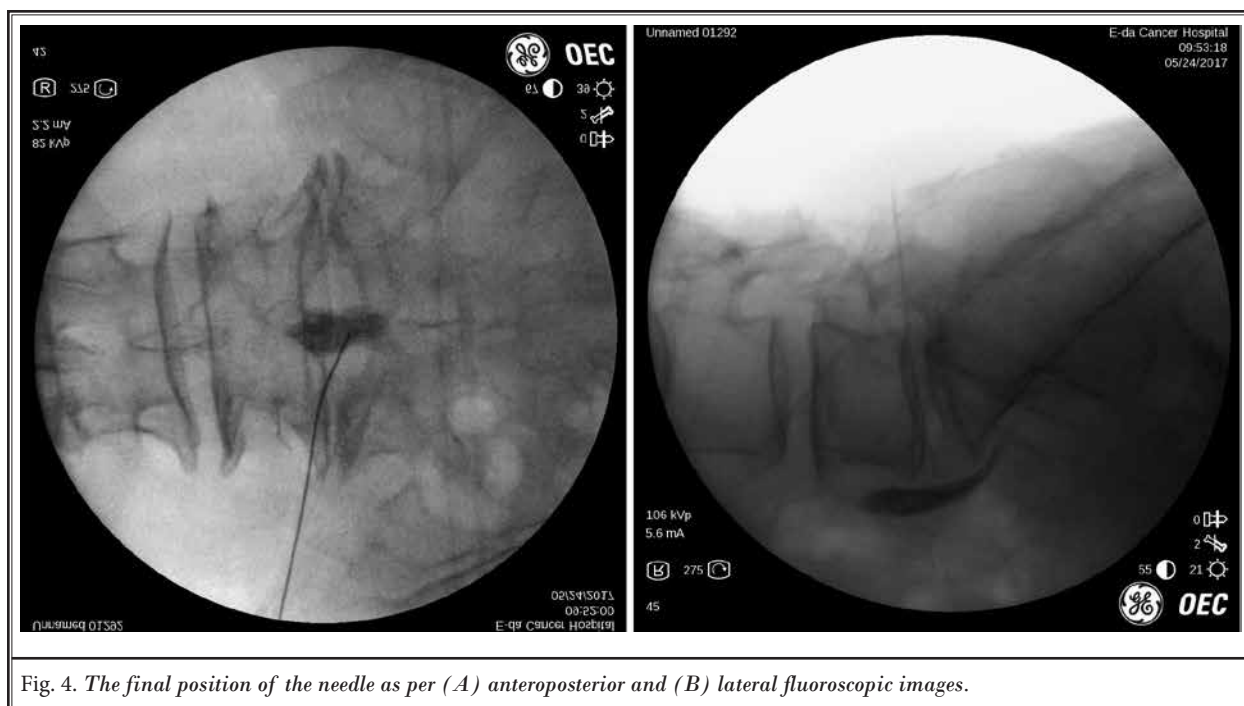


Fig. 4. The final position of the needle as per (A) anteroposterior and (B) lateral fluoroscopic images.

abdominal pain was sustained, and her quality of life significantly improved. She had stopped fentanyl and was occasionally receiving paracetamol and tramadol. Her VAS score decreased from 9 (peri-operative) to 2. She survived 2 months after the block with good pain relief.

## Discussion

We had an axial CT scan used for pre-procedure plan. Axial CT or MRI could be very helpful for pre-procedure plan. With axial CT or MRI, we can plot the starting distance and optimal needle angle to avoid multiple disc punctures. The entry point of our needle was 7–8 cm to the left from the midline of the L4-5 level. The direction was slightly advanced caudally (parallel to the iliac crest) toward the L5-S1 disc. Our path was at an approximately 40° angle from the vertical plane. Before entering the L5-S1 disc, the needle could pass beneath the facet joint and cephalad to the ilium. We used this approach for L5-S1 nucleoplasty; it would not be obstructed by bony structures (6). We advanced the needle into the L5-S1 disc under lateral fluoroscopic control. Our opinion is that it is easier and more convenient than an oblique tunnel view (4).

Plancarte et al (2,3) described a two-needle posterior approach with fluoroscopic guidance. However, there are several difficulties using this method because

of anatomical barriers, such as the iliac crest and transverse process of L5 (4,5). Using the classic two-needle approach was somewhat time consuming (7). To facilitate an easier approach, various methods have been described (4,5,7-10). The posterior (4) and posteromedial transdiscal approach (5) are alternatives to classic SHPB. The transdiscal technique has several advantages: ease, convenience, avoidance of organ punctures (9), lower risk of intravascular injection (10), and only a single injection is necessary.

Our method has some modifications to the posterior transdiscal approach (4,5): a more lateral entry point and a caudal direction. This path could avoid obstruction from bony structures. The procedure was performed under a lateral fluoroscopic view. Unlike the interlaminar approach, our method could avoid thecal sac punctures (5), which risk nerve injury (11).

A possible complication of the transdiscal method is the risk of discitis (4). The use of prophylactic antibiotics could decrease the risk of discitis during this procedure (4,5,7). Recent literature has shown the risk of infection to be low (4,5,7). In a series of 20 patients, Erdine et al did not report any complications related to discitis in their study using intravenous antibiotic administration. Another concern of this technique is L5 nerve root injury. Nerve damage to nerve root could occur in this technique, but it is rare and usually causes

only transient symptoms from the experience of L5-S1 discography and nucleoplasty (12).

Some physicians performed superior hypogastric plexus neurolysis after a positive response to diagnostic blocks (1). The pain relief of diagnostic blocks (bupivacaine or lidocaine) was short. Subsequent neurolysis using chemical agents could improve the duration of pain relief. In most patients the pain relief of neurolysis could persist up to 6 months (1).

Some physicians would prefer using a curved needle in SHPB because of anatomical considerations. The superior hypogastric plexus is in the retroperitoneum, bilaterally extending from the lower third of the fifth lumbar vertebral body to the upper third of the first sacral vertebral body (13). If you had a curved needle it is more likely that you could navigate to the middle and inject the sympathetic plexus laterally.

SHPB has also been used successfully to relieve chronic pelvic pain associated with noncancer conditions (14-16). Chronic noncancer pelvic pain unresponsive to pharmacological treatment could also benefit from this minimally invasive procedure.

## CONCLUSION

Although different approaches exist, we prefer a posterolateral transdiscal approach for SHPB using a single needle. This approach is already familiar to surgeons performing percutaneous nucleoplasty. Using an entry point 7–8 cm to the left of from the midline at the L4-5 level, the direction was slightly caudal and at a 40° angle from the vertical plane. The needle could pass beneath the facet joint and cephalad to the ilium. This technique is a valuable alternative to classic SHPB.

## REFERENCES

- De Leon-Casasola OA, Kent E, Lema MJ. Neurolytic superior hypogastric plexus block for chronic pelvic pain associated with cancer. *Pain* 1993; 54:145-151.
- Plancarte R, Amescua C, Patt RB, Aldrete JA. Superior hypogastric plexus block for pelvic cancer pain. *Anesthesiology* 1990; 73:236-239.
- Plancarte R, de Leon-Casasola OA, El-Helaly M, Allende S, Lema MJ. Neurolytic superior hypogastric plexus block for chronic pelvic pain associated with cancer. *Reg Anesth* 1997; 22:562-568.
- Erdine S, Yucler A, Celik M, Talu GK. Transdiscal approach for hypogastric plexus block. *Reg Anesth Pain Med* 2003; 28:304-308.
- Turker G, Basagan E, Gurbet A, Ozturk C, Uckunkaya N, Sahin S. A new technique for superior hypogastric plexus block: The posteromedian transdiscal approach. *Tohoku J Exp Med* 2005; 206:277-281.
- Liliang PC, Lu K, Liang CL, Chen YW, Tsai YD, Tu YK. Nucleoplasty for treating lumbar disk degenerative low back pain: An outcome prediction analysis. *J Pain Res* 2016; 31:893-898.
- Gamal G, Helaly M, Labib YM. Superior hypogastric block: Transdiscal versus classic posterior approach in pelvic cancer pain. *Clin J Pain* 2006; 22:544-547.
- Waldman SD, Wilson WL, Kreps RD. Superior hypogastric plexus block using a single needle and computed tomography guidance: Description of a modified technique. *Reg Anesth* 1991; 16:286-287.
- Kanazi GE, Perkins FM, Thakur R, Dotson E. New technique for superior hypogastric plexus block. *Reg Anesth Pain Med* 1999; 24:473-476.
- Mc Donald JS. Management of chronic pelvic pain. *Obstet Gynecol Clin North Am.* 1993; 20:817-838.
- Auroy Y, Narchi P, Messiah A, Litt L, Rouvier B, Samii K. Serious complications related to regional anesthesia: Results of a prospective survey in France. *Anesthesiology* 1997; 87:479-486.
- Peh W. Provocative discography: Current status. *Biomed Imaging Interv J* 2005; 1:e2.
- De Leon-Casasola OA. Sympathetic nerve block: Pelvic. In: Raj PP. eds. *Practical management of pain*. 3rd ed. St. Louis: Mosby; 2001:683-688.
- Pollitt CI, Salota V, Leschinskiy D. Chemical neurolysis of the superior hypogastric plexus for chronic non-cancer pelvic pain. *Int J Gynaecol Obstet* 2011; 114:160-161.
- Wechsler RJ, Maurer PM, Halpern EJ, Frank ED. Superior hypogastric plexus block for chronic pelvic pain in the presence of endometriosis: CT techniques and results. *Radiology* 1995; 196:103-106.
- Michalek P, Dutka J. Computed tomography-guided anterior approach to the superior hypogastric plexus for noncancer pelvic pain: A report of two cases. *Clin J Pain* 2005; 21:553-556.

