

A NOVEL APPROACH TO TRANSNASAL SPHENOPALATINE GANGLION INJECTION

Ian Y. Yang, MD, and Saeed Oraee, MD

Background: Sphenopalatine ganglion block is used to treat headache and facial pain. There are transnasal, transoral and lateral approaches to establish the blockade. The transnasal application of topical anesthetic is the simplest and most common technique among the three. However, the diffusion of topical anesthetic to the ganglion is unpredictable and the blockade is not durable.

Objective: To describe a novel transnasal injection technique to block sphenopalatine ganglion.

Methods: The technique includes

topical anesthesia to the nasal mucosa between the middle and inferior turbinates from nares to the nasopharynx, followed by a needle insertion in the same tract guided by its tailored plastic cover-sheath for blocking agent injection to the ganglion.

Results: Fluoroscopy revealed that with this technique the needle tip located near the medial pterygoid plate at the level of the middle concha and contrast flowed superoposteriorly to the maxilla without vascular uptake. Pain relief for this patient was prolonged from one day

with topical technique to four weeks with this technique. The subsequent blocks without fluoroscopy provided similar prolonged pain relief.

Conclusion: This method preserves the technical simplicity of the original transnasal approach and includes the predictability and durability of the blockade from needle injection.

Key Words: Headache, facial pain, sphenopalatine ganglion block, transnasal injection

The sphenopalatine ganglion is the largest peripheral parasympathetic ganglion having multiple connections to general sensory fibers, and the internal carotid plexus without synapsing (1). The blockade of the ganglion has been used to treat headache and facial pain. There are generally three approaches to block this ganglion: 1) transnasal application of topical anesthetic with a cotton-tipped applicator to the nasopharyngeal mucosa posterior to the middle turbinate; 2) transoral approach with a curved dental needle up to the sphenopalatine foramen through the posterior palatine canal and; 3) the lateral

approach with a straight needle to the pterygopalatine fossa through the infratemporal fossa (2). The transnasal application of topical anesthetic is the simplest and the most tolerable technique among the three approaches. However, the diffusion of topical anesthetic to the ganglion is unpredictable and the blockade is not durable with this approach. We present a case of a cluster headache patient who, although excessively apprehensive of needles, underwent sphenopalatine ganglion blocks with a new transnasal injection technique.

REPORT OF A TRANSNASAL TECHNIQUE

Our Institutional Review Board did not require a full process of review for this type of report. A 36-year-old, 167-cm, 82-kg man with a 6-year history of chronic, left sided, cluster headache was referred to us for nerve blocks. His headache initially followed an episodic pattern and became more chronic with no remission period despite vigorous preventive or abortive treatment. Thirty-five medications have been tried in the past: over-the-counter analgesics, non-steroidal anti-inflammation drugs

including indomethacin, triptans, anti-serotonins, opioids, ergot derivatives, oxygen, beta-blockers, calcium channel blockers, antidepressants, anticonvulsants, corticosteroid and others. He was maintained with zolmitriptan nasal spray, prednisone and oxycodone/acetaminophen at interview. With these medications, the attack frequency was 3-5 times per day and several days a week. The pain intensity was 9-10/10 on a numerical pain scale and the duration was 30-45 minutes. Due to his apprehension of needles, initial nerve blocks started with non-invasive transnasal topical anesthesia (4% lidocaine) using cotton-tipped applicators. The first block gave him 60% pain relief for one day. The following several blocks produced similar results without prolonged effect. The lateral approach of needle injection was offered, but he was reluctant to undergo the procedure.

Because the patient tolerated the transnasal topical block, we designed a technique using topical anesthetic to anesthetize nasal mucosa with cotton-tipped applicators followed by a transnasal needle insertion guided by its tailored plastic cover-sheath for injecting

From: Department of Anesthesiology and Pain Medicine, Bronx-Lebanon Hospital Center, Albert Einstein College Of Medicine, Bronx, NY
Address Correspondence: Ian Y. Yang, MD, 75 Cayuga Road, Yonkers, NY 10710
Email: iyangmd@yahoo.com

This work was presented as a poster discussion at the 11th World Congress on Pain, August 22-25, 2005, Sydney, Australia.

Disclaimer: There was no external funding in preparation of this manuscript.

Conflict of Interest: None

Manuscript received on 02/22/2006

Revision submitted on 03/22/2006

Accepted for publication on 03/28/2006

blocking agents. With minimally expected disturbances, the patient consented. The first procedure was performed with fluoroscopy. The left nasal cavity, between the middle and inferior turbinates, from nares to posterolateral wall of the nasopharynx was anesthetized topically with 1.5% lidocaine + 1:200,000 epinephrine using cotton-tipped applicators. This passage was sterilized by an additional cotton-tipped applicator soaked with iodine solution. A 26-gauge/5-inch spinal needle with its plastic cover-sheath (The New Gertie Marx® Needle, IMD Inc., Huntsville, Utah) was used for the transnasal injection. We chose this brand due to the presence of an indicator on the hub for the location of needle tip side port and the slim profile of the cover-sheath to fit the nasal meatus between the middle and inferior turbinates of this patient. The tip of the sheath was cut obliquely at 45° with a sterile scalpel to expose the needle tip (2 mm). The bevel of the cut was marked on the other end of the sheath. The exposed needle tip was bent along the port side with a sterile needle-holder to form a 45° angle opposite to the bevel

of the sheath, so that the side port indicator on the hub became a tip pointer (Fig. 1). The needle was then withdrawn back in the sheath until its tip disappeared. The sheath-needle assembly was lubricated with 2% lidocaine jelly, inserted into the anesthetized nasal meatus and advanced with the bevel mark facing laterally. When the tip of the assembly came in contact with the posterolateral wall of the nasopharynx, the needle was pushed out through the sheath into the posterolateral nasopharyngeal mucosa with the tip pointer facing laterally. The patient did not feel the process of needle penetration. After negative aspiration, 1.5 mL contrast (iohexol 240 mg I/ml) was injected and fluoroscopy was taken on both anteroposterior and lateral views. It revealed the needle tip located near the posterolateral wall of the left nasal cavity medial to the medial pterygoid plate at the level of the middle concha (Fig. 2a). Satisfactory contrast flow in the pterygopalatine fossa superoposterior to the left maxilla was shown without vascular uptake (Fig. 2b). Subsequently, triamcinolone 20 mg in 1.5 mL of 0.2% ropivacaine was injected. The needle

was flushed and removed. A dry cotton-tipped applicator was inserted down to assure no bleeding after needle removal. The patient tolerated the procedure well without sedation. He was pain free for one week and had 60% pain reduction with less frequent episodes (1-3 times/day), which were easily controlled with abortive medicine for three weeks. We performed further blocks without fluoroscopy. The patient experienced similar pain relief.

DISCUSSION

Sluder first advocated the sphenopalatine ganglion block transnasally with topical use of cocaine in 1908 (3). Later, he advanced his technique to transnasal needle injection of carbolic acid (phenol) in an effort to obtain prolonged relief (4). Ruskin introduced the transoral and the lateral injection approaches thereafter (5, 6).

The transnasal injection technique, either blindly or with the assistance of a speculum, carries the danger of nasal mucosa sloughing during needle insertion (7). This led to the development of the transnasal endoscopic technique in which the topical block, or needle infiltration, was performed under direct vision using rigid sinuscope (8). For the transoral approach, the identification of the needle entry point may be difficult in inexperienced hands. The needle may not stop automatically on the sphenoid and pass beyond the buttress of the sphenoid to anesthetize other structures (5, 7). The lateral infratemporal approach definitely requires image guidance (7, 9, 10). The transnasal topical technique remains the most popular approach for the block because of its simplicity (11-13). It can be easily done with a cotton-tipped applicator soaked with local anesthetics or performed with local anesthetic dripping or spray (14). However, the diffusion of the topical anesthetics through the nasal mucosa is not predictable even with a properly placed applicator (15). When the dripping or spray method uses large amount of local anesthetics, systemic effect of absorbed local anesthetics may play a role of analgesia. This has raised concerns for checking blood levels of local anesthetics in relation to deter-




Fig. 1. *Transnasal sphenopalatine ganglion injection needle-sheath assembly. A 26-G/5-inch spinal needle with its plastic cover-sheath was modified for injection: the tip of the sheath was cut obliquely at 45° to expose the needle tip (2mm) and the exposed needle tip was bent 45° opposite to the sheath bevel. The needle was withdrawn in the sheath until its tip disappeared before the use.*

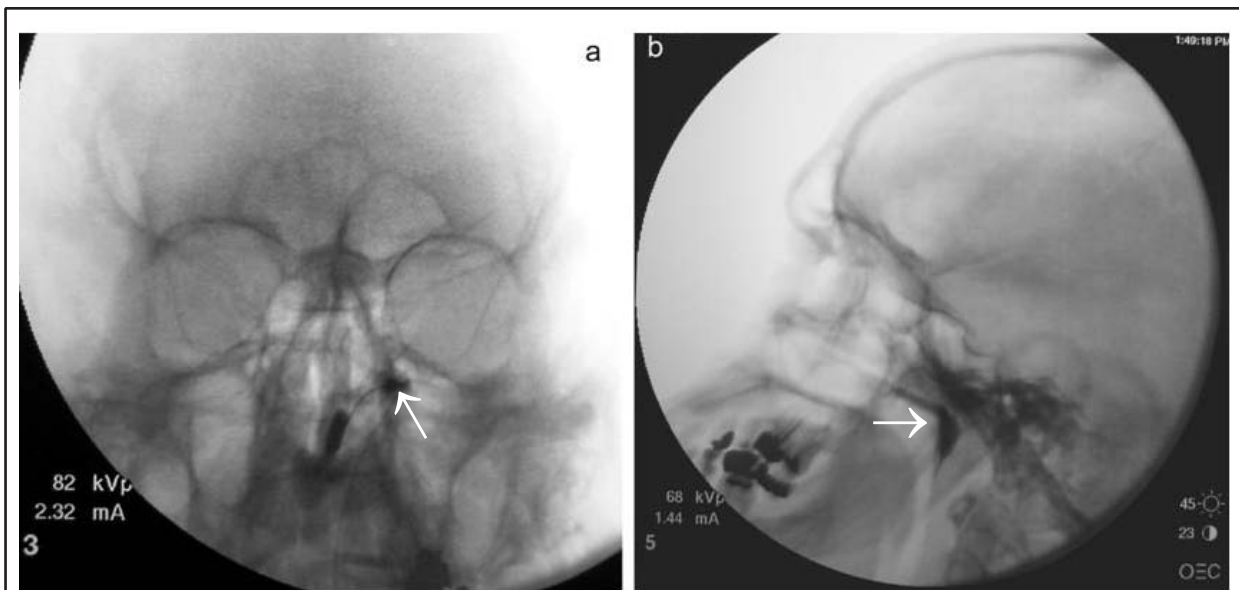


Fig. 2. Fluoroscopic views of blocking needle and contrast flow. On the anteroposterior view, the needle tip was located in the left nasal cavity medial to the medial pterygoid plate of the sphenoid bone at the level of the middle concha (arrow) (a). On the lateral view, x-ray contrast flow in the pterygopalatine fossa superoposterior to the left maxilla was shown without vascular uptake (arrow) (b).

mining their analgesic effects (16).

Our method is a blind, yet accurate, safe transnasal needle injection technique. It is similar to the original transnasal topical approach but takes advantages of needle injection. The fact that the patient underwent the procedure without any sedation suggested its tolerability. The fluoroscopic findings evidenced its accuracy. No bleeding or other complications occurring after each block demonstrated its safety. Prolonged pain relief as compared with the results from topical technique in the same patient indicated its predictable and durable effect.

The tailored plastic cover-sheath of the needle may have played an important role in this setting. First, the plastic sheath over the needle was successfully used as an atraumatic guide avoiding needle scratching. The 45° bevel on the tip of the sheath made the sheath tip opening contact the nasopharynx posterolaterally, thus the needle was guided toward the posterolateral wall during its emergence. The 45° angle on the needle tip further facilitated the needle penetrating laterally. Second, the plastic sheath functioned as a stopper to prevent over-penetration when the needle

was pushed out. The sheath was purposely cut approximately 2 mm shorter than the length of the needle shaft. When the needle was pushed until the hub contacted against the sheath the depth of needle penetration in the mucosa would be approximately 2 mm. Third, the hollow sheath tip may have incidentally acted as a compressor around the needle entrance to achieve hemostasis. A gentle pressure applied on the sheath-needle assembly to determine the contact between the sheath tip and the nasopharynx provided a compression effect on the tissue around the needle entrance. There was no bleeding found after each block. This was confirmed by a routine dry cotton-tipped pledget placed down to the nasopharynx after each needle removal. Therefore, the tailored plastic cover-sheath functioned as a guide, a stopper and a compressor for this new transnasal injection technique.

CONCLUSION

Sphenopalatine ganglion injection via topically anesthetized nasal cavity, guided by a tailored plastic sheath, may be an effective alternative to the conventional techniques. The sheath-needle

assembly we used was a crude manual modification of an existing needle. A manufactured needle with a bent tip and differently sized sheathes will better fit the variety in patient anatomy.

AUTHOR AFFILIATION:

Ian Y. Yang, MD
 Department of Anesthesiology and Pain Medicine
 Bronx-Lebanon Hospital Center
 Albert Einstein College of Medicine
 1650 Grand Concourse
 Bronx, NY 10457
 Email: iyangmd@yahoo.com

Saeed Oraee, MD
 Department of Anesthesiology and Pain medicine
 Bronx-Lebanon Hospital Center
 Albert Einstein College of Medicine
 1650 Grand Concourse
 Bronx, NY 10457

REFERENCES

1. Berkovitz BKB. Nose, nasal cavity, paranasal sinuses and pterygopalatine fossa. In Standring S (ed). *Gray's Anatomy: The Anatomical Basis of Clinical Prac-*

- tice. 39th ed. Elsevier Churchill Livingstone, Edinburgh, UK, 2005, p 578.
2. Waldman SD. Sphenopalatine ganglion block. In Waldman SD (ed). Atlas of interventional pain management. 2nd ed. WB Saunders, Philadelphia, 2004, pp 11-22.
 3. Sluder G. The role of the sphenopalatine ganglion in nasal headache. *NY State J Med* 1908; 27:8-13.
 4. Sluder G. A phenol (carbolic acid) injection treatment for sphenopalatine ganglion neuralgia. *JAMA* 1911; 62:2137.
 5. Sluder G. Injection of the nasal ganglion and comparison of methods. *Ann Otol Rhinol Laryngol* 1927; 86:648-655.
 6. Ruskin SL. Techniques of sphenopalatine therapy. *Eye Ear Nose Throat Mon* 1951; 30:28-31.
 7. Cambareri JJ. Sphenopalatine ganglion. In Thomas PS (ed). Image Guided Pain Management. Lippincott Raven Publishers, Philadelphia, 1997, pp 27-33.
 8. Prasanna A, Murthy PS. Sphenopalatine ganglion block under vision using rigid nasal sinuscope. *Reg Anesth* 1993; 18: 139-140.
 9. Day M. Sphenopalatine ganglion analgesia. *Curr Rev Pain* 1999; 3: 342-347.
 10. Raj PP, Lou L, Erdine S, Staats PS. Sphenopalatine ganglion block and neurolysis. In: Raj PP, Lou L, Erdine S, Staats PS (eds). *Radiographic Imaging for Regional Anesthesia and Pain Management*. Churchill Livingstone, New York, 2003, pp 66-71.
 11. Peterson JN, Schames J, Schames M, King E. Sphenopalatine ganglion block: a safe and easy method for the management of orofacial pain. *Cranio* 1995; 13: 177-181.
 12. Saberski L, Ahmad M, Wiske P. Sphenopalatine ganglion block for treatment of sinus arrest in postherpetic neuralgia. *Headache* 1999; 39:42-44.
 13. Shah RV, Racz GB. Long-term relief of posttraumatic headache by sphenopalatine ganglion pulsed radiofrequency lesioning: a case report. *Arch Phys Med Rehabil* 2004; 85:1013-1016.
 14. Russell AL. Sphenopalatine block-the cheapest technique in the management of chronic pain. *Clin J Pain* 1991; 7: 256-257.
 15. Janzen VD, Scudds R. Sphenopalatine block in the treatment of pain in fibromyalgia and myofascial pain syndrome. *Laryngoscope* 1997; 107: 1420-1422.
 16. Redick LF. Response to sphenopalatine ganglion block with intranasal lidocaine on submaximal effort tourniquet test pain. *Reg Anesth* 1994; 19: 293.