

## Anatomic Study

# e The Morphology and Possible Clinical Significance of the Intraforaminal Ligaments in the Entrance Zones of the L1-L5 Levels

Enyi Zhong, PhD<sup>1</sup>, Qinghao Zhao, PhD<sup>2</sup>, Benchao Shi, PhD<sup>3</sup>, Yushan Xie, MD<sup>1</sup>, Zihai Ding, MD<sup>1</sup>, Hai Lv, PhD<sup>2</sup>, Shizhen Zhong, MD<sup>1</sup>, and Wenhua Huang, PhD<sup>3</sup>

From: <sup>1</sup>Department of Anatomy, Guangdong Provincial Key Laboratory of Medical Biomechanics, School of Basic Medical Science, Southern Medical University, No.1838, Guang Zhou Avenue North, Guangzhou 510515, China; <sup>2</sup>Department of Orthopedics, The Third Affiliated Hospital of Southern Medical University, No. 183, Zhongshan Rd West, Guangzhou, 510630, China; <sup>3</sup>Department of Orthopedics, Zhujiang Hospital, Southern Medical University, No. 253, Gongye Rd, Guangzhou 510282, China

Address Correspondence: Wenhua Huang, PhD  
Department of Anatomy  
Guangdong Provincial Key Laboratory of Medical Biomechanics  
School of Basic Medical Science  
Southern Medical University,  
No.1838  
Guang Zhou Avenue North  
Guangzhou 510515, China  
E-mail:  
huangwenhua2009@139.com

Disclaimer: Enyi Zhong and Qinghao Zhao contributed equally to this work. This study was supported by grants from the Science and Technology Project of Guangzhou (Grant No. 201704020033) and the Science and Technology Project of Guangdong Province (Grant No. 2015B010125005). There are no potential conflicts of interest-associated biases in the text of the manuscript.

Manuscript received: 06-02-2017  
Revised manuscript received: 09-15-2017  
Accepted for publication: 10-20-2017

Free full manuscript:  
www.painphysicianjournal.com

**Background:** The extraforaminal ligaments between the L1-L5 lumbar spinal nerves and the tissues surrounding the intervertebral foramina (IVF) have been well studied. However, little research has been performed to describe the local anatomy of the entrance zones at the L1-L5 level. Detailed anatomic studies of the intraforaminal ligaments (IFLs) in the entrance zones at the L1-L5 levels have not been performed.

**Objectives:** The objective of this study is to identify and describe the IFLs in the entrance zones of the L1-L5 IVF and to determine their possible clinical significance.

**Study Design:** A dissection-based study of 10 fresh-frozen human cadavers.

**Setting:** Guangdong Provincial Key Laboratory of Medical Biomechanics in Anatomy Department of Southern Medical University.

**Methods:** Eighty L1-L5 IVF from 10 fresh cadavers were studied, and the IFLs in the entrance zones were identified. The quantities, morphologies, origins, insertions, and spatial orientations of the IFLs in the entrance zones of the L1-L5 IVF were observed. The lengths, widths, diameters, and thicknesses of the ligaments were measured using a vernier caliper. Ten intraforaminal radiating ligaments were removed for histological examination.

**Results:** A total of 197 ligaments were identified in the entrance zones of the 80 L1-L5 IVF, including 191 (96.95%) radiating ligaments and 6 (3.05%) transforaminal ligaments. The thickest ligaments were observed at the L3-L4 IVF. The lengths of the ligaments varied from 0.59 to 11.92 mm. There were 66 (33.50%) ligaments in the superior aspect of the entrance zone of the IVF, 58 (29.44%) ligaments at the anterior aspect, 43 (21.83%) ligaments at the posterior aspect, and 30 (15.23%) ligaments at the inferior aspect. The morphologies of the IFLs were divided into 2 types: the strap type and the trabs type. Histological examination of the meningovertebral ligaments revealed fibrous connective tissue.

**Limitations:** The major limitation of this study is the lack of actual clinical data from live patients. In addition, future medical biomechanics experiments are expected to contribute more objective data on the strength of the IFLs.

**Conclusions:** In the lumbar spine, IFLs are common structures in the entrance zones of the L1-L5 IVF, and radiating ligaments are more likely to be present.

**Key words:** Clinical Anatomy, microdissection, intraforaminal ligament, the entrance zone, L1-L5 intervertebral foramen, endoscopic spinal adhesiolysis, sacral hiatus, cerebrospinal fluid leakage, dural laceration

**Pain Physician 2018; 21:E157-E165**

Lee et al (1) divided the intervertebral foramen (IVF) into the entrance zone, middle zone, and exit zone. The entrance zone is the most cranial part of the IVF and is located medial side of the pedicles and superior articular process. The mid zone is located under the pars interarticularis part of the lamina and below the pedicle. The exit zone is the area surrounding the IVF. The nerve roots proceed through these zones from the inside to the outside. Amonoo-Kuofi et al (2) divided the ligaments associated with the L1-L4 IVFs into 3 categories: internal ligaments, intraforaminal ligaments (IFLs), and external ligaments. The internal ligament group includes the oblique inferior transforaminal ligaments (TFLs) in the lower part of IVF. A great deal of research has been undertaken to describe the extraforaminal ligaments (EFLs) at the lumbar level, and the oblique inferior TFLs and superior corporotransverse ligaments are the most frequently reported types of TFL (3-9).

Several authors (3,6-8,10-12) have indicated that TFLs decrease the cross-sectional area of the IVF and increase the risk of lumbar nerve root compression in the foramen. However, the ligaments in the entrance zones of the L1-L5 IVFs have been largely overlooked. Previous researches have not elaborated the morphologies, distributions, or possible clinical significances of the IFLs in the entrance zone of L1-L5 IVFs.

Endoscopic spinal adhesiolysis through the sacral hiatus is a minimally invasive procedure that allows the visualization and accurate localization of lesions in the spinal canal or neural foramen for mechanical release treatment (13). However, surgeons' lack of knowledge of the structure of the entrance zone in the IVF may probably influence the efficiency of operation. Once handled incorrectly, it may cause failures in wound healing or sinus tract formations (14,15). Therefore, detailed knowledge of the IFLs in the entrance zones of L1-L5 IVFs will help improve the efficacy of endoscopic spinal adhesiolysis and reduce the incidence of complications. The purpose of this study was to clarify the anatomy and possible surgical significance of these ligaments.

## METHODS

The foraminal anatomies of 10 cadavers (6 men and 4 women, with no evidence of previous spinal surgery) with ages at the time of death ranging from 35 to 75 years (mean age, 55 years) were studied. No specimen exhibited any evidence of spinal pathology, such as catagenic disorders, abnormalities, arthritic or

rheumatic conditions, or trauma involving or disrupting the IVF structures. The L1-L5 spinal columns were separated from the T11 to T12 discs and the sacroiliac joint with an electric band saw. The independent ethics committee approved the study.

The soft tissues around the spine were carefully removed and the spine columns were opened in the median sagittal plane. The spinal nerve roots within the fascia were identified and the overlying remnants of adipose tissue and fascia were carefully removed. The loose connective tissue in the IVF was scrupulously separated from the lateral IVF to the medial IVF opening under a surgical microscope (Carl Zeiss Inc., Jena, Germany) while preserving any tough ligamentous structures that were encountered in the process. The various IFLs were outlined and identified from the entrance zones of the L1-L5 IVFs. The relationships of the IFLs with the spinal nerve and other surrounding structures were photographically documented.

For all of the IVFs, the morphologies, distributions, origins, insertions, and spatial orientations of the ligamentous structures were recorded. The lengths, widths, diameters, and thicknesses of the ligamentous structures were measured with a caliper (accurate to 0.01 mm) under a surgical microscope.

Ten radiating IFLs in the entrance zones were removed from the IVFs, which were subject to regular paraffin embedding, sectioning, hematoxylin and eosin staining, and Masson trichrome staining before the histological properties were examined under a microscope.

The commercially available SPSS Version 20.0 software (IBM Corporation, Armonk, NY) was used to analyze the recorded data. The measurement data were expressed in the form " $\bar{X} \pm S(\text{min-max})$ ," and the enumeration data were tested with the Wilcoxon signed-rank test and the Kruskal-Wallis H test. The data represent repeated measurements from the same researcher, and the average values of the repeated measurements were used for the statistical analyses. The surveyor was not blinded during the analysis.

## RESULTS

In this study, a total of 197 ligaments were identified in the entrance zones of the 80 L1-L5 IVFs, and the occurrence rate of IFLs was 100%. One hundred ninety-one (96.95%) of the ligaments were radiating ligaments that connected the nerve root sleeves that radiated to the transverse processes or the walls of the IVF, and 6 (3.05%) ligaments were TFLs that connected

the structures around the IVFs. The radiating ligaments were identified more often than the TFLs were ( $Z = -3.933, P = 0.000$ ). The thickest ligament was observed at the L3-L4 IVF. The lengths of the ligaments varied from 0.59 to 11.92 mm. There were 66 (33.50%) ligaments at the superior aspect of the entrance zone of the IVFs, 58 (29.44%) ligaments at the anterior aspect, 43(21.83%) ligaments at the posterior aspect, and 30 (15.23%) ligaments at the inferior aspect.

The superior radiating ligaments originated from the medial margin of the pedicle of the vertebral arch or the posterior longitudinal ligament of the postero-superior margin of the vertebra and proceeded to the nerve root. The inferior ligaments originated from the

anterior of the zygapophysial joint, and the posterior longitudinal ligament of the postero-inferior margin of the vertebra or the postero-superior margin of the disc and proceeded to the nerve root. The anterior radiating ligaments originated from the posterior longitudinal ligament of the posterior margin of the vertebra and proceeded to the nerve root, whereas the posterior ligaments originated from the ligamentum flavum and proceeded to the nerve root. The TFLs originated from the posterior longitudinal ligament of the posterior margin of the intervertebral disc and proceeded to the superior articular process.

The measurements of the ligaments in the entrance zones of the IVFs are presented in Table 1.

Table 1. *The measurements of the ligaments in the entrance zones of the IVFs “ $\bar{X} \pm S$  (minimum–maximum).”*

Vertebral Segments	Shape	Direction	Number (%)	Length (mm)	Width (mm)	Diameter/Thickness (mm)
L1-L2	Strap	Superior	16 (34.78)	4.74 ± 1.48 (1.24 – 6.59)	2.46 ± 1.14 (0.77 – 4.56)	0.60 ± 0.30 (0.14 – 0.99)
		Inferior	4 (8.70)	6.32 ± 3.03 (3.65 – 10.63)	2.93 ± 1.19 (2.01 – 4.56)	1.15 ± 0.10 (1.09 – 1.30)
		Anterior	8 (17.39)	3.11 ± 0.49 (2.39 – 3.69)	2.59 ± 1.29 (1.02 – 3.98)	0.73 ± 0.54 (0.35 – 2.01)
		Posterior	3 (6.52)	3.61 ± 0.14 (3.52 – 3.77)	1.60 ± 0.13 (1.45 – 1.68)	0.40 ± 0.14 (0.25 – 0.53)
	Trabs	Superior	0	—	—	—
		Inferior	3 (6.52)	6.61 ± 2.69 (4.56 – 9.66)	—	1.14 ± 0.07 (1.09 – 1.22)
		Anterior	10 (21.74)	4.13 ± 0.98 (2.94 – 5.64)	—	0.73 ± 0.29 (0.32 – 1.02)
		Posterior	2 (4.35)	4.73 ± 1.18 (4.60 – 4.86)	—	0.60 ± 0.03 (0.58 – 0.62)
L2-L3	Strap	Superior	18 (28.13)	5.64 ± 1.75 (2.09 – 8.19)	2.60 ± 1.22 (0.35 – 4.68)	0.66 ± 0.22 (0.33 – 0.96)
		Inferior	8 (12.50)	4.04 ± 0.73 (3.51 – 5.66)	1.19 ± 0.77 (0.66 – 3.00)	0.60 ± 0.27 (0.29 – 0.92)
		Anterior	14 (21.88)	4.12 ± 1.48 (2.35 – 6.98)	1.85 ± 0.85 (0.65 – 2.98)	0.65 ± 0.32 (0.25 – 1.16)
		Posterior	8 (12.50)	3.28 ± 0.79 (2.29 – 4.69)	2.81 ± 2.65 (1.09 – 8.09)	0.64 ± 0.32 (0.19 – 1.04)
	Trabs	Superior	2 (3.13)	6.63 ± 0.24 (6.46 – 6.80)	—	0.47 ± 0.08 (0.41 – 0.52)
		Inferior	4 (6.25)	4.86 ± 1.10 (3.25 – 5.60)	—	0.42 ± 0.22 (0.20 – 0.65)
		Anterior	2 (3.13)	5.36 ± 1.00 (4.65 – 6.06)	—	0.66 ± 0.01 (0.65 – 0.66)
		Posterior	8 (12.50)	2.35 ± 0.76 (1.47 – 3.29)	—	1.27 ± 0.28 (0.89 – 1.65)

Table 1 (cont.). *The measurements of the ligaments in the entrance zones of the IVFs “ $\bar{X} \pm S$  (minimum–maximum).”*

Vertebral Segments	Shape	Direction	Number (%)	Length (mm)	Width (mm)	Diameter/Thickness (mm)
L3-L4	Strap	Superior	6 (14.29)	4.26 ± 2.53 (2.65 – 9.06)	2.34 ± 1.59 (1.05 – 5.03)	0.94 ± 0.25 (0.55 – 1.25)
		Inferior	2 (4.76)	6.12 ± 0.04 (6.09 – 6.15)	3.58 ± 2.11 (2.09 – 5.07)	1.02 ± 0.70 (0.52 – 1.51)
		Anterior	10 (23.81)	2.66 ± 1.49 (1.09 – 6.09)	5.03 ± 1.37 (2.59 – 6.19)	0.50 ± 0.21 (0.25 – 0.85)
		Posterior	14 (33.33)	3.67 ± 1.23 (2.11 – 3.36)	3.27 ± 1.42 (1.24 – 5.67)	0.43 ± 0.23 (0.21 – 0.98)
	Trabs	Superior	4 (9.52)	4.02 ± 3.11 (2.09 – 8.66)	—	1.02 ± 0.33 (0.56 – 1.29)
		Inferior	0	—	—	—
		Anterior	6 (14.29)	3.75 ± 0.23 (3.43 – 4.09)	—	1.74 ± 1.40 (0.35 – 4.02)
		Posterior	0	—	—	—
L4-L5	Strap	Superior	14 (31.11)	3.80 ± 2.31 (0.59 – 6.86)	1.65 ± 1.05 (0.22 – 2.99)	1.40 ± 1.27 (0.26 – 3.95)
		Inferior	4 (8.89)	10.20 ± 1.93 (8.07 – 11.92)	3.29 ± 1.19 (2.64 – 5.06)	0.53 ± 0.35 (0.32 – 1.05)
		Anterior	4 (8.89)	2.60 ± 0.07 (2.52-2.65)	2.97 ± 0.09 (2.89 – 3.09)	0.74 ± 0.15 (0.64 – 0.96)
		Posterior	8 (17.78)	2.24 ± 0.80 (1.31-3.23)	2.73 ± 2.08 (0.66 – 5.01)	1.56 ± 1.30 (0.28 – 2.86)
	Trabs	Superior	6 (13.33)	5.09 ± 3.03 (2.08 – 9.61)	—	0.62 ± 0.20 (0.35 – 0.95)
		Inferior	5 (11.11)	8.39 ± 1.91 (5.69 – 1.095)	—	1.06 ± 0.05 (0.98 – 1.11)
		Anterior	4 (8.89)	2.96 ± 0.03 (2.94 – 2.99)	—	1.47 ± 0.28 (1.05 – 1.65)
		Posterior	0	—	—	—

(%) = Ligament number percentage within each direction; IVF = intervertebral foramen

**L1-L2 IVF**

A total of 46 (23.35%) ligaments were found in the entrance zone of 20 IVFs. All of these ligaments were radiating ligaments. Of these, relative to the nerve root, 18 (39.13 %) ligaments were located anterior, 16 (34.78 %) were located superior, 7 (15.22 %) were located inferior, and 5 (10.87 %) were located posterior. One internal ligament that passed obliquely downward and backward from the posterolateral surface of the L1-L2 intervertebral disc to the anterior surface of the superior articular process was found (Figs. 1 and 2).

**L2-L3 IVF**

A total of 64 (32.49%) ligaments were found in the entrance zones of the 20 IVFs, and the distribution of

ligaments at this level was the highest ( $\chi^2 = 42.819$ ,  $P = 0.000$ ). Sixty (93.75%) of these were radiating ligaments, and 4 (6.25%) were TFLs. Of these, relative to the nerve root, 20 (31.25%) ligaments were located superior, 16 (25.00%) were located posterior, 16 (25.00%) were located anterior, and 12 (18.75%) were located inferior. One internal ligament that passed obliquely downward and backward from the posterolateral surface of the L2-L3 intervertebral disc to the anterior surface of the superior articular process was found. The TFL originated from the posterior longitudinal ligament of the posterior margin of the intervertebral disc and proceeded to the superior articular process (Figs. 3 and 4).

Fig. 1. (A and B) Medial views of the right L1-L2 IVF. Photo of fresh cadavers.

CR = cranial; L1 = first lumbar vertebral body; D1 = intervertebral disc of the first lumbar vertebra; SP = cross section of the first lumbar spinous process; NR = L1 nerve root; P = pedicle of the vertebra; Z = zygapophyseal joint; I = internal ligament; V = vein . \*IFLs intraforaminal ligaments.

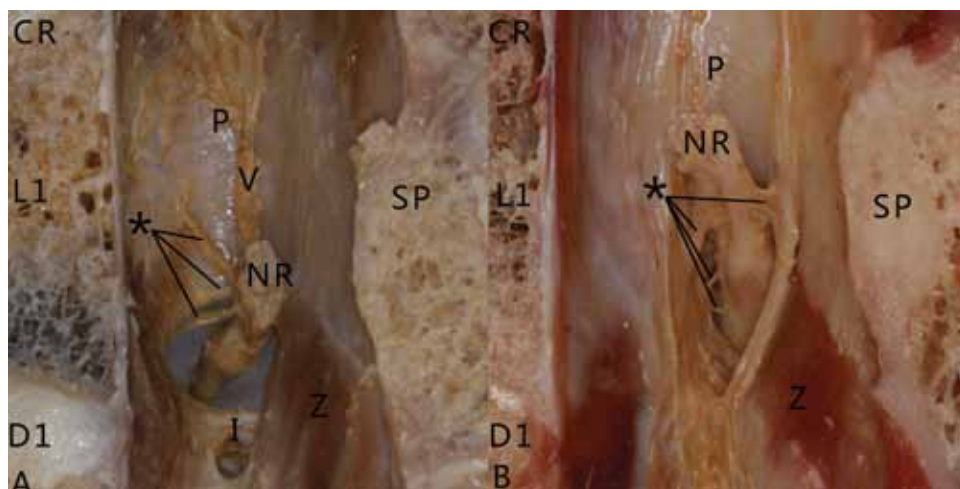
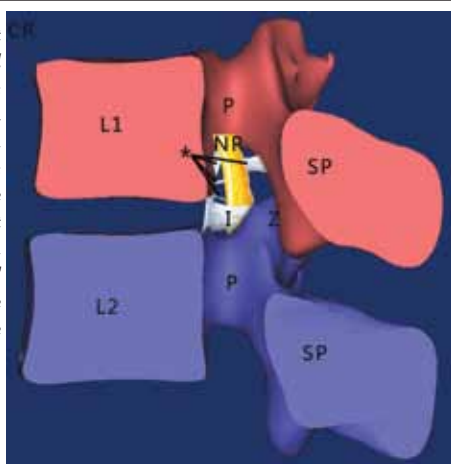
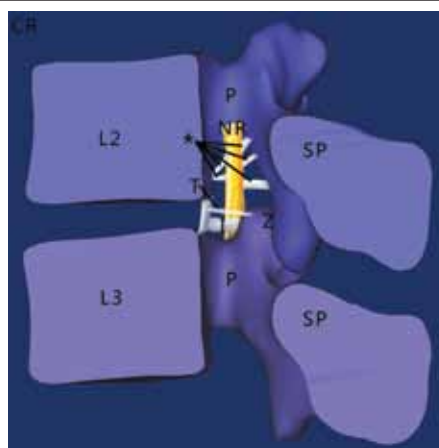


Fig. 2. Right medial view. This simulation diagram illustrates all of the ligaments that are described in the L1-2 IVF entrance zone section of the text.



CR = cranial; L1 = first lumbar vertebral body; L2 = second lumbar vertebral body; P = pedicle of the vertebra; NR = L1 nerve root; SP = cross section of the lumbar spinous process; Z = zygapophyseal joint; I = internal ligament . \*IFLs

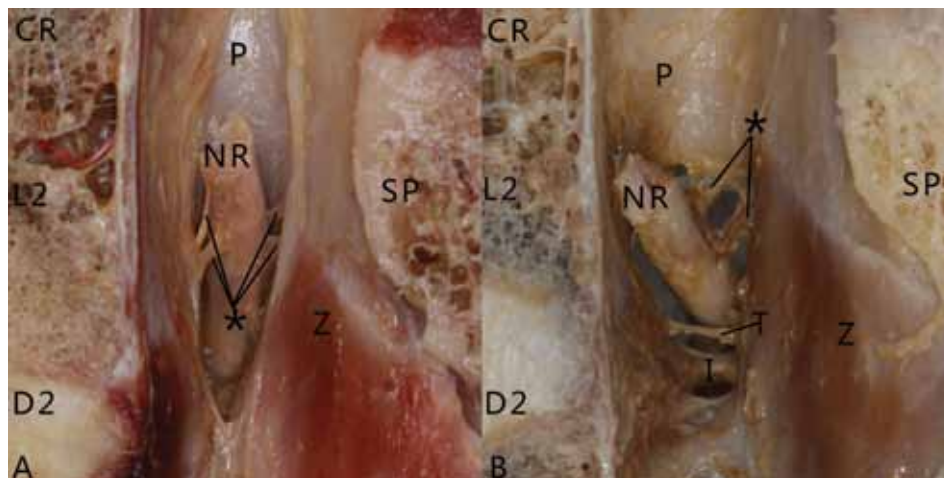
Fig. 4. Right medial view. This is a simulation diagram illustrating all of the ligaments that are described in the L2-L3 IVF entrance zone section of the text.



CR = cranial; L2 = second lumbar vertebral body; L3 = third lumbar vertebral body; P = pedicle of the vertebra; NR = L2 nerve root; SP = cross section of the lumbar spinous process; Z = zygapophyseal joint; I = internal ligament; T = transforaminal ligament . \*IFLs

Fig. 3. (A and B) Medial views of the right L2-L3 IVF. All photos are of fresh cadavers.

CR = cranial; L2 = second lumbar vertebral body; D2 = intervertebral disc of the second lumbar vertebra; SP = cross section of the second lumbar spinous process; NR = L2 nerve root; P = pedicle of the vertebra; I = internal ligament; Z = zygapophyseal joint; T = transforaminal ligament . \*IFLs



**L3-L4 IVF**

A total of 42 (21.32%) ligaments were found in the entrance zones of 20 IVFs. Forty (95.24%) of these were radiating ligaments, and 2 (4.76%) were TFLs. Of these ligaments, 16 (38.10%) were located anterior to the nerve root, 14 (33.33%) were located posterior, 10 (23.81%) were located superior, and 2 (4.76%) were located inferior. The thickest ligament (4.02 mm) was observed in the anterior aspect in the entrance zone of the L3-L4 IVF. We observed some small vasculature coming from the radiculomedullary arterial structures that spanned the IFL to nourish the spinal canal structures through the superior edge of the IVF (Figs. 5 and 6).

**L4-L5 IVF**

A total of 45 (22.84%) ligaments were found in the entrance zones of the 20 IVFs. All of these ligaments were radiating ligaments. Of these ligaments, 20 (44.44%) were located superior to the nerve root, 9 (20.00%) were inferior, 8 (17.78%) were anterior, and 8 (17.78%) were posterior. We observed some IFLs that were accompanied by small vascular structures nourishing spinal nerve root and other structures in the spinal canal; these structures originated from the radiculomedullary artery and progressed through the superior edge in the IVF (Figs. 7 and 8).

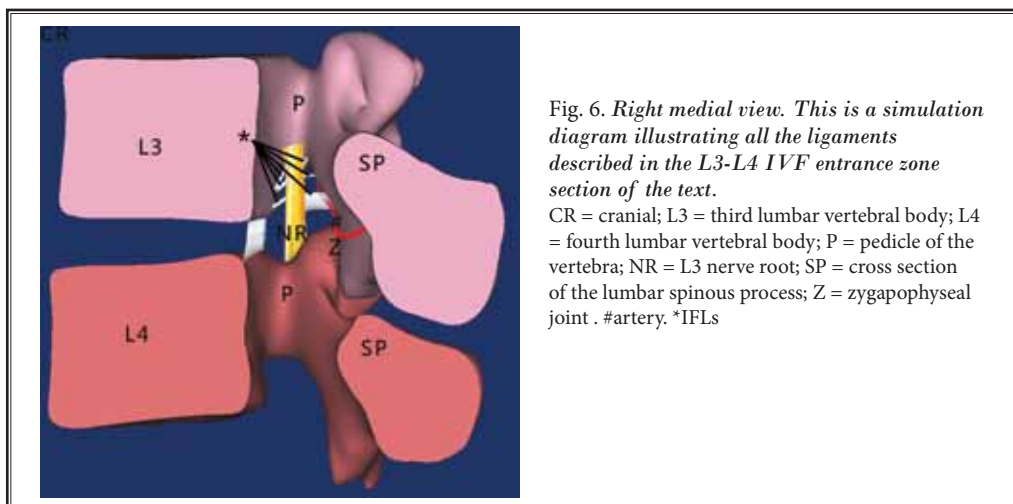
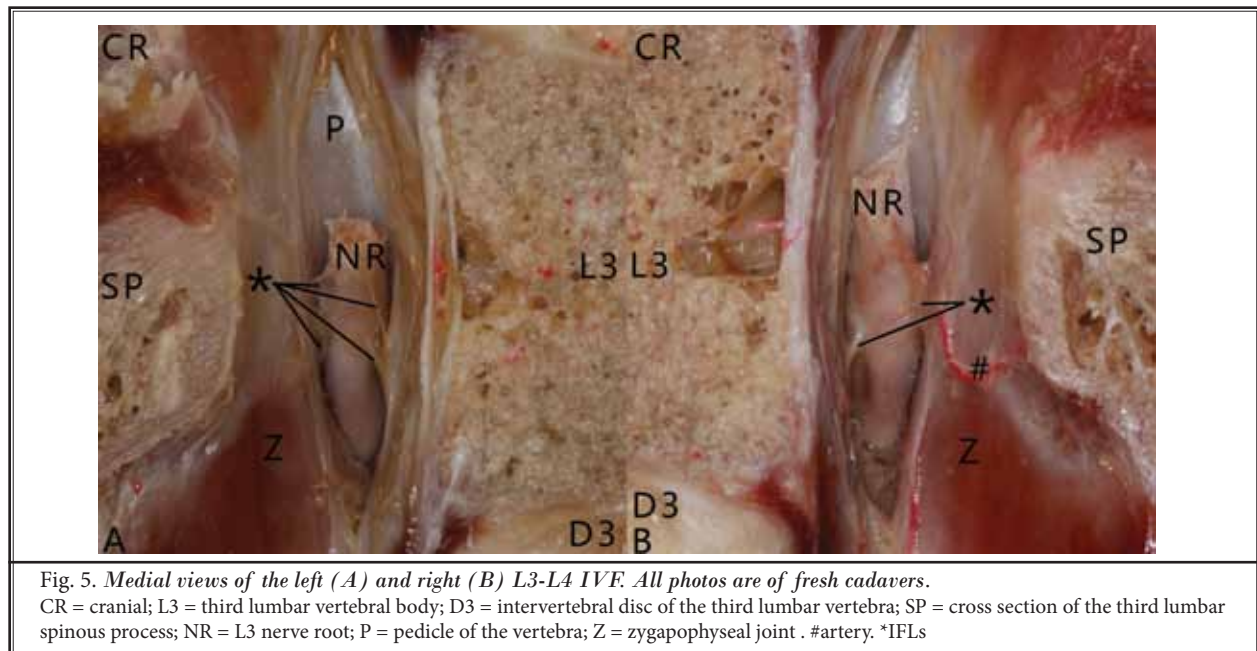
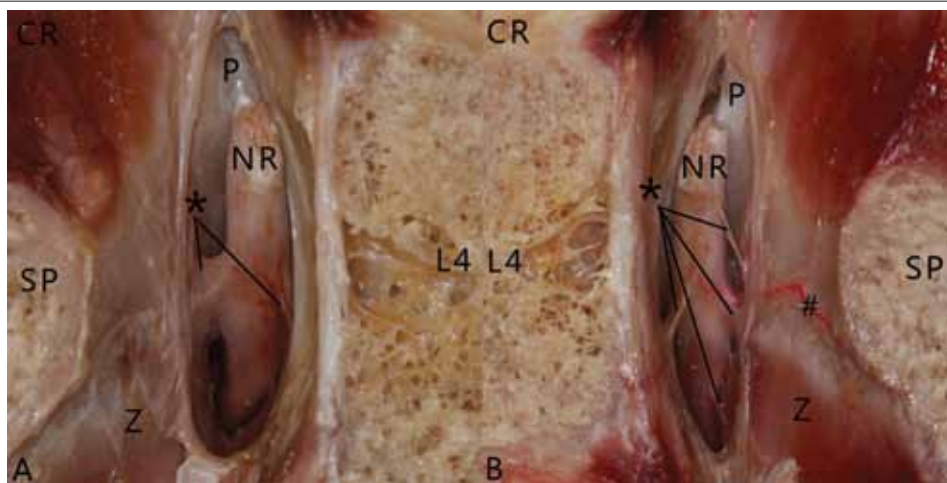


Fig. 7. Medial views of the left (A) and right (B) L4-L5 IVF. All photos are of fresh cadavers. CR = cranial; L4 = fourth lumbar vertebral body; SP = cross section of the fourth lumbar spinous process; NR = L4 nerve root; P = pedicle of the vertebra; Z = zygapophyseal joint #artery \*IFLs



Under a light microscope, hematoxylin and eosin staining (Fig. 9A) revealed that the radiating ligaments in the entrance zones were composed of fibrous connective tissue. Masson trichrome staining (Fig. 9B), which labels collagen fiber with blue and elastic fiber with red, revealed that the radiating ligaments consisted mostly of collagen fibers and a few elastic fibers.

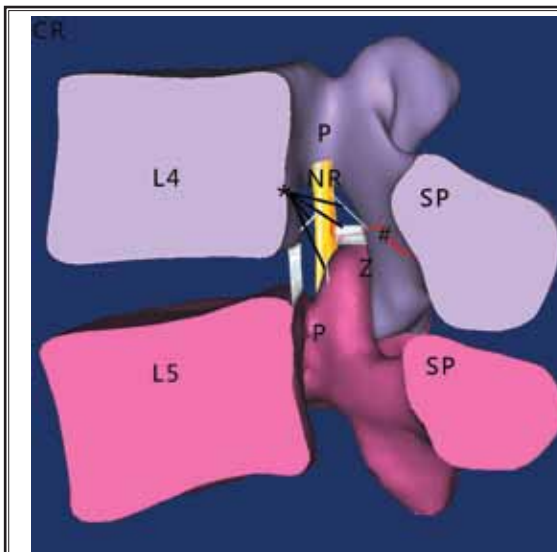


Fig. 8. Right medial view. This is a simulation diagram illustrating all of the ligaments described in the L4-L5 IVF entrance zone section of the text. CR = cranial; L4 = fourth lumbar vertebral body; L5 = fifth lumbar vertebral body; P = pedicle of the vertebra; NR = L4 nerve root; SP = cross section of the lumbar spinous process; Z = zygapophyseal joint #artery \*IFLs

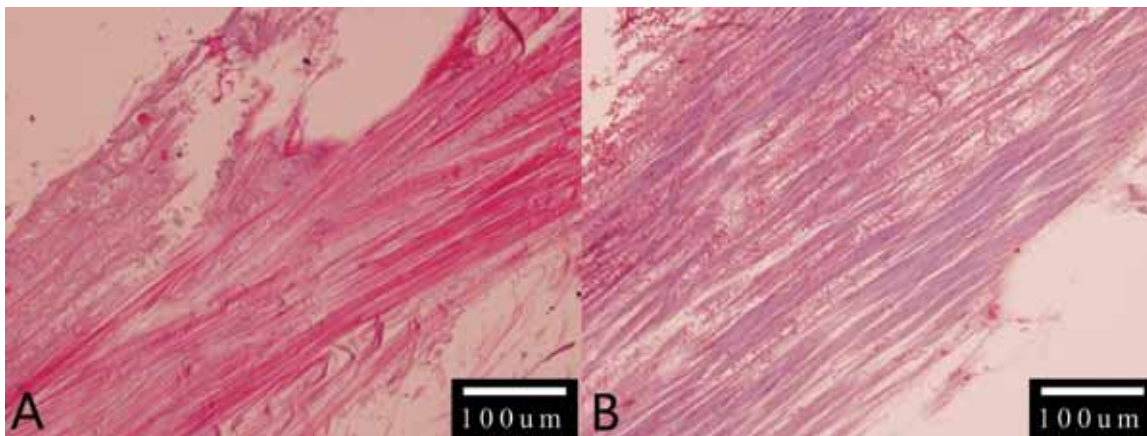


Fig. 9. The photomicrographs of hematoxylin and eosin staining (A) and Masson trichrome staining (B). Both images are at 20× magnification. HE staining reveals that the radiating ligaments are composed of fibrous connective tissue. Masson's trichrome staining reveals that the radiating ligaments consist of many collagen fibers staining green and relatively fewer elastic fibers staining red.

## DISCUSSION

Grimes et al (16) found 4 distinct bands extending radially from the nerve root sleeve in the lower lumbar IVFs. The most prominent nerve root attachment was to the facet capsule posteriorly. Other ligaments fanned out with attachments inferiorly and superiorly to the adjacent pedicles and anteriorly to the intervertebral disc. Akdemir et al (4) studied IFLs within the thoracic and lumbar IVFs and found that these IFLs extend around the transforaminal ligaments, periosteum, and vessels to the nerve root. These ligaments were visible throughout the length of the foramina in each level of each cadaver's spine. But the IFLs in the entrance area had not been described in detail in previous researches. We observed the quantities, morphologies, origins, insertions, and spatial orientations of the IFLs in the entrance zones of the L1-L5 IVFs in detail. In our experiment, we found that most of the IFLs in the entrance zone are radiating ligaments, connecting nerve roots to the periosteum and TFLs of the IVFs. In addition, we also observed that the morphologies of the IFLs could be mainly classified into 2 types: one is the strap type, which is relatively slender ligament strongly stretching the nerve root, and another is the trabs type, which is relatively wide ligament loosely connecting with the nerve root.

Park et al (7) suggested that the degeneration of the intervertebral disc can cause a decreased foraminal cross-sectional area and compression of the anterior branch of the nerve root by the TFL, which manifests as low back pain symptoms. Kraan et al (17) described the EFLs' attachments to human lumbar nerves; at all lumbar levels (Th12-L5), superior and inferior ligaments can be observed. The superior EFLs have an effect on anteroposterior positioning of the spinal nerve. When moved up and down, the EFLs' attachment could prevent nerve roots from contacting the IVF. Inferior EFLs at L2-L5 levels prevent the spinal nerve from being pulled out of the IVFs. In 2010, Kraan et al (5) studied the biomechanical properties of the EFLs, and further confirmed that the lumbar EFLs act to provide traction relief and prevent spinal nerve compression. Moreover, Akdemir et al (4) suggested that the IFL within IVF acts in conjunction with the dura and the periosteum to mechanically protect the nerve roots, and further suggested that the pain and neurological deficits experienced by patients following surgery or degenerative disease progression can be caused by damage to these IFLs. Grimes et al (16) considered that lower lumbar foraminal ligaments may limit motion of the nerve root.

Zhao et al (18) described the IFLs at the L5-S1 levels in their systematic anatomy study and concluded that the IFLs have a protective effect on the nerve root in normal circumstances, but under abnormal condition, the IFLs may cause back pain.

Therefore, we speculate that the IFLs in the entrance zones of L1-L5 IVFs may play a similar role. Under normal circumstances, the IFLs in the entrance zones of the L1-L5 IVFs may restrict or stretch the spinal nerves to prevent extrusion by the lumbar vertebral pedicles or other bony structures, which would cause lumbocrural pain during ordinary physical activities that produce flexion, extension, lateral bending, or axial rotation of the spine. In a few cases, when the ligaments are abnormally distributed or hypoplastic or when the nerve roots are abnormally developed, it could significantly increase the risk of compression of blood vessel or nerve root within the IVF (5,16). In the test we observed that the gap between the nerve root and the IVF wall is filled with fat and other soft tissue, and we speculate that the IFLs may immobilize or resist the nerve root such that it cannot migrate to the opposite side to escape compression. This situation may produce compression symptoms when the nerve root is compressed by a herniated disc or a lesion in a bony structure.

Endoscopic spinal adhesiolysis through the sacral hiatus is a minimally invasive procedure that allows for direct visualization and accurate localization of the spinal canal or neural foramen lesion for mechanical release treatment (13). If surgeons know the morphology and distribution of the nerve root, blood vessels, and ligaments in the region clearly, they could release nerve root or inject drugs in higher precision, which may reduce operation time, lower potential risks, and improve the efficiency of surgery (13,18).

Histologically, Akdemir (4) demonstrated that the intraforaminal ligaments, which radially surrounded the roots and attached to the root sheath, were mainly composed of the collagen located in the fat. Similarly, our histological examination also showed that the radiating ligaments mainly comprised collagen fibers with low content of elastic fibers.

Through cautious dissections of cadavers, we found that some IFLs were accompanied by small vascular structures. Excessive manipulations of these ligaments may cause epidural hemorrhaging due to injuries to these epidural vessels, which are closely linked to the ligaments. We also found that the distribution of venous plexus in the intravertebral region is complicated. Additionally, future studies of the arterial and venous



plexus surrounding the nerve roots are expected to contribute more objective data.

### Limitations

The major limitation of this study is the lack of actual clinical data from live patients. In addition, future medical biomechanics experiments are expected to contribute more objective data on the strength of the IFLs.

### CONCLUSION

This is the first systematic anatomical study to describe the IFLs in the entrance zones at the L1-L5 level, which provides the surgeons with detailed and accurate anatomical data. Thorough understanding of the anatomical characteristics and distribution of these ligaments may reduce the operation time and improve the efficiency of surgery.

### REFERENCES

- Lee CK, Rauschnig W, Glenn W. Lateral lumbar spinal canal stenosis: Classification, pathologic anatomy and surgical decompression. *Spine (Phila Pa 1976)* 1988; 13:313-320.
- Amonoo-Kuofi HS, El-Badawi MG, Fattani JA. Ligaments associated with lumbar intervertebral foramina. 1. L1 to L4. *J Anat* 1988; 156:177-183.
- Qian Y, Qin A, Zheng MH. Transforaminal ligament may play a role in lumbar nerve root compression of foraminal stenosis. *Med Hypotheses* 2011; 77:1148-1149.
- Akdemir G. Thoracic and lumbar intraforaminal ligaments. *J Neurosurg Spine* 2010; 13:351-355.
- Kraan GA, Smit TH, Hoogland PV, Snijders CJ. Lumbar extraforaminal ligaments act as a traction relief and prevent spinal nerve compression. *Clin Biomech (Bristol, Avon)* 2010; 25:10-15.
- Min JH, Kang SH, Lee JB, Cho TH, Suh JG. Anatomic analysis of the transforaminal ligament in the lumbar intervertebral foramen. *Neurosurgery* 2005; 57:37-41.
- Park HK, Rudrappa S, Dujovny M, Diaz FG. Intervertebral foraminal ligaments of the lumbar spine: Anatomy and biomechanics. *Childs Nerv Syst* 2001; 17:275-282.
- Bakkum BW, Mestan M. The effects of transforaminal ligaments on the sizes of T11 to L5 human intervertebral foramina. *J Manipulative Physiol Ther* 1994; 17:517-522.
- Golub BS, Silverman B. Transforaminal ligaments of the lumbar spine. *J Bone Joint Surg Am* 1969; 51:947-956.
- Cramer GD, Skogsbergh DR, Bakkum BW, Winterstein JF, Yu S, Tuck NR Jr. Evaluation of transforaminal ligaments by magnetic resonance imaging. *J Manipulative Physiol Ther* 2002; 25:199-208.
- Spencer DL, Irwin GS, Miller JA. Anatomy and significance of fixation of the lumbosacral nerve roots in sciatica. *Spine (Phila Pa 1976)* 1983; 8:672-679.
- Hasue M, Kikuchi S, Sakuyama Y, Ito T. Anatomic study of the interrelation between lumbosacral nerve roots and their surrounding tissues. *Spine (Phila Pa 1976)* 1983; 8:50-58.
- Pereira P, Severo M, Monteiro P, Silva PA, Rebelo V, Castro-Lopes JM, Vaz R. Results of lumbar endoscopic adhesiolysis using a radiofrequency catheter in patients with postoperative fibrosis and persistent or recurrent symptoms after discectomy. *Pain Pract* 2016; 16:67-79.
- Sugawara T, Itoh Y, Hirano Y, Higashiyama N, Shimada Y, Kinouchi H, Mizoi K. Novel dural closure technique using polyglactin acid sheet prevents cerebrospinal fluid leakage after spinal surgery. *Neurosurgery* 2005; 57:290-294.
- Wang JC, Bohlman HH, Riew KD. Dural tears secondary to operations on the lumbar spine. Management and results after a two-year-minimum follow-up of eighty-eight patients. *J Bone Joint Surg Am* 1998; 80:1728-1732.
- Grimes PF, Massie JB, Garfin SR. Anatomic and biomechanical analysis of the lower lumbar foraminal ligaments. *Spine (Phila Pa 1976)* 2000; 25:2009-2014.
- Kraan GA, Delwel EJ, Hoogland PV, van der Veen MR, Wuisman PI, Stoelkarts R, Kleinrensink GJ, Snijders CJ. Extraforaminal ligament attachments of human lumbar nerves. *Spine (Phila Pa 1976)* 2005; 30:601-605.
- Zhao Q, Zhong E, Shi B, Li Y, Ding Z. The morphology and clinical significance of the intraforaminal ligaments at the L5-S1 levels. *Spine J* 2016; 16:1001-1006.

