

Cross-sectional Study



Long-term Clinical Effects of DiscoGel for Cervical Disc Herniation

Havva Sayhan, MD¹, Serbüent Gökhan Beyaz, MD¹, Ali Metin Ülgen, MD¹,
Mehmet Fatih Yüce, MD², and Yakup Tomak, MD¹

From: ¹Sakarya University Faculty of Medicine, Department of Anesthesiology and Pain Medicine, Sakarya; ²Istanbul Fatih Sultan Mehmet Training Research Hospital, Department of Anesthesiology, Istanbul

Address Correspondence:
Serbüent Gökhan Beyaz, MD
Sakarya University Training Research Hospital
Korucuk Campus
Anesthesiology and Pain Medicine
54290, Adapazarı
Sakarya, Republic of Turkey
E-mail: sgbeyaz@gmail.com

Disclaimer: There was no external funding in the preparation of this manuscript. Conflict of interest: Each author certifies that he or she, or a member of his or her immediate family, has no commercial association (i.e., consultancies, stock ownership, equity interest, patent/licensing arrangements, etc.) that might pose a conflict of interest in connection with the submitted manuscript.

Manuscript received: 04-04-2017
Revised manuscript received:
06-15-2017
Accepted for publication:
06-27-2017

Free full manuscript:
www.painphysicianjournal.com

Background: Radiopaque gelified ethanol (RGE; DiscoGel®, Gelscom SAS, France) is used as a chemonucleolysis substance in treating intradiscal herniation, showing good results without complications. It has also been used in cervical disc herniations (CDHs), demonstrating the potential efficacy of this substance.

Objective: The aim of the study is to investigate the long-term effectiveness and safety of DiscoGel® in patients with CDH and chronic neck pain.

Study Design: This is a cross-sectional, single-center study.

Setting: The study was conducted from November 2013 to May 2016 on patients visiting Sakarya University Training and Research Hospital's pain clinic .

Methods: Each patient was evaluated before the procedure (baseline) and at 1, 3, 6, and 12 months after the procedure, using the visual analog scale (VAS) score for pain, the Oswestry Disability Index score to measure degree of disability, and estimate quality of life for those with pain; this coincides with scores on the Neuropathic Pain Questionnaire (DN4) for differential diagnoses.

Results: Thirty-three patients with CDH underwent the same treatment with DiscoGel® between November 2013 and May 2016. Significant pain relief was noted, as opposed to preoperative pain, at 1, 3, 6, and 12 months after the procedure according to each patient's self-evaluation ($P=0.01$). Differences in VAS, ODI, and DN4 scores between 1, 3, 6, and 12 months with the same variables were not statistically significant. There were no complications with the procedure.

Limitations: Our study was conducted retrospectively, which led to problems with long-term follow-up data. In addition, this study was performed with a small group of patients.

Conclusions: RGE is a potential alternative to surgery for patients with pain at the cervical level. However, we concluded that more studies with longer follow-up intervals with RGE will be necessary for assessment of the technique's efficiency.

Key words: Cervical pain, herniation, neuropathic pain, injection, DiscoGel®, chemonucleolysis

Pain Physician 2018; 21:E71-E78

Disc disorders of the cervical spine often present as cervical radiculopathy or myelopathy and can affect a patient's quality of life. Symptomatic cervical disc disease has been reported at an annual incidence of 83 per 100,000 individuals in the general population (1,2).

The cervical spinal cord may be considered the more important segment of the spinal anatomy compared to that in the lumbar or thoracic segments. This

portion of the spinal cord is susceptible to life-altering injuries, due to anatomic structures affecting the respiratory musculature in the autonomic nervous system. Disc herniation is one of the most common spine diseases, so several techniques have been introduced as conservative methods (medication and physical therapy), epidural injections (interlaminar or transforaminal), minimally invasive percutaneous treatments, and surgery (3,4). In general, minimally invasive approaches provide lower

complication rates, shorter hospital stays, and reduced stress in patients (5). To date, there is an increase in patients with cervical disc disorders, common in the neck, shoulders, and arms, which leads to pain and disability. Therefore, the use of cervical percutaneous treatment has an obviously growing importance for nonsurgical management (6).

Chemonucleolysis is among the percutaneous treatments; it is an efficient technique, consisting of an intradiscal injection that incorporates chemical properties to dissolve the nucleus pulposus (NP) and lower intradiscal pressure (7). Injection of radiopaque gelified ethanol (RGE) in the disc results in molecular splitting of proteoglycans in the NP, reducing nuclear volume and withdrawal of the protrusion (8). High diffusibility of liquid ethanol can be managed by adding ethylcellulose for increased viscosity and better injection control, with less dispersion of the material post-injection (9). The ethylcellulose acts on the herniated disc to generate dehydration of the NP, given its hydrophilic properties.

RGE (DiscoGel[®], Gelscom SAS, France) is used as a chemonucleolysis substance to treat lumbar intradiscal herniation (LDH), showing good results without complications (9). It has also been used in cervical disc herniations (CDHs), demonstrating the potential efficacy of this substance (10). In spite of satisfactory clinical outcomes and good patient compliance, DiscoGel[®] is a safe, alternative therapy in selected cases; however, it is not often used in patients with CDH. This uncommon technique for the cervical level can affect significant anatomic structures, given their close proximity to the dura and narrow intervertebral discs of the spine, which can lead to severe injuries.

The aim of this study was to investigate the long-term efficacy and safety of DiscoGel[®] as a therapeutic substance for chemonucleolysis application in patients with CDH, especially those who have had chronic pain and weakness of the neck, shoulders, and arms.

METHODS

This cross-sectional, single-center study of 33 patients used DiscoGel[®] at Sakarya University Training and Research Hospital in Sakarya, Turkey. Sakarya University's Faculty of Medicine Review Board (71522473/050.01.04/131) approved the study, and it was registered on www.ClinicalTrials.gov.

Participants

The study was conducted from November 2013 to May 2016 on patients visiting the hospital's pain clinic;

they usually had cervical discogenic or radicular pain that did not resolve after conventional therapy or cervical interlaminar or transforaminal epidural steroid injection therapy. Written informed consent was obtained from all patients. A sample of 33 patients undergoing RGE was assessed and observed until the end of the follow-up period (12 months), whereas if any patients were difficult to follow, they were excluded.

Inclusion criteria were as follows: 18–70 years of age, continuous radicular pain radiating to the upper limb, with a duration \geq 12 weeks and an intensity $>$ 4/10 as rated by the patient on a visual analog scale (VAS, 0 = no pain at all and 10 = worst pain imaginable), resistant to appropriate conservative treatment (combining anti-inflammatory drugs and physical therapy), and confirmed by a computed tomography (CT) or magnetic resonance imaging (MRI) of a herniated disc putting pressure on a nerve root consistent with the clinical pain.

Exclusion criteria included a history of surgery of the cervical spine, along with any contraindication to percutaneous chemonucleolysis techniques (coagulopathy or infection), allergy to drugs, imaging results that did not support clinical results, presence of a herniated disc that was calcified on imaging, possible interference with pain evaluation due to any medical condition or treatment, and incomplete data collection.

STUDY DESIGN

This study was designed to evaluate long-term clinical effects of DiscoGel[®] in patients with CDH. Data collected from medical record forms and the hospital's electronic medical record system were used in the analysis of data (with regard to age, gender, and related complications). Each patient was evaluated at time intervals before the procedure (baseline) and at 1, 3, 6, and 12 months after the procedure, using the VAS score (11) for pain, the Oswestry Disability Index (ODI) to measure the degree of disability, and estimate quality of life for those with pain (12), along with scores on the Neuropathic Pain Questionnaire (DN4) (13) for differential diagnoses. A resident who was not involved in the study interviewed each patient in a follow-up visit to collect the related information. Adverse effects were also recorded after the procedure.

Techniques

Procedures were performed with conscious sedation under aseptic conditions and fluoroscopy guidance (C-arm x-ray system, Siemens Healthcare, Germany).

Sedation was achieved with 50 µg fentanyl and 1 mg midazolam plus local injection of lidocaine into the subcutaneous tissue. Intravenous injection of antibiotic therapy included 1 g of ceftriaxone disodium and was performed before the procedure. All interventions were done with spinal needles (22-gauge, 10 cm), as the patient was placed in a supine position to advance the needle into the cervical intervertebral discs with an anterolateral approach. The neck was put into slight hyperextension by placing a pillow under the shoulders. The right-sided approach was preferred in all cases, as a consequence of the esophagus being on the left.

The spinal needle was advanced between the larynx and jugular-carotid vessels under sublaxation of the larynx, until it reached the anterior longitudinal ligament, with continuous fluoroscopic control. At that point, the needle was advanced to the center of the disc space (Fig. 1). When satisfied with the needle placement, anteroposterior, oblique, and lateral images were obtained for fluoroscopic guidance to check the needle-tip's position. Next, 0.2 mL of DiscoGel® was injected slowly (0.1 mL/min) into the NP. The syringe plunger was pushed all the way in with the medication and was maintained for 10 minutes prior to releasing the pressure and removing the needle. The fluoroscopic image involved a repeated injection.

Post-Procedural Care

Patients were monitored for a half hour after the procedure in the post-anesthetic care unit and then transferred to the general ward. Posterioranterior (PA) and lateral radiography were performed 3 hours after the injection for all patients; this was done to evaluate the distribution of RGE and possible leaks. After that, patients were discharged in the absence of any complications and were told to take anti-inflammatories, antibiotics, and analgesic drugs until the follow-up consultation 10 days later. A soft cervical collar was prescribed for 3 days to limit neck motion and to provide splinting and rest in a comfortable position.

Statistical Analysis

Analysis was performed on the VAS, ODI, and DN4 score values collected from all of the patients before treatment and at 1, 3, 6, and 12 months after treatment. Their descriptive statistics such as mean, SD, median, and interquartile range are shown in Figs. 2 and 3. To detect a statistically significant change of the VAS, ODI, and DN4 score values in the post-treatment period compared to the pretreatment period, we used a paired t

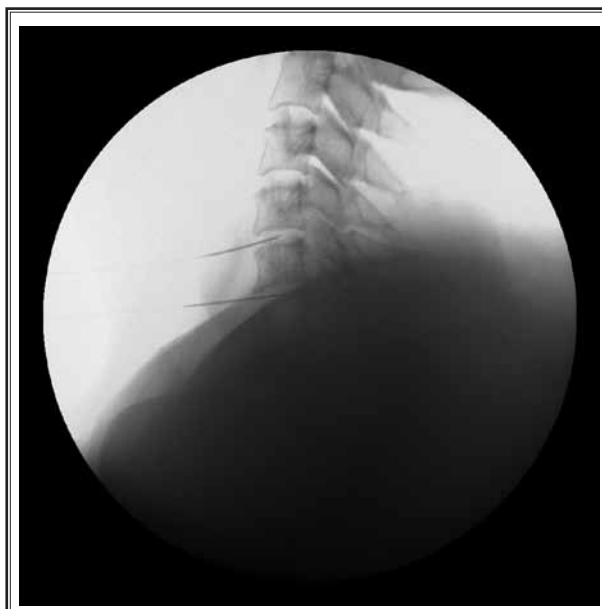

Fig. 1. The needle was advanced to the center of the disc space.

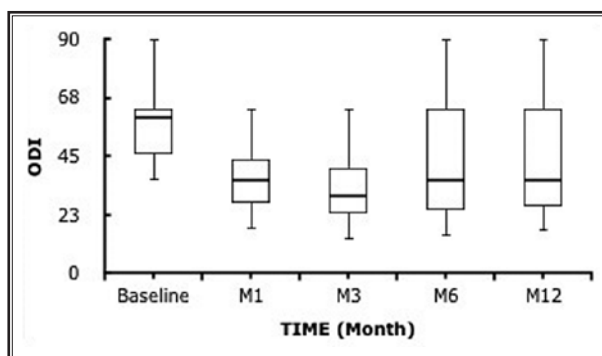


Fig. 2. Evolution of pain intensity values on the VAS at the pre-operative consultation and at one and three months after the procedure with DiscoGel®. The whiskers show the range of values and the horizontal line within each box represents the median.

Abbreviations: M1 = 1 month postoperative; M3 = 3 months postoperative; M6 = 6 months postoperative; M12 = 12 months postoperative; baseline = preoperative

test and Wilcoxon matched-pairs signed-rank test. The null hypothesis, i.e., no difference between observed values before and after treatment, was then assumed for each series of scores. The series of ODI scores were labeled according to the canonical standing 12 and then cross-tabulated to represent the Pre-to-Post Rank transition. In correspondence to each rank detected

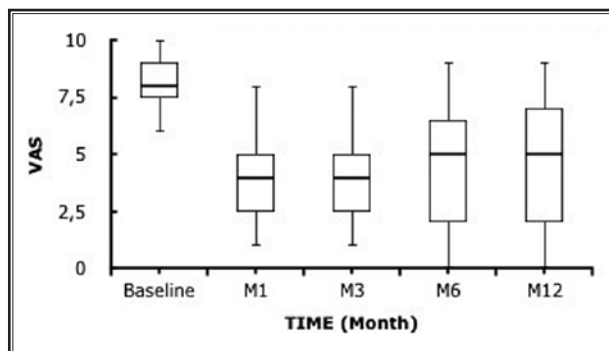


Fig. 3. Evolution of pain intensity values on the ODI at the pre-operative consultation and at one and 3 months after the procedure with DiscoGel®. The whiskers show the range of values and the horizontal line in each box represents the median.

Abbreviations: M1 = 1 month postoperative; M3 = 3 months postoperative; M6 = 6 months postoperative; M12 = 12 months postoperative; baseline = preoperative

before RGE injection, as well as the percentage of patients who recovered after treatment, the best rank (i.e., minimal disability with the ODI score not 20%) was calculated.

The differences between pain intensities at the 5 time-points (baseline and 1, 3, 6, and 12 months postoperative) and between each time residual pain was assessed using the Kruskal-Wallis or the Mann-Whitney test. The influence of categorical variables (gender, disc level, location of the herniation, etc.) was assessed using the t test or Mann-Whitney test or, in the case of multiple comparisons, the Kruskal-Wallis test followed by Dunn's multiple comparisons test (if the Kruskal-Wallis test was globally significant). Differences in pain intensity changes across the groups defined by the abovementioned variables were assessed using the Kruskal-Wallis test in the event of a significant difference, using Dunn's Multiple Comparison Test. Moreover, $P < 0.05$ was considered significant. We computed 95% confidence intervals (95% CIs). The statistical analyses were performed using SPSS Version 9.0 (SPSS Inc., Chicago, IL).

RESULTS

Thirty-three patients with CDH underwent the same treatment for a single- or double-disc level problem with RGE (Fig. 4). Eighteen women (55%) and 15 men (45%) from 34 to 65 years old (mean 48.68 ± 9.40) were treated. Treatment was technically successful in 33 patients, for a total of 48 disc herniations (C4-C5: 7 patients; C5-C6: 15 patients; C6-C7: 26 patients). In 18

patients, a single disc level (C6-7) was treated, and in 15 patients, 2 disc levels were treated (C5-6/C6-7: 8 cases; C4-5/C5-6: 7 cases). There were no relevant complications related to the procedure in any patient preoperatively, and there were also no cases of local or systemic infection. Again, we evaluated RGE treatment at 1, 3, 6, and 12 months postoperatively versus preoperatively on the VAS, ODI, and DN4 scores, as shown in Table 1. Significant pain relief was noted, as opposed to preoperative pain, at 1, 3, 6, and 12 months postoperatively according to the patient's self-evaluation ($P = 0.01$). Differences in VAS, ODI, and DN4 scores at the follow-up intervals with the same variables were not statistically significant ($P > 0.05$).

The boxplot of the data for VAS scores was recorded before and after specific time intervals for percutaneous intradiscal injection of RGE, as shown in Fig. 2. Before treatment, VAS scores were concentrated on the upper values of the scale (median = 8; 25th percentile = 7; 75th percentile = 9); this distribution was negatively skewed (skewness = -0.489). The distribution of VAS scores in the post-treatment survey at one month (median = 4; 25th percentile = 2; 75th percentile = 5) and at 3 months (median = 4; 25th percentile = 2; 75th percentile = 5) became positively skewed (skewness 1 = 0.160, skewness 3 = 0.256). No outliers were identified (Fig. 1).

Between the preoperative and postoperative period of one month, the median of the VAS scores dropped by 50 percentage points. This decline was significant for the paired sample t-test ($t = 8.470$; $P < 0.0001$). For the preoperative and postoperative period of 3 months, the median of the VAS scores still dropped by 50 percentage points. This decline was significant for the paired sample t-test ($t = 8.593$; $P < 0.0001$). Between post-treatment at one month and post-treatment at 3 months, the VAS scores were not significantly different for the paired sample t-test ($t = 1.000$; $P < 0.05$).

In addition, the boxplot of the data of ODI scores recorded at the follow-up intervals demonstrated a percutaneous intradiscal injection of RGE (Fig. 2). The index is expressed in percentage points and ranges from 0–100%. The lower limit corresponds to the absence of disability; the upper limit corresponds to the maximum degree of disability (patients were bed-bound). Before treatment, the distribution of ODI scores (median = 60%; 25th percentile = 46%; 75th percentile = 63%) was positively skewed (skewness = 0.629) and stayed positively skewed (skewness = 0.447) in the post-treatment survey after one month (median = 36%; 25th percentile

Table 1. The outcome scores of cervical DiscoGel® treatment.

	Baseline (Mean ± SD)	M1 (Mean±SD)	M3 (Mean ± SD)	M6 (Mean ± SD)	M12 (Mean ± SD)	P-Value
VAS	7.97 ± 0.19	4.26 ± 0.33	4.19 ± 0.34	4.71 ± 0.48	4.87 ± 0.50	< 0.05
ODI	57.29 ± 2.71	36.23 ± 2.14	33.32 ± 2.23	41.94 ± 3.86	42.32 ± 3.79	< 0.05
DN4	5.33 ± 0.25	2.27 ± 0.60	2.20 ± 0.60	2.33 ± 0.62	2.53 ± 0.66	< 0.05

The change in VAS, ODI, and DN4* scores for patients who had cervical DiscoGel® application showed $P < 0.05$, with significance in the postoperative first and third month values compared with preoperative values.

*: Results included DN4 score 4 and over.

M1 = 1 month postoperative; M3 = 3 months postoperative; M6 = 6 months postoperative; M12 = 12 months postoperative; baseline = preoperative; SD = standard deviation; VAS = visual analog scale; ODI = Oswestry Disability Index; DN4 = Neuropathic Pain Questionnaire

= 26%; 75th percentile = 45%), and after 3 months (median = 30%; 25th percentile = 22%; 75th percentile = 43%), it skewed positively (skewness = 0.650).

As stated, the boxplot of the data of DN4 scores were recorded for percutaneous intradiscal injection of RGE (Fig. 3). Before treatment, the DN4 scores were nearly 2-fold after treatment scores (median = 3; 25th percentile = 2; 75th percentile = 6); therefore, this distribution was negatively skewed (skewness = -0.274). The DN4 scores in the post-treatment survey at 3 months (median = 0; 25th percentile = 0; 75th percentile = 3.0) became positively skewed (skewness = 1.147).

Statistical analysis indicated a significant difference in scores between pre- and post-treatment at 1, 3, 6, and 12 month conditions (Figs. 2 and 3). The percentage of the study's success was 82%. The mean decrease of the VAS scores was 4.52 with a 95% CI, 5.33 to 3.71 after one month ($P < 0.0001$) and 4.60 with a 95% CI, 5.40 to 3.80 after 3 months ($P < 0.0001$). The mean decrease of the ODI scores was 25.04 with a 95% CI, 32.25 to 17.83 after one month ($P < 0.0001$) and 28.48 with a 95% CI, 35.69 to 21.27 after 3 months ($P < 0.0001$).

After the operation, 51% (n = 17) of patients had a sore throat, 39% (n = 13) had dysphagia, 22% (n = 7) had neck stiffness, and 18% (n = 6) had some transient increase in pain, while 27% (n = 9) had no complaints. In all of the cases, symptoms resolved spontaneously a few days after treatment, while in one patient, there was a delay of 7 days. Two patients (6%) were referred to a specialist due to hoarseness, with improvement noted in 2 weeks.

DISCUSSION

Percutaneous intradiscal injection of RGE is simple, rapid, imaging-guided, and minimally invasive for intervertebral disc herniation and is performed as an outpatient procedure. RGE that was used in the cervical region reduced patients' pain severity, decreased neuropathic symptoms, and improved functional sta-

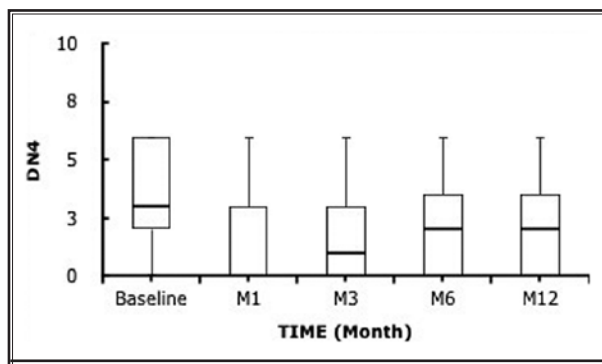


Fig. 4. Evolution of pain intensity values on the DN4 at the pre-operative consultation and at one and three months after the procedure with DiscoGel®. The whiskers show the range of values and the horizontal line within each box represents the median.

Abbreviations: M1 = 1 month postoperative; M3 = 3 months postoperative; M6 = 6 months postoperative; M12 = 12 months postoperative; baseline = preoperative

tus. RGE as a chemonucleolytic agent was introduced in 2007 by Theron et al (9), with successful results for LDH. This provides retraction of disc herniation due to dehydration of the NP. Despite this, Theron et al (10) reported therapeutic success in CDH in 2010, with a limited number of studies in the literature. The distribution of RGE in the center of the disc without any leak was controlled with C-arm fluoroscopy images. This comparison of fluoroscopy images after the procedure to those from previous studies for CDH coincides with the technique's success (10).

The most commonly affected disc levels are C5-C6 and C6-C7 in the cervical spine, which fits our cases (14). Santis et al (15) treated 50 discs in 32 patients for LDH, with L4-L5: 38%, L5-S1: 34%, L3-L4: 16%, L2-L3: 8%, and L1-L2: 4%. However, Touraine et al (16) treated 42 disc herniations at L5-S1 of 64.3% patients, L4-L5 of 33.3% patients, and L3-L4 of 2.4% patients. Our treatment was a success (neck pain relief) in 27

out of 33 patients (82%), whereas it was deemed a failure (poor outcome - recourse to surgery) in the remaining 6 patients (18%). In LDH, Volpentesta et al (17) demonstrated results of chemonucleolysis with RGE in 80.4% of 72 patients, despite a radicular irritation with neuropathic pain and a transitory sensory-motor deficit as complications in 5.45%. The study included 276 patients by Theron et al (9), which was reported as having a success rate of 89.9%, versus 2 cases with a negative outcome who went into surgery, and 8 cases who had acute herniations along with hyperalgesia. In CDH, Theron et al (10) showed improved experience in 89.5% of 57 patients for RGE, without complications. Bellini et al (18) described significant symptom improvement in 6 of 7 (83%) patients, without clinical side effects. Our experience with RGE at the cervical level has shown very promising results for the treatment of CDH, with improved symptoms in 82% of patients, similar to those published. There were no treatment-linked complications related to RGE in any patients, such as systemic allergic reactions, discitis, and neurologic injury. However, some of our patients had minimal discomfort such as a sore throat, dysphagia, neck stiffness, and a transient increase in pain at the injection site due to the needle's irritation, which disappeared spontaneously within a day of the procedure or the day after that. Two patients reported hoarseness, with improvement noted by 2 weeks. This symptom was probably due to irritation of the recurrent laryngeal nerve at the injection site.

Bellini and colleagues (18) evaluated ODI and VAS scores in 80 patients with 9 CDHs, but did not distinguish the results for the lumbar or cervical region and did not evaluate the neuropathic pattern of pain. For this reason, we cannot evaluate the results of this study with those of our own study in the same direction. Theron et al (10) described 57 patients who identified the technique in the cervical region, although there is no effective methodology to evaluate pain and functioning associated with CDH in their study. We think that the results of this study correctly assessed the effectiveness of the process performed. No related evaluation was found for ODI and VAS here, although the VAS was adequate for measuring pain between pre-treatment (baseline) and post-treatment 1, 3, 6, and 12 month conditions (Figs. 2 and 3), with the mean decrease of the VAS index at 4.52 and the ODI score at 25.04 after one month; in addition, the decrease of the mean VAS and ODI scores was 4.60 and 28.48, respectively, at 12 months.

The improvement in pain scores is in accordance with the study of Bellini et al (18), who showed that the mean decrease of VAS scores was 3.56 and ODI values was 30.38. However, they treated 9 CDHs, where 2 of 7 patients were treated for 2 discs in the same session. Another point that should be mentioned is that the VAS and ODI score values analysis was not performed separately on the CDH. Thus, there were no data relevant to pain reduction for CDH. In spite of the important reduction of symptoms in 57 patients for CDH by using RGE, Theron et al (10) did not provide any pain scale for its quantification. Further treatment response for CDH was followed-up for 3 months in the study by Bellini et al (18) and for 6 weeks by Theron et al (10). However, Touraine et al (16) reported that VAS scores in LDH were low, with a median value of 4.6 after 3 months. In the study done by Li et al (19) for LDH, a high decrease of VAS and ODI scores was found in assessments at 6 months follow-up, with a mean of 6.3 and 22.4 compared to baseline values in the same group at all points of follow-up.

Guha et al (20) performed chemonucleolysis with chymopapain on 149 patients and followed them for 5 years. The authors reported good to excellent results based on ODI and VAS scores. In a similar study, Shah et al (21) used the ODI questionnaire to estimate the functional outcome of chemonucleolysis, with a mean ODI score of 44. Karnalkar et al (22) observed a significant reduction in the VAS and ODI scores for intradiscal injection of oxygen-ozone and intraforaminal steroid for treatment of a prolapsed intervertebral disc. Final VAS and ODI scores for patients 4 years after treatment (with one diseased segment) were 4.2 and 28.0. Pauza et al (23) reported that intradiscal electrothermal annuloplasty (IDET) was a minimally invasive alternative treatment for chronic discogenic low back pain. After treatment in 32 patients, the mean VAS dropped from 6.6 to 4.2 (SD 2.3), and the mean ODI dropped from 31 to 20 (SD 11).

Chronic pain that radiates down the leg (lumbar radiculopathy or sciatica) or arm (cervical radiculopathy) is an example of neuropathic pain originating from the back or spine. Neuropathy can result from a lesion or disease affecting the somatosensory system. In addition to special hypersensitivity to a normally painful stimulus, pain from light touch or another stimulus (that does not typically cause pain) may also be characterized as neuropathy. Patients with neuropathy often describe it as being unlike any other pain they've felt before. Although it is known that disc herniation leads to neuro-

pathic pain as well as chronic and acute pain, DiscoGel® treatment for neuropathic pain is still not investigated in the literature. In this study, the DN4 questionnaire was used for evaluation of neuropathic pain following DiscoGel® treatment for CDH. DN4 scores demonstrated significantly lower values compared to baseline, except for 5 patients who had a DN4 score over 4, regardless of CDH symptoms. The DN4 scores evaluating neuropathic pain, as shown in Fig. 4, reveal that patients scored 2.53 ± 0.66 after a 12-month follow-up, with pain not characterized as neuropathic. We found that a significant improvement could be obtained with DiscoGel® treatment in CDH (24,25).

Our study does have some limitations however; it was conducted retrospectively, which led to problems in obtaining long-term follow-up data. In addition, this study was performed with a small patient population. Thus, prospective, multidisciplinary studies with large series are required.

CONCLUSION

Similar results to studies previously published for CDH confirm that RGE is potentially an efficient, cost-effective, and time-saving alternative to surgery for patients with pain at the cervical level. It should be pointed out that there were similar success rates in the treatment of disc herniations with alternative (minimally invasive) techniques, such as chymopapain, RGE, oxygen-ozone, IDET, etc. However, there are a limited number of publications on chemonucleolysis as treatment at the cervical level, which does not include long-term patient follow-ups. We conclude that continued studies with longer follow-up intervals with RGE are necessary for assessment of the technique's efficiency. Additional studies are needed to compare the outcomes of RGE with other cervical chemonucleolysis and intradiscal techniques.

REFERENCES

1. Radhakrishnan K, Litchy WJ, O'Fallon WM, Kurland LT. Epidemiology of cervical radiculopathy. A population-based study from Rochester, Minnesota, 1976 through 1990. *Brain* 1994; 117:325-335.
2. Kelsey JL, Githens PB, Walter SD, Southwick WO, Weil U, Holford TR, Ostfeld AM, Calogero JA, O'Connor T, White AA 3rd. An epidemiological study of acute prolapsed cervical intervertebral disc. *J Bone Joint Surg Am* 1984; 66:907-914.
3. Gogan WJ, Fraser RD. Chymopapain: A 10-year, double-blind study. *Spine (Phila, Pa 1976)* 1992; 17:388-394.
4. Krause D, Drape JL, Jambon F, de Souza-Lima A, Tongio J, Maitrot D, Orenstein D, Giannetti A, Boyer P, Srouf R. Cervical nucleolysis: Indications, technique, results. 190 patients. *Journal of neuro-radiology. J Neuroradiol* 1993; 20:42-59.
5. Muto M, Andreula C, Leonardi M. Treatment of herniated lumbar disc by intradiscal and intraforaminal oxygen-ozone injection. *J Neuroradiol* 2004; 31:183-189.
6. Oglesby M, Fineberg SJ, Patel AA, Pelton MA, Singh K. Epidemiological trends in cervical spine surgery for degenerative diseases between 2002 and 2009. *Spine (Phila, Pa 1976)* 2013; 38:1226-1232.
7. Theron J, Blais M, Casasco A, Courtheoux P, Adam Y, Derlon JM, Houtteville JP. Therapeutic radiology of the lumbar spine. Disk chemonucleolysis, infiltration and coagulation of posterior articulations. *J Neuroradiol* 1983; 10:209-230.
8. Riquelme C, Musacchio M, Mont'Alverne F, Tournade A. Chemonucleolysis of lumbar disc herniation with ethanol. *J Neuroradiol* 2001; 28:218-229.
9. Theron J, Guimaraens L, Casasco A, Sola T, Cuellar H, Courtheoux P. Percutaneous treatment of lumbar intervertebral disk hernias with radiopaque gelified ethanol: A preliminary study. *J Spinal Disord Tech* 2007; 20:526-532.
10. Theron J, Cuellar H, Sola T, Guimaraens L, Casasco A, Courtheoux P. Percutaneous treatment of cervical disk hernias using gelified ethanol. *AJNR Am J Neuroradiol* 2010; 31:1454-1456.
11. Grant S, Aitchison T, Henderson E, Christie J, Zare S, McMurray J, Dargie H. A comparison of the reproducibility and the sensitivity to change of visual analogue scales, Borg scales, and Likert scales in normal subjects during submaximal exercise. *Chest* 1999; 116:1208-1217.
12. Fairbank JC, Pynsent PB. The Oswestry Disability Index. *Spine (Phila Pa 1976)* 2000; 25:2940-2952.
13. Bouhassira D, Attal N, Alchaar H, Boureau F, Brochet B, Bruxelle J, Cunin G, Fermanian J, Ginies P, Grun-Overdyking A, Jafari-Schluep H, Lantéri-Minet M, Laurent B, Mick G, Serrie A, Valade D, Vicaut E. Comparison of pain syndromes associated with nervous or somatic lesions and development of a new neuropathic pain diagnostic questionnaire (DN4). *Pain* 2006; 114:29-36.
14. Gangi A, Tsoumakidou G, Buy X, Cabral JF, Garnon J. Percutaneous techniques for cervical pain of discal origin. *Semin Musculoskelet Radiol* 2011; 15:172-180.
15. de Santis F, Dall'Olio M, Princiotta C, Cirillo L, Simonetti L, Leonardi M. *Lumbar disk hernias: Percutaneous treatment with DiscoGel® in patients who did not respond to oxygen-ozone chemonucleolysis*. Oral communications lecture, III World Congress of Oxygen-ozone Therapy. Brescia, Italy. Delivered April 15, 2011.
16. Touraine S, Damiano J, Tran O, Laredo JD. Cohort study of lumbar percutaneous chemonucleolysis using ethanol gel in sciatica refractory to conservative treatment. *Eur Radiol* 2015; 25:3390-3397.
17. Volpentesta G, De Rose M, Bosco D, Stroschio C, Guzzi G, Bombardieri C, Chirchiglia D, Plastino M, Romano M, Cristofalo S, Pardatscher K, Lavano A.

- Lumbar percutaneous intradiscal injection of radiopaque gelified ethanol ("Discogel") in patients with low back and radicular pain. *J Pain Relief* 2014; 3:145.
18. Bellini M, Romano DG, Leonini S, Grazzini I, Tabano C, Ferrara M, Piu P, Monti L, Cerase A. Percutaneous injection of radiopaque gelified ethanol for the treatment of lumbar and cervical intervertebral disk herniations: Experience and clinical outcome in 80 patients. *AJNR Am J Neuroradiol* 2015; 36:600605.
 19. Li J, Yan DI, Zhang ZH. Percutaneous cervical nucleoplasty in the treatment of cervical disc herniation. *Eur Spine J* 2008; 17:1664-1669.
 20. Guha AR, Debnath UK, D'Souza S. Chemonucleolysis revisited: A prospective outcome study in symptomatic lumbar disc prolapse. *J Spinal Disord Tech* 2006; 19:167-170.
 21. Shah NH, Dastgir N, Gilmore MF. Medium to long-term functional outcome of patients after chemonucleolysis. *Acta Orthop Belg* 2003; 69:346-349.
 22. Karnalkar A, Karnalkar P. Intradiscal injection of oxygen-ozone and intraforaminal steroid for the treatment of prolapsed intervertebral disc: 4 years follow up. *Int J Res Med Sci* 2015; 3:3848-3852.
 23. Pauza KJ, Howell S, Dreyfuss P, Pelozo JH, Dawson K, Bogduk N. A randomized, placebo-controlled trial of intradiscal electrothermal therapy for the treatment of discogenic low back pain. *Spine J* 2004; 4:27-35.
 24. Hiyama A, Watanabe M, Katoh H, Sato M, Sakai D, Mochida J. Evaluation of quality of life and neuropathic pain in patients with low back pain using the Japanese Orthopedic Association Back Pain Evaluation Questionnaire. *Eur Spine J* 2015; 24:503-512.
 25. Bouhassira D, Attal N, Alchaar H, Boureau F, Brochet B, Bruxelle J, Cunin G, Fermanian J, Ginies P, Grun-Overdyking A, Jafari-Schluep H, Lantéri-Minet M, Laurent B, Mick G, Serrie A, Valade D, Vicaut E. Comparison of pain syndromes associated with nervous or somatic lesions and development of a new neuropathic pain diagnostic questionnaire (DN4). *Pain* 2005; 114:29-36.