

Retrospective Study

Early Experience of Full-Endoscopic Interlaminar Discectomy for Adolescent Lumbar Disc Herniation with Sciatic Scoliosis

Zhiming Tu, MD, Bing Wang, MD, Lei Li, MD, Yawei Li, MD, PhD, Yuliang Dai, MD, Guohua Lv, MD, PhD, and Tuoqi Li, PhD

From: Department of Spine, The Second Xiangya Hospital of Central South University, Changsha, Hunan China

Address Correspondence: Bing Wang, MD
Department of Spine
The Second Xiangya Hospital of Central South University,
No. 139 Renmin Rd
Changsha, Hunan China 410011
E-mail: xywb801@csu.edu.cn

Disclaimer: There was no external funding in the preparation of this manuscript. Conflict of interest: Each author certifies that he or she, or a member of his or her immediate family, has no commercial association (i.e., consultancies, stock ownership, equity interest, patent/licensing arrangements, etc.) that might pose a conflict of interest in connection with the submitted manuscript.

Manuscript received: 04-10-2017
Accepted for publication: 06-27-2017

Free full manuscript: www.painphysicianjournal.com

Background: Full-endoscopic interlaminar discectomy (FEID) has achieved satisfactory outcome in adolescent lumbar disc herniation (ALDH). Sciatic scoliosis is found to be a common presentation in ALDH. However, few reports are focused on the influences of sciatic scoliosis on ALDH and the prognosis of sciatic scoliosis after FEID.

Objective: This study aims to evaluate the clinical and radiological results of FEID in the treatment of ALDH with sciatic scoliosis and to identify the effects of sciatic scoliosis on complication and recurrence.

Study Design: A retrospective study.

Setting: An inpatient surgery center.

Methods: A series of cases of patients under age 20 with single-level ALDH that underwent FEID between January 2010 and December 2014 were retrospectively analyzed. The patients were divided into 2 groups according to if they had scoliosis or not. Clinical outcomes were evaluated using a visual analog scale (VAS) for low back and leg pain, Oswestry Disability Index (ODI) for the functional assessment, and modified Macnab criteria for the patient satisfaction. Radiological parameters of the scoliosis group such as Cobb angle, CVSL-max, and CVSL-C7 were statistically analyzed.

Results: No significant differences were found between both groups in terms of the mean operative time, the mean length of hospital stay, complications, and recurrences ($P > 0.05$). VAS and ODI scores were significantly improved in both groups ($P < 0.05$). However, there were no statistically significant differences between the 2 groups in VAS, ODI, and modified MacNab criteria ($P > 0.05$). For the scoliosis group, significant improvements were observed in the postoperative sagittal and coronal alignment parameters ($P < 0.05$).

Limitations: This was a retrospective study with a relatively small sample size. Additionally, the length of follow-up was short.

Conclusions: The application of FEID in the treatment of ALDH could achieve satisfactory clinical and radiological outcomes. Sciatic scoliosis was corrected spontaneously without increasing the risk of complication and recurrence.

Key words: Adolescent lumbar disc herniation, full-endoscopic interlaminar discectomy, sciatic scoliosis, recurrence

Pain Physician 2018; 21:E63-E70

Lumbar disc herniation (LDH) is one of the most common degenerative spinal diseases found among adults, while it is rarely seen among

adolescents. The incident rate of LDH varies from 1 to 5% in the pediatric and adolescent population, as reported in previous studies (1-3), and trauma is

believed to be the common cause. It has been shown that 30–60% of children and adolescents suffering from symptomatic LDH have a history of trauma or sport-related injury (4). Besides, genetic factors have also been proved as a significant cause of adolescent LDH (ALDH) (5).

Clinical presentations of ALDH are typically different from those for adults. Neurological symptoms such as numbness and weakness are less commonly seen for ALDH. However, sciatic scoliosis associated with lumbar LDH has been found for both adolescent and adult patients (6-8). The explicit pathological reasons for this phenomenon has not been elucidated, yet possible mechanisms include compensatory positioning and gait abnormalities to relieve nerve irritation (9). The direction of sciatic scoliosis is related to the side of disc herniation instead of the topographic location of nerve root compression (7). Scoliosis is more likely to occur for adolescents compared to adults, with a reported incidence of 9–82% (6,10-13).

Conservative treatment is the first choice for LDH. Surgical treatment is usually recommended for patients who have failed in nonsurgical therapy, suffering from the progressive neurologic deficit or debilitating pain (14). Open discectomy (OD) is traditionally employed as the standard operation. In recent years, endoscopic techniques have been widely used for LDH. As reported, full-endoscopic interlaminar discectomy (FEID) has achieved satisfactory outcome (15-20), as well as in the treatment of ALDH (12,21,22). A previous study suggests that scoliosis may increase the risk of recurrence of LDH after microdiscectomy (23). However, few reports are focused on the influences of sciatic scoliosis on ALDH and the prognosis of sciatic scoliosis after FEID. As such, this work aims to evaluate the clinical and radiological results of FEID for ALDH patients with sciatic scoliosis and to investigate the effects of sciatic scoliosis on complication and recurrence.

METHODS

Inclusion and Exclusion Criteria

This retrospective study included a series of patients who met the following criteria between January 2010 and December 2014: 1) younger than 20 years old (ranging from 13 to 20 years), 2) had single-level, nonforaminal and soft disc herniation located at either L4-L5 or L5-S1, as proven by magnetic resonance imaging (MRI), 3) exhibited significant symptoms and signs including low back pain, neurogenic claudication,

radiculopathy, and/or a positive straight leg-raise test, and 4) all patients underwent FEID without previous surgery. Exclusion criteria were: 1) had foraminal disc herniation, 2) older than 20 years, 3) had received prior lumbar surgery, and 4) possessed fractures, spondylolisthesis, spinal infection, tumor, spinal deformity, or other lumbar diseases. All patients had failed in some conservative treatment previously and the time interval before the surgery was at least 6 weeks.

Sciatic scoliosis was identified utilizing whole spine radiographs prior to the surgery. The criteria of scoliosis included that the Cobb's angle was $\geq 10^\circ$ (24). The patients were divided into 2 groups: the scoliosis group and the non-scoliosis group. All demographic data and perioperative and postoperative records were collected and compared between the 2 groups.

Surgical Procedures

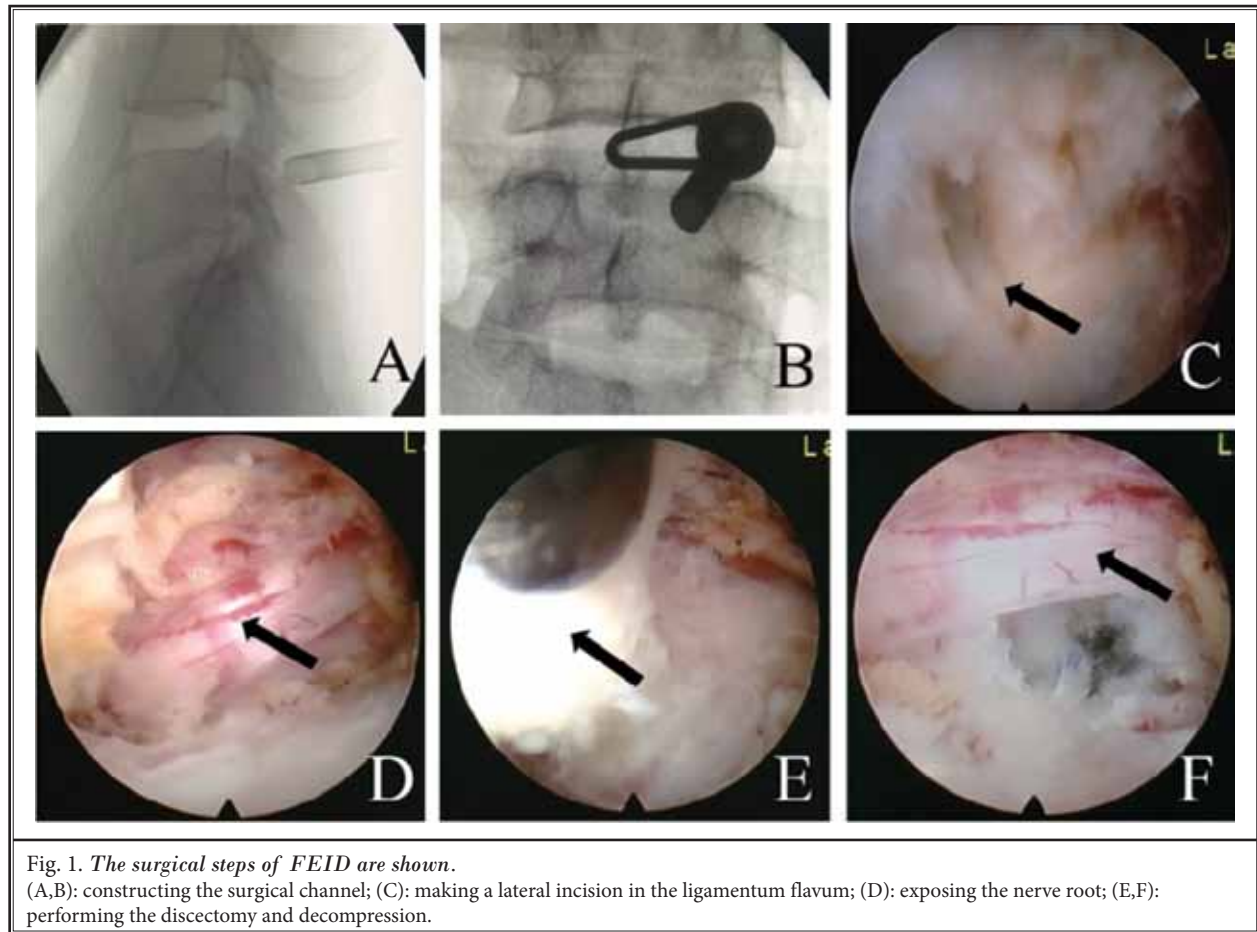
In this work, all patients underwent FEID, which was first described by Ruetten et al (18,25). All procedures were completed through an 8 mm incision with the patient in the prone position. Specific steps are shown in Fig. 1, including: 1) constructing the surgical channel, 2) making a lateral incision in the ligamentum flavum, 3) exposing the nerve root (a bur was used when necessary), and 4) performing the discectomy and decompression. All surgical instruments were supplied by Richard Wolf GmbH, Knittlingen, Germany, and all operations were performed by an experienced surgeon in our department.

Outcome Assessment

General parameters such as mean operative time, mean length of hospital stay, complications, and recurrences were recorded. Clinical outcomes were evaluated using a visual analog scale (VAS) for low back and leg pain, Oswestry Disability Index (ODI) for the functional assessment, and modified Macnab criteria for the patient satisfaction (26). Preoperative and postoperative radiological parameters of the scoliosis group including Cobb angle, CVSL-max, and CVSL-C7 were statistically analyzed.

Statistical Analysis

All statistical analyses were performed using SPSS Version 17.0 (SPSS Inc., Chicago, IL). Quantitative data were presented as the mean \pm standard deviation. Analysis of variance (ANOVA) was used to analyze the difference in mean values, and the Fisher's exact test and chi-square test were utilized for categorical



data between the 2 groups and for the comparison between preoperative and postoperative results. The Mann-Whitney U test and paired t-test were applied to compare the preoperative and postoperative VAS, ODI, and radiological parameters. Significant difference was accepted at $P < 0.05$.

RESULTS

Demographic Data

In this retrospective study, a total of 42 patients (female/male: 30/12) were consecutively enrolled with a follow-up period of 39.0 months in average. The general characteristics of the patients are summarized in Table 1. Twenty-eight patients (35.7%) comprised the scoliosis group, and 46 patients (64.3%) comprised the non-scoliosis group. There were 29 cases with L4-L5 disc herniation (scoliosis/non-scoliosis: 12/17) and 13 cases with L5-S1 disc herniation (scoliosis/non-scoliosis: 3/10).

As shown in Table 1, the demographic data of both groups are similar to each other. There were no statistically significant differences in age, gender, mean duration of symptoms, trauma, body mass index (BMI), level of herniated disc, type of herniated disc, nor the mean time of follow-up between the 2 groups ($P > 0.05$).

Clinical Outcomes

All operations were successfully performed. General parameters are summarized in Table 2. The mean operation time was 58.4 ± 9.5 minutes in the scoliosis group and 56.2 ± 10.4 minutes in the non-scoliosis group. The mean length of hospital stay of the scoliosis group was similar to that of the non-scoliosis group (3.5 ± 0.6 days vs. 3.4 ± 0.8 days). No serious complications occurred in either group. Dural tears were noticed in one case (scoliosis: 0; non-scoliosis: 1, 3.7%) during the operation, but no further treatment was required. Transient postoperative dysesthesia occurred in 2 cases (scoliosis: 1, 6.7%, non-scoliosis: 1, 3.7%). Recurrences

Table 1. Demographic data in all patients.

Demographic Data	Scoliosis Group	Non-Scoliosis Group	P-Value
Number of Patients	28 (37.8%)	46 (62.2%)	
Mean Age (yrs)	17.8 ± 3.5	18.1 ± 4.2	> 0.05
Gender (male/female)	20/8	35/11	> 0.05
Mean Duration of Symptoms (mos)	3.1 ± 0.6	3.2 ± 0.7	> 0.05
Trauma	16(57.1%)	28(60.8%)	> 0.05
BMI	27.2 ± 5.8	25.2 ± 4.4	> 0.05
Herniated Level (L4-L5/L5-S1)	21/7	30/15	> 0.05
Herniated Type (protrusion/extrusion/sequestration)	18/7/3	30/11/5	> 0.05
Mean Follow-Up (mos)	36.5 ± 8.2	38.3 ± 7.8	> 0.05

BMI = body mass index

Table 2. General parameters of scoliosis and nonscoliosis group.

General Parameters	Scoliosis	Non-Scoliosis	P-Value
Mean Operative Time	58.4 ± 9.5 min	56.2 ± 10.4 min	> 0.05
Mean Length of Hospital Stay	3.5 ± 0.6 days	3.4 ± 0.8 days	> 0.05
Complications	1 (6.7%)	2 (7.4%)	> 0.05
Recurrences	1 (6.7%)	1 (3.7%)	> 0.05

were detected for one patient (6.7%) in the scoliosis group and for one patient (3.7%) in the non-scoliosis group, with no significant difference ($P > 0.05$). No significant differences were found between both groups with regards to the mean operative time, the mean length of hospital stay, complications, and recurrences ($P > 0.05$).

Preoperative and postoperative VAS scores of back and leg pain and ODI evaluations of both groups are shown in Table 3. The postoperative VAS and ODI scores decreased significantly for both groups. For the scoliosis group, the VAS score of leg and back pain decreased from the preoperative values of 7.1 ± 1.4 and 3.8 ± 1.6 points to 1.5 ± 0.9 and 1.3 ± 0.9 points at the final follow-up, respectively ($P < 0.05$). The mean decreases from preoperative to postoperative were 5.6 ± 1.2 and 2.5 ± 1.3 points for leg and back pain, respectively. The ODI score was $74.5\% \pm 12.3\%$ preoperatively, which declined to $16.5\% \pm 5.0\%$ at the final follow-up with a mean decrease of $58.0\% \pm 9.8\%$ ($P < 0.05$). For the non-scoliosis group, the VAS score of leg and back pain decreased from the preoperative values of 6.9 ± 1.5

and 3.6 ± 1.8 points to 1.3 ± 1.0 and 1.2 ± 1.1 points at the final follow-up, respectively ($P < 0.05$). The mean decreases from preoperative to postoperative were 5.6 ± 1.3 and 2.4 ± 1.4 points for leg and back pain, respectively. The ODI score was $73.6\% \pm 11.5\%$ points preoperatively, which declined to $14.4\% \pm 5.5\%$ points at the final follow-up, with a mean decrease of $59.2\% \pm 9.6\%$ ($P < 0.05$). No significant differences of the preoperative and postoperative VAS and ODI scores were noticed between the 2 groups ($P > 0.05$).

Patient satisfaction is presented in Table 4. According to the modified Macnab criteria, the clinical good-to-excellent rate was 93.3% in the scoliosis group: excellent- 6 (40.0%), good- 8 (53.3.0%), fair- 1 (6.7%), and no poor cases. As a comparison, the good-to-excellent rate for the non-scoliosis group was 92.6%: excellent- 12 (44.4%), good- 13 (48.2%), fair- 1 (3.7%), and poor- 1 (3.7%). No significant difference was found between the 2 groups ($P > 0.05$).

Radiological Outcomes

Preoperative and postoperative radiographic parameters such as Cobb angle, CVSL-max, and CVSL-C7 were measured in the scoliosis group (Table 5). There were significant changes observed in the postoperative sagittal and coronal alignment parameters ($P < 0.05$). A representative case is presented in Fig. 2.

DISCUSSION

LDH is rarely seen in the adolescent population. Trauma and genetic factors are believed to be the most common causes. Sciatic scoliosis shows a greater incidence rate (9–82%) for ALDH patients compared to adult patients (6,10-13). The relationship between scoliotic posture and LDH still remains inexplicit. Kim et al (22) found that women and L4-5 disc herniation patients are highly subject to sciatic scoliosis and trunk list. The goal of the treatment of ALDH is to relieve symptoms and allow an early return-to-routine life. Although a small portion of ALDH patients achieve pain relief after some conservative treatment, the persistent scoliotic posture and trunk shift are still observed (24). Earlier operation helps avoid the persistent nonstructural curve progressing into a structural scoliosis and provides a greater opportunity for the correction of scoliotic posture (24).

Surgical treatments, such as OD, microendoscopy discectomy (MED), and percutaneous endoscopic lumbar discectomy (PELD), for ALDH could achieve appreciable pain relief and function improvement (10,12,21).

Table 3. Clinical outcomes of scoliosis and nonscoliosis groups.

Outcome	Group	Preoperative	Postoperative			
			3 mos	6 mos	1 yr	Final F/U
VAS Leg Pain	Scoliosis	7.1 ± 1.4	1.8 ± 0.8	1.6 ± 0.9	1.5 ± 1.1	1.5 ± 0.9
	Non-scoliosis	6.9 ± 1.5	1.6 ± 0.9	1.5 ± 0.8	1.4 ± 0.9	1.3 ± 1.0
VAS Back Pain	Scoliosis	3.8 ± 1.6	2.1 ± 1.3	1.8 ± 1.1	1.5 ± 0.8	1.3 ± 0.9
	Non-scoliosis	3.6 ± 1.8	2.0 ± 1.2	1.8 ± 0.9	1.4 ± 1.0	1.2 ± 1.1
ODI (%)	Scoliosis	74.5 ± 12.3	24.6 ± 5.2	18.4 ± 4.6	17.1 ± 4.3	16.5 ± 5.0
	Non-scoliosis	73.6 ± 11.5	22.8 ± 6.2	16.7 ± 4.8	14.9 ± 4.6	14.4 ± 5.5

Final F/U = final follow-up. There was no significant difference in the VAS and ODI scores in both groups preoperatively ($P > 0.05$). The VAS and ODI scores improved significantly postoperatively in each group ($P < 0.05$). No significant differences of the VAS and ODI scores could be noticed postoperatively between the 2 groups ($P > 0.05$).

Table 4. Modified Macnab criteria for patients' satisfaction.

	Scoliosis Group	Non-Scoliosis Group
Excellent	6 (40.0%)	12 (44.4%)
Good	8 (53.3%)	13 (48.2%)
Fair	1 (6.7%)	1 (3.7%)
Poor	0	1 (3.7%)

Table 5. Radiological results of the scoliosis group.

Measures	Preoperative	Postoperative		
		3 mos	6 mos	Final F/U
Cobb angle	18.4 ± 4.6	8.7 ± 2.4	5.4 ± 2.3	2.1 ± 0.8
CVSL-max	3.6 ± 1.2	1.6 ± 0.8	1.2 ± 0.5	0.6 ± 0.4
CVSL-C7	2.4 ± 0.8	1.2 ± 0.6	0.8 ± 0.4	0.5 ± 0.3

Final F/U = final follow-up

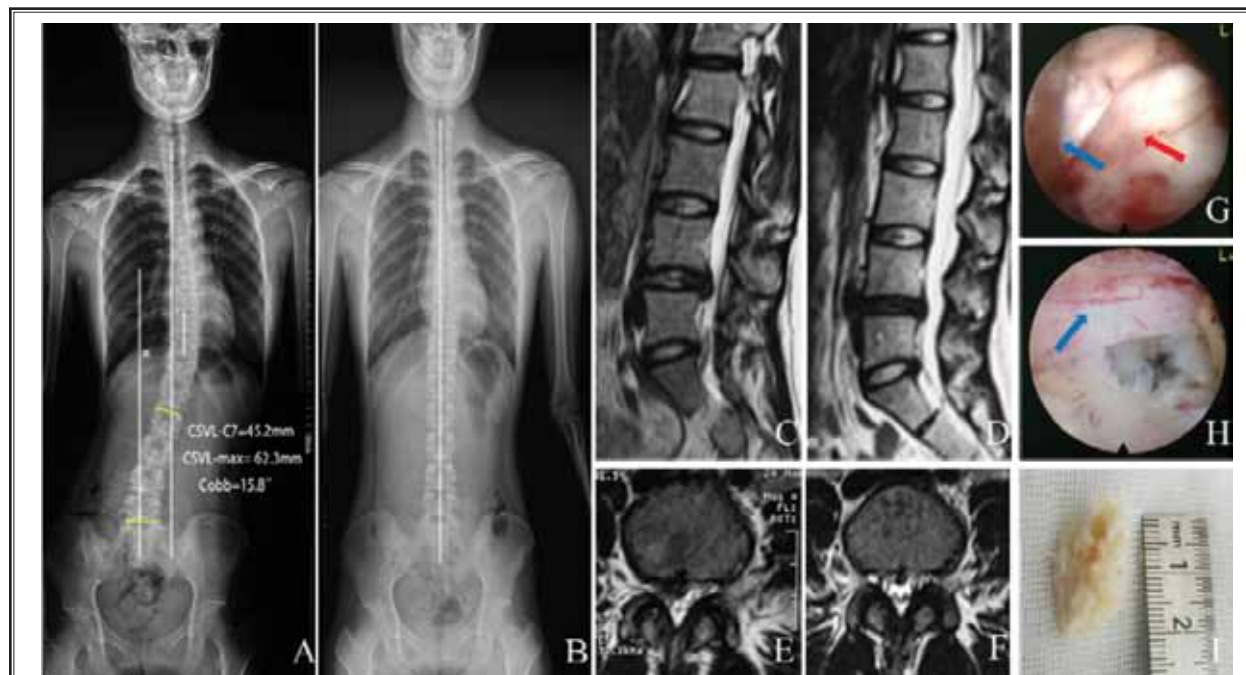


Fig. 2. An illustrative case is presented. A 17-year-old girl presented with low back and right leg pain and trunk shift for 3 months. Conservative treatments were ineffective. (A): x-ray showed scoliosis with a Cobb angle 15.8°; (C,E): lumbar disc herniation at L4/5 was found in MRI. FEID was performed after admission. (G): the nerve (blue arrow) was compressed by herniated nucleus pulposus (red arrow); (H): complete decompression of the nerve root is presented; (I): excised nucleus pulposus is shown; (B): postoperative x-ray showed that scoliosis was spontaneously corrected at 3 months; (D,F): at the final follow-up, MRI showed complete decompression of the L5 nerve root was achieved.

However, problems still arise due to the trauma of open surgery such as residual low back pain, iatrogenic instability, and epidural scarring (27). It is crucial to remove the appropriate amount of bone and ligament during the OD in order to access the disc while preserving the spinal stability (14). Compared to the traditional OD and MED treatments, PELD is capable of reducing intraoperative bleeding, postoperative drainage, and postoperative hospital stay, as well as the time spent in bed, thereby allowing earlier return to work (16,27-29). Full-endoscopic lumbar discectomy has been widely adopted since the first introduction by Ruetten et al (25). It has unique advantages of minimizing trauma to the normal spinal structures, such as the ligament flavum, muscle, lamina, and facet joint, and preventing iatrogenic instability, as well as the formation of epidural scar tissue (17,19). Studies have proven the epidural scar to be related to postoperative back pain, and it also increases the risk of dural sac and nerve injuries in the revision surgery (17,19).

FEID has been recommended to be a safe and effective treatment for ALDH and therefore, it is considered as the first option to treat ALDH (21). In this study, FEID was performed in all cases. VAS and ODI scores decreased significantly, and the overall good-to-excellent rate was 92.9%, which is similar to previous reports (10,12,21). Notably, no significant difference was observed between the scoliosis and non-scoliosis group. The existence of scoliosis does not affect the clinical outcome, consistent with a previous study that shows a weak correlation between the amount of trunk list and the low back pain/disability index (30).

Complications following PELD have been reported 4.0% in ALDH (12), while the whole incident rate is 7.1% in this study. Dual tears and transient dysesthesia are the most common complications that have been reported. The incident rate of dural tears varies from 0.4% to 10.4% (15-20), which is comparable to the value obtained during this study. Dural tears generally result from the lack of a 3-dimensional view of the operative field (31). Ruetten et al (27) reported a 3.8% incidence rate of transient dysesthesia after FEID for LDH, which may be related to the inevitable intraoperative retraction of nerves in the small operating space.

Recurrence of LDH has been found to be high for men, cigarette smokers, and patients who have traumatic events, "incompetent" annulus fibrosus, high BMI, diabetes, and occupational heavy weight lifting as summarized (23). Besides, the herniated level and

type may affect the recurrence (32). In fact, the etiology of recurrence after successful discectomy remains unclear. Surgically undesired disc fragment remnants and incomplete decompression by piecemeal removal may lead to a higher early recurrence (33). On the contrary, minimized size of annular defect using the annular sealing technique may help decrease the recurrent rate (34). As noted, the recurrence rate of FEID was 3.3–5.7% for adults (25,35,36), while no recurrence was reported in a 19.7 month follow-up for ALDH (21). In the present study, the overall recurrent rate was 4.8%.

The effect of sciatic scoliosis with regards to the risk of LDH recurrence following FEID has not been identified. Previous studies suggest that scoliosis may increase the risk of recurrence of LDH after MED (23). In this study, recurrences were detected in one case (6.7%) in the scoliosis group and 2 cases (3.7%) in the non-scoliosis group, with no significant difference ($P > 0.05$). It is seemed to be in contrary to the previous study by Chang et al (23). However, they did not clarify the type of scoliosis and ignored the herniated level and type in the baseline data. In addition, sciatic scoliosis is non-structural and its effects on lumbar biomechanics are limited. Similar to our radiological results, this reactive scoliosis would usually ameliorate once the herniation is resolved (6,7).

In a previous study, after OD, sciatic scoliosis completely disappeared for 45% (18/40) of the patients by a mean time interval of 7.5 months (6) and for 69% (31/45) of the patients by 7 days in average (7). Similarly, trunk list was reversible for more than 50% of patients within 6 months after PELD (22). However, previous studies involved a wide age-ranged population including children and adults, and some cases had a Cobb angle less than 10°. In terms of a Cobb angle more than 10°, Zhu (24) reported that the mean Cobb angle of the lumbosacral curve was 19.5° at presentation, but decreased to 8.5° immediately after surgery, and 2 patients still had a residual lumbosacral curve greater than 20°. Therefore, earlier discectomy and adjunct postsurgical conservative measures can provide a greater opportunity for correction and stabilization of scoliotic posture (24). The true prognosis of sciatic scoliosis in ALDH after FEID has not been investigated. In the present study, the criteria of scoliosis include the Cobb's angle $\geq 10^\circ$. All of the patients have a curve improvement postoperatively. The initial Cobb angle is 18.4° in average, and it decreases to 8.7° at 3 months postoperatively and to 2.1° at the final follow-up.

Several limitations exist in this study. Firstly, this study is a retrospective design and the size of the cases was relatively small. Secondly, it was a short-term follow-up, and a long-term follow-up may be preferred. However, satisfied outcomes have been achieved and no significant effect of sciatic scoliosis on complications, recurrences, and clinical outcome measures have been found.

CONCLUSION

The application of FEID in the treatment of ALDH successfully achieved satisfactory clinical and radiological outcomes. Low back and leg pain were relieved, and functional disability was improved. Additionally, sciatic scoliosis was corrected spontaneously without increasing the risk of complication and recurrence. FEID offers an alternative for treating ALDH with sciatic scoliosis.

REFERENCES

- Bradbury N, Wilson LF, Mulholland RC. Adolescent disc protrusions. A long-term follow-up of surgery compared to chymopapain. *Spine (Phila Pa 1976)* 1996; 21:372-377.
- Lee JY, Ernestus RI, Schröder R, Klug N. Histological study of lumbar intervertebral disc herniation in adolescents. *Acta Neurochir (Wien)* 2000; 142:1107-1110.
- Kumar R, Kumar V, Das NK, Behari S, Mahapatra AK. Adolescent lumbar disc disease: Findings and outcome. *Childs Nerv Syst* 2007; 23:1295-1299.
- Papagelopoulos PJ, Shaughnessy WJ, Ebersold MJ, Bianco AJ Jr, Quast LM. Long-term outcome of lumbar discectomy in children and adolescents sixteen years of age or younger. *J Bone Joint Surg Am* 1998; 80:689-698.
- Battié MC, Videman T. Lumbar disc degeneration: Epidemiology and genetics. *J Bone Joint Surg Am* 2006; 88:3-9.
- Matsui H, Ohmori K, Kanamori M, Ishihara H, Tsuji H. Significance of sciatic scoliotic list in operated patients with lumbar disc herniation. *Spine (Phila Pa 1976)* 1998; 23:338-342.
- Suk KS, Lee HM, Moon SH, Kim NH. Lumbosacral scoliotic list by lumbar disc herniation. *Spine (Phila Pa 1976)* 2001; 26:667-671.
- Pinto FC, Poetscher AW, Quinhones FR, Pena M, Taricco MA. Lumbar disc herniation associated with scoliosis in a 15-year-old girl: Case report. *Arq Neuropsiquiatr* 2002; 60:295-298.
- Kim HJ, Green DW. Adolescent back pain. *Curr Opin Pediatr* 2008; 20(1):37-45.
- Xu DR, Song YD, Wang H, Li SG. [Meta-analysis of lumbar disc herniation in Chinese adolescents]. *Zhonghua Yi Xue Za Zhi* 2013; 93:3606-3609.
- Ozgen S, Konya D, Toktas OZ, Dalgıncı A, Ozek MM. Lumbar disc herniation in adolescence. *Pediatr Neurosurg* 2007; 43:77-81.
- Wang H, Cheng J, Xiao H, Li C, Zhou Y. Adolescent lumbar disc herniation: Experience from a large minimally invasive treatment centre for lumbar degenerative disease in Chongqing, China. *Clin Neurol Neurosurg* 2013; 115:1415-1419.
- Cahill KS, Dunn I, Gunnarsson T, Proctor MR. Lumbar microdiscectomy in pediatric patients: A large single-institution series. *J Neurosurg Spine* 2010; 12:165-170.
- Lavelle WF, Bianco A, Mason R, Betz RR, Albanese SA. Pediatric disk herniation. *J Am Acad Orthop Surg* 2011; 19:649-656.
- Sencer A, Yorukoglu AG, Akcakaya MO, Aras Y, Aydoseli A, Boyali O, Sencan F, Sabancı PA, Gımlıksız C, İmer M, Kırıs T, Hepgul K, Unal OF, İzgi N, Canbolat AT. Fully endoscopic interlaminar and transforaminal lumbar discectomy: Short-term clinical results of 163 surgically treated patients. *World Neurosurg* 2014; 82:884-890.
- Wang B, Lü GH, Li J, Kang YJ, Deng YW, Liu WD, Hu JR, Li L, Chen F, Chen WH, Kuang L, Wang XB. [Contrast study of full-endoscopic interlaminar approach for the surgical treatment of lumbar disc herniation]. *Zhonghua Wai Ke Za Zhi* 2011; 49:74-78.
- Ruetten S, Komp M, Merk H, Godolias G. Recurrent lumbar disc herniation after conventional discectomy: A prospective, randomized study comparing full-endoscopic interlaminar and transforaminal versus microsurgical revision. *J Spinal Disord Tech* 2009; 22:122-129.
- Ruetten S, Komp M, Merk H, Godolias G. Use of newly developed instruments and endoscopes: Full-endoscopic resection of lumbar disc herniations via the interlaminar and lateral transforaminal approach. *J Neurosurg Spine* 2007; 6:521-530.
- Choi G, Lee SH, Raiturker PP, Lee S, Chae YS. Percutaneous endoscopic interlaminar discectomy for intracanalicular disc herniations at L5-S1 using a rigid working channel endoscope. *Neurosurgery* 2006; 58:ONS59-ONS68.
- Tu Z, Li YW, Wang B, Lu G, Li L, Kuang L, Dai Y. Clinical outcome of full-endoscopic interlaminar discectomy for single-level lumbar disc herniation: A minimum of 5-year follow-up. *Pain Physician* 2017; 20:E425-E430.
- Wang X, Zeng J, Nie H, Chen G, Li Z, Ji-ang H, Kong Q, Song Y, Liu H. Percutaneous endoscopic interlaminar discectomy for pediatric lumbar disc herniation. *Childs Nerv Syst* 2014; 30:897-902.
- Kim R, Kim RH, Kim CH, Choi Y, Hong HS, Park SB, Yang SH, Kim SM, Chung CK. The incidence and risk factors for lumbar or sciatic scoliosis in lumbar disc herniation and the outcomes after percutaneous endoscopic discectomy. *Pain Physician* 2015; 18:555-564.
- Chang HK, Chang HC, Wu JC, Tu TH, Fay LY, Chang PY, Wu CL, Huang WC, Cheng H. Scoliosis may increase the risk of recurrence of lumbar disc herniation after microdiscectomy. *J Neurosurg Spine* 2016; 24:586-591.
- Zhu Z, Zhao Q, Wang B, Yu Y, Qian B, Ding Y, Qiu Y. Scoliotic posture as the initial symptom in adolescents with lumbar disc herniation: Its curve pattern and natural history after lumbar discectomy. *BMC Musculoskelet Disord* 2011; 12:216.
- Ruetten S, Komp M, Godolias G. A new full-endoscopic technique for the in-

- terlaminar operation of lumbar disc herniations using 6-mm endoscopes: Prospective 2-year results of 331 patients. *Minim Invasive Neurosurg* 2006; 49:80-87.
26. Macnab I. Negative disc exploration. An analysis of the causes of nerve-root involvement in sixty-eight patients. *J Bone Joint Surg Am* 1971; 53:891-903.
 27. Ruetten S, Komp M, Merk H, Godolias G. Full-endoscopic interlaminar and transforaminal lumbar discectomy versus conventional microsurgical technique: A prospective, randomized, controlled study. *Spine (Phila Pa 1976)* 2008; 33:931-939.
 28. Li M, Yang H, Yang Q. Full-endoscopic technique discectomy versus microendoscopic discectomy for the surgical treatment of lumbar disc herniation. *Pain Physician* 2015; 18:359-363.
 29. Birkenmaier C, Komp M, Leu HF, Wegener B, Ruetten S. The current state of endoscopic disc surgery: Review of controlled studies comparing full-endoscopic procedures for disc herniations to standard procedures. *Pain Physician* 2013; 16:335-344.
 30. Gillan MG, Ross JC, McLean IP, Porter RW. The natural history of trunk list, its associated disability and the influence of McKenzie management. *Eur Spine J* 1998; 7:480-483.
 31. Casal-Moro R, Castro-Menéndez M, Hernández-Blanco M, Bravo-Ricoy JA, Jorge-Barreiro FJ. Long-term outcome after microendoscopic discectomy for lumbar disk herniation: A prospective clinical study with a 5-year follow-up. *Neurosurgery* 2011; 68:1568-1575.
 32. Dewing CB, Provencher MT, Riffenburgh RH, Kerr S, Manos RE. The outcomes of lumbar microdiscectomy in a young, active population: Correlation by herniation type and level. *Spine (Phila Pa 1976)* 2008; 33:33-38.
 33. Choi KC, Lee JH, Kim JS, Sabal LA, Lee S, Kim H, Lee SH. Unsuccessful percutaneous endoscopic lumbar discectomy: A single-center experience of 10,228 cases. *Neurosurgery* 2015; 76:372-380; discussion 380-381.
 34. Kim HS, Park JY. Comparative assessment of different percutaneous endoscopic interlaminar lumbar discectomy (PEID) techniques. *Pain Physician* 2013; 16:359-367.
 35. Ruetten S, Komp M, Merk H, Godolias G. Use of newly developed instruments and endoscopes: Full-endoscopic resection of lumbar disc herniations via the interlaminar and lateral transforaminal approach. *J Neurosurg Spine* 2007; 6:521-530.
 36. Chumnanvej S, Kesornsak W, Sarnvivad P, Paiboonsirijit S, Kuansongthum V. Full endoscopic lumbar discectomy via interlaminar approach: 2-year results in Ramathibodi Hospital. *J Med Assoc Thai* 2011; 94:1465-1470.