

Prospective Observational Study

Outcome of Transforaminal Epidural Steroid Injection According to the Severity of Lumbar Foraminal Spinal Stenosis

Min Cheol Chang, MD and Dong Gyu Lee, MD

From: Department of Physical Medicine and Rehabilitation, College of Medicine, Yeungnam University, Taegu, Republic of Korea

Address Correspondence: Min Cheol Chang, MD
Department of Physical Medicine and Rehabilitation
College of Medicine
Yeungnam University 317-1, Daemyungdong, Namku
Taegu, 705-717, Republic of Korea
E-mail: wheel633@ynu.ac.kr

Disclaimer: There was no external funding in the preparation of this manuscript.
Conflict of interest: Each author certifies that he or she, or a member of his or her immediate family, has no commercial association (i.e., consultancies, stock ownership, equity interest, patent/licensing arrangements, etc.) that might pose a conflict of interest in connection with the submitted manuscript.

Manuscript received: 06-03-2017
Revised manuscript received: 07-03-2017
Accepted for publication: 07-14-2017

Free full manuscript:
www.painphysicianjournal.com

Background: Lumbar foraminal spinal stenosis (LFSS) is a common cause of radicular pain in the lower extremities. Transforaminal epidural steroid injection (TFESI) is being used widely for controlling radicular pain induced by LFSS. The efficacy of TFESI has been demonstrated in previous studies. However, no study has evaluated the outcome of TFESI according to the severity of LFSS.

Objective: In this study, we evaluated the outcome of TFESI in patients with chronic lumbar radicular pain due to LFSS according to the severity of LFSS by using magnetic resonance imaging (MRI).

Study Design: A prospective observational study.

Setting: A university hospital.

Methods: Sixty patients with chronic lumbar radicular pain due to LFSS were included in this prospective study and received TFESI at our university hospital. Three patients were lost to follow-up. On the basis of sagittal lumbar MRI findings, we assigned patients with mild to moderate LFSS to group A ($n = 31$) and those with severe LFSS to group B ($n = 26$). Pain intensity was evaluated using a numeric rating scale (NRS) before treatment and at 1, 2, and 3 months after treatment.

Results: Compared to pretreatment NRS scores, a significant decrease in NRS scores was observed in patients in both groups at 1, 2, and 3 months after treatment ($P = 0.000$). However, reductions in the NRS scores over time were significantly larger in group A ($P = 0.023$). Three months after treatment, 27 patients (87.1%) in group A and 11 patients (42.3%) in group B reported successful pain relief (pain relief of $\geq 50\%$).

Limitations: This study had a small number of patients.

Conclusions: After TFESI, chronic lumbar radicular pain was significantly reduced regardless of the severity of LFSS, and the effects of TFESI were sustained for at least 3 months after treatment. However, the outcome of TFESI was superior in the group with a mild to moderate degree of LFSS, compared to the group with a severe degree of LFSS. We believe that our study provides useful information for establishing a treatment plan for radicular pain due to LFSS.

Key words: Lumbar foraminal spinal stenosis, transforaminal epidural steroid injection, disease severity, magnetic resonance imaging, numeric rating scale, corticosteroids

Pain Physician 2018; 21:67-72

Lumbar foraminal spinal stenosis (LFSS) is a common cause of radicular pain in the lower extremities. Its incidence has been reported to be 8–11% (1-3). LFSS is a disorder marked by narrowing of the bony exit

of a nerve root, which causes mechanical compression of nerve roots. This compression is associated with loss of intervertebral disc height with or without bulging of the intervertebral disc, hypertrophy of the facet

joints, and buckling of the ligamentum flavum (4). The compression of the nerve root produces venous engorgement and arterial insufficiency of radicular blood supply, which can lead to nerve root injury via an ischemic neuritis (5). Moreover, the impingement of the nerve root causes an inflammatory response, in which multiple biochemical mediators, including lactate, phospholipase A2, cytokines, nitric oxide, proteoglycans, and immune response cells, are implicated and cause radicular pain in patients with LFSS (5).

For the management of radicular pain, various conservative treatments have been applied for patients with LFSS. Transforaminal epidural steroid injection (TFESI) is one of the most effective methods for controlling radicular pain after LFSS and has been increasingly used lately (6-12). Corticosteroids inhibit the synthesis of various pro-inflammatory mediators (13). Therefore, TFESI can reduce nerve root inflammation induced by mechanical compression at the narrowed foramen. Several previous studies demonstrated the effectiveness of TFESI on reducing radicular pain after LFSS (6-12). However, little is known about the treatment outcome of TFESI according to the severity of LFSS.

In the current study, we evaluated the treatment outcome of TFESI in patients with chronic lumbar radicular pain due to LFSS according to the severity of LFSS by using magnetic resonance imaging (MRI).

METHODS

Patients

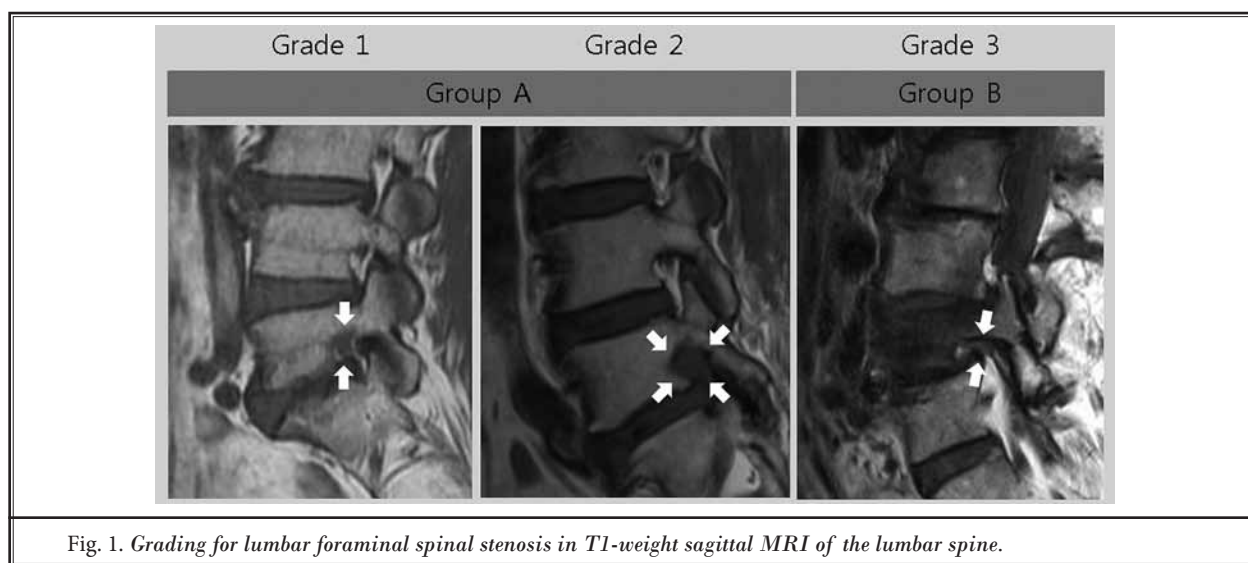
From January 2015 to February 2017, we prospectively evaluated 60 consecutive patients who had lumbar radicular pain due to LFSS according to the following inclusion criteria: (1) age 20–79 years old; (2) presentation with \geq 3-month history of symptomatic lumbar radicular pain of at least 4 on the numeric rating scale (NRS; 0 = no pain, 10 = the worst pain), despite oral medications (meloxicam and tramadol/acetaminophen); (3) MRI findings of a LFSS pathology compatible with pain symptoms; and (4) \geq 50% temporary pain relief following a diagnostic nerve block with 1 mL of 2% lidocaine: the diagnostic block was performed only for diagnostic purposes, not for therapeutic purposes. Exclusion criteria were as follows: (1) the presence of lateral recess or central stenosis, herniation of the lumbar disc, spondylolisthesis, myelopathy, or infection on the spine; (2) previous history of spinal surgery, such as lumbar fusion or laminectomy; (3) bilateral symptoms or involvement of more than one segment; and (4)

coagulation disorder. The institutional review board of our hospital approved the study and all patients provided a signed informed consent form.

The severity of LFSS was assessed based on the findings of lumbar sagittal MRI according to Lee et al's study (14) (Fig. 1). Grade 0 refers to the absence of foraminal stenosis. Grade 1 indicates mild foraminal stenosis showing perineural fat obliteration surrounding the nerve root in the 2 opposing directions (vertical or transverse); it involves contact with the superior and inferior portions of the nerve root or anterior and posterior portions of the nerve root without morphologic change of the nerve root. Grade 2 refers to moderate foraminal stenosis showing perineural fat obliteration surrounding the nerve root in the 4 directions without morphologic change in both vertical and transverse directions. Grade 3 is severe foraminal stenosis showing nerve root collapse or morphologic change. Out of 60 patients, 18, 15, and 27 patients were classified as grades 1, 2, and 3, respectively. We reclassified grade 1 and 2 as group A, in which the degree of foraminal stenosis was mild to moderate. Grade 3 was reclassified as group B, in which the degree of foraminal stenosis was severe. Therefore, 33 patients were in group A, and 27 patients were in group B.

TFESI Procedures

All injections were performed by a single interventional physiatrist who specializes in spinal injections. Strict aseptic technique was utilized in the performance of the TFESI procedures. Patients were placed prone and C-arm fluoroscopy (Siemens, Erlangen, Germany) was utilized for level identification and needle guidance. Lidocaine 1% was administered at the needle insertion site, and the tip of a 25-gauge, 90 mm spinal needle with a bend at the tip to allow for guidance was positioned between the lateral vertebral body and the 6 o'clock position below the pedicle. Lateral fluoroscopic imaging demonstrated the needle-tip between the spinal lamina margin and the posterior vertebral body. Under anterior-posterior (AP) fluoroscopy, 0.3 mL of non-ionic contrast material was injected to confirm the absence of vascular uptake and spread of contrast into the foramen. Then, the further injection of contrast medium was performed under real-time fluoroscopic monitoring (Fig. 2). Subsequently, 20 mg (40 mg/mL) of triamcinolone with 0.5 mL of bupivacaine hydrochloride was injected. After the TFESI, physical therapy or manual therapy was not performed in all of the recruited patients.



Outcome Measures

The assessments at pretreatment and follow-up periods were performed by one investigator; this investigator was blinded to the group allocation and did not participate in any treatments. Pain intensity was assessed using a NRS. The NRS scores were measured before treatment and at 1, 2, and 3 months after TFESI. Successful treatment was defined as more than 50% reduction in the NRS score at 3 months when compared to the pre-treatment NRS score. To validate the change in pain reduction, NRS scores were evaluated by assessing the difference between the pretreatment NRS scores and the 3-month post-treatment scores (change in NRS [%] = [pretreatment score - score at 3 months after treatment]/pretreatment score \times 100).

After 3 months, the patient global perceived effect was assessed using a 7-point Likert scale (Table 1) (15,16). Patients reporting very good (score = 7) or good (score = 6) results were considered to be satisfied with the procedure.

Statistical Analysis

Data were analyzed using SPSS Version 22.0 (IBM Corporation, Armonk, NY). Demographic data and successful pain relief rate were compared between the 2 groups using the Mann-Whitney U test and chi-square test. The changes in NRS scores in groups A and B were evaluated using repeated measure one-factor analysis. Repeated measure 2-factor analysis was used to compare changes between groups over time. Multiple comparisons were obtained following a contrast using

the Bonferroni correction. The level of statistical significance was set at $P < 0.05$.

RESULTS

Two patients in group A and one patient in group B were lost to follow-up. Accordingly, 31 patients in group A and 26 patients in group B were followed for 3 months after TFESI. No adverse events were observed in either group. No significant intergroup differences were observed for demographic data ($P > 0.05$) (Table 2).

In group A, the mean NRS decreased after treatment. The pretreatment NRS was 5.0 ± 1.0 . At one month, the mean NRS was 1.7 ± 1.1 , at 2 months, 1.7 ± 1.1 , and at 3 months, 1.7 ± 1.0 (Fig. 3). In group B, the mean NRS decreased from 5.4 ± 1.2 before treatment to 2.9 ± 1.8 at one month, 3.0 ± 1.8 at 2 months, and 3.1 ± 1.7 at 3 months after treatment (Fig. 3).

The NRS scores for each group were significantly different over time ($P = 0.000$) (Fig. 3). In both groups, NRS scores at 1, 2, and 3 months were significantly decreased when compared to pretreatment NRS scores ($P = 0.000$). Reductions in the NRS scores over time were significantly larger in group A ($P = 0.023$). In addition, the scores from pretreatment to each evaluation time-point were significantly more reduced in group A compared to group B (1 month: $P = 0.044$, 2 months: $P = 0.021$, 3 months: $P = 0.017$). Three months after treatment, 27 patients (87.1%) in group A and 11 patients (42.3%) in group B reported successful pain relief (pain relief of $\geq 50\%$). The rates of successful pain relief at

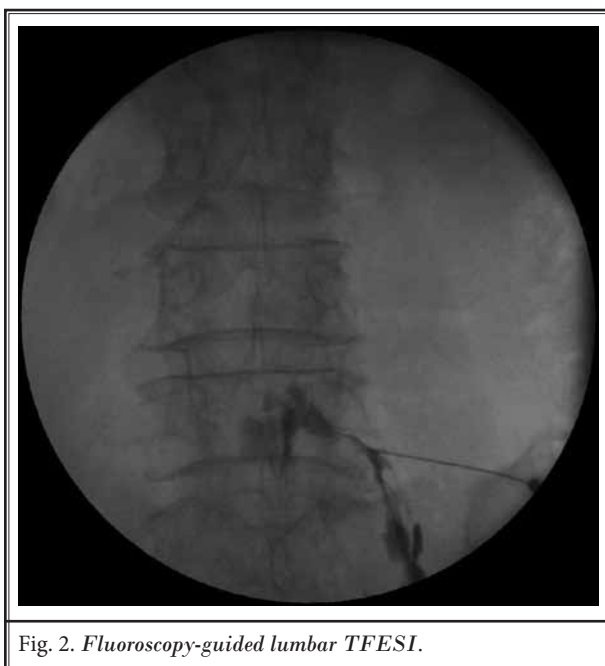


Fig. 2. Fluoroscopy-guided lumbar TFESI.

Table 1. Global perceived effect according to a Likert scale.

Score	% Change	Description
7	≥ 75 improvement	Very good
6	50–74 improvement	Good
5	25–49 improvement	Fairly good
4	0–24 improvement or worse	Same as before
3	25–49 worse	Fairly bad
2	50–74 worse	Bad
1	≥ 75 worse	Very bad

3 months after treatment were significantly different between the 2 groups ($P = 0.000$).

On the 7-point Likert scale, very good results (score = 7) were seen in 12 patients (38.7%) in group A. Good (score = 6) and fairly good (score = 5) results were observed in 15 (48.4%) and 2 patients (6.5%), respectively. However, no change in results (score = 4) was observed in 2 patients (6.5%). Accordingly, 27 patients (87.1%) of the patients in group A were satisfied with the results 3 months after TFESI. Fairly bad (score = 3), bad (score = 2), and very bad (score = 1) results were not reported after TFESI. In group B, very good and good results were observed in 5 (19.2%) and 6 (23.1%) patients, respectively. Fairly good and no change in results were observed in 9 (34.6%) and 6 (23.1%) patients, respectively. Fairly bad, bad, and very bad results were not reported after TFESI. Therefore, 11 patients (42.3% of

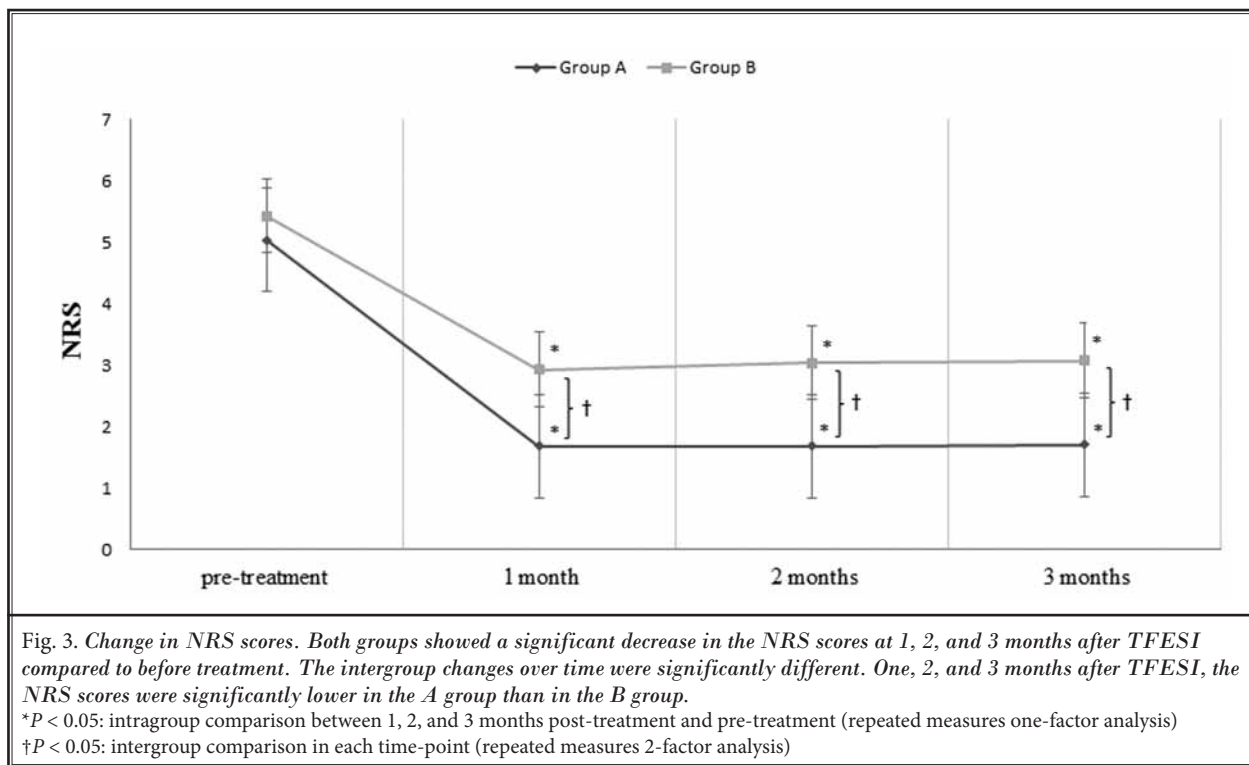
the patients in group B) were satisfied with the results 3 months after TFESI. The rates of patient satisfaction were significantly higher in group A, compared to group B ($P = 0.000$).

DISCUSSION

In the current study, we evaluated the effects of TFESI in patients with chronic radicular pain due to LFSS according to the severity of the foraminal stenosis. Our results showed that the severity of pain, which was measured using the NRS score, was significantly reduced after TFESI in both groups regardless of the severity of foraminal stenosis. However, the reduction in the NRS scores was greater in patients with mild to moderate LFSS compared to patients with severe LFSS at 1, 2, and 3 months after the TFESI. Furthermore, the rate of successful pain relief (more than 50% reduction of the pain at 3 months after TFESI) after TFESI was 87.1% in patients with mild to moderate LFSS, but that in patients with LFSS with the severe degree was 42.3%, which was significantly lesser compared to that in patients with severe LFSS. Moreover, the rates of patient satisfaction were significantly higher in patients with mild to moderate LFSS than in patients with severe LFSS. Our results indicate that TFESI can effectively control the radicular pain in patients with mild to moderate LFSS, but has less effect on severe LFSS.

Regarding the efficacy of TFESI, the main purpose of steroid injection is reducing production and release of inflammation-related mediators. The compression of the nerve root induces various cytokines and inflammation-mediated cells, which is one of the causes responsible for the radicular pain after LFSS (5). The anti-inflammatory properties of steroids reduce inflammation-related mediators, consequently inhibiting the processes leading to the occurrence of radicular pain (17,18). Furthermore, decreased inflammation can reduce the edema on the nerve root or tissues around the nerve root resulting from inflammation. Reduction of the edema can make a space between the bony exit and the nerve root, which can reduce the degree of compression of the nerve root, venous engorgement, and arterial insufficiency (5). In addition, corticosteroids inhibit neural transmission within the nociceptive C-fibers (19,20), in addition to having an anti-inflammatory effect. By these actions of corticosteroids, our patients' pain was reduced after TFESI.

As for the different effect of TFESI following the severity of LFSS, patients with severe LFSS have nerve root impingement in the outlet of the lumbar foramen,



which was shown as morphologic changes of nerve root on the lumbar MRI (14). If this condition persists, it can lead to continuous mechanical stimulation of the nociceptive nerves and repeated occurrence of inflammation in the nerve root. Thus, although patients with LFSS without impingement of the nerve root (i.e., mild to moderate degree) showed excellent outcome after TFESI, LFSS with severe degree showed poorer response compared to LFSS with mild to moderate degree.

Several studies demonstrated the positive effects of TFESI for managing radicular pain due to spinal stenosis (6,12). Limited to LFSS, to date, 2 studies evaluated the effect of TFESI in patients with LFSS (9,10). In 2013, Park et al (9) recruited 40 patients with LFSS and evaluated the relationship between injectate pressure and short-term effect of TFESI. The degree of pain relief after TFESI was not correlated with injectate pressure, and radicular pain was reduced in 27 patients (67.5%) at 2 weeks after the procedure. In 2015, Park et al (10) compared the efficacy of TFESI in patients with chronic radicular pain following LFSS with that of percutaneous adhesiolysis (PA). They retrospectively recruited 30 patients who received TFESI and 15 patients who received PA. At 3 months after PA and TFESI, 73.3% and 43.3% of patients showed more than 50% reduction of

Table 2. Demographic characteristics of patients in groups A and B.

	Group A	Group B	P-Value
Number (n)	31	26	
Age (yrs)	66.0 ± 7.8	69.0 ± 6.3	0.138
Male:Female	12:19	10:16	0.985
NRS (pre-treatment)	5.0 ± 1.0	5.4 ± 1.2	0.193
Pain Duration (months)	19.0 ± 23.4	14.9 ± 23.2	0.474
Site of Pain (right/left)	17/14	10/16	
Injection Level (L3/L4/L5)	1/10/20	6/20	

Values are presented as numbers or means ± standard deviations. NRS = numeric rating scale

pain, respectively. However, in these previous studies, the authors did not describe the severity of LFSS of the recruited patients. Also, they did not evaluate the outcome of TFESI according to the severity of LFSS.

CONCLUSION

We found that TFESI can significantly relieve chronic lumbar radicular pain in patients regardless of the severity of LFSS. The effects of TFESI persisted for at least 3 months after treatment. However, the effect of TFESI was superior in the group with mild to

moderate degree of LFSS, compared to the group with severe degree of LFSS. Moreover, successful pain relief and patient satisfaction at 3 months were higher in the group with mild to moderate LFSS. This is the first study to evaluate the effects of TFESI for managing lumbar radicular pain due to LFSS according to the severity of LFSS. We believe that our study can give clinicians

useful information for establishing a treatment plan for radicular pain induced by LFSS. However, this study has some limitations. First, we recruited a small number of patients. Second, we did not evaluate the long-term effects of TFESI. Third, the measurement of functional status was not performed. Therefore, further studies addressing these limitations are necessary.

REFERENCES

- Jenis LG, An HS. Spine update: Lumbar foraminal stenosis. *Spine (Phila Pa 1976)* 2000; 25:389-394.
- Kunogi J, Hasue M. Diagnosis and operative treatment of intraforaminal and extraforaminal nerve root compression. *Spine (Phila Pa 1976)* 1991; 16:1312-1320.
- Porter RW, Hibbert C, Evans C. The natural history of root entrapment syndrome. *Spine (Phila Pa 1976)* 1984; 9:418-421.
- Hasegawa T, An HS, Haughton VM, Nowicki BH. Lumbar foraminal stenosis: Critical heights of the intervertebral discs and foramina. A cryomicrotome study in cadavera. *J Bone Joint Surg Am* 1995; 77:32-38.
- Akuthota V, Lento P, Soxa G. Pathogenesis of lumbar spinal stenosis pain: Why does an asymptomatic stenotic patient flare? *Phys Med Rehabil Clin N Am* 2003; 14:17-28, v.
- Davis N, Hourigan P, Clarke A. Transforaminal epidural steroid injection in lumbar spinal stenosis: An observational study with two-year follow-up. *Br J Neurosurg* 2017; 31:205-208.
- Kim HJ, Yeom JS, Lee JW, Chang BS, Lee CK, Lee GW, Im SB, Kim HJ. The influence of pain sensitivity on the treatment outcome of transforaminal epidural steroid injection in patients with lumbar spinal stenosis. *Pain Pract* 2014; 14:405-412.
- Ohtori S, Miyagi M, Eguchi Y, Inoue G, Orita S, Ochiai N, Kishida S, Kuniyoshi K, Nakamura J, Aoki Y, Ishikawa T, Arai G, Kamoda H, Suzuki M, Takaso M, Furuya T, Toyone T, Takahashi K. Epidural administration of spinal nerves with the tumor necrosis factor-alpha inhibitor, etanercept, compared with dexamethasone for treatment of sciatica in patients with lumbar spinal stenosis: A prospective randomized study. *Spine (Phila Pa 1976)* 2012; 37:439-444.
- Park CH, Lee SH. Effect of relative injectate pressures on the efficacy of lumbar transforaminal epidural steroid injection in patients with lumbar foraminal stenosis. *Pain Pract* 2014; 14:223-227.
- Park Y, Lee WY, Ahn JK, Nam HS, Lee KH. Percutaneous adhesiolysis versus transforaminal epidural steroid injection for the treatment of chronic radicular pain caused by lumbar foraminal spinal stenosis: A retrospective comparative study. *Ann Rehabil Med* 2015; 39:941-949.
- Ploumis A, Christodoulou P, Wood KB, Varvarousis D, Sarni JL, Beris A. Caudal vs transforaminal epidural steroid injections as short-term (6 months) pain relief in lumbar spinal stenosis patients with sciatica. *Pain Med* 2014; 15:379-385.
- Smith CC, Booker T, Schaufele MK, Weiss P. Interlaminar versus transforaminal epidural steroid injections for the treatment of symptomatic lumbar spinal stenosis. *Pain Med* 2010; 11:1511-1515.
- Lee DG, Ahn SH, Lee J. Comparative effectiveness of pulsed radiofrequency and transforaminal steroid injection for radicular pain due to disc herniation: A prospective randomized trial. *J Korean Med Sci* 2016; 31:1324-1330.
- Lee S, Lee JW, Yeom JS, Kim KJ, Kim HJ, Chung SK, Kang HS. A practical MRI grading system for lumbar foraminal stenosis. *AJR Am J Roentgenol* 2010; 194:1095-1098.
- Likert R. A technique for the measurement of attitudes. *Arch Psychol* 1932; 140:5-55.
- Farrar JT, Young JP Jr., LaMoreaux L, Werth JL, Poole RM. Clinical importance of changes in chronic pain intensity measured on an 11-point numerical scale. *Pain* 2001; 94:149-158.
- Greaves MW. Anti-inflammatory action of corticosteroids. *Postgrad Med J* 1976; 52:631-633.
- Narouze SN, Vydyanathan A, Kapural L, Sessler DI, Mekhail N. Ultrasound-guided cervical selective nerve root block: A fluoroscopy-controlled feasibility study. *Reg Anesth Pain Med* 2009; 34:343-348.
- Johansson A, Hao J, Sjölund B. Local corticosteroid application blocks transmission in normal nociceptive C-fibres. *Acta Anaesthesiol Scand* 1990; 34:335-338.
- Li JY, Xie W, Strong JA, Guo QL, Zhang JM. Mechanical hypersensitivity, sympathetic sprouting, and glial activation are attenuated by local injection of corticosteroid near the lumbar ganglion in a rat model of neuropathic pain. *Reg Anesth Pain Med* 2011; 36:56-62.