

## Literature Review



## A Practical Guide for Treatment of Pain in Patients with Systemic Mast Cell Activation Disease

Stefan Wirz, MD, PhD<sup>1</sup> and Gerhard J. Molderings, MD, PhD<sup>2</sup>

From: <sup>1</sup>Abteilung für Anästhesie, Interdisziplinäre Intensivmedizin, Schmerzmedizin/Palliativmedizin – Zentrum für Schmerzmedizin, CURA – katholisches Krankenhaus im Siebengebirge, Bad Honnef, Germany; <sup>2</sup>Institute of Human Genetics, University Hospital of Bonn, Germany

Address Correspondence:  
Gerhard J. Molderings, MD  
Institute of Human Genetics, University Hospital of Bonn, Sigmund-Freud-Strasse 25, D-53127 Bonn, Germany  
E-mail: molderings@uni-bonn.de

Disclaimer: Both authors contributed equally to this manuscript. There was no external funding in the preparation of this manuscript. Conflict of interest: Each author certifies that he or she, or a member of his or her immediate family, has no commercial association (i.e., consultancies, stock ownership, equity interest, patent/licensing arrangements, etc.) that might pose a conflict of interest in connection with the submitted manuscript.

Manuscript received: 12-22-2016  
Revised manuscript received: 02-06-2017  
Accepted for publication: 02-15-2017

Free full manuscript:  
[www.painphysicianjournal.com](http://www.painphysicianjournal.com)

Systemic mast cell activation disease (MCAD, a subclass of mastocytosis), which has a prevalence of around 17% (at least in the German population), is characterized by accumulation of genetically altered dysfunctional mast cells with abnormal release of these cells' mediators. Since mast cells affect functions in potentially every organ system, often without causing abnormalities in routine laboratory or radiologic testing, this disease has to be considered routinely in the differential diagnosis of patients with chronic multisystem polymorbidity of a generally inflammatory and allergic theme. Pain in its different manifestations is a common symptom in MCAD found in more than three-quarters of the MCAD patients. Because of the specific mast cell-related causes of pain in MCAD it should be treated specifically, if possible, deduced from their putative mast cell mediator-related causes. As yet, there is no official guideline for treatment of MCAD at all. The present review focuses on mast cell mediator-induced acute and chronic pain and the current state of analgesic drug therapy options in MCAD. Due to the high prevalence of MCAD, many physicians are often faced with the issue of pain management in MCAD patients. Hence, our practical guide should contribute to the improvement of patient care.

**Key words:** Pain therapy, mast cell activation disease, mast cell activation syndrome, systemic mastocytosis, mast cell

**Pain Physician 2017; 20:E849-E861**

**M**ast cell activation disease (MCAD) is the variant of mastocytosis which comprises the full spectrum of primary systemic mast cell disease, i.e., systemic mastocytosis (SM) which is further divided into several subtypes (1) (Table 1), mast cell activation syndrome (MCAS) (Table 1) (2-4), and mast cell leukemia (MCL). While the prevalence of SM in Europeans ranges between 0.3 and 13 per 100,000, the prevalence of MCAS, at least in Germany, has been determined to be 17% (5).

Pathogenetically, MCAD denotes a group of polygenic mast cell disorders (6) characterized by an aberrant

release of variable subsets of mast cell mediators together with accumulation of either morphologically altered and immunohistochemically identifiable mutated mast cells due to mast cell proliferation (SM and MCL) or morphologically ordinary mast cells due to decreased apoptosis (MCAS and well-differentiated SM) (Table 1) (5). It is the unregulated release of the mediators by inappropriate mast cell activation (whether constitutive and/or reactive), not inappropriate MC proliferation, that underlies the given presentations of MCAD. Specific mutation sets appear to drive specific patterns of aberrant constitutive mast cell activation

as well as aberrant mast cell reactivity resulting in unregulated increased mediator release, ultimately activating local and/or remote ordinary mast cells, thereby, starting a cascade of mast cell activation with mediator release inducing the variety of symptoms (7). Due to both the wide-spread distribution of mast cells and the great heterogeneity of aberrant mediator expression patterns, symptoms may occur in all organs and tissues. Hence, the clinical presentation of MCAD is very diverse, sometimes to the even-further-confounding point of presenting opposite abnormalities in different patients (or even in the same patient at different times, or in different sites in the same patient at the same time) (5).

Establishing an initial suspicion of systemic mast cell activation is the first step in diagnosis of MCAD. It is reasonable to suspect MCAD when at least several symptoms and signs of mast cell activation are present (5) and no other diagnosis better accounting for the full range of findings is present. Recognition of a mast cell mediator release syndrome, i.e., a pattern of symptoms caused by the unregulated increased release of mediators from mast cells, can be aided by the use of a validated checklist which lists the complaint complexes to be considered (8). In addition, the occurrence of further diagnostic criteria has to be investigated to make the final diagnosis (Table 2).

Currently, there is no cure for primary mast cell disorders. However, it is possible to achieve a complete

or partial symptomatic response to drug therapy. As the primary feature of MCAD is an inappropriate mast cell activity, treatment invariably involves trigger identification respectively and avoidance, if possible, plus control of mast cell mediator production/action. Mast cells secrete prestored mediators and synthesize mediators in response to allergic, microbial, and nonimmune triggers which can often be named by the patients from their experience. Thus, a detailed history provides the best access to the detection of triggers. Treatment of MCAD should be focused on the individual patient, and tailored to the patient's symptoms, disease manifestations, and the clinical course (Fig. 1). In most MCAD patients, moderate improvement is mostly attainable, although both patients and providers must exercise patience. Sometimes many lines (and formulations) of therapy must be tried. Generally, less expensive interventions (e.g., histamine H1 and H2 receptor antagonists, leukotriene receptor antagonists, cromolyn) are tried first, but often symptoms persist in many patients. In those patients, medical treatment using a stepwise approach to manage the increased mast cell activity should be provided (Fig. 1) (9). In this context, it should be noted that there is no official guideline for treatment of MCAD.

The present review focuses on mast cell mediator-induced acute and chronic pain and the current state of analgesic drug therapy in SM and MCAS. It is based on

Table 1. *Current classification of mastocytosis.*

Variant term	Subvariants
Systemic mast cell activation disease	
Systemic mastocytosis (SM)	Indolent SM -Smouldering SM - Isolated bone marrow mastocytosis - Well-differentiated SM SM with an associated hematological neoplasm - SM with myelodysplastic syndrome - SM with myeloproliferative neoplasm - SM with hypereosinophilic syndrome - SM with chronic myelomonocytic leukemia - SM with non-Hodgkin lymphoma Aggressive SM Mast cell leukemia -Leukemic mast cell leukemia -Aleukemic mast cell leukemia
Systemic mast cell activation syndrome	With hypertryptasemia Without hypertryptasemia
Cutaneous mastocytosis	Urticaria pigmentosa Diffuse cutaneous mastocytosis Mastocytoma of the skin
Mast cell sarcoma	
Extracutaneous mastocytoma	

Table 2. *Diagnostic criteria for the variants of MCAD (2).*

<b>Current criteria used to define mast cell activation syndrome (MCAS)</b>	
Major criteria	
	Constellation of clinical symptoms attributable to pathologically increased mast cell activity (mast cell mediator release syndrome)
	Disseminated increased number of mast cells in marrow and/or extracutaneous organ(s) (e.g., gastrointestinal tract biopsies; CD117-, tryptase-, and CD25-stained)
Minor criteria	
1.	Abnormal spindle-shaped morphology in > 25% of mast cells in marrow or other extracutaneous organ(s)
2.	Abnormal mast cell expression of CD2 and/or CD25 (i.e., co-expression of CD117/CD25 or CD117/CD2)
3.	Detection of genetic changes in mast cells from blood, bone marrow, or extracutaneous organs for which an impact on the state of activity of affected mast cell in terms of an increased activity has been proven.
4.	Evidence (typically from body fluids such as whole blood, serum, plasma, or urine) of increased levels of mast cell mediators including: <ul style="list-style-type: none"> <li>• tryptase in blood</li> <li>• histamine or its metabolites (e.g., N-methylhistamine) in urine</li> <li>• heparin in blood</li> <li>• chromogranin A in blood (following exclusion of potential confounders of cardiac or renal failure, neuroendocrine tumors, or recent proton pump inhibitor use)</li> <li>• other relatively mast cell-specific mediators (e.g., eicosanoids including prostaglandin PGD<sub>2</sub>, its metabolite 11-β-PGF<sub>2α</sub>, or leukotriene E<sub>4</sub>)</li> </ul>
5.	Symptomatic response to inhibitors of mast cell activation or mast cell mediator production or action (e.g., histamine H <sub>1</sub> and/or H <sub>2</sub> receptor antagonists, cromolyn)
Diagnosis of MCAS assigned according to: (1) both major criteria; (2) one major criterion plus any one of the minor criteria; or (3) any 3 minor criteria.	
<b>Diagnostic criteria for systemic mastocytosis (1)</b>	
Major Criterion	
	Multifocal, dense aggregates of mast cells (15 or more) in sections of bone marrow or other extracutaneous tissues and confirmed by tryptase or CD117 immunohistochemistry
Minor Criteria	
	Abnormal spindle-shaped morphology in > 25% of mast cells in marrow or other extracutaneous organ(s)
	Abnormal mast cell expression of CD2 and/or CD25 (i.e., co-expression of CD117/CD25 or CD117/CD2)
	KIT codon 816 mutation in mast cells from marrow, blood, or extracutaneous organs
	Persistent elevation of serum total tryptase > 20 ng/mL
Diagnosis of SM assigned according to: (1) major criterion plus any one or more minor criteria; or (2) any 3 minor criteria.	

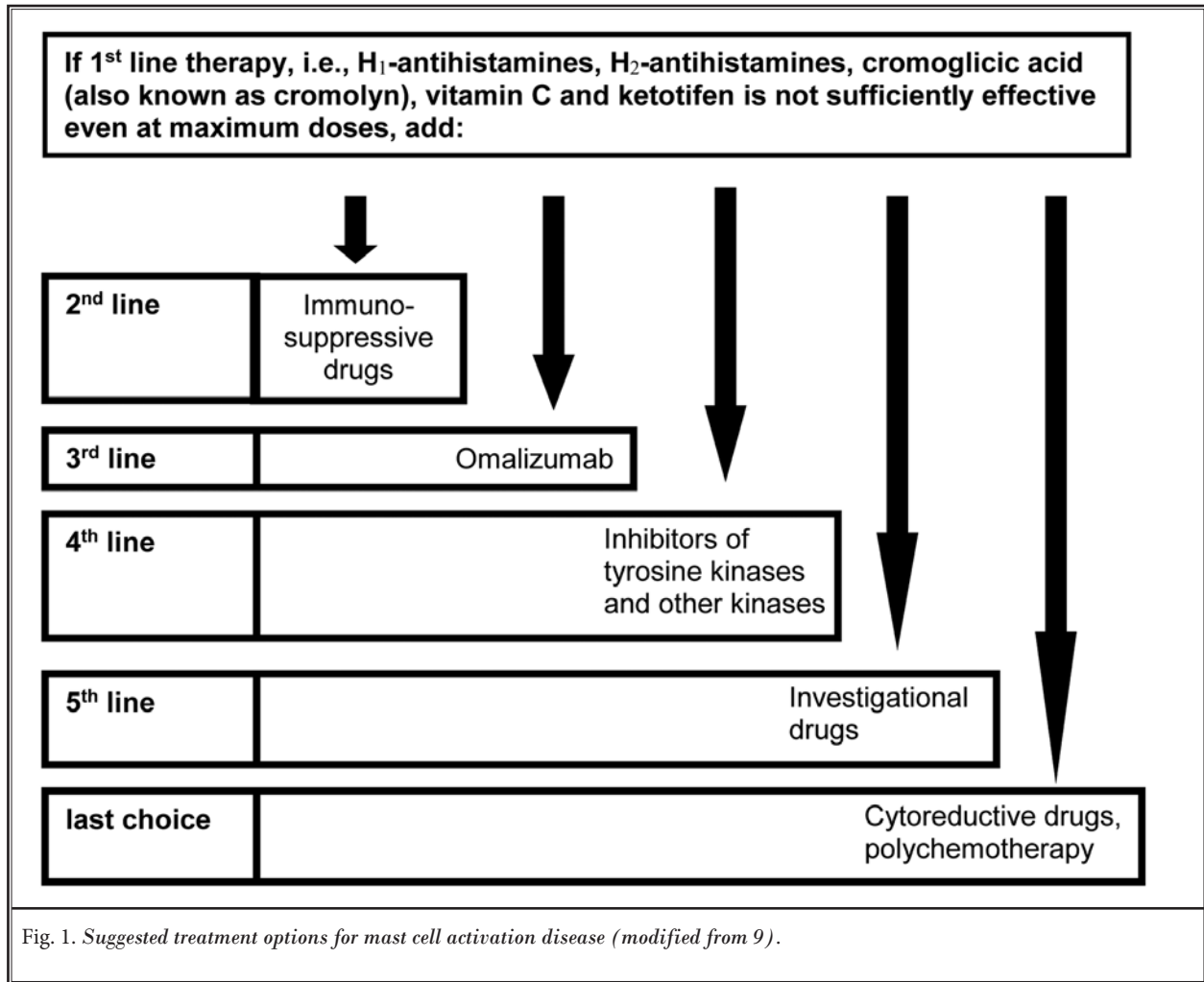
a comprehensive evaluation of the literature published before December 2016 and is strengthened by our personal experiences in the treatment of a large number of MCAD patients.

### **Mast Cell-nerve Interactions in Nociception**

Mast cells and the nervous system influence each other's responses through bidirectional communication through the release of mediators and cytokines (10). In the periphery, mast cells are often found in close proximity to nerves and vasculature (11,12). Several mast cell mediators such as bradykinin, substance P, TNF $\alpha$ , nerve growth factor, prostaglandins, tryptase, and histamine are released, stimulating receptors that are expressed at sensory afferent nerve terminals, generally resulting in pain perception (Fig. 2). When these neurons are

stimulated, they send signals to the central nervous system (CNS) and concomitantly release neuromodulators, such as substance P and calcitonin-gene related peptide, the vasoactive intestinal protein, and corticotropin releasing hormone (CRH), which, in turn, can further stimulate mast cell activation creating a bidirectional positive feedback-loop potentially resulting in neurogenic inflammation (13). Furthermore, mast cells can recruit other immune cells such as eosinophils, neutrophils, macrophages, and T-cells, which release pro-nociceptive mediators and boost the maintenance of inflammatory reactions (14). As a consequence, inflammation can affect not only injured zones, but also adjacent territories, creating a secondary widespread hyperalgesia or panalgesia.

Mast cells are also implicated in central integra-



tion of nociceptive pain signaling from the periphery to the CNS. Depolarization induced by stimulation of primary afferent nerve fibers spreads to the dorsal horn of the spinal cord via 2 pathways (Fig. 2). One, corresponding to fast pain, is mediated by A-delta fibers that are responsible for the precise localization of pain sites. It joins the lateral thalamus by the neospinothalamic tract, then the S1 and S2 areas of the sensory cortex. The second way of pain transmission is mediated by unmyelinated C fibers, responsible for slow and widespread – unlocalized – pain. In the CNS, nociceptive input is conveyed to the medial thalamus, the limbic structures, the insula, the cingulate cortex, and the frontal cortex. The thalamus is an essential nociceptive relay, discriminating nociceptive stimulations and transmitting some of them from the spinal cord to the cortex, which then enhances the conscious perception of pain sensation. In

turn, the thalamus can be influenced by the cortex as well as by the limbic system, where the pain acquires its psychoaffective coloration. Signals from the supraspinal centers are also integrated in the periaqueductal gray, which modulates descending facilitation and inhibition of nociceptive input via the rostral ventromedial medulla. Supraspinal afferents influence the activity of spinal interneurons releasing a variety of neurotransmitters to modulate nociceptive forwarding to the CNS. Spinal interneurons themselves exert inhibitory effects on the processing of pain signals. In this network, mast cells are versatile gatekeepers of pain (15). It is known, that mast cells, centrally located, are aggregated in the infundibulum, pituitary gland, area postrema, choroid plexus, and in the region near the third ventricle of the cerebrum, the hypothalamus, and thalamus (Fig. 2; (16). Since mast cells are located on the brain side of

the blood-brain barrier as well as in the leptomeninges, they can communicate with neurons, glia cells, microglia, and vascular endothelial cells by transmitting their mediators via several ways (Table 3). And mast cell mediators can spread through brain tissue volume several orders of magnitude greater than a synaptic cleft (17). Since 90% of thalamic histamine and up to 50% of total brain histamine is synthesized by mast cells (18), mast cells in the brain can influence brain functions directly by releasing histamine.

**Pain Related to MCAD**

Aberrant mast cell activation, causing both inappropriate mast cell mediator release and inappropriate

ate mast cell reactivity, effects a potentially enormous range of aberrant reactions in all tissues and systems

Table 3. *Forms of communication between mast cells and effector cells, e.g., neurons.*

• Mediator release by degranulation (56)
• Selective exocytotic mediator release (synonyms: piecemeal degranulation, differential release; [56-58])
– undirected
– at a synaptic contact with a target cell (59)
• Release of exosomes loaded with mRNA, mikroRNA and proteins (58-60)
• Diffusion of mediators into the extracellular biophase (58)
• Physical contact with exchange of intracellular substances (61)

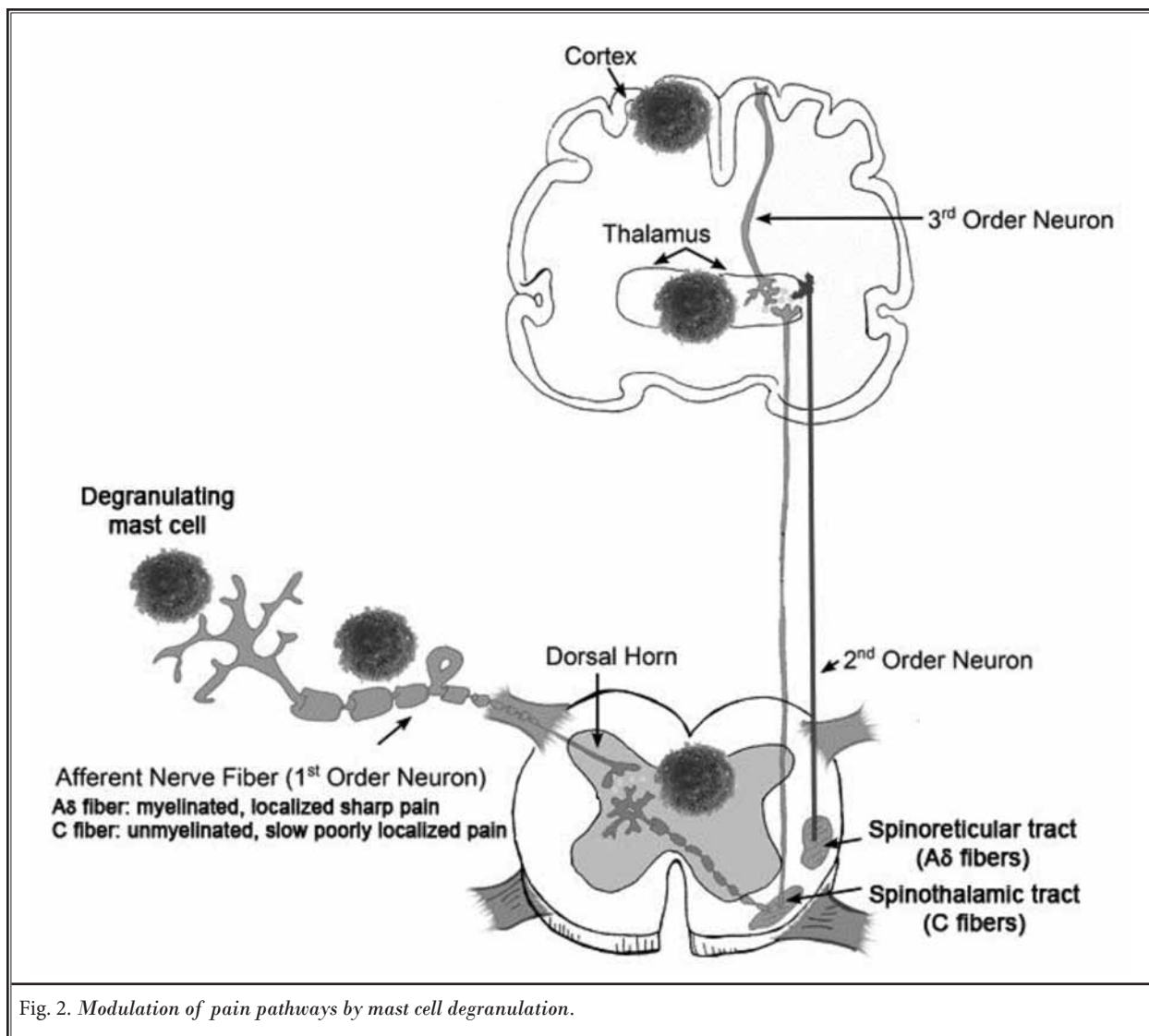


Fig. 2. *Modulation of pain pathways by mast cell degranulation.*

due to (1) the widespread distribution of mast cells, (2) the enormous range of mast cells' normal biological activity, and (3) great heterogeneity in aberrant mast cell mediator expression patterns creating MCAD's clinical signature of multisystem polymorbidity (5). Mast cell activation displays different symptoms such as hives, rash, anaphylaxis, hot flushing of skin, tachycardia, nausea, and fatigue (19). Pain is a common symptom in MCAD. It compromises headache, epigastric pain, abdominal pain, skeletal pain, stomatitis, bone pain, muscle pain, joint pain, ocular discomfort, and ear/nose/throat inflammation. Often, pain is described as migratory referring to a particular region of the body or even the entire body (19,20). In the largest survey on symptoms in mast cell disorders performed so far (420 patients, cutaneous mastocytosis 24%, SM 51%, MCAS 12%), pain was reported in the chest (in 36.7% of the patients), stomach (72.9%), upper abdomen (46.4%), lower abdomen (56.4%), bones (56.4%), joints (61.4%), muscles, and nerves or connective tissues (50%) (21). With regard to quality of life, pain is one of the most severe symptoms in MCAD patients (22).

### **Options for the Treatment of Pain in MCAD Patients**

Since pain is one of the most effective triggers for the activation of mast cells, its elimination is crucial for the prevention of worsening of patients' MCAD. Often, treatment of pain in MCAD is challenging, especially because classical analgesics – most narcotics and non-steroidal anti-inflammatory drugs (NSAIDs) – can trigger MCAD and turn out to be ineffective. Therefore, pain perception in MCAD should be treated specifically, in some cases deduced from their putative mast cell mediator-related causes (Table 4).

#### ***Non-drug Arrangements***

In the context of pain treatment, it is important to note that sometimes non-drug arrangements, that are not expected to have analgesic effect, reveal striking effects, achieving such analgesic effects. By avoidance of food containing gluten, cow's milk proteins, beef, and baker's yeast, a massive pain reduction can often already be obtained (23-26); hence, it should be the first therapeutic action before initiation of drug therapy.

#### ***Drug Therapy of Musculoskeletal Pain***

About 75% of MCAD patients present with MCAD-driven musculoskeletal pain, most often accompanied by peripheral (usually distal) sensory and/

or motor neuropathies including paresthesias (5). In physical examinations of MCAD patients, muscular pain sensation can be induced frequently by pressure at specific tender points of the muscles in all 4 quadrants of the body (27), thus fulfilling the criteria for the formal diagnosis of fibromyalgia syndrome (FMS) (28,29). In fact, a large number of patients are diagnosed with FMS before the diagnosis of MCAD is made (27). It is not surprising that several studies on FMS patients demonstrated an increased mast cell infiltration (30) and increased mast cell degranulation with increased PAR2 activity (31) in skin biopsies, and increased levels of IL-1, IL-6, IL-8, and MCP-1 in the serum of FMS patients vs. healthy controls (32,33). These findings suggest that at least a subset of fibromyalgia may be a clinical manifestation of MCAD. The pathogenesis of pain in these MCAD/FMS patients appears to be based on the activation of mast cells by locally released CRH and substance P via CRH and NK1 receptors, respectively, which can lead to a feed-forward neuroendocrine sensitization of the peripheral and central nervous system (34-36). In addition, in the periphery, mast cells closely surrounding the primary afferent A $\delta$  and C fibers (Fig. 2) may influence nerve fiber function by released mediators in MCAD patients (37-39). Generally, this neuropathic pain is only poorly (if at all) responsive to classical drug management of neuropathic pain (5) (Table 5). Furthermore, some of those drugs may worsen the severity of symptoms by further increasing mast cell activity (Table 5).

#### ***Drug Therapy of Intestinal Pain***

A majority of MCAD patients complain about abdominal pain and/or cramping usually accompanied by bloating-gassiness of the bowel, diarrhea, constipation, thereby fulfilling the diagnostic criteria for irritable bowel syndrome (IBS). A bulk of results suggest roles of mast cell infiltration and activation in IBS-related pain pathology (Table 6). In a pilot study on therapy-resistant IBS patients, evidence of pathologic mast cell activation due to MCAS was found as the causative disease in almost all patients (40). Similar to neuropathic pain, the effectiveness of drug therapy in IBS is rather limited. So far, despite immense research, therapeutic options have not yet shown significant progress, possibly because they target symptoms but not the underlying root cause. Therefore, it is not surprising that the mast cell stabilizers cromolyn and ketotifen have been shown to reduce the visceral hypersensitivity in IBS patients (41,42). Therefore, in MCAD/IBS patients, it



Table 4. Treatment of different pain sensations in MCAD.

System	Pain sensation	Supported role of mast cells in the pathogenesis	Treatment options
Gastrointestinal	angina pectoris-like pain	(exclusion of a primary disorder of the heart); bloating in left colic flexure	local thermal treatment; dipyrone
	non-cardiac chest pain	release of mediators from mast cells in the esophagus; gastroesophageal reflux	histamine H <sub>2</sub> -receptor blocker; proton pump inhibitor
	colicky gastric pain	presumably release of mediators from mast cells in the stomach inducing inappropriate gastric motility (e.g., giant contractions)	proton pump inhibitor; acute therapy: butylscopolamine
	colicky intestinal pain, irritable bowel syndrome	distension of the bowel during the transport of scybala trapping diarrheal feces; release of mediators from mast cells in the gut promoting peristalsis and colonic motility	local thermal treatment; prevention: macrogol to prevent scybala formation; acute therapy: dipyrone
	pain in the spine or hip joint	(exclusion of an orthopedic reason); referred pain from bloating in the sigmoid colon or inflammation of the intestine located in the left or right lower abdomen (colitis, enteritis)	dose escalation of the H <sub>1</sub> antihistamine; etoricoxib, short-term high-dose glucocorticoid therapy
	biliary colic	increased risk for the formation of biliary calculus in MCAD	dipyrone; no application of meperidine because of high risk to induce a massive mast cell mediator release; if it has happened, coping with bolus injection of 100 mg prednisone
Neurologic	migraine, trigeminal neuralgia	release of mediators from mast cells located close to meningeal nerves; decreased potassium in the biophase of meningeal nerves	acetaminophen, dipyrone, (ibuprofen*), triptans; oral substitution of K <sup>+</sup> for 2-3 days
Musculoskeletal	muscle pain	release of mediators from mast cells in the muscle; frequently begin is suddenly with high intensity and it also disappears suddenly; pulsatile character; varying locations	dose escalation of the H <sub>1</sub> antihistamine; etoricoxib; dipyrone; no massage
	bone pain	unknown cause; frequently begin and disappearance is suddenly; pulsatile character; also boring pain possible; often described as migratory	dose escalation of the H <sub>1</sub> antihistamine; etoricoxib; dipyrone; in case of osteopenia or osteoporosis bisphosphonates
	neuropathic pain, fibromyalgia	presumably release of mediators from mast cells located close to pain fibers; varying intensity and described as migratory referring to a particular region of the body or even the entire body	avoidance of food containing gluten, cow's milk proteins, beef and baker's yeast; dose escalation of the H <sub>1</sub> antihistamine; omalizumab; cannabinoids; pirritramide; oral low dose ketamine; amitriptyline; palmitoylethanolamide; minocycline
Cardiovascular	angina pectoris	coronary vasospasms induced by vasoconstrictive mast cell mediators	nitrates; calcium channel blockers
Renal	renal colic	increased risk for the formation of ureteral calculus in MCAD	dipyrone; butylscopolamine; no application of meperidine because of high risk to induce a massive mast cell mediator release; if it has happened, coping with bolus injection of 100 mg prednisone
Oropharyngeal	sore throat	release of mediators from pharyngeal mast cells	dose escalation of the H1 antihistamine; etoricoxib

\* Use with caution because ibuprofen like all acidic NSAIDs can induce mast cell activation.

Table 5. Notes on application of drugs used in classical drug management of nociceptive and neuropathic pain (modified from 62,63) in patients with MCAD and MCAD-associated disorders.

Neurophysiological correlate	Mechanisms of drug action	Drug	Comments
Nociceptive Pain	non-steroidal anti-inflammatory drugs (NSAIDs)	acidic NSAIDs e.g., ibuprofen and acetylsalicylic acid	help some MCAD patients but trigger others (64)
		non-acidic 1,5-diarylpyrazole derivatives etoricoxib and celecoxib	reduced risk to activate mast cells compared with acidic NSAIDs (50)
	opioid receptor agonists	tramadol; morphine, meperidine, oxycodone, fentanyl, methadone, levorphanol	can trigger mast cell activation (reviewed in [65]);
Neuropathic Pain	calcium channel $\alpha$ 2- $\delta$ ligands (anti-epileptic drugs)	gabapentin, pregabalin	not effective in FMS (66); may be effective in a sub-set of FMS-patients with small-fiber disease
	opioid receptor agonists	tramadol, morphine, meperidine, oxycodone, fentanyl, methadone, levorphanol	can trigger mast cell activation (65)
	tricyclic antidepressants	amitriptyline, nortriptyline, desipramine, imipramine	amitriptyline can reduce mast cell activity (65,67)
	selective serotonin norepinephrine reuptake inhibitors	venlafaxine, duloxetine	no substantial reduction of symptoms in FMS (68)
	cannabinoid receptor agonists	dronabinol, tetrahydrocannabinol/cannabidiol	can be used to effectively reduce mast cell activity (69,70; for review, see 9)
	sodium channel blocker	mexiletine	
	anti-epileptic drugs with sodium channel blocking properties	carbamazepine, lamotrigine, oxcarbazepine, topiramate, valproic acid	increased risk for severe immunological adverse effects in MCAD patients (65)
	NMDA receptor antagonists	memantine, dextromethorphan	dextromethorphan has been reported to induce bullous mastocytosis (71)
	inhibition of sodium channels	topical 5% lidocaine patch	increased risk for intolerance in MCAD (65)
	TRPV1-agonist	topical 8% capsaicin	initially induction of mast cell activation; in the course of the therapy it can induce mast cell inactivation (72)

Table 6. Findings supporting the mast cell-related disease character of IBS.

<ul style="list-style-type: none"> <li>increased mast cell counts in the jejunal, terminal ileal, cecal, colonic, and rectal mucosa of IBS patients compared to control individuals (73-76)</li> </ul>
<ul style="list-style-type: none"> <li>increased tryptase levels in colonic biopsies (74-76), in the blood serum and intestinal fluid of IBS patients (73)</li> </ul>
<ul style="list-style-type: none"> <li>increased numbers of degranulating mast cells located in the proximity (&lt; 5 <math>\mu</math>m) of colonic nerve fibers correlating with pain scores of the IBS patients (11,77,78)</li> </ul>
<ul style="list-style-type: none"> <li>increased numbers of degranulating mast cells were associated with increased substance P and vasoactive intestinal peptide (79)</li> </ul>
<p>increased intestinal permeability presumably due to an action of mast cell-derived tryptase at PAR2 (80,81) was correlated with increased nociception in IBS patients (77,82)</p>
<ul style="list-style-type: none"> <li>injecting supernatant from colonic biopsies of IBS patients increased visceral sensation in rats (83) and exhibited enhanced mesenteric afferent firing in a mast cell-dependent manner in rats and guinea pigs respectively (83,84)</li> </ul>
<ul style="list-style-type: none"> <li>injecting supernatant from colonic biopsies of IBS patients increased activity of human enteric neurons, while histamine receptor antagonists and protease inhibitors inhibited enhanced excitation (83,85)</li> </ul>
<ul style="list-style-type: none"> <li>mast cell-derived serotonin acting at the intestinal nerve system may contribute to pain in IBS (86,87)</li> </ul>
<ul style="list-style-type: none"> <li>NGF contributed to visceral hyperalgesia in rats via mucosal dysfunction promoting direct mast cell-nerve interaction (88,89)</li> </ul>
<ul style="list-style-type: none"> <li>mast cells regulate epithelial secretion (90)</li> </ul>



appears justified to treat pain and intestinal symptoms in the MCAD-specific way (Table 4).

### **Drug Therapy of Headache/Migraine Syndromes**

The pathophysiology of MCAD-related headache syndromes/migraine, which is present in more than 60% of the MCAD patients (5), has been extensively reviewed elsewhere (19,43,44). First-line therapy is the application of acetaminophen, dipyrrone, and NSAIDs (the latter with particular caution). If headache is resistant to these analgesics, decreased potassium in the biophase of meningeal nerves may be the underlying cause. A therapeutic trial with oral substitution of K<sup>+</sup> for 2 – 3 days would support the diagnosis. Another possible cause could be unrecognized MCAD-related nocturnal hypertension which would be an indication for antihypertensive therapy. In MCAD patients, triptans, e.g., sumatriptan, should be applied cautiously, since they have been shown to increase the mast cell number, at least in the rat brain (45), and thereby may have the potential to aggravate MCAD-related headache/migraine in humans.

### **Treatment of Intraoperative/Postsurgical Pain and Inflammatory Pain**

In order to prevent an acute release of mast cell mediators by trigger stimuli in connection with surgical or endoscopic procedures and, thus, to prevent a prolonged aggravation of MCAD, shielding of the mast cells by means of a MCAD-specific intravenous premedication composed of a glucocorticoid (e.g., 30 – 100 mg prednisone depending on the disease intensity), 50 mg ranitidine, and 1 mg dimetindenmaleate per 10 kg body weight about 30 minutes before the beginning of the operative procedure or endoscopic examination is necessary. Injection solutions containing ethanol should not be used in MCAD patients, since these patients often react highly intolerant even to the smallest quantities of ethanol.

In the intra- and postoperative pain therapy (Table 7), known potential intolerances of MCAD patients against a series of analgesics must be taken into account when selecting the analgesic drugs. The opioid analgesics pethidine, morphine, and codeine should be avoided, because of their high risk to induce a massive mast mediator release (46-48). Therapeutic alternatives with a lower risk for inducing mast cell activation are remifentanyl, alfentanil, fentanyl, oxycodone, and piritramide (Table 7). Piritramide is the only opioid analgesic which potently inhibits mast cell activity and,

Table 7. *Treatment options for acute pain respectively postsurgical pain in MCAD patients.*

Remifentanyl, alfentanil, fentanyl, oxycodone when individual tolerance is known
Piritramide
Ketamine
Dipyrrone
Acetaminophen up to 1 g/day (Cave liver toxicity!)
Flupirtine
Etoricoxib, celecoxib
Ibuprofen or acetylsalicylic acid when individual tolerance is known*
Peridural anesthesia with lidocaine**

\* Use with caution because all acidic NSAIDs can induce mast cell activation.

\*\* Use with caution because local anesthetics have the potential to induce mast cell activation.

therefore, it is particularly suitable in the therapy of postsurgical pain in MCAD patients (48). Ketamine is also an analgesic with a pronounced inhibitory effect on mast cells (49). However, its application is limited by its specific side effects. Dipyrrone and acetaminophen (Table 7) can be administered orally or parenterally to prevent or treat postoperative surgical pain or non-surgical acute pain, when the use of highly potent opioid analgesics is not yet required. In contrast to NSAIDs, both compounds do not activate mast cells, if there is no individual hypersensitivity (Table 5) (50). Flupirtine, a selective neuronal potassium channel opener that also has NMDA receptor antagonist and GABAA receptor modulatory properties (51) (Table 7), is suitable as a centrally acting non-opioid analgesic for acute pain in moderate-to-severe cases (52). Its muscle relaxant properties make it popular for back pain, but it is also used for headaches, in oncology, and postoperative care. Due to issues with liver toxicity its use has been limited to acute pain for no more than 2 weeks, and only for people who cannot use other painkillers (53). As yet, flupirtine has not been shown to elicit mast cell mediator release, supporting its application in MCAD patients. Finally, mast cell stabilization with cromolyn or ketotifen may promote antinociceptive effects (54).

For the treatment of inflammatory pain, NSAIDs should be used. Among the NSAIDs, the 1,5-diarlylpyrazole derivatives etoricoxib and celecoxib contrast with the acidic NSAIDs (e.g., ibuprofen and acetylsalicylic acid) in that they have only a low risk of activating mast cells (but an increased risk for cardiovascular events has to be kept in mind during long-term

use), whereas the latter help some MCAD patients but trigger others (Tables 5 and 7). Pain relief and anti-inflammatory effect do not substantially differ within the NSAIDs.

## CONCLUSIONS

Pain is a debilitating condition tremendously affecting quality of life of the MCAD patients. The absence of any response of the pain to or even its aggravation under classical pain therapy must not be misconstrued as a somatoform disorder. In MCAD, the different pain sensations have to be treated specifically, if possible deduced from their putative mast cell mediator-related causes. The therapeutic efficacy can be poor and vary between patients. Preventing and inhibiting mast cell degranulation by avoiding mast cell triggers and by mast cell stabilizers and/or other mast cell inhibitors is essential for any analgesic therapy in MCAD. The

future development of novel analgesic therapeutic approaches such as the administration of the endogenous cannabinoid-like compound N-palmitoyl-ethanolamine or the tetracycline minocycline (9) may enhance the analgesic therapeutic options in MCAD patients.

Multi-disciplinary approaches for quantification of pain and elucidating mechanistic contribution of mast cells to pain pathobiology are needed to improve analgesic strategies. Individual patient circumstances may permit cognitive-behavioral psychotherapeutic co-treatment to be helpful supporting patients in mentally coping with the incurability of the disease, and psychotherapy also can illustrate strategies for dealing with the social environment that often reacts uncomprehendingly and adversely against the MCAD patient. Finally, activation of mast cells by psychological stress (e.g., via CRH) (55) may be lessened by psychotherapeutic approaches which successfully reduces stress.

## REFERENCES

- Valent P, Akin C, Escribano L, Födinger M, Hartmann K, Brockow K, Castells M, Sperr WR, Klugin-Nelemans HC, Hamdy NA, Lortholary O, Robyn J, van Doormaal J, Sotlar K, Hauswirth AW, Arock M, Hermine O, Hellmann A, Triggiani M, Niedoszytko M, Schwartz LB, Orfao A, Horny HP, Metcalfe DD. Standards and standardization in mastocytosis: Consensus statements on diagnostics, treatment recommendations and response criteria. *Eur J Clin Invest* 2007; 37:435-443.
- Molderings GJ, Brettner S, Homann J, Afrin LB. Mast cell activation disease: A concise practical guide for diagnostic workup and therapeutic options. *J Hematol Oncol* 2011; 4:10.
- Hamilton MJ, Hornick JL, Akin C, Castells MC, Greenberger NJ. Mast cell activation syndrome: A newly recognized disorder with systemic clinical manifestations. *J Allergy Clin Immunol* 2011; 128:147-152.
- Valent P, Akin C, Arock M, Brockow K, Butterfield JH, Carter MC, Castells M, Escribano L, Hartmann K, Lieberman P, Nedoszytko B, Orfao A, Schwartz LB, Sotlar K, Sperr WR, Triggiani M, Valenta R, Horny HP, Metcalfe DD. Definitions, criteria, and global classification of mast cell disorders with special reference to mast cell activation syndromes: A consensus proposal. *Int Arch Allergy Immunol* 2012; 157:215-225.
- Afrin LB, Butterfield JH, Raithel M, Molderings GJ. Often seen, rarely recognized: Mast cell activation disease – a guide to diagnosis and therapeutic options. *Ann Med* 2016; 48:190-201.
- Molderings GJ. Transgenerational transmission of systemic mast cell activation disease-genetic and epigenetic features. *Transl Res* 2016; 174:86-97.
- Molderings GJ, Homann J, Brettner S, Raithel M, Frieling T. Mast cell activation disease: A concise practical guide for diagnostic workup and therapeutic options. *Dtsch Med Wochenschr* 2014; 139:1523-1534.
- Afrin LB, Molderings GJ. A concise, practical guide to diagnostic assessment for mast cell activation disease. *World J Hematol* 2014; 3:1-17.
- Molderings GJ, Haenisch B, Brettner S, Homann J, Menzen M, Dumoulin FL, Panse J, Butterfield J, Afrin LB. Pharmacological treatment options for mast cell activation disease. *Naunyn Schmiedeberg Arch Pharmacol* 2016; 389:671-694.
- McKay DM, Bienenstock J. The interaction between mast cells and nerves in the gastrointestinal tract. *Immunol Today* 1994; 15:533-538.
- Barbara G, Stanghellini V, De Giorgio R, Cremon C, Cottrell GS, Santini D, Pasquinelli G, Morselli-Labate AM, Grady EF, Bunnett NW, Collins SM, Corinaldesi R. Activated mast cells in proximity to colonic nerves correlate with abdominal pain in irritable bowel syndrome. *Gastroenterology* 2004; 126:693-702.
- Stead RH, Dixon MF, Bramwell NH, Riddell RH, Bienenstock J. Mast cells are closely apposed to nerves in the human gastrointestinal mucosa. *Gastroenterology* 1989; 97:575-585.
- Kowalski ML, Kaliner MA. Neurogenic inflammation, vascular permeability, and mast cells. *J Immunol* 1988; 140:3905-3911.
- Zuo Y, Perkins NM, Tracey DJ, Geczy CL. Inflammation and hyperalgesia induced by nerve injury in the rat: A key role of mast cells. *Pain* 2003; 105:467-479.
- Chatterjea D, Martinov T. Mast cells: Versatile gatekeepers of pain. *Mol Immunol* 2015; 63:38-44.
- Afrin LB, Pöhlau D, Raithel M, Haenisch B, Dumoulin FL, Homann J, Mauer UM, Harzer S, Molderings GJ. Mast cell activation disease: An underappreciated cause of neurologic and psychiatric symptoms and diseases. *Brain Behav Immun* 2015; 50:314-321.
- Nautiyal KM, McKellar H, Silverman AJ, Silver R. Mast cells are necessary for the hypothermic response to LPS-induced sepsis. *Am J Physiol Regul Integr Comp Physiol* 2009; 296:R595-R602.

18. Goldschmidt RC, Hough LB, Glick SD. Rat brain mast cells: Contribution to brain histamine levels. *J Neurochem* 1985; 44:1943-1947.
19. Afrin LB. Mast cell activation disease and the modern epidemic of chronic inflammatory disease. *Transl Res* 2016; 174:33-59.
20. Hermine O, Lortholary O, Leventhal PS, Catteau A, Soppelsa F, Baude C, Cohen-Akenine A, Palmérini F, Hanssens K, Yang Y, Sobol H, Fraytag S, Ghez D, Suarez F, Barete S, Casassus P, Sans B, Arock M, Kinet JP, Dubreuil P, Moussy A. Case-control cohort study of patients' perceptions of disability in mastocytosis. *PLoS ONE* 2008; 3:e2266.
21. Jennings S, Russell N, Jennings B, Slee V, Sterling L, Castells M, Valent P, Akin C. The mastocytosis society survey on mast cell disorders: Patient experiences and perceptions. *J Allergy Clin Immunol Pract* 2014; 2:70-76.
22. van Anrooij B, Kluijn-Nelemans JC, Safy M, Flokstra-de Blok BM, Oude Elberink JN. Patient-reported disease-specific quality-of-life and symptom severity in systemic mastocytosis. *Allergy* 2016; 71:1585-1593.
23. Assa'ad A, Fiocchi A. Guidelines change the diagnostic process of cow milk food allergy: Problem-based learning. *Curr Opin Allergy Clin Immunol* 2012; 12:564-569.
24. Isasi C, Colmenero I, Casco F, Tejerina E, Fernandez N, Serrano-Vela JI, Castro MJ, Villa LF. Fibromyalgia and non-celiac gluten sensitivity: A description with remission of fibromyalgia. *Rheumatol Int* 2014; 34:1607-1612.
25. Makharia A, Catassi C, Makharia GK. The overlap between irritable bowel syndrome and non-celiac gluten sensitivity: A clinical dilemma. *Nutrients* 2015; 7:10417-10426.
26. Volta U, Pinto-Sanchez MI, Boschetti E, Caio GP, De Giorgio R, Verdu EF. Dietary triggers in irritable bowel syndrome: Is there a role for gluten. *J Neurogastroenterol Motil* 2016; doi: 10.5056/jnm16069.
27. Molderings GJ, Haenisch B, Bogdanow M, Fimmers R, Nöthen MM. Familial occurrence of systemic mast cell activation disease. *PLoS One* 2013; 8:e76241.
28. Wolfe F, Smythe HA, Yunus MB, Bennett RM, Bombardier C, Goldenberg DL, Tugwell P, Campbell SM, Abeles M, Clark P, Fam AG, Farber SJ, Fiechtner JJ, Franklin CM, Gatter RA, Hamaty D, Leassard J, Lichtbroun AS, Masi AT, McCain GA, Reynolds WY, Romano TJ, Russell IJ, Sheon RTP. The American College of Rheumatology 1990 criteria for the classification of fibromyalgia. *Arthritis Rheum* 1990; 33:160-172.
29. Bernstein C, Marcus D. Fibromyalgia: Current concepts in diagnosis, pathogenesis, and treatment. *Pain Med News* 2008; 6:8-19.
30. Eneström S, Bengtsson A, Frödin T. Dermal IgG deposits and increase of mast cells in patients with fibromyalgia – relevant findings or epiphenomena? *Scand J Rheumatol* 1997; 26:308-313.
31. Blanco I, Bérizte N, Argüelles M, Cárcaba V, Fernández F, Janciauskiene S, Oikonomopoulou K, de Serres FJ, Fernández-Bustillo E, Hollenberg MD. Abnormal overexpression of mastocytes in skin biopsies of fibromyalgia patients. *Clin Rheumatol* 2010; 29:1403-1412.
32. Lucas HJ, Brauch CM, Settas L, Theoharides TC. Fibromyalgia – new concepts of pathogenesis and treatment. *Int J Immunopathol Pharmacol* 2006; 19:5-9.
33. Zhang Z, Cherryholmes G, Mao A, Marek C, Longmate J, Kalos M, Amand RP, Shively JE. High plasma levels of MCP-1 and eotaxin provide evidence for an immunological basis of fibromyalgia. *Exp Biol Med (Maywood)* 2008; 233:1171-1180.
34. Theoharides TC, Donelan JM, Papadopoulou N, Cao J, Kempuraj D, Conti P. Mast cells as targets of corticotropin-releasing factor and related peptides. *Trends Pharmacol Sci* 2004; 25:563-568.
35. Theoharides TC, Petra AI, Stewart JM, Tsilioni I, Panagiotidou S, Akin C. High serum corticotropin-releasing hormone (CRH) and bone marrow mast cell CRH receptor expression in a mastocytosis patient. *J Allergy Clin Immunol* 2014; 134:1197-1199.
36. Cao J, Papadopoulou N, Kempuraj D, Boucher WS, Sugimoto K, Cetrulo CL, Theoharides TC. Human mast cells express corticotropin-releasing hormone (CRH) receptors and CRH leads to selective secretion of vascular endothelial growth factor. *J Immunol* 2005; 174:7665-7675.
37. Xanthos DN, Gaderer S, Drdla R, Nuro E, Abramova A, Ellmeier W, Sandkühler J. Central nervous system mast cells in peripheral inflammatory nociception. *Mol Pain* 2011; 7:42.
38. Buhner S, Schemann M. Mast cell-nerve axis with a focus on the human gut. *Biochim Biophys Acta* 2012; 1822:85-92.
39. Demir IE, Schorn S, Schremmer-Danninger E, Wang K, Kehl T, Giese NA, Algül H, Friess H, Ceyhan GO. Perineural mast cells are specifically enriched in pancreatic neuritis and neuropathic pain in pancreatic cancer and chronic pancreatitis. *PLoS One* 2013; 8:e60529.
40. Frieling T, Meis K, Kolck UW, Homann J, Hülsdonk A, Haars U, Hertfelder HJ, Oldenburg J, Seidel H, Molderings GJ. Evidence for mast cell activation in patients with therapy-resistant irritable bowel syndrome. *Z Gastroenterol* 2011; 49:191-194.
41. Stefanini GF, Saggioro A, Alvisi V, Angelini G, Capurso L, di Lorenzo G, Dobrilla G, Doderio M, Galimberti M, Gasbarrini G, Manghisi O, Marsigli L, Mazzacca G, Rigo L, Sacerdoti G, Scolozzi R, Surrenti C, Grazioli I, Melzi G. Oral cromolyn sodium in comparison with elimination diet in the irritable bowel syndrome, diarrheic type. Multicenter study of 428 patients. *Scand J Gastroenterol* 1995; 30:535-541.
42. Klooker TK, Braak B, Koopman KE, Welting O, Wouters MM, van der Heide S, Schemann M, Bischoff SC, van den Wijngaard RM, Boeckxstaens GE. The mast cell stabiliser ketotifen decreases visceral hypersensitivity and improves intestinal symptoms in patients with irritable bowel syndrome. *Gut* 2010; 59:1213-1221.
43. Theoharides TC, Donelan J, Kandere-Grzybowska K, Konstantinidou A. The role of mast cells in migraine pathophysiology. *Brain Res Rev* 2005; 49:65-76.
44. Smith JH, Butterfield JH, Cutrer FM. Primary headache syndromes in systemic mastocytosis. *Cephalalgia* 2011; 31:1522-1531.
45. Dubayle D, Servière J, Menétrey D. Evidence for serotonin influencing the thalamic infiltration of mast cells in rat. *J Neuroimmunol* 2005; 159:20-30.
46. Li F. Pharmacologically induced histamine release: Sorting out hypersensitivity reactions to opioids. *Drug therapy topics* 2006; 35:13-16.
47. Klein NJ, Misseldine S. Anesthetic considerations in pediatric mastocytosis: A review. *J Anesth* 2013; 27:588-598.
48. Sido B, Dumoulin FL, Homann J, Hertfelder HJ, Bollmann M, Molderings GJ. Surgical interventions in patients with mast cell activation disease. Aspects relevant for surgery using the example of a cholecystectomy. *Chirurg* 2014;

- 85:327-333.
49. Fujimoto T, Nishiyama T, Hanaoka K. Inhibitory effects of intravenous anesthetics on mast cell function. *Anesth Analg* 2005; 101:1054-1059.
  50. Doña I, Blanca-López N, Jagemann LR, Torres MJ, Rondón C, Campo P, Gómez AI, Fernández J, Laguna JJ, Rosado A, Blanca M, Canto G. Response to a selective COX-2 inhibitor in patients with urticaria/angioedema induced by nonsteroidal anti-inflammatory drugs. *Allergy* 2011; 66:1428-1433.
  51. Szelenyi I. Flupirtine, a re-discovered drug, revisited. *Inflamm Res* 2013; 62:251-258.
  52. Harish S, Bhuvana K, Bengalorkar GM, Kumar T. Flupirtine: Clinical pharmacology. *J Anaesthesiol Clin Pharmacol* 2012; 28:172-177.
  53. European Medicines Agency. Flupirtine-containing medicines. November 21, 2013.
  54. Yasuda M, Kido K, Ohtani N, Masaki E. Mast cell stabilization promotes antinociceptive effects in a mouse model of postoperative pain. *J Pain Res* 2013; 6:161-166.
  55. Alysandratos KD, Asadi S, Angelidou A, Zhang B, Sismanopoulos N, Yang H, Critchfield A, Theoharides TC. Neurotensin and CRH interactions augment human mast cell activation. *PLoS One* 2012; 7:e48934.
  56. Gaudenzio N, Sibilano R, Marichal T, Starkl P, Reber LL, Cenac N, McNeil BD, Dong X, Hernandez JD, Sagi-Eisenberg R, Hammel I, Roers A, Valitutti S, Tsai M, Espinosa E, Galli SJ. Different activation signals induce distinct mast cell degranulation strategies. *J Clin Invest* 2016; 126:3981-3998.
  57. Theoharides TC, Kempuraj D, Tagen M, Conti P, Kalogeromitros D. Differential release of mast cell mediators and the pathogenesis of inflammation. *Immunol Rev* 2007; 217:65-78.
  58. Moon TC, Befus AD, Kulka M. Mast cell mediators: Their differential release and the secretory pathways involved. *Front Immunol* 2014; 5:569.
  59. Carroll-Portillo A, Surviladze Z, Cambi A, Lidke DS, Wilson BS. Mast cell synapses and exosomes: Membrane contacts for information exchange. *Front Immunol* 2012; 3:46.
  60. D'Inca F, Pucillo CE. Exosomes: Tiny clues for mast cell communication. *Front Immunol* 2015; 6:73.
  61. Elishmereni M, Alenius HT, Bradding P, Mizrahi S, Shikotra A, Minaai-Fleminger Y, Mankuta D, Eliashar R, Zabucchi G, Levi-Schaffer F. Physical interactions between mast cells and eosinophils: A novel mechanism enhancing eosinophil survival in vitro. *Allergy* 2011; 66:376-385.
  62. Deng Y, Luo L, Hu Y, Fang K, Liu J. Clinical practice guidelines for the management of neuropathic pain: A systematic review. *BMC Anesthesiol* 2016; 16:12.
  63. Finnerup NB, Attal N, Haroutounian S, McNicol E, Baron R, Dworkin RH, Gilron I, Haanpää M, Hansson P, Jensen TS, Kamerman PR, Lund K, Moore A, Raja SN, Rice AS, Rowbotham M, Sena E, Siddall P, Smith BH, Wallace M. Pharmacotherapy for neuropathic pain in adults: A systematic review and meta-analysis. *Lancet Neurol* 2015; 14:162-173.
  64. Butterfield JH. Survey of aspirin administration in systemic mastocytosis. *Prostaglandins Other Lipid Mediat* 2009; 88:122-124.
  65. Aich A, Afrin LB, Gupta K. Mast cell-mediated mechanisms of nociception. *Int J Mol Sci* 2015; 16:29069-29092.
  66. Arnold LM, Schikler KN, Bateman L, Khan T, Pauer L, Bhadra-Brown P, Clair A, Chew ML, Scavone J; Pregabalin Adolescent Fibromyalgia Study Group. Safety and efficacy of pregabalin in adolescents with fibromyalgia: A randomized, double-blind, placebo-controlled trial and a 6-month open-label extension study. *Pediatr Rheumatol Online J* 2016; 14:46.
  67. Ferjan I, Lipnik-Štangelj M. Chronic pain treatment: The influence of tricyclic antidepressants on serotonin release and uptake in mast cells. *Mediators Inflamm* 2013; 2013:340473.
  68. Häuser W, Urrútia G, Tort S, Uçeyler N, Walitt B. Serotonin and noradrenaline reuptake inhibitors (SNRIs) for fibromyalgia syndrome. *Cochrane Database Syst Rev* 2013; 1:CD010292.
  69. Sugawara K, Zákány N, Hundt T, Emelianov V, Tsuruta D, Schäfer C, Klopper JE, Bíró T, Paus R. Cannabinoid receptor 1 controls human mucosal-type mast cell degranulation and maturation in situ. *J Allergy Clin Immunol* 2013; 132:182-193.
  70. Vincent L, Vang D, Nguyen J, Benson B, Lei J, Gupta K. Cannabinoid receptor-specific mechanisms to alleviate pain in sickle cell anemia via inhibition of mast cell activation and neurogenic inflammation. *Haematologica* 2016; 101:566-577.
  71. Cook J, Stith M, Sahn EE. Bullous mastocytosis in an infant associated with the use of a nonprescription cough suppressant. *Pediatr Dermatol* 1996; 13:410-414.
  72. Frydas S, Varvara G, Murrura G, Saggini A, Caraffa A, Antinolfi P, Teté S, Tripodi D, Conti F, Cianchetti E, Toniato E, Rosati M, Speranza L, Pantalone A, Saggini R, Di Tommaso LM, Theoharides TC, Conti P, Pandolfi F. Impact of capsaicin on mast cell inflammation. *Int J Immunopathol Pharmacol* 2013; 26:597-600.
  73. Guilarte M, Santos J, de Torres I, Alonso C, Vicario M, Ramos L, Martínez C, Casellas F, Saperas E, Malagelada JR. Diarrhoea-predominant IBS patients show mast cell activation and hyperplasia in the jejunum. *Gut* 2007; 56:203-209.
  74. Goral V, Kucukoner M, Buyukbayram H. Mast cells count and serum cytokine levels in patients with irritable bowel syndrome. *Hepatogastroenterology* 2010; 57:751-754.
  75. O'Sullivan M, Clayton N, Breslin NP, Harman I, Bountra C, McLaren A, O'Morain CA. Increased mast cells in the irritable bowel syndrome. *Neurogastroenterol Motil* 2000; 12:449-457.
  76. Park JH, Rhee PL, Kim HS, Lee JH, Kim YH, Kim JJ, Rhee JC. Mucosal mast cell counts correlate with visceral hypersensitivity in patients with diarrhea predominant irritable bowel syndrome. *J Gastroenterol Hepatol* 2006; 21:71-78.
  77. Vivinus-Nébot M, Dainese R, Anty R, Saint-Paul MC, Nano JL, Gonthier N, Marjoux S, Frin-Mathy G, Bernard G, Hébuterne X, Tran A, Theodorou V, Piche T. Combination of allergic factors can worsen diarrheic irritable bowel syndrome: Role of barrier defects and mast cells. *Am J Gastroenterol* 2012; 107:75-81.
  78. Di Nardo G, Barbara G, Cucchiara S, Cremon C, Shulman RJ, Isoldi S, Zecchi L, Drago L, Oliva S, Saule R, Barbaro MR, Stronati L. Neuroimmune interactions at different intestinal sites are related to abdominal pain symptoms in children with IBS. *Neurogastroenterol Motil* 2014; 26:196-204.
  79. Sohn W, Lee OY, Lee SP, Lee KN, Jun DW, Lee HL, Yoon BC, Choi HS, Sim J, Jang KS. Mast cell number, substance p and vasoactive intestinal peptide in irritable bowel syndrome with diarrhea. *Scand J Gastroenterol* 2014; 49:43-51.
  80. Cenac N, Andrews CN, Holzhausen M, Chapman K, Cottrell K, Andrade-Gordon P, Steinhoff M, Barbara G, Beck P, Bunnett NW, Sharkey KA, Ferraz JG, Shaffer E, Vergnolle N. Role for protease activity in visceral pain in irritable bowel syndrome. *J Clin Invest* 2007;

- 117:636-647.
81. Gecse K, Róka R, Ferrier L, Leveque M, Eutamene H, Cartier C, Ait-Belgnaoui A, Rosztóczy A, Izbéki F, Fioramonti J, Wittmann T, Bueno L. Increased faecal serine protease activity in diarrhoeic IBS patients: A colonic luminal factor impairing colonic permeability and sensitivity. *Gut* 2008; 57:591-599.
  82. Piche T, Barbara G, Aubert P, Bruley des Varannes S, Dainese R, Nano JL, Cremon C, Stanghellini V, De Giorgio R, Galliche JP, Neunlist M. Impaired intestinal barrier integrity in the colon of patients with irritable bowel syndrome: Involvement of soluble mediators. *Gut* 2009; 58:196-201.
  83. Barbara G, Wang B, Stanghellini V, de Giorgio R, Cremon C, Di Nardo G, Trevisani M, Campi B, Geppetti P, Tonini M, Bunnett NW, Grundy D, Corinaldesi R. Mast cell-dependent excitation of visceral-nociceptive sensory neurons in irritable bowel syndrome. *Gastroenterology* 2007; 132: 26-37.
  84. Song J, Zhang L, Bai T, Qian W, Li R, Hou X. Mast cell-dependent mesenteric afferent activation by mucosal supernatant from different bowel segments of guinea pigs with post-infectious irritable bowel syndrome. *J Neurogastroenterol Motil* 2015; 21:236-246.
  85. Buhner S, Li Q, Vignali S, Barbara G, De Giorgio R, Stanghellini V, Cremon C, Zeller F, Langer R, Daniel H, Michel K, Schemann M. Activation of human enteric neurons by supernatants of colonic biopsy specimens from patients with irritable bowel syndrome. *Gastroenterology* 2009; 137:1425-1434.
  86. Kushnir-Sukhov NM, Brittain E, Scott L, Metcalfe DD. Clinical correlates of blood serotonin levels in patients with mastocytosis. *Eur J Clin Invest* 2008; 38:953-958.
  87. Cremon C, Carini G, Wang B, Vasina V, Cogliandro RF, De Giorgio R, Stanghellini V, Grundy D, Tonini M, De Ponti F, Corinaldesi R, Barbara G. Intestinal serotonin release, sensory neuron activation, and abdominal pain in irritable bowel syndrome. *Am J Gastroenterol* 2011; 106:1290-1298.
  88. Barreau F, Salvador-Cartier C, Houdeau E, Bueno L, Fioramonti J. Long-term alterations of colonic nerve-mast cell interactions induced by neonatal maternal deprivation in rats. *Gut* 2008; 57:582-590.
  89. Dothel G, Barbaro MR, Boudin H, Vasina V, Cremon C, Gargano L, Bellacosa L, De Giorgio R, Le Berre-Scoul C, Aubert P, Neunlist M, De Ponti F, Stanghellini V, Barbara G. Nerve fiber outgrowth is increased in the intestinal mucosa of patients with irritable bowel syndrome. *Gastroenterology* 2015; 148:1002-1011.
  90. Zhang L, Song J, Hou X. Mast cells and irritable bowel syndrome: From the bench to the bedside. *J Neurogastroenterol Motil* 2016; 22:181-192.

