

Randomized Trial

Sonographic Guidance for Supraclavicular Brachial Plexus Blocks: Single vs. Double Injection Cluster Approach

Jung Ju Choi, MD, PhD¹, Hyun Jeong Kwak, MD, PhD¹, Wol Seon Jung, MD, PhD¹,
Seung Hyun Chung, MD, PhD², and Mi Geum Lee, MD, PhD¹

From: Department of Anesthesiology and Pain Medicine, ¹Gachon University, Gil Medical Center, Incheon, South Korea; ²Dongguk University Ilsan Hospital, Ilsan, South Korea

Address Correspondence:
Mi Geum Lee, MD, PhD
Department of Anesthesiology and Pain Medicine
Gachon University
Gil Medical Center
1198 Guwol-dong
Namdong-gu, Incheon 405-760,
South Korea
E-mail:
mikeum2@gilhospital.com

Disclaimer: Jung Ju Choi and Hyun Jeong Kwak contributed equally to this work.
Conflict of interest: Each author certifies that he or she, or a member of his or her immediate family, has no commercial association (i.e., consultancies, stock ownership, equity interest, patent/licensing arrangements, etc.) that might pose a conflict of interest in connection with the submitted manuscript.

Manuscript received: 11-15-2016
Revised manuscript received: 02-25-2017
Accepted for publication: 03-09-2017

Free full manuscript:
www.painphysicianjournal.com

Background: The cluster approach for supraclavicular brachial plexus block (SC-BPB) can be easily performed but may result in asymmetric local anesthetic (LA) spread. The authors hypothesized that the use of a cluster approach in each of the 2 planes would achieve better 3-dimensional LA distribution than the traditional single cluster approach.

Objectives: The purpose of the present study was to compare a double injection (DI) in 2 planes (one injection in each plane) with the traditional single injection (SI) cluster approach for ultrasound-guided SC-BPB.

Study Design: A randomized, controlled trial.

Setting: Department of Anesthesiology and Pain Medicine, Gachon University Gil Medical Center.

Methods: In the SI group (n = 18), 30 mL of LA was injected into the main neural cluster after penetrating the brachial plexus sheath laterally. In the DI group (n = 18), the needle penetrated the sheath in a downward direction at the first skin puncture, and 15 mL of LA was injected, and at the second skin puncture (behind the initial puncture site), the needle penetrated the sheath in an upward direction, and 15 mL was again injected. Ultrasound-guided SC-BPB was evaluated from immediately after the block every 5 minutes to 30 minutes by sensory and motor testing. The main outcome variables were procedural time; onset time (time for complete sensory and motor block of the median, radial, ulnar, and musculocutaneous nerves); and rate of blockage of all 4 nerves.

Results: Procedure times (medians [interquartile range]) were similar in the DI and SI groups (5.5 [4.75 – 8] vs. 5 [4 – 7] minutes, respectively; $P = 0.137$). Block onset time in the DI group was not significantly different from that in the SI group (10 [5 – 17.5] vs. 20 [6.25 – 30] minutes, $P = 0.142$). However, the rate of blockage of all 4 nerves was significantly higher in the DI group (94% vs. 67%, $P = 0.035$).

Limitations: Although the results of this study indicate LA distribution in the DI group was more evenly spread within brachial plexus sheaths than in the SI group, this was not confirmed by ultrasonography or contrast radiography.

Conclusion: The DI approach can be performed easily as single cluster approach and increases the consistency of ultrasound-guided SC-BPB over the SI approach in terms of the rate of blocking of all 4 nerves.

Key words: Brachial plexus block, corner pocket approach, cluster approach, multiple injection, supraclavicular block, ultrasound

Pain Physician 2017; 20:529-535

Ultrasound-guided supraclavicular brachial plexus block (SC-BPB) is commonly used in clinical practice to achieve generalized regional anesthesia during upper extremity surgery or for pain control. Sonographic guidance can be used to assess anatomic normality rapidly, guide the block needle safely under real-time visualization, and confirm correct distribution of local anesthetics (LAs), and thus, enhances the efficacy, speed, and safety of general anesthesia (1).

Ultrasound-guided SC-BPB is performed just above the clavicle, where the neural cluster compactly formed by the trunks or divisions of the brachial plexus are situated superolaterally to the subclavian artery (SA) (2). Many different approaches have been devised for ultrasound-guided SC-BPB, and they have different pros and cons and success rates (3-8). The corner pocket approach has a high success rate, but it is difficult to accurately position the needle tip at the junction of the first rib and SA (4). On the other hand, the cluster approach can be performed easily but may increase the risk of asymmetric LA spread (3,9).

Therefore, we hypothesized that use of the cluster approach in each of the 2 planes (referred to as the 2 plane – 2 injection approach [DI group]) would achieve better 3-dimensional distribution of LAs than the traditional single cluster approach (referred to as the 1 plane – 1 injection approach [SI group]), and that this would be reflected by a reduction in onset time and a higher rate of blockage of all 4 nerves.

METHODS

After obtaining approval from the Ethical Review Board of our hospital (GAIRB2015-44), and registering the study with the WHO International Clinical Trials Portal (NCT02505633), written informed consent was obtained from all patients. Thirty-six patients scheduled for forearm or hand surgery were enrolled in the study. Patients were aged 18 to 80 years and were of American Society of Anesthesiologists physical status (ASA) I or II. The study exclusion criteria were as follows; pre-existing neuropathy in the operated limb, ASA \geq III, coagulation disorder, known allergy to LAs, local infection at the puncture site, chronic obstructive pulmonary disease or respiratory failure, pregnancy, breast-feeding, prior surgery in the supraclavicular region, a BMI of \geq 35 kg/m², failure to cooperate, and refusal to participate (5-8).

Patients were randomized to the 1 plane – 1 injection group (the SI group, n = 18) or the 2 plane – 2 injec-

tion group (the DI group, n = 18). Randomization was performed using a computer-generated random number table (Fig. 1). Patients were not informed of group allocations. Supplemental oxygen (via a nasal cannula at 4 L/min) and standard monitoring (noninvasive blood pressure, electrocardiogram, and pulse-oximetry) were applied throughout the procedure; anxiolysis was not established.

For the procedure, each patient was positioned supine with a small roll beneath the ipsilateral shoulder and the head turned to the contralateral side. The supraclavicular region was prepared with povidone iodine solution. A 10-MHz linear probe (Zonare Medical Systems, California, USA) with a sterile plastic cover and gel were used, and the transducer was positioned parallel and immediately above the clavicle to visualize the SA and brachial plexus above the first rib or pleura.

In the SI group (Fig. 2 a – c) (9), after subcutaneously injecting 2% lidocaine (1 mL), a 22-gauge, 120-mm stimulating needle (Stimuplex insulated needle; D Plus B. Braun, Melsungen, Germany) attached to a nerve stimulator (Stimuplex HNS12; B. Braun, Melsungen, Germany) was advanced using an ultrasound in-plane approach lateral to medial. After the needle penetrated the nerve sheath, the nerve stimulator was turned on, and stimulation was started at 0.5 mA. When distal motor response in the hand was observed (even at 0.3 mA), 30 mL of LA (1.5% lidocaine mixed with 1:200,000 epinephrine) was injected slowly with intermittent negative aspiration under direct ultrasound visualization of LA spread while ensuring expansion of the brachial plexus within the sheath. If paresthesia was elicited during the procedure, the needle was withdrawn by 2 to 3 mm, and the anesthesiologist ensured no further paresthesia was elicited before injecting the LA.

In the DI group (Fig. 2 d – f), subcutaneous LA injection was performed in a fan-like manner because 2 skin punctures were required. A 22-gauge, 120 mm stimulating needle attached to a nerve stimulator was then advanced using an ultrasound in-plane approach lateral to medial. After the needle penetrated the nerve sheath in a downward direction, the nerve stimulator was turned on, and the stimulation current was started at 0.5 mA. When distal motor response in the hand was observed (even at 0.3 mA), 15 mL of LA was injected. After making the second skin puncture and moving the probe behind the initial puncture site, the nerve sheath was penetrated with the needle in the upward direction, and then 15 mL of LA was injected in the same manner. The total volume of LA administered was iden-

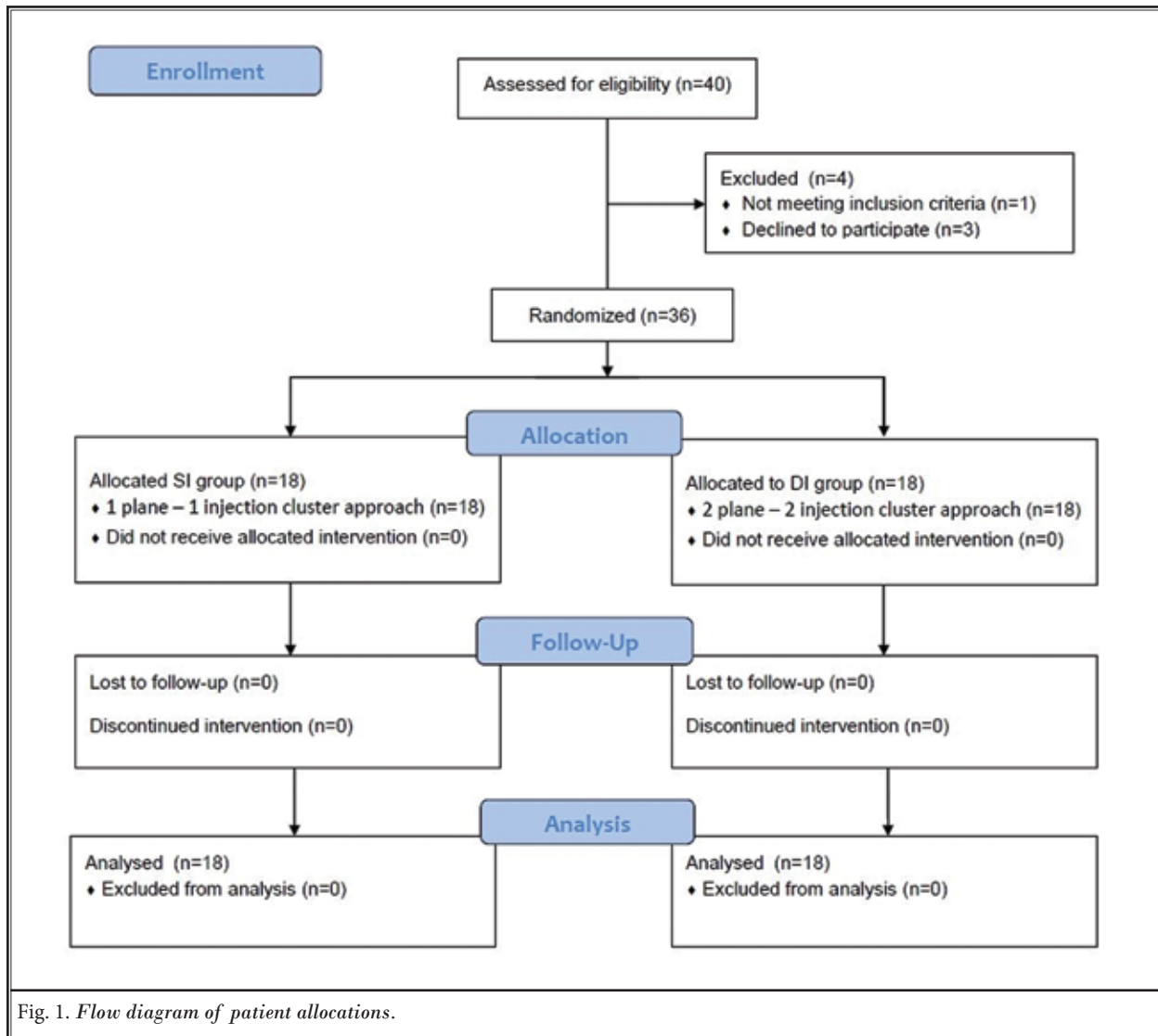


Fig. 1. Flow diagram of patient allocations.

tical in the SI and DI groups. All blocks were performed by an anesthesiologist with experience of more than 60 cases, and were supervised by the co-authors who had experience in both techniques.

Brachial plexus blockade was evaluated immediately after LA injection every 5 minutes for 30 minutes by an independent observer unaware of group allocations. Sensory block was evaluated using an alcohol swab on dermatomes of the ulnar (fifth finger), median (palmar aspect of the second finger), radial (dorsum of the hand between the thumb and second finger), and musculocutaneous (lateral aspect of forearm) nerves (5). Patients quantified the level of sensory block using a 10-point scale (0 = no sensation to cold, 10 = normal

sensation). Complete sensory block was defined as a score of 0 in each nerve dermatome. Motor block was evaluated using a 3-point scale where 0 = no block, 1 = paresis, reduced force compared with the contralateral arm, and 2 = paralysis, inability to overcome gravity, which was applied to the whole arm (5). Accordingly, complete motor block was defined as a score of 2. After completing the evaluation, the patient was moved to the operating room for surgery.

Procedure time was defined as time from probe positioning to completion of LA injection (9). Onset time was defined as the time required to obtain full sensory and motor block of median, ulnar, radial, and musculocutaneous nerves (3). Total anesthesia-related

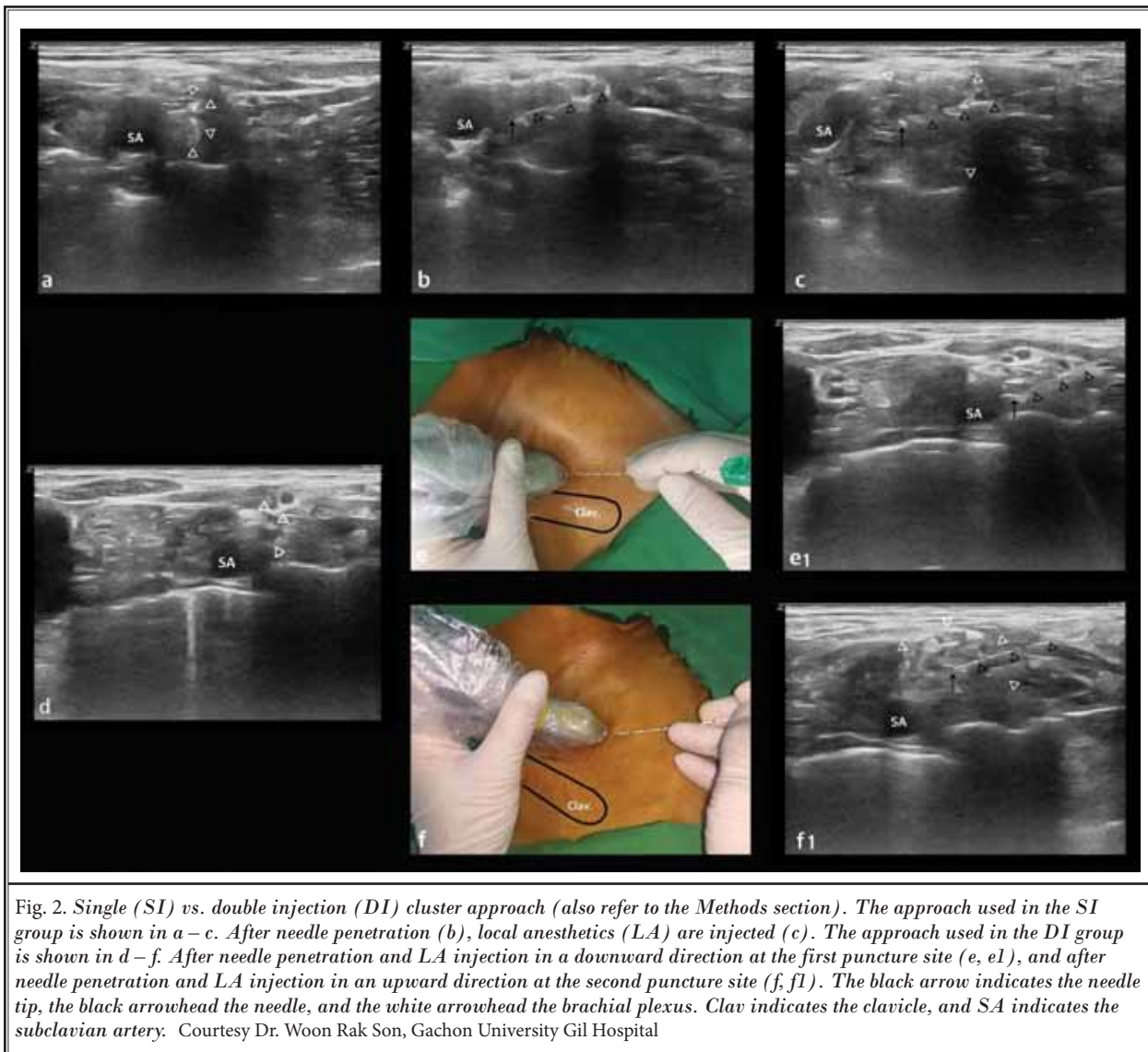


Fig. 2. Single (SI) vs. double injection (DI) cluster approach (also refer to the Methods section). The approach used in the SI group is shown in a – c. After needle penetration (b), local anesthetics (LA) are injected (c). The approach used in the DI group is shown in d – f. After needle penetration and LA injection in a downward direction at the first puncture site (e, e1), and after needle penetration and LA injection in an upward direction at the second puncture site (f, f1). The black arrow indicates the needle tip, the black arrowhead the needle, and the white arrowhead the brachial plexus. Clav indicates the clavicle, and SA indicates the subclavian artery. Courtesy Dr. Woon Rak Son, Gachon University Gil Hospital

time was defined as the sum of procedure and onset times (3). The case which even one nerve is not blocked, we did not include it in calculating of onset time and total anesthesia-related time. Anesthesia grade was assessed after the end of surgery using a 4-point scale, where: excellent = when surgery was completed with only brachial plexus block; good = complete analgesia, but when a patient complained about position, necessitating intravenous (IV) medication (< 100 µg fentanyl and midazolam 5 mg), insufficient = when IV medication of ≥ 100 µg fentanyl and midazolam 5 mg, or propofol infusion (25 – 80 µg/kg/min) or additional local injection at operative site was required, but the surgery was finished successfully; and failure = when

general anesthesia was required to complete surgery (10). When a patient requested sedation during the surgery, regardless of anesthetic grade, midazolam 2 – 5 mg was administered as decided by an anesthesiologist unaware of group allocations. Patients were asked to assess procedure-related pain immediately after block using a 10-cm visual analog scale (VAS) (0 cm = no pain, 10 cm = worst imaginable pain) (3,6), and to provide details of complications on the day after surgery by an independent observer also unaware of group allocations.

In a preliminary study, ulnar nerve sparing occurred in one of 5 SI treated patients, but in 0 of 5 DI treated patients. Sixteen patients were required per group for an α value of 0.05 and a power of 90%, and thus, 36

patients were recruited to cope with a possible dropout rate of 10%.

Results are presented as means ± standard deviations, medians [interquartile ranges], or as numbers (percentages). Statistical analyses were performed using SPSS Ver. 12.0 for Windows (SPSS Inc., Chicago, IL). The Chi-squared test was used to analyze categorical data, and the student's unpaired t-test to analyze continuous data. *P* values of < 0.05 were considered statistically significant.

RESULTS

Patient demographic data are shown in Table 1. No significant differences were observed between the 2 groups.

Data regarding ultrasound-guided SC-BPB are shown in Table 2. Procedure times (medians [interquartile ranges]) for the DI and SI groups were similar (5.5 [4.75 – 8] vs. 5 [4 – 7] minutes, *P* = 0.137). Block onset times in the DI and SI groups were not significantly different (10 [5 – 17.5] vs. 20 [6.25 – 30] minutes, *P* = 0.142). However, the rate of blockage of all 4 nerves was significantly higher in the DI group (94% vs. 67%, *P* = 0.035). Regarding nerve territory missed cases, 6 cases in the SI group were ulnar nerve spared (2 good cases, 3 insufficient cases, one failed case), and one case in the DI group was median nerve spared (one excellent case).

The proportions of patients with a complete sensory block and a complete motor block at each evaluation time (up to 30 minutes post-block) were similar in the 2 groups. However, the ulnar nerve was blocked significantly faster in the DI group (Fig. 3).

No vascular or pleural puncture occurred during the procedures, and no patient complained of tourniquet-related pain. Complications were chest tightness (one case), nausea (one case), and paresthesia (one case) in the SI group, and shivering (2 cases), bruise at injection site (one case), and paresthesia (one case) in the DI group. No paresthesia remained at one-week follow-up chart reviews.

Table 1. Patient characteristics in the 2 groups.

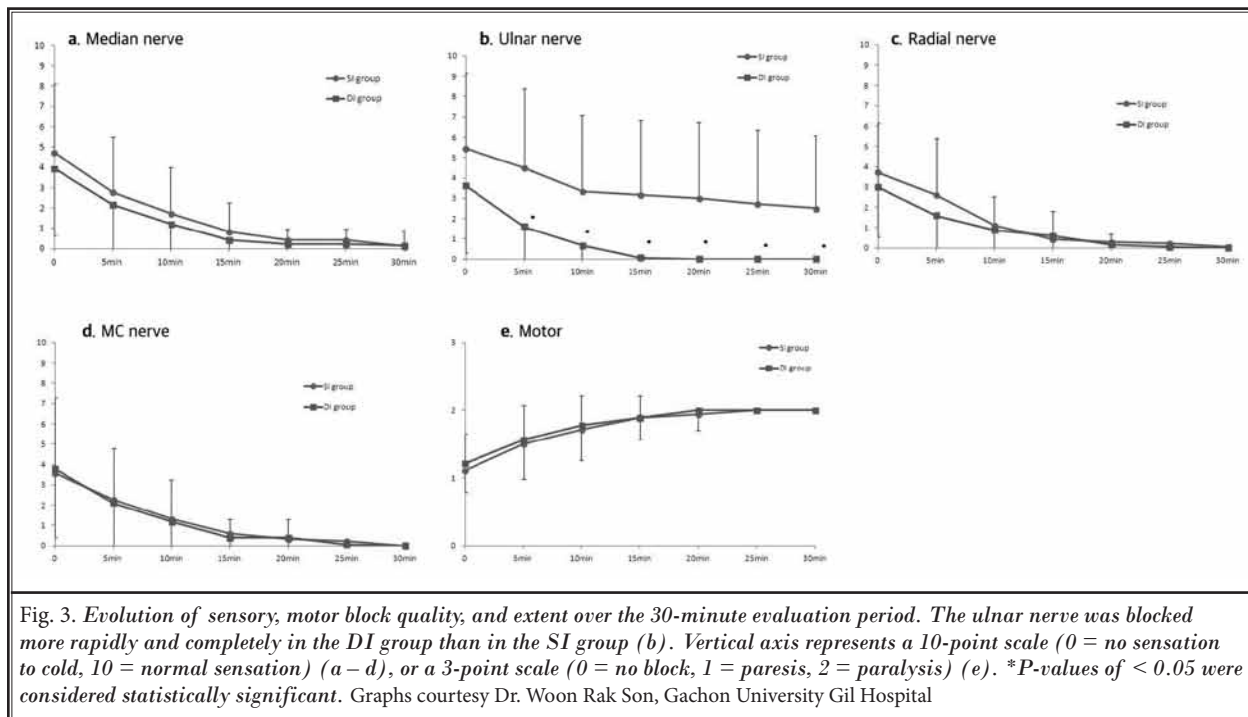
	SI group (n = 18)	DI group (n = 18)	P-value
Age (yr)	50 ± 17	49 ± 19	0.912
Gender (M/F)	12/6	10/8	0.494
Height (cm)	166.7 ± 12.6	165.1 ± 10.5	0.669
Weight (kg)	66.6 ± 16.0	66.2 ± 17.2	0.937
ASA PS class (I/II)	10/8	13/5	0.298

Values are means ± SDs, or numbers of patients. SI group: patients that underwent a single injection (1 plane – 1 injection), DI group: patients that underwent double injection (2 plane – 2 injection). ASA PS: American Society of Anesthesiologists physical status.

Table 2. Data on supraclavicular brachial plexus blocks.

	SI group (n = 18)	DI group (n = 18)	P-value
Type of surgery			
hand/wrist/forearm/elbow	16/2/0/0	7/9/1/1	0.019
Time:			
Procedure time (min)	5 [4 – 7]	5.5 [4.75-8]	0.137
Onset time (min)	20 [6.25 – 30]	10 [5 – 17.5]	0.142
Total anesthesia-related time (min)	24 [10.25 – 35]	19 [12 – 22.5]	0.276
Rate of all 4 nerves blocked (n)	12 (67%)	17 (94%)	0.035
Anesthesia grade			
Excellent/good/insufficient/fail	11/3/3/1	17/1/0/0	0.099
Sedative/analgesic drugs			
Fentanyl (n)	7	1	0.016
Midazolam (n)	12	9	0.310
VAS during block	0 [0 – 0.25]	0 [0 – 1]	0.471

Values are medians [interquartile ranges] or numbers of patients. SI group: patients that underwent a single injection (1 plane – 1 injection), DI group: patients that underwent double injection (2 plane – 2 injection). Procedure time – time from probe positioning to the completion of LA administration, Onset time – time required to obtain full sensory and motor block of median, ulnar, radial, and musculocutaneous nerves, Total anesthesia-related time – the sum of procedure time and onset time, VAS – visual analog scale (0 cm = no pain, 10 cm = worst imaginable pain).



DISCUSSION

Our results show the DI technique could improve quality of nerve block without significantly increasing procedure time as compared with the SI technique. In addition, the ulnar nerve territory, which is difficult to block completely even using a corner pocket technique (11-14), was blocked in all 18 patients in the DI group.

In the present study, we focused on paths of the brachial plexus following the SA in the posterior direction. When we moved the probe posteriorly to the SA, we were able to visualize the different shapes of the brachial plexus sequentially. For the DI approach, we first injected LA in one ultrasound plane, and then visualized the extended, well-defined brachial plexus sheath surrounded by LA in a second plane. Furthermore, because the second LA injection was performed easily, procedure times were similar in the 2 study groups.

In the present study, group onset times were not different, presumably because of large standard deviations. However, we consider increased block consistency, represented by the rate of blockage of all 4 nerves, is as meaningful as a reduced onset time, because failure to block one nerve territory can result in failed anesthesia if surgery is conducted in an area innervated by an unblocked nerve.

Several previous comparative studies on single versus multiple injections in one plane have been performed using ultrasound-guided SCBPB (5-8). We believe that LA was better distributed within the brachial plexus sheath in the DI group than in the SI group, but suggest further studies be conducted to compare the DI approach and other multiple injections in one plane or the corner pocket approach. Techasuk et al (7) showed that a novel targeted intracluster injection approach provides rapid onset times and 100% success, but the detection of all satellite neural clusters adjacent to the main cluster is not an easy matter, especially for novices. However, the described DI approach can be performed as easily as the single cluster approach.

A number of study limitations should be considered. First, one anesthesiologist performed all blocks in the present study, and thus, was not blinded to group allocations. However, the sensory and motor test evaluations were performed by an independent blinded observer. Therefore, we believe unintentional bias toward positive results had little impact on overall results (15). Second, types of surgery were significantly different in the 2 study groups. However, group anesthesia grades were similar, which suggests this difference did not affect results. Third, although we presumed LA distribution would be more evenly spread within the sheath of the brachial plexus in the DI group, we did not con-

firm this by ultrasonography of contrast radiography. Fourth, the generalizability of our results may be limited because of the small number of patients recruited ($n = 36$), and thus, we suggest a larger scale study be conducted to confirm our findings.

The DI approach needs 2 skin punctures. Because of the fan-like subcutaneous LA injection used at the first skin puncture, patients did not perceive the second skin puncture, and thus, procedural-related pain in the DI group (VAS) was no greater than in the SI group.

Penetrating the plexus sheath during ultrasound-guided SC-BPB does not mean an intraneural injection. This intrafascial injection produces an increase in the diameter of the compartment, which results in extraneural connective tissue expansion, and not intraneural injection (16,17). In this study, to confirm needle posi-

tion, we used a nerve stimulator combined with ultrasound, as has been previously described (2,9). Stimulation currents were set at 0.3 to 0.5 mA and a clearly visible twitch of the hand was considered adequate response (18,19). Stimulation currents of ≤ 0.2 mA were not applied for preventing intraneural injection (16,20). Moreover, in cases of insufficient block, no additional block was performed in the distal nerve territory because additional block in an already anesthetized nerve can cause nerve injury, regardless of the use of ultrasound (11).

In conclusion, the described DI approach can be performed as easily as the single cluster approach and increases the consistency of ultrasound-guided SC-BPB over the SI approach in terms of the rate of blocking of median, radial, ulnar, and musculocutaneous nerves.

REFERENCES

1. Sites BD, Brull R. Ultrasound guidance in peripheral regional anesthesia: Philosophy, evidence-based medicine, and techniques. *Curr Opin Anaesthesiol* 2006; 19:630-639.
2. Perlas A, Lobo G, Lo N, Brull R, Chan VW, Karkhanis R. Ultrasound-guided supraclavicular block: Outcome of 510 consecutive cases. *Reg Anesth Pain Med* 2009; 34:171-176.
3. Tran DQ, Munoz L, Russo G, Finlayson RJ. A trick shot to the corner pocket. *Reg Anesth Pain Med* 2008; 33:503-504.
4. Samet R, Villamater E. Eight ball, corner pocket for ultrasound-guided supraclavicular block: High risk for a scratch. *Reg Anesth Pain Med* 2008; 33:87.
5. Roy M, Nadeau MJ, Côté D, Levesque S, Dion N, Nicole PC, Turgeon AF. Comparison of a single- or double-injection technique for ultrasound-guided supraclavicular block: A prospective, randomized, blinded controlled study. *Reg Anesth Pain Med* 2012; 37:55-59.
6. Tran DQ, Muñoz L, Zaouter C, Russo G, Finlayson RJ. A prospective, randomized comparison between single- and double-injection, ultrasound-guided supraclavicular brachial plexus block. *Reg Anesth Pain Med* 2009; 34:420-424.
7. Techasuk W, González AP, Bernucci F, Cupido T, Finlayson RJ, Tran DQ. A randomized comparison between double-injection and targeted intracenter-injection ultrasound-guided supraclavicular brachial plexus block. *Anesth Analg* 2014; 118:1363-1369.
8. Arab SA, Alharbi MK, Nada EM, Alrefai DA, Mowafi HA. Ultrasound-guided supraclavicular brachial plexus block: Single versus triple injection technique for upper limb arteriovenous access surgery. *Anesth Analg* 2014; 118:1120-1125.
9. Chan VW, Perlas A, Rawson R, Odukoya O. Ultrasound-guided supraclavicular brachial plexus block. *Anesth Analg* 2003; 97:1514-1517.
10. Rucci FS, Barbagli R, Pippa P, Boccaccini A. The optimal dose of local anaesthetic in the orthogonal two-needle technique. Extent of sensory block after the injection of 20, 30 and 40 mL of anaesthetic solution. *Eur J Anaesthesiol* 1997; 14:281-286.
11. Meco BC, Ozcelik M, Oztuna DG, Armançil M, Guclu CY, Turhan SC, Okten F. Can we gain an advantage by combining distal median, radial and ulnar nerve blocks with supraclavicular block? A randomized controlled study. *J Anesth* 2015; 29:217-222.
12. Brull R, Chan VW. The corner pocket revisited. *Reg Anesth Pain Med* 2011; 36:308.
13. Morfey DH, Brull R. Finding the corner pocket: Landmarks in ultrasound-guided supraclavicular block. *Anaesthesia* 2009; 64:1381.
14. Sadowski M, Tuřaza B, Lysenko L. Re-naissance of supraclavicular brachial plexus block. *Anaesthesiol Intensive Ther* 2014; 46:37-41.
15. Choi S, McCartney CJ. Evidence base for the use of ultrasound for upper extremity blocks: 2014 update. *Reg Anesth Pain Med* 2016; 41:242-250.
16. Bigeleisen PE, Moayeri N, Groen GJ. Extraneural versus intraneural stimulation thresholds during ultrasound-guided supraclavicular block. *Anesthesiology* 2009; 110:1235-1243.
17. Morfey D, Brull R. Ultrasound-guided supraclavicular block: What is intraneural? *Anesthesiology* 2010; 112:250-251.
18. Jeon DG, Kim WI. Comparison of a supraclavicular block showing upper arm twitching response with a supraclavicular block showing wrist or finger twitching response. *Korean J Anesthesiol* 2010; 58:464-467.
19. Haleem S, Siddiqui AK, Mowafi HA, Ismail SA, Ali QA. Nerve stimulator evoked motor response predicting a successful supraclavicular brachial plexus block. *Anesth Analg* 2010; 110:1745-1746.
20. Franco CD, Domashevich V, Voronov G, Rafizad AB, Jeleu TJ. The supraclavicular block with a nerve stimulator: To decrease or not to decrease, that is the question. *Anesth Analg* 2004; 98:1167-1171.

