

Anatomic Assessment

e 3D Morphometric Analysis of Normal Sacroiliac Joints: A New Classification of Surface Shape Variation and the Potential Implications in Pain Syndromes

Mary Kristen Jesse, MD^{1,2}, Christopher Kleck, MD², Adam Williams, MD¹, Brian Petersen, MD³, Deborah Glueck, PhD⁴, Kimberly Lind, PhD⁴, and Vikas Patel, MD²

From: ¹Department of Radiology, University of Colorado, Aurora, CO; ²Department of Orthopedics, University of Colorado, Aurora, CO; ³Inland Imaging, Providence Health, Spokane, WA; ⁴Colorado School of Public Health, University of Colorado, Aurora, CO

Address Correspondence:
Mary Kristen Jesse, MD
University of Colorado Hospital,
Department of Radiology
Academic Building 1
12631 East 17th Ave, Room 2413
Aurora, CO 80045
E-mail:
mary.jesse@ucdenver.edu

Disclaimer: There was no external funding in the preparation of this manuscript.

Conflict of interest: Each author certifies that he or she, or a member of his or her immediate family, has no commercial association (i.e., consultancies, stock ownership, equity interest, patent/licensing arrangements, etc.) that might pose a conflict of interest in connection with the submitted manuscript.

Manuscript received: 10-27-2016

Revised manuscript received:
12-13-2016

Accepted for publication:
12-30-2016

Free full manuscript:
www.painphysicianjournal.com

Background: Normal sacroiliac (SI) joints vary widely in shape, and it is unclear whether SI joint morphology plays a role in the development of pain. To answer this question, we used 3D-CT surface rendering to image healthy study participants and used the resulting images to develop a classification system for SI joint morphology. In a case-control study comparing healthy research participants to patients with SI pain, we assessed whether the classification of SI joint morphology was associated with pain.

Objectives: We aimed to define normal variation in area and shape of the synovialized SI joint. We also aimed to determine interactions between joint area and shape and SI pain in men and women.

Study Design: A retrospective cohort study

Setting: University hospital tertiary care center.

Methods: We conducted a retrospective case-control study. We acquired 3D-CT surface rendered images of the SI joint in 223 normal controls and 34 patients with SI pain syndrome. We measured the sacral and iliac surface areas and performed morphologic 3D assessment of both articular surfaces. We classified SI joints into 3 types based on morphology (types one, 2, and 3). We used descriptive statistics to provide a reference standard for normal SI joints. We used multivariate models to assess whether articular surface area differed between study participants with and without SI pain. We also assessed the association between morphology type and the presence of pain.

Results: Sacral and iliac surface areas differ by participant gender. Sacral and iliac surface area was associated with SI joint pain in both men ($P = 0.0007$) and in women ($P = 0.02$). In women ($P = 0.04$), but not in men ($P = 0.11$), joint shape was associated with pain.

Limitations: A retrospective study may create potential for misclassification bias if SI joint symptoms/histories were present but not well-documented in the electronic medical record. A lack of clinical standardization in the pre-procedural assessment of SI joint pain via provocative maneuvers (FABER, etc.) is also a limitation.

Conclusion: Our study provides insight into the association between shape and joint surface area and SI joint pain. Further, prospective studies will allow us to determine the role of joint shape and surface area in the patho-etiology of SI joint pain, and thus provide information for patients and physicians about prevention or treatment.

Key words: Sacroiliac joint, spine pain, 3D reformation, SI joint area, SI joint shape, SI joint pain syndrome

Pain Physician 2017; 20:E701-E709

The sacroiliac (SI) joint is a diarthroidal auricular shaped joint between the sacrum and the ilium that serves as a means for bipedal movement. The SI joint's ability to transfer axial load from the lower appendicular skeleton to the spine (1-6) is based largely on diffusion through subtle bimodal rotational motion termed nutation (6-11).

Given the critical role in stability of the pelvis and load-bearing of the entire upper body, the SI joint is susceptible to dysfunction and is thought to be responsible for a large number of low back and leg pain cases (12-13). While several studies have found predisposing surgical, behavioral, and developmental factors in the development of SI joint pain (13-18), no studies to date have explored associations between the underlying morphology and area of the SI joint, synovialized surface, and SI joint pain. In our study, through the use of 3D-CT surface rendering, we evaluate the variation in SI joint surface morphology and surface area in control patients and SI joint pain patients, with the goal of providing a novel classification system of normal anatomic variations in surface morphology. We further applied that data to a subset of SI joint pain patients to determine if certain SI joint morphologies predispose to the development of SI joint pain syndromes.

METHODS

Our retrospective case-control study was comprised of patients with and without SI joint pain from a single-center hospital. This study was reviewed by our institutional review board and deemed exempt. Data from a total of 370 patients were abstracted from electronic medical records. The control group was randomly selected from a subset of patients who underwent non-contrast CT scans in the emergency department for abdominal pain, and comprised of 300 patients before exclusion. The SI joint pain group comprised of 70 patients who underwent CT-guided SI joint anesthetic and steroid injections at our institution. SI joint injections were performed using a standardized technique under CT guidance. Using image guidance, the intraarticular portion of the SI joint was accessed with a 22G spinal needle. Following image-confirmed access to the SI joint, 1mL Celestone (6mg/mL) and 1mL 0.5% ropivacaine anesthetic was instilled in each joint. Patients were included in the pain group if they had post-injection pain relief, measured using a visual analog scale (VAS) and defined as greater than 3 points improvement in the VAS. CT slice thickness of less than 2mm and imaging through the entire SI joint was required for in-

clusion in order to ensure adequate resolution for 3D reconstruction. Patients in the control group were excluded if they had complaints of lower back pain or hip pain at the time of the CT scan. Patients in both the control group and pain group were excluded from the study if they had a history of previous lumbar or thoracic fusion procedures, inflammatory/seronegative arthropathy, history of pelvic trauma, or surgery. Imaging exclusion criteria that applied to both groups included patients with transitional segmentation, SI joint ankylosis, osteoporosis, or SI degenerative disease. Osteoporotic patients were excluded from both groups given the resulting suboptimal visualization of the bone on 3D surface rendered images. Potential cases were further excluded based on the absence of pain relief after SI joint injection (defined as 3 or less improvement in VAS) under the assumption that pain was not truly SI joint mediated.

The SI joints of each patient were reconstructed in 3D format using TeraRecon AquariusNET software (Foster City, CA). The SI joints were virtually disarticulated using the TeraRecon manual subtraction technique to obtain en face 2D images of the sacral and iliac SI joint articulating surfaces. Using the 2D images of the synovialized sacral and iliac portions of the SI joint, measurements of the areas (mmsq) of both the sacral and iliac sides of the SI joint were performed in each patient by 2 radiologists with 4 and 7 years of experience, as well as a trained postgraduate in biomedical sciences.

Investigation of the 2D synovialized SI joint surface revealed variable shape morphologies that were visually classified into 3 types defined as the following: type one "scone-shaped," type 2 "auricle-shaped," and type 3 "crescent-shaped". Upon visually recognizing these distinct morphologies, we then aimed to operationalize the identification of these morphologies by evaluating an "alpha-angle" corresponding to each shape. The alpha-angle was defined as the relative width of the SI joint at the maximum axis of nutation (sacral genu), approximately at the level of S2. Calculation of the alpha-angle is illustrated in Fig. 1.

Quantification of the angles led to the identification of an alpha-angle cut-off point for each morphology type. Type one was defined by an alpha-angle $> 160^\circ$; type 2 was defined by an alpha-angle of 130° – 160° ; and type 3 was defined by an alpha-angle $< 130^\circ$ (Fig. 2).

Surface area measurements and surface morphology assessments were subsequently performed in the subset of SI joint pain patients. SI joint pain distribu-

tion was bilateral, left, or right and was fairly equally distributed amongst patients.

Statistical Analysis

We used 2 datasets to conduct the analysis. The full dataset contained all the data from all the study participants. The sampled dataset contained one joint (both sacral and iliac surfaces) from each study participant. The joint from the normal control was sampled at random from the 2 joints. From the study participants with SI joint pain, we took the single affected joint if the pain was unilateral, and sampled one of the 2 affected joints at random if the pain was bilateral. We note in each case whether we used the sampled or full dataset.

All analyses were stratified by gender, since human pelvic anatomy differs so greatly by gender. We used a type one error rate of 0.05 for all tests, unless otherwise specified.

Using the full dataset, we calculated descriptive statistics for all SI joint outcomes for the healthy normal study participants, including means, standard deviations, medians, and ranges for continuous variables, as well as frequencies for categorical variables. For study participants with measurements on both the left and right SI joints, we used the Stuart-Maxwell test for marginal homogeneity (14) to assess agreement between joint shape category between the right and left sides. We used a general linear multivariate model and the sampled dataset to evaluate the association between the synovial surface areas of the sacrum, ilium, and pain, and to evaluate whether the side of the study participant where the joint was located affected the association. For the multivariate model, each study participant contributed 2 outcomes: one sacral area and one iliac area. As predictors, we fit indicator variables for case status and side on which the joint was located (left or right). We used a planned sequence of hypothesis tests to assess, in order, the contributions of side and presence of pain. In the final, best fitting model, which had case status as the sole predictor, we evaluated the case by joint surface interaction. In the sampled dataset, a Cochran-Mantel-Haenszel test of general association was used to evaluate the association between joint shape category and pain. In the

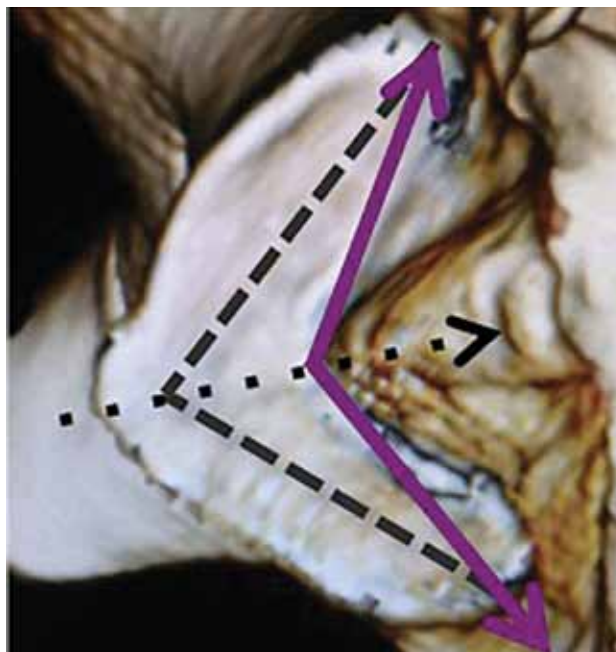


Fig. 1. *Alpha-angle measurement for SI joint morphologic classification.*

The alpha-angle (solid line) was defined as the relative width of the SI joint at the maximum axis of nutation (sacral genu). To calculate the alpha-angle, 2 lines are drawn along the axis of the anterior and posterior limbs of the SI joint articular surface (dashed lines). Next, a line bisecting the resultant angle is drawn to estimate the point of maximum nutation on an anterior-posterior axis (dotted line). The alpha-angle is formed by the 2 lines that originate from the midpoints of the distal aspects of the anterior and posterior limbs, which intersect at the site of maximum nutation on the posterior aspect of the SI joint (solid line).

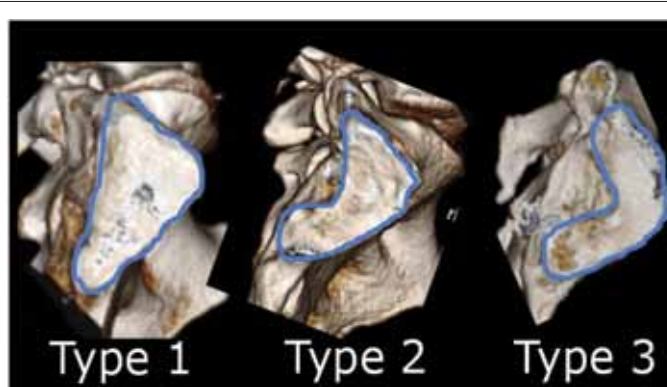


Fig. 2. *Sacroiliac joint morphologic classification. Representation of the Type 1 (scone-shaped), Type 2 (auricle-shaped), and Type 3 (crescent-shaped) sacroiliac joint morphology.*

sampled dataset, to evaluate the association between SI joint shape category and synovial surface area, we fit general linear univariate models with the synovial surface area as the outcome and indicator variables for the 3 shape categories as predictors. We fit 4 such models (2 for men and 2 for women) with outcomes of iliac and sacral surface area respectively. For each model, adopting an alpha-spending approach, we conducted the ANOVA test for no difference between the categories on the outcome of synovial surface area at the $\alpha = 0.04$ level, and then the step-down tests for no difference between morphology categories one and 2, and categories 2 and 3 at the $\alpha = 0.01/2$ level.

RESULTS

CT scans from 300 control patients and 70 case patients were reviewed. After exclusion, 223 patients without SI

joint pain (controls; 129 women and 94 men, mean age of 43 years old, ranging from 18 – 70 years old), and 34 patients with SI joint pain (cases; 27 women and 7 men, mean age of 45 years old) were included in the study and subsequently analyzed.

Normal Control Analysis

Descriptive statistics for sacral and iliac articular surface areas in study participants without SI pain are presented in Table 1.

In the joint shape analysis, type 2 was the most common shape observed in the control sample, with a right/left frequency of 72%/68%, respectively. Type 2 joints were slightly more common in men (74%) than in women (67%). Types one and 3 were not observed as frequently, but together comprised almost one third of all SI joints included in this study. There was a similar distribution of shape type in men and women (Table 2).

Sacral and iliac surface areas did not vary significantly by joint shape category in women or in men ($P > 0.05$ for each).

Table 3 compares the morphology types for each joint for the 197 patients in which joint shape was assessed for both the right and left side. For these 197 patients, the proportions of articular surface shape types in the right joint are not statistically unequal to the proportion of articular surface shape types in the left joint ($P = 0.3884$).

SI Joint Area and Pain

The results of the models testing the association between synovial surface area and SI joint pain stratified by gender are displayed in Table 4. In women and men, there were no significant 3-way interactions between side, pain, and surface ($P = 0.10$ and $P = 0.18$, respectively), nor 2-way interactions between side and pain ($P = 0.96$ and $P = 0.79$, respectively), nor between side and surface ($P = 0.23$ and $P = 0.07$, respectively), nor was there a significant main effect of side ($P = 0.45$ and $P = 0.79$, respectively).

There was a significant interaction between surface area and pain in both women ($P = 0.04$) and men ($P = 0.00008$). This interaction is due to pain cases having larger sacral and larger iliac areas compared to controls (Table 4).

SI Joint Shape and Pain

In women (Table 5), there was a significant

Table 1. Sacral and iliac articular surface area measurements (mmsq) in normal SI joints.

	Right Sacral Area	Left Sacral Area	Right Iliac Area	Left Iliac Area
Females (n = 105 sacrum, n = 104 iliac)				
Range	799 – 1732	742 – 1813	725 – 1740	713 – 2073
Mean (SD)	1189.2 (216.5)	1197.5 (214.2)	1176.9 (216.5)	1198.4 (237.6)
Median	1171	1173	1160	1210.5
Quartile 1	1026	1018	1025	1012
Quartile 3	1346	1380	1329.5	1347.5
Males (n = 71 sacrum, n = 72 iliac)				
Range	655 – 1883	521 – 1833	725 – 2102	560 – 1915
Mean (SD)	1319.9 (279.2)	1315.3 (268.2)	1328.2 (289.1)	1328.6 (278.1)
Median	1329	1323	1305.5	1338
Quartile 1	1135	1124	1124	1155.5
Quartile 3	1519	1501	1573.5	1530

Table 2. Frequency analysis of SI joint anatomy shape classification.

Shape Category	Side	n	Frequency (%)	Gender	n	Frequency (%)
Type 1	Right	29	14.1%	Female	35	14.5%
	Left	32	15.5%	Male	26	15.1%
Type 2	Right	149	72.3%	Female	163	67.3%
	Left	141	68.0%	Male	127	73.8%
Type 3	Right	28	13.6%	Female	44	18.2%
	Left	33	16.0%	Male	19	11.0%

association between the presence of SI joint pain and joint shape category according to the Cochran Mantel Haenszel test ($P = 0.04$). The Cochran-Mantel-Haenszel P -value reflects a shift in the distribution of joint shapes among cases. Roughly 32% of those with type 3 have SI pain, compared to 5% of those with type one and 17.5% of those with type 2. In men, there was not a significant association between the presence of SI joint pain and joint shape category ($P = 0.11$).

Joint Shape and Synovial Surface Area

The results for the estimates and P -values produced by the linear regression model, evaluating the association between synovial surface area and joint shape stratified by gender, are presented in Table 6. For gender, iliac, and sacral surfaces there was no association between surface area and joint shape category.

DISCUSSION

The SI joint is thought to be an under diagnosed cause of low back pain and is currently proposed to cause between 15–25% of axial low back pain cases (15,19-21).

Table 3. Right vs. left SI joint morphology on complete cases.

		Left Joint Morphology		
		T1	T2	T3
Right Joint Morphology	T1	19	10	0
	T2	13	115	15
	T3	0	9	16

Stuart-Maxwell Test for Marginal Homogeneity $P = 0.3884$

*Complete cases: patient had both right and left SI joint measurements on record

Table 4. Synovial surface area and SI pain by gender.

	Parameter Estimate (95% Confidence Interval)	Standard Error	ndf	ddf	F Value	P Value
Females (n = 146)						
Side*pain			2	141	0.74	0.4797
Side			2	142	0.54	0.5863
Surface area*pain			2	143	3.94	0.0217
Sacrum (pain)	1283.50 (1194.71 – 1372.29)	44.92				
Sacrum (no pain)	1178.15 (1136.82 – 1219.48)	20.91				
Iliac (pain)	1306.00 (1211.39 – 1400.61)	47.87				
Iliac (no pain)	1164.10 (1120.06 – 1208.14)	22.28				
Males (n = 93)						
Side*pain			2	88	0.99	0.3767
Side			2	89	1.41	0.2499
Surface area*pain			2	90	7.96	0.0007
Sacrum (pain)	1640.29 (1434.46 – 1846.11)	103.62				
Sacrum (no pain)	1315.74 (1257.02 – 1374.47)	29.56				
Iliac (pain)	1523.71 (1322.07 – 1725.36)	101.51				
Iliac (no pain)	1335.03 (1277 – 1392.56)	28.96				

Table 5. SI pain and joint shape category by gender.

	Shape 1	Shape 2	Shape 3	P Value
Females (n = 144)				
Case, frequency (column %)	1 (5.0%)	16 (17.2%)	10(32.3%)	0.04
Control, frequency (column %)	19 (95.0%)	77 (82.8%)	21 (67.7%)	
Males (n = 87)				
Case, frequency (column %)	0	5 (7.8%)	2 (25.0%)	0.11
Control, frequency (column %)	15 (100%)	53 (92.2%)	6 (75.0%)	

Recent studies have implicated factors in the pre-disposition to develop SI joint pain including gait abnormalities, prolonged exercise, scoliosis, pregnancy, and lumbar fusions to the sacrum (13-18,22-24). What studies have yet to explore is if the basic anatomic size and shape of the SI joint may play a role in the development of SI joint pain and dysfunction. The only study noting variability in the actual shape of the articular surface evaluated 26 cadaveric specimens with the primary goal of defining the small axial joint (6). In this study, the authors mention some intra and inter-personal variability in the morphology of the SI joint, but no classification or further description was assigned to this data.

Our method of using 3D-CT reconstruction of the SI joint surface allows for the evaluation of a large number of joints in a non-invasive fashion, increasing the generalizability of our study. Using this method we identified morphologic SI joint surface variability similar to prior authors (6), but with a larger sample size we were able to further analyze this data and devised a classification system to describe these morphologies.

Unlike previous SI joint studies that have focused on external causes of SI joint pain, we attempted to determine if an association exists between SI joint architectural morphology and the presence of SI joint pain. In our study, through 3D-CT imaging, we identified 3 predominant SI joint sacral articular surface morphologies (types 1, 2, and 3) and applied these types to a sub-

set of SI joint pain patients. We were able to establish a defined distribution of joint shape in the control patients in which the type 2 (auricular) joint morphology presented with the highest frequency in both women and men without joint pain, and it was set as the "normal" joint morphology. In the pain population, we found a similar preponderance of the type 2 surface morphology but noted a relatively high percentage of type 3 morphologies and a low percentage of type one morphology compared to the control group. We postulated that significance was found in women but not in men, due to the fact that women are 3 – 4 times more likely to be affected by SI joint pain than men, leading to the small cohort of men in our SI joint pain sampling (20,21,25). Given that we found no association between joint shape category and synovial surface area, it appears that the associations between joint shape and pain, as well as between synovial surface area and pain, are independent of each other. In other words, both shape and surface area are associated with pain, and surface area does not appear to be mediating the association between pain and shape.

A possible explanation of our findings lies in the ability of various joint shapes to dissipate transmitted force. For example, type 3 "crescent" morphology has a relative decrease in contiguous surface area available for dissipation of force when compared to that of the more ovoid types one and 2, which have a more broad continuous surface area available for force dissipation.

Table 6. Synovial surface area and joint shape category, stratified by gender.

Joint Shape Category	Parameter Estimate (95% CI)	F Value	P Value	Parameter Estimate (95% CI)	F Value	P Value
	Females					
	Sacral Area (n = 148)			Iliac Area (n = 147)		
Type 1	1213.84 (1064.13, 1363.55)	0.05	0.96	1214.89 (1053.63, 1376.16)	0.25	0.78
Type 2	1203.87 (1135.47, 1272.28)			1204.45 (1129.94, 1278.96)		
Type 3	1187.03 (1069.83, 1304.24)			1156.03 (1029.78, 1282.28)		
Males						
	Sacral Area (n = 93)			Iliac Area (n = 95)		
Type 1	1302.40 (1063.62, 1541.18)	0.38	0.68	1295.00 (1055.77, 1534.23)	0.27	0.77
Type 2	1384.38 (1265.97, 1502.78)			1383.46 (1266.73, 1500.19)		
Type 3	1260.13 (933.17, 1587.08)			1312.13 (984.55, 1639.71)		

This would theoretically lead to increased force transmission to the periarticular ligamentous structures in type 3 morphology and may account for the propensity for pain in these patients.

Similarly, type one (scone-shaped) morphology, which was seen in a lower percentage in the pain groups (although not reaching clinical significance), is more ovoid in shape. This, theoretically, would allow for a greater degree of force dissipation across the synovialized surface, preventing excess forces from reaching the supporting ligamentous structures and decreasing propensity for pain.

We also found a statistically significant association between SI joint surface area and pain in both men and women pain patients having overall larger synovial surface areas. Although the pathophysiology behind this association is not immediately clear, we feel this is most likely related to the fact that larger bones and joints often belong to patients with larger height, and that larger height may then result in an increase of mass effect and stress to the SI joint with motion.

The ability to determine patients at higher risk of SI joint pain syndrome has a potential influence on treatment planning. For example, when assessing a patient for spinal fusion to the sacrum, a radiographically derived predictive parameter to determine the likelihood of SI joint pain may be useful in patient selection and operative planning.

Pre-operative assessment of SI morphology may also prove useful during placement of SI joint implants and ilio-sacral fixation screws. Literature discussion regarding the anatomic considerations in implant placement and screw fixation primarily focuses on optimization of screw placement based on a universal SI joint anatomy (26-34). One may postulate that if the transmission of nutational force across the SI joint varies with the orientation and morphology of the synovialized surface, then stabilization of these nutational forces in the setting of SI joint fusion/fixation may in fact require slightly different implant orientation, unique to the aforementioned morphologic variability and classification. Our study may serve as a classification guideline for these future clinical studies in the field of spine surgery and pain.

Our study does, however, have several limitations. First, the study is retrospective. Despite due diligence in reviewing the electronic medical records of the control patients for the current or historical complaint of lower back pain, SI joint pain, or pelvic trauma, there remains a potential for misclassification

bias if these symptoms/histories were present but not well-documented.

Another limitation of the study lies in the pre-injection physical assessment of SI joint mediated pain. Our study did not standardize the evaluation of pre-procedural SI mediated pain through the use of specific provocative maneuvers. Instead, we used improvement with injection of anesthetic to the SI joint as our "gold standard". While in future studies we aim to ensure a more uniform physical examination prior to injection, we assume that our method of diagnosis was as close to a "gold standard" as possible in this complex pain syndrome. This assumption is supported by a comprehensive meta-analysis, which states that there is limited evidence that provocative maneuvers are helpful in determining the likelihood of SI joint pain and concludes that the use of a single anesthetic injection for the diagnosis of SI joint mediated pain does not appear to result in unacceptably high false positive rates (35). Despite this conclusion supporting the use of injections for the diagnosis of SI joint pain, we acknowledge that this remains a limitation, as there is no means of diagnosis that is free of false positives in this complex pain syndrome.

Finally, with regard to the quantified classification system, one may propose that the numerical delineation of shape variation was subject to an arbitrary cut-off on a spectrum of variability. In response to this potential limitation, we note that the shape classification was constructed in a way that would identify outliers on the spectrum rather than to propose or suggest a clear tri-modal distribution of shape variability.

Regardless of these limitations, we feel that our study remains relevant in that it offers insight into a potential anatomic predisposition to the development of SI joint pain that may be clinically useful in the diagnosis, treatment, planning, and outcomes in susceptible patient populations.

CONCLUSION

SI joint morphologic variability can be classified into 3 types (type one, type 2, type 3) based on the relative width of the joint at the axis of nutation. Application of data from this study, in patients who have documented low back or SI joint pathology, revealed that variability in the synovial surface morphology of the SI joint may have a predisposing effect on the development of SI joint pain. Type 3 (crescent) morphology was more highly represented in the SI joint pain population. Further research in susceptible patient popula-

tions is necessary to confirm the clinical applicability of this data and solidify the conclusions.

Acknowledgments

Dr. Jesse had full access to all of the data in the study and takes responsibility for the integrity of the data and the accuracy of the data analysis. Drs. Jesse, Petersen, Kleck, and Patel designed the study protocol.

Drs. Jesse, Williams, and Kleck managed the literature searches and summaries of previous related work and wrote the first draft of the manuscript.

The authors wish to thank members of the 3D radiology lab at the University of Colorado for assistance with the reformation of images. We would also like to thank the editorial board of *Pain Physician* for review and criticism in improving the manuscript.

REFERENCES

- Paquin JD, van der Rest M, Marie PJ, Mort JS, Pidoux I, Poole AR, Roughley PJ. Biochemical and morphologic studies of cartilage from the adult human sacroiliac joint. *Arthritis Rheum* 1983; 26:887-895.
- Cole JD, Blum DA, Ansel LJ. Outcome after fixation of unstable posterior pelvic ring injuries. *Clin Orthop Relat Res* 1996; 329:160-179.
- Vleeming A, Stoeckart R, Volkers AC, Snijders CJ. Relation between form and function in the sacroiliac joint. Part I: Clinical anatomical aspects. *Spine* 1990; 15:130-132.
- Vleeming A, Volkers AC, Snijders CJ, Stoeckart R. Relation between form and function in the sacroiliac joint. Part II: Biomechanical aspects. *Spine* 1990; 15:133-136.
- Bowen V, Cassidy JD. Macroscopic and microscopic anatomy of the sacroiliac joint from embryonic life until the eighth decade. *Spine* 1981; 6:620-628. PMID: 7336283
- Bakland O, Hansen JH. The axial sacroiliac joint. *Anat Clin* 1984; 6:29-36.
- Egund N, Olsson TH, Schmid H, Selvic G. Movements in the sacroiliac joint demonstrated with roentgen stereophotogrammetry. *Acta Radiol Diagn (Stockh)*. 1978; 19:833-846.
- Bellamy N, Park W, Rooney PJ. What do we know about the sacroiliac joint? *Semin Arthritis Rheum* 1983; 12:282-313.
- Sturesson B, Selvik G, Uden A. Movements of the sacroiliac joints: A roentgen stereophotogrammetric analysis. *Spine* 1989; 14:162-165.
- Sturesson B. Movement of the sacroiliac joint with special reference to the effect of load. Ed: Vleeming A. In: *Movement, Stability, and Lumbopelvic Pain: Integration of Research and Therapy*. Churchill Livingstone; Edinburgh, UK 2007 pp. 343-352.
- Vleeming A, van Wingerden JP, Dijkstra PF, Stoeckart R, Snijders CJ. Mobility in the sacroiliac joints in the elderly: A kinematic and radiological study. *Clin Biomech* 1992; 7:170-176.
- Bernard TN, Kirkaldy-Willis WH. Recognizing specific characteristics of nonspecific low back pain. *Clin Orthop Relat Res* 1987; 217:266-280.
- Maigne JY, Planchon CA. Sacroiliac joint pain after lumbar fusion. A study with anesthetic blocks. *Eur Spine J* 2005; 14:654-658.
- Herzog W, Conway PJ. Gait analysis of sacroiliac joint patients. *J Manipulative Physiol Ther* 1994; 17:124-127.
- D'Amico M, Roncoletta P, Di Felice F, Porto D, Bellomo R, Saggini R. LBP and lower limb discrepancy: 3D evaluation of postural rebalancing via underfoot wedge correction. *Stud Health Technol Inform* 2012; 176:108-112.
- Kiapour A, Abdelgawad AA, Goel VK, Souccar A, Terai T, Ebraheim NA. Relationship between limb length discrepancy and load distribution across the sacroiliac joint—a finite element study. *J Orthop Res* 2012; 30:1577-1580.
- Marymont JV, Lynch MA, Henning CE. Exercise-related stress reaction of the sacroiliac joint: An unusual cause of low back pain in athletes. *Am J Sports Med* 1986; 14:320-323.
- Schoenberger M, Hellmich K. Sacroiliac dislocation and scoliosis. *Hippokrat* 1964; 35:476-479.
- Freburger JK, Holmes GM, Agans RP, Jackman AM, Darter JD, Wallace AS, Castel LD, Kalsbeek WD, Carey TS. The rising prevalence of chronic low back pain. *Arch Intern Med* 2009; 169:251-258.
- Kirkaldy-Willis, WH; Bernard, TN Jr. Making a specific diagnosis. In: *Managing Low Back Pain* (4th ed.) Churchill Livingstone, Philadelphia: 1999; pp. 206-226.
- Sembrano JN, Polly DW Jr. How often is low back pain not coming from the back? *Spine* 2009; 34:E27-E32.
- Albert HB, Godskesen M, Westergaard J. Prognosis in four syndromes of pregnancy-related pelvic pain. *Acta Obstet Gynecol Scand* 2001; 80:505-510.
- Katz V, Schofferman J, Reynolds J. The sacroiliac joint: A potential cause of pain after lumbar fusion to the sacrum. *J Spinal Disord Tech* 2003; 16:96-99.
- Ebraheim NA, Elgafy H, Semaan HB. Computed tomographic findings in patients with persistent sacroiliac pain after posterior iliac graft harvesting. *Spine* 2000; 25:2047-2051.
- Isaac Z, Feeney R. Sacroiliac joint dysfunction. Ed: Frontera WR, Silver JK, Rizzo TD Jr. In: *Essentials of Physical Medicine and Rehabilitation*, 3rd ed. Elsevier Saunders, Philadelphia, PA; 2014 chap 51.
- Esses SI, Botsford DJ, Huler RJ, Rauschnig W. Surgical anatomy of the sacrum. A guide for rational screw fixation. *Spine* 1991; 16:S283-S288.
- Mirkovic S, Abitbol JJ, Steinman J, Edwards CC, Shaffler M, Massie J, Garfin SR. Anatomic consideration for sacral screw placement. *Spine* 1991; 16:S289-S294.
- Cecil ML, Rollins JR, Ebraheim NA, Yeasting RA. Projection of the S2 pedicle onto the posterolateral surface of the ilium. A technique for lag screw fixation of sacral fractures or sacroiliac joint dislocations. *Spine* 1996; 21:875-878.
- Pieske O, Landersdorfer C, Trumm C, Greiner A, Wallmichrath J, Gottschalk O, Rubenbauer B. CT-guided sacroiliac percutaneous screw placement in unstable posterior pelvic ring injuries: Accuracy of screw position, injury reduction and complications in 71 patients with 136 screws. *Injury* 2015; 46:333-339.
- Fischer S, Vogl TJ, Marzi I, Zangos S, Wichmann JL, Scholtz JE, Mack MG, Schmidt S, Eichler K. Percutaneous cannulated screw fixation of sacral fractures and sacroiliac joint disruptions with CT-

- controlled guidewires performed by interventionalists: Single center experience in treating posterior pelvic instability. *Eur J Radiol* 2015; 84:290-294.
31. Radetzki F, Wohlrab D, Goehre F, Noser H, Delank KS, Mendel T. Anatomical conditions of the posterior pelvic ring regarding bisegmental transverse sacroiliac screw fixation: A 3D morphometric study of 125 pelvic CT datasets. *Arch Orthop Trauma Surg* 2014; 134:1115-1120.
32. Mendel T, Noser H, Kuervers J, Goehre F, Hofmann GO, Radetzki F. The influence of sacral morphology on the existence of secure S1 and S2 transverse bone corridors for iliosacroiliac screw fixation. *Injury* 2013; 44:1773-1779.
33. Takao M, Nishii T, Sakai T, Yoshikawa H, Sugano N. Iliosacral screw insertion using CT-3D-fluoroscopy matching navigation. *Injury* 2014; 45:988-994.
34. Noser H, Radetzki F, Stock K, Mendel T. A method for computing general sacroiliac screw corridors based on CT scans of the pelvis. *J Digit Imaging* 2011; 24:665-671.
35. Simopoulos TT, Manchikanti L, Singh V, Gupta S, Hameed H, Diwan S, Cohen SP. A systematic evaluation of prevalence and diagnostic accuracy of sacroiliac joint interventions. *Pain Physician* 2012; 15:305-344.

