

Retrospective Study

e Complications of Lumbar Disc Herniation Following Full-endoscopic Interlaminar Lumbar Discectomy: A Large, Single-Center, Retrospective Study

Tian-Hang Xie, MD¹, Jian-Cheng Zeng, MD, PhD¹, Zhu-Hai Li, MD², Liang Wang, MD¹, Hong-Fei Nie, MD¹, Hu-Shan Jiang, MD¹, Yue-Ming Song, MD, PhD¹, and Qing-Quan Kong, MD, PhD¹

From: ¹Department of Orthopedics, West China Hospital/West China School of Medicine, Sichuan University, Chengdu, China; ²Department of Orthopedics, People's Hospital of Guangxi zhuang autonomous region, Nanning, China

Address Correspondence: Jian-Cheng Zeng, MD, PhD
Department of Orthopaedics, West China Hospital, Sichuan University, 37# Wainan Guoxue Road, Chengdu 610041, China
Email: tomzeng5@126.com

Disclaimer: There was no external funding in the preparation of this manuscript.

Conflict of interest: Each author certifies that he or she, or a member of his or her immediate family, has no commercial association (i.e., consultancies, stock ownership, equity interest, patent/licensing arrangements, etc.) that might pose a conflict of interest in connection with the submitted manuscript.

Manuscript received: 05-07-2016

Revised manuscript received: 08-19-2016

Accepted for publication: 08-24-2016

Free full manuscript: www.painphysicianjournal.com

Background: The new surgical procedure of full-endoscopic interlaminar lumbar discectomy (FILD) has achieved favorable effects in the treatment of lumbar disc herniation (LDH). Along with the wide range of applications of FILD, a series of complications related to the operation has gradually emerged.

Objective: To describe the types, incidences, and characteristics of complications following FILD and to explore preventative and treatment measures.

Study Design: Retrospective, observational study.

Setting: A spine center affiliated with a large general hospital.

Method: In total, 479 patients with LDH underwent FILDs that were performed by a single experienced spine surgeon between January 2010 and April 2013. Data concerning the complications were recorded.

Results: All 479 cases successfully underwent the procedure. A total of 482 procedures were completed. The mean follow-up time was 44.3 months with a range of 24 to 60 months. The average patient age was 47.8 years with a range of 16 to 76 years. Twenty-nine (6.0%) related complications emerged, including 3 cases (0.6%) of incomplete decompression in which the symptoms gradually decreased following 3 – 6 weeks of conservative treatment, 2 cases (0.4%) of nerve root injury in which the patients recovered well following 1 – 3 months of neurotrophic drug and functional exercise treatment, 15 cases (3.1%) of paresthesia that gradually improved following 1 – 8 weeks of rehabilitation exercises and treatment with mecobalamin and pregabalin, and 9 cases of recurrent herniation (1.9%). The latter condition was controlled in 4 cases with a conservative method, and 5 of these cases underwent reoperations that included 3 traditional open surgeries and 2 FILDs. Furthermore, the complication rate for the first 100 cases was 18%. This rate decreased to 2.9% for cases 101 – 479. The incidence of L4-5 herniation (8.2%) was significantly greater than that of L5-S1 (4.5%).

Limitations: This is a retrospective study, and some bias exists due to the single-center study design.

Conclusion: FILD is a surgical approach that has a low complication rate. Incomplete decompression, nerve root injury, paresthesia, and recurrent herniation were observed in our study. Some effective measures can prevent and reduce the incidence of the complications including strict indications for surgery, a thorough action plan, and a high level of surgical skill.

Key words: Complication, lumbar disc herniation, lumbar discectomy, endoscopic, inter-laminar discectomy, minimally invasive spine surgery

Pain Physician 2017; 20:E379-E387

Due to further exploration of the concept of minimally invasive surgery and the rapid development of surgical instruments, minimally invasive techniques have come to be widely used in various surgical fields. Full-endoscopic lumbar discectomy (FLD) is currently a hot field in research on minimally invasive surgeries of the spine. The initial underlying principle is complete decompression by the removal of the nucleus pulposus via the Kambin's triangle into the intradiscal area (1). Full-endoscopic interlaminar lumbar discectomy (FILD) is a new surgical approach that was proposed by Ruetten et al (2). This approach achieves decompression through an interlaminar window that is used to enter the corresponding area (2). This technology has a unique advantage, particularly in cases of L5-S1 disc herniation. A series of anatomical factors that block the working cannula from entering the designated area can be resolved. These anatomical factors include a high iliac crest, a small intervertebral foramen, and hypertrophy and hyperplasia of the transverse and articular processes, which are challenging issues for full-endoscopic transforaminal lumbar discectomy (FTLD). The majority of spine surgeons are increasingly interested in FILD, because it provides a similar surgical path and a familiar anatomy with respect to traditional open surgery (3-9). Due to the popularity of FILD and its steep learning curve, a series of surgery-related complications has gradually emerged (1,10-14). Thus, an accurate understanding of the related complications and the identification of some appropriate measures to prevent these complications will significantly influence the development of FILD.

METHODS

This study aimed to discuss the complications related to FILD and sought to identify countermeasures. This study was approved by the Sichuan University Institutional Review Board and retrospectively analyzed a consecutive cohort of 479 patients with lumbar disc herniations (LDHs) who underwent FILD performed by a single trained spine surgeon between January 2010 and April 2013 at the West China Hospital. All patients underwent preoperative imaging of the lumbar spine with x-rays, magnetic resonance imaging (MRI), and computed tomography (CT).

Inclusion Criteria

- Disc herniation located at L4-5 and/or L5-S1 as confirmed by MRI

- The main symptoms were radicular, and the symptoms and signs were consistent with the imaging results.

Exclusion Criteria

- Higher segment or extraforaminal LDH
- Recurrent LDH
- Combined lumbar segmental instability

Surgical Procedures

The procedures were performed under general anesthesia. The patients were placed in the prone position on a radiolucent table. The operating table was adjusted to reduce the front arch of the lumbar spine and to broaden the interlaminar window. Using anterior-posterior fluoroscopy, the index segment was identified, and the posterior midline was marked at the tips of the spinous processes. A puncture needle was inserted 2 cm lateral to the posterior median line of the symptomatic side to confirm the correct disc level and also because a puncture 2 cm lateral to the midline avoids injury to the dural sac and nerve root. The puncture extended to the surface of the facet joint as confirmed with C-arm fluoroscopy. According to the position of the puncture needle, a 0.7-cm incision was made using a sharp scalpel at 0.5 cm lateral to the posterior median line of the index segment so that the working tube could easily reach the interlaminar space and have sufficient mobility during the procedure. A dilator was inserted into the lateral edge of the interlaminar space until the facet joint or the ligamentum flavum (LF) was reached. A working cannula was rotated along the dilator, and C-arm fluoroscopy was used to re-confirm the location. Next, the endoscope (Spinendos GmbH, Germany) was placed. The soft tissue on the surface of the LF was removed using a bipolar radiofrequency electrode (Ellman Trigger-flex probe, Ellman International, Hewitt, NY). A small break was created in the median part of the LF using punch scissors. Water, with a pressure of 80 cm, was then sent through the hole, which pushed the dural sac and nerve root away from the ligamentum. The LF was then cut outwards until the shoulder of the nerve root was reached. The working cannula was rotated into the canal along the LF under direct visual control (a part of the bone of the inner edge of the superior articular process was removed with a burr and/or rongeur). The extruded core and degenerated tissues were exposed by rotating the external working sheath to medially retract the neural structures. Then, the region was removed with grasping forceps after a

lateral-medial shift of the working sheath. Sufficient space was released by the above operation. Next, the working cannula was adjusted upward and downward to explore the remaining extruding core for its removal. The axilla of the nerve root was then examined by medially retracting the operation sheath (when the patient had an axillary LDH, these steps were performed in the reverse order). An annuloplasty was performed using a bipolar radiofrequency electrode after the nerve was sufficiently decompressed, which indicated a favorable mobility of the nerve root and a favorable pulse of the dural sac. Forty milligrams of Sou-Medrol were then injected into the surgical field to prevent inflammation before the end of the operation.

All of the patients were treated for 1 – 3 days with drugs (mecobalamin and a non-steroidal anti-inflammatory drug). The patients were instructed to perform back muscle exercise and to walk with the protection of a waist brace, which was used to maintain a fixed position for a long duration and to prevent dramatic waist rotary motion.

The patients were followed-up postoperatively in outpatient clinics or via telephone or e-mails at one month, 3 months, 6 months, one year, and 2 years. All electronic medical records and preoperative and post-operative imaging data of the patients were collected and analyzed.

Statistics

All data management and statistical analysis were performed with SPSS version 18.0 software (SPSS Inc., Chicago, IL, USA). When a Levene's test for the comparison of variances did not result in the rejection of the hypothesis of equal variance between groups, the mean values were compared using ANOVA with Bonferroni corrections. Kruskal–Wallis tests were applied to non-normally distributed data. The analyses were performed with significance level of $\alpha = .05$ (two-sided).

RESULTS

A total of 483 patients with LDH underwent FILD treatment. We lost contact with 4 of the patients during follow-up. The remaining 479 patients received a total of 482 procedures. There were 252 men (52.6%) and 227 women (47.4%). The mean age was 47.8 years with a range of 16 to 76 years. The mean history was 3.3 years with a range of 3 months to 20 years. The general information and clinical data for the patients are provided in Table 1. The mean follow-up time was 38 months with a range of 24 to 60 months. We observed a

total of 29 (6.0%) patients with related complications. These patients exhibited incomplete decompression, nerve root injury, paresthesia, and recurrent herniation. Moreover, we observed that among the first 100 patients who underwent FILD, 18 (18%) suffered from related complications, and this rate subsequently decreased to 3.4% for cases 101 – 479. The incidence of L4-5 herniation (8.2%) was significantly greater than that for L5-S1 (4.5%). This distribution is provided in Table 2.

Three patients presented with residual radicular symptoms without a pain-free interval, and these symptoms were found to be due to incomplete decompression based on MRI. These findings revealed that a small volume of the residual nucleus pulposus continued to squeeze the nerve root. The symptoms gradually decreased after 3 – 6 weeks of conservative treatment that included medication (analgesics and neurotrophic) and lower back muscle exercises. Two patients, both with L4-5 disc herniations with lateral recess stenosis, experienced nerve root injury during the surgery. These patients presented with ipsilateral aggravating leg pain and weakened myodynamia, and one of these patients presented with merger saddle-area dysesthesia. These patients recovered after 1 – 3 months of neurotrophic drug and functional exercise

Table 1. Patient descriptions.

	Mean	N (%)
Population	-	479 (100%)
Age (year)	47.8	-
History (year)	3.3	-
Gender		
Male	-	252 (52.6%)
Female	-	227 (47.4%)
Disc number	-	482 (100%)
Lesion segment		
L4-5	-	193 (40.3%)
L5-S1	-	283 (59.1%)
L4-5 + L5-S1	-	3 (0.6%)
Type of herniation		
Central	-	41 (8.5%)
Paracentral	-	293 (60.8%)
Foraminal	-	148 (30.7%)
Combine situation		
Calcification	-	46 (9.5%)
Lateral recess stenosis	-	15 (3.1%)

Table 2. *The complications distribution.*

	All cases	The first 100	Case 101-479	L4-5 (196)	L5-S1 (286)
Total	29 (6.0%)	18 (18%)	11 (2.9%)	16 (8.2%)	13 (4.5%)
Incomplete decompression	3 (0.6%)	3 (3.0%)	0	2 (1.0%)	1 (0.3%)
Never root injury	2 (0.4%)	2 (2.0%)	0	2 (1.0%)	0
Paresthesia	15 (3.1%)	9 (9.0%)	6 (1.6%)	6 (3.1%)	9 (3.2%)
Recurrent herniation	9 (1.9%)	6 (6.0%)	5 (1.3%)	6 (3.1%)	3 (1.0%)

treatment. Postoperative paresthesia was present in 15 individuals. The clinical manifestations were pain and numbness with different extents and natures. All of these cases were confirmed to be free of nerve compression by MRI. Following 1 – 8 weeks of rehabilitation therapy combined with mecobalamin and pregabalin, the symptoms gradually improved. During the follow-up visits, 9 cases of recurrent herniation were recorded. There were 6 patients with an L4-5 LDH and 3 patients with an L5-S1 LDH including 7 cases of recurrent herniation in the original location and 2 cases of contralateral herniation. All of these patients presented with ipsilateral or contralateral symptoms that were similar to the preoperative conditions. In 4 of these patients, the conditions were controlled following the application of some conservative methods, and 5 cases underwent reoperations that included 3 traditional open surgeries and 2 FILDs.

Discussion

Due to its high level of effectiveness, economy, and minimally invasive nature, FILD has become increasingly popular with both spine surgeons and patients with LDH. This procedure for treating LDH, particularly L5-S1 LDH, has achieved widespread validation, and it has also produced favorable effects in cases of lumbar spinal stenosis (4,6,7,9,15). Although several investigations of FILD have been reported, there are few reports about the complications of this procedure. Ruetten et al (16) treated LDH with full endoscopic (FILD and FTLD) or microsurgical techniques. The results demonstrated that the complication rate of the full-endoscopic group (10.9%) was significantly lower than that of the microsurgical group (19.5%). There were no significant differences in the complication rates between FILD and FTLD. Choi et al (15) reported that the rate of complications of FILD was 18.5%. However, previous studies have provided no detailed analyses of the causes of and response measures for complications. Our study described the types, incidences, and characteristics of the complications

following FILD in detail, and we also explored preventative and treatment measures.

Incomplete decompression always results in persistent radicular pain without a pain-free interval after surgery (3). Lee et al (17) indicated that herniations with high-canal compromise and high-grade migration that are treated with FLD are associated with a high rate of incomplete decompression. The scope of the manipulation of the working cannula in FILD is considerably larger than that in FTLD; thus, we propose that FILD has an advantage in the treatment of migratory herniations. Two cases in our study involved high-canal compromise (< 50%), and another one occurred in the initial stage (Fig. 1). It is difficult to accurately ensure the end-point of the procedure, which may result in the inability to remove the nucleus pulposus in its entirety. Overall, we propose that the end-point is particularly important for the prevention of incomplete decompression. An important sign of complete decompression is the free mobilization of the neural tissues (when the nerve was sufficiently decompressed, the spontaneous pulsations of dura can be observed under constant hydraulic pressure, H₂O, with a pressure of 80 cm and a favorable mobility of the nerve root could also be observed by adjusting the hydraulic pressure by repeatedly opening and closing the hydrovalve of the endoscope), in addition to the performance of preoperative MRI analysis to confirm that the size of the nucleus pulposus that is intraoperatively removed is consistent with the preoperative MRI (3). Moreover, it is important to examine the residual fragments in the shoulder, axillary areas, and track of the nerve root carefully before the end-point is reached.

Compared with other methods, operations under direct vision can better distinguish the relationship of the nerve root with other tissues. Even so, nerve root injury is still a common complication of FLD (16,18,19). Two cases in our study involved L4-5 herniations combined with recess stenosis and calcification. During the surgeries, we found that the nerve root was pushed to the rear by the nucleus pulposus and attached to the

ligamentum flavum despite some adhesion and inflammatory vasculature wrapped round the nerve root. One such instance occurred when the ligament flavum was cut (Fig. 2), and another occurred when the nucleus pulposus was moved. Overall, we observed the following points. First, space is a consideration. When faced with a smaller laminar window, which is a challenge to the implantation and mobilization of the working cannula, a larger window should first be made using a high-speed burr and rongeur. Additionally, when lumbar spinal canal stenosis caused by facet joint hyperplasia, ligamentum flavum pachismus,

or herniation with calcification is present, there is not sufficient space to operate. Moreover, due to the above factors, the nerve root may be far from its normal anatomical position. A larger space should be made after part of the extruded core is removed. Thus, at a later period, we summed up our experience. When faced the recess stenosis, calcification, and other situations that limit the working space, some bone resection is usually required so that a larger working space can be created. Second, cleaning is an important consideration. Inflammatory vascular hyperplasia is observed in most patients, particularly those with long histories. Additionally, inflammatory bleeding caused by an increase in blood pressure during the irritation of freeing the nerve root and inflammatory vasculature may blur the surgical field and affect the fluency and accuracy of the operation. Thus, the achievement of effective hemosta-

sis with the radiofrequency electrode and the control of blood pressure are very necessary. Furthermore, gentle and accurate manipulation in a step-by-step manner without anxiousness or roughness is required.

Paresthesia had the highest incidence (15 cases, 3.1%) among all complications in our observations. Moreover, there is no uniform interpretation for its occurrence. Some studies have observed that intraoperative spinal ganglion or nerve root irritation may cause postoperative paresthesia (16,20). An analysis of our cases revealed that neuropathic pain (NP) was another important factor. In 8 of the 15 patients who exhibited paresthesia, the paresthesia was transient and disappeared within one week without any drug therapy. However, the other 7 patients exhibited persistent postoperative dysesthesia, hyperalgesia, or aggravated numbness that lasted for more than one week.

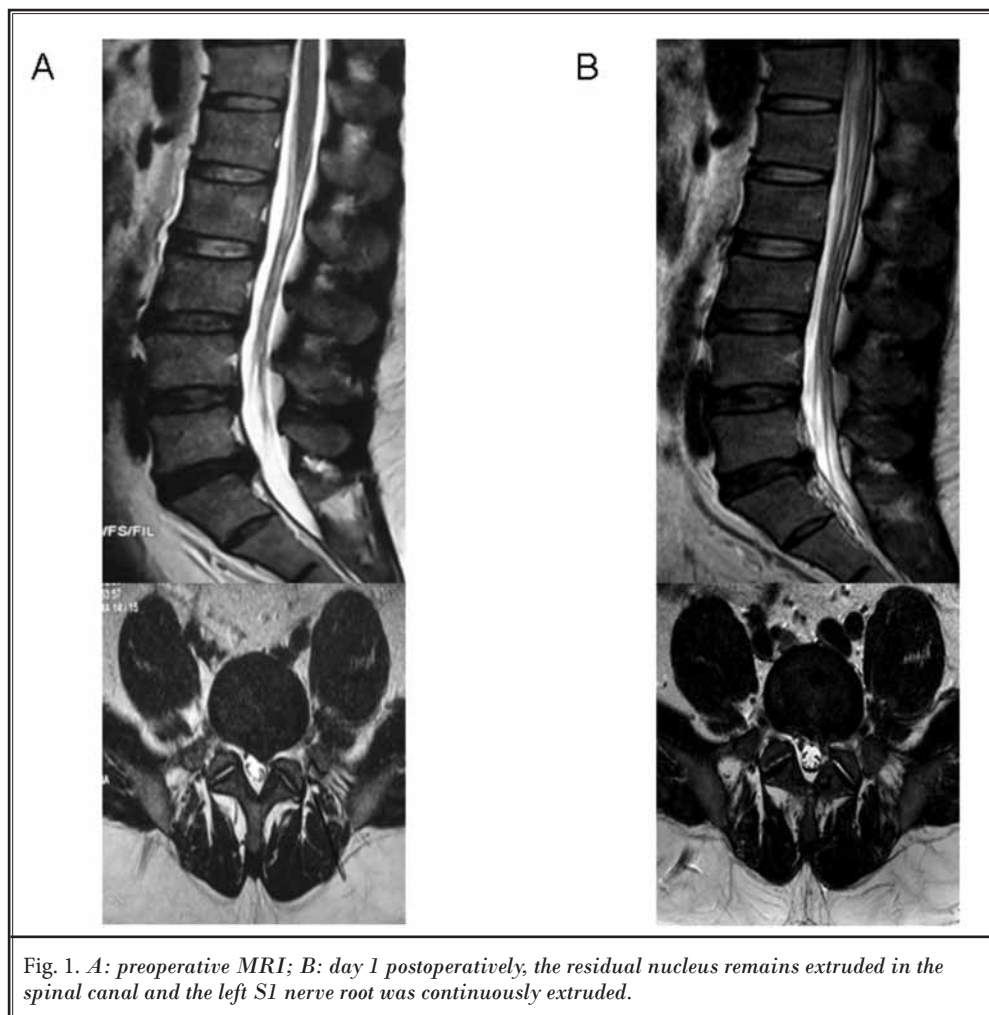
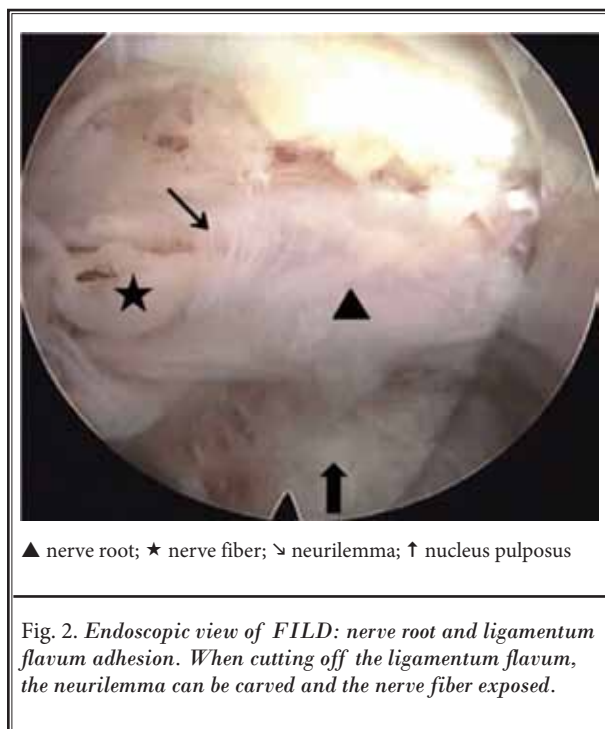


Fig. 1. *A: preoperative MRI; B: day 1 postoperatively, the residual nucleus remains extruded in the spinal canal and the left S1 nerve root was continuously extruded.*



The ID pain scores were 3.29 ± 0.76 on postoperative day one and 3.71 ± 0.76 at one week postoperative (21). After treatment with pregabalin, the scores significantly decreased to 2.29 ± 0.49 at postoperative week 2, 1.571 ± 0.789 at postoperative week 4, and 0.43 ± 0.54 at postoperative week 8. No significant differences were observed between postoperative day one and postoperative week one ($P > 0.05$). There were significant differences between postoperative week one and postoperative week 2 ($P < 0.001$), between postoperative week one and postoperative week 4 ($P < 0.001$), and between postoperative week one and postoperative week 8 ($P < 0.001$). Therefore, we believe that the symptoms were due to NP (22). Additionally, we found that the incidence of postoperative paresthesia among the patients with lateral recess stenosis (4 cases, 27%) was significantly greater than that among the patients without lateral recess stenosis (11 cases, 2.4%). We proposed that lateral recess stenosis resulted in the nerve root being squeezed, which caused preoperative irritation. Thus, it is necessary to reduce the number of unnecessary operations to reduce the irritation of the nerve root. Moreover, pregabalin was demonstrated to have favorable effects in the treatment of NP in our patients.

Recurrent lumbar disc herniations (RLDHs) occur following various operations of lumbar discectomy (23-26). Suk et al (27) defined RLDH as disc herniation at the same level with a pain-free interval longer than 6 months after surgery regardless of whether the herniation is ipsilateral or contralateral. The risk factors include smoking, gender, BMI, and diabetes (28). The primary cause is continual degeneration of the operated segments. We used the definition proposed by Suk et al (27) and found 9 cases with confirmed RLDH according to MRI (Fig. 3). These patients ranged in age from 26 to 50 years old with an average of 36.3 years. The range of recurrence was 8 to 40 months with an average of 18.6 months after surgery. These patients included 7 ipsilateral recurrences and 2 contralateral cases, and there were 6 men (4 smokers) and 3 women. Furthermore, 6 of these patients (67%) had histories of trauma, heavy lifting, or acute and substantial changes in waist posture. Thus, we propose that exogenic action may be a precipitating cause of RLDH. Kim and Park (19) divided recurrence into early recurrence (≤ 6 months) and late recurrence (> 6 months). The study groups were treated with FILD using annular sealing, and the control groups were treated without annular sealing. The recurrence rate of the study group (5.5%, early 2.2% and late 3.3%) was significantly lower than that of the control group (13.5%, early 9.8% and late 3.8%). Taken together, these results suggest that annular sealing can effectively reduce recurrence, particularly during the early stage. We did not seal the annulus, but we did perform annuloplasties (i.e., processing of the crevasse of the annulus by RF) (Fig. 4). Additionally, both the extruded parts and basal parts (some loose fragments of the inner crevasse) were removed in our operations. In addition to this technical tip, some factors unrelated to the procedure were equally important for preventing recurrence, and we believe that some fixed factors (i.e., height, age, and gender) can be ignored. Moreover, some health education should be provided to the patients, such as the need for increased exercise, weight reduction, and the avoidance of smoking and drugs. Furthermore, doctors should guide patients to perform back muscle exercises and suggest to their patients that they walk with the protection of a waist brace within the month following surgery. Moreover, patients should be advised to avoid heavy lifting and maintaining a fixed position for a long time and to induce little waist rotary motion.

Other common complications that have been re-

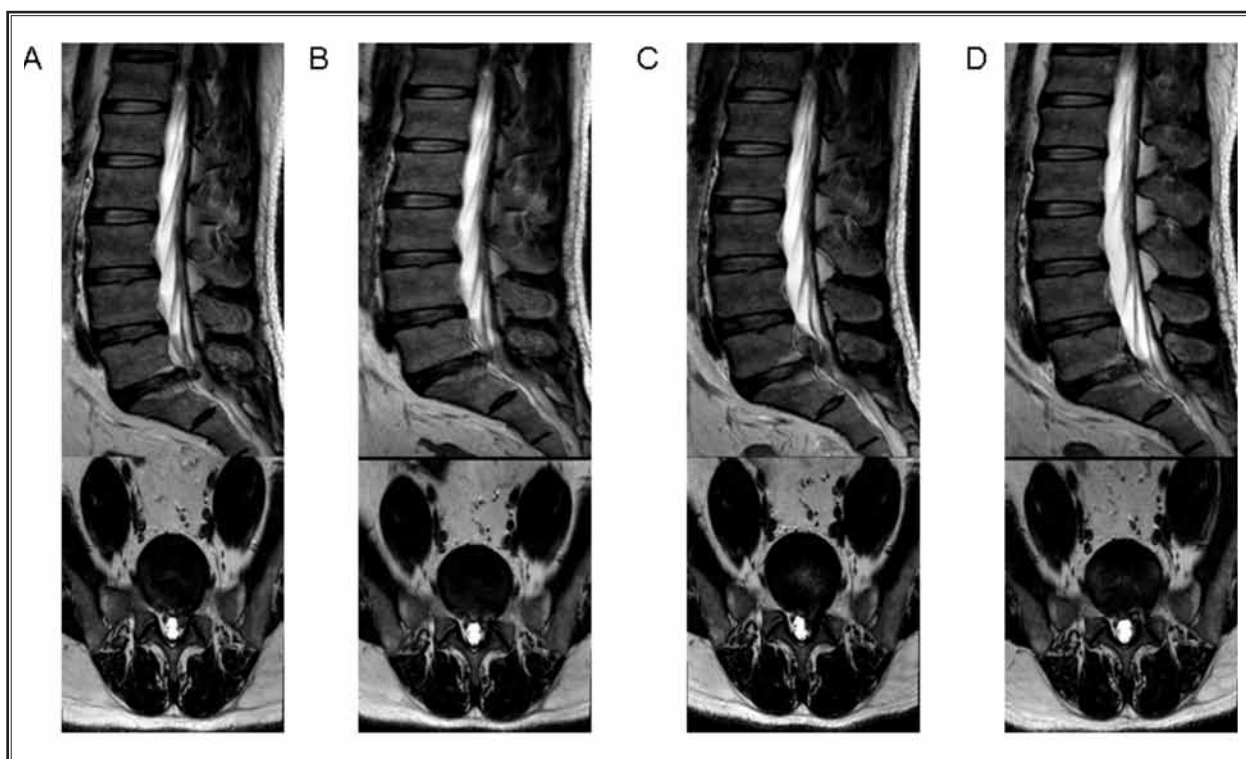


Fig. 3. A: before the initial FILD; B: 3 months after the initial FILD, the left S1 nerve root was not extruded; C: 12 months after the initial FILD, the left S1 nerve root was extruded again; D: one day after the second FILD. The left S1 nerve root was never extruded.

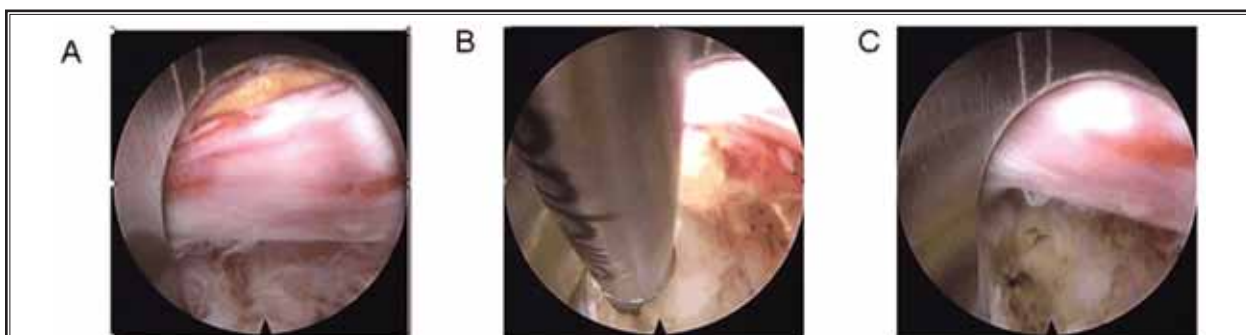

Fig. 4. A: before the annuloplasty; B: during the annuloplasty; C: after the annuloplasty.

ported in the literature include dural tears, which are a well-known and serious complication of lumbar spinal surgery (29). Patients with less extensive tearing may have no obvious symptoms and may only require supine rest with a pressure dressing. However, patients with serious tearing, which can cause intractable radicular pain, uncontrolled cerebrospinal fluid (CSF) leakage,

and even the formation of a nerve root herniation, will always need secondary open repair surgery (30-33). No dural tears were detected in our study. Because FILD uses the posterior approach, similar to traditional open surgery, it provides some benefits, such as reduced damage to the bone and soft tissue. Theoretically, the risk of dural tears may be relatively low. We

propose that the initial insertion point and control of the intraoperative direction of the working sheath are important. With regard to axillary herniations, the FL should be cut off close to the upper edge of the lower lamina. After exposure of the nerve root and dural sac and following the removal of the epidural fat tissue, the working sheath should be adjusted slightly outward and upward to reach the axilla, and the sheath should be rotated to place the nerve tissue outside. Regarding non-axillary herniations, the initial insertion point is the lateral edge of the interlaminar space, and the insertion should be extended until the facet joint is reached. Next, a lateral-medial shift of the working sheath should be performed to protect the nerve tissue. Moreover, there were no cases of infection in the present study. We did not use prophylactic antibiotics in the operations, although some studies have indicated that the prophylactic use of antibiotics in FLD (including FILD and FTLD) is necessary (6,34). First, FILD should be considered an aseptic operation. The infrequent use of fluoroscopy and a shorter operation time can reduce the probability of infection in an open operation. Furthermore, the inflammatory chemicals could be washed away persistently during the operation with a sufficient amount of normal saline. By combining these advantages with strict aseptic manipulation, we propose that infection may be prevented.

Analysis of our observations revealed that the complication rate of the first 100 patients was 18.0%, and these complications included fragment omission (3.0%), root injury (2.0%), paresthesia (9.0%), and recurrence (6.0%). The rates of these complications in the first 100 patients were significantly greater than

those among the total population. These findings are consistent with the notion that FILD has a long and steep learning curve. Furthermore, the complication rate for the L4-5 herniations (8.2%) was greater than that for the L5-S1 herniations (4.5%). We believe the main reason for this finding is that the laminar window of L4-5 is smaller than that of L5-S1. The smaller window increases the difficulty and risk of the entry of the working cannula into the canal and extension of the working cannula to the shoulder of nerve root for L4-5 herniations, particularly when combined with stenosis and/or facet hypertrophy. Therefore, many previous studies have proposed that FILD is more suitable for L5-S1 herniations (4,7,15). We treated 196 cases of L4-5 herniations with FILD and achieved satisfactory results. Furthermore, the complication rate declined from 12.0% (the first 100 L4-5 cases) to 4.2% (L4-5 cases 100 to 196). Thus, we propose that as the surgeon becomes more skillful and experienced, FILD can be equally efficacious in the treatment of L4-5 and L5-S1 herniations.

CONCLUSION

FILD is a new technology that has a low incidence of complications. These complications are mostly associated with improper operative procedures. To reduce the complication rate, we provide the following recommends: specify the precise surgical procedure and employ a combination of superb surgical skills and targeted perioperative management.

ACKNOWLEDGMENTS

We thank Duan Wang for assisting with the data collection and management.

REFERENCES

1. Yeung AT. Minimally invasive disc surgery with the Yeung Endoscopic Spine System (YESS). *Surg Technol Int* 1999; 8:267-277.
2. Ruetten S, Komp M, Godolias G. A New full-endoscopic technique for the interlaminar operation of lumbar disc herniations using 6-mm endoscopes: Prospective 2-year results of 331 patients. *Minim Invasive Neurosurg* 2006; 49:80-87.
3. Ahn Y. Transforaminal percutaneous endoscopic lumbar discectomy: Technical tips to prevent complications. *Expert Rev Med Devices* 2012; 9:361-366.
4. Chen HT, Tsai CH, Chao SC, Kao TH, Chen YJ, Hsu HC, Shen CC, Tsou HK. Endoscopic discectomy of L5-S1 disc herniation via an interlaminar approach: Prospective controlled study under local and general anesthesia. *Surg Neurol Int* 2011; 2:93.
5. Kim CH, Chung CK, Sohn S, Lee S, Park SB. The surgical outcome and the surgical strategy of percutaneous endoscopic discectomy for recurrent disk herniation. *J Spinal Disord Tech* 2014; 27:415-422.
6. Komp MG, G.Ruetten, S. Bilateral spinal decompression of lumbar central stenosis with the full-endoscopic interlaminar versus microsurgical laminotomy technique: A prospective, randomized, controlled study. *Pain Physician* 2015; 18:61-70.
7. Li ZZ, Hou SX, Shang WL, Song KR, Zhao HL. The strategy and early clinical outcome of full-endoscopic L5/S1 discectomy through interlaminar approach. *Clin Neurol Neurosurg* 2015; 133:40-45.
8. Sencer A, Yorukoglu AG, Akcakaya MO, Aras Y, Aydoseli A, Boyali O, Sencan F, Sabanci PA, Gomleksiz C, Imer M. Fully endoscopic interlaminar and transforaminal lumbar discectomy: Short-

- term clinical results of 163 surgically treated patients. *World Neurosurg* 2014; 82:884-890.
9. Wang X, Zeng J, Nie H, Chen G, Li Z, Jiang H, Kong Q, Song Y, Liu H. Percutaneous endoscopic interlaminar discectomy for pediatric lumbar disc herniation. *Childs Nerv Syst* 2014; 30:897-902.
 10. Ahn Y, Kim JU, Lee BH, Lee SH, Park JD, Hong DH, Lee JH. Postoperative retroperitoneal hematoma following transforaminal percutaneous endoscopic lumbar discectomy. *J Neurosurg Spine* 2009; 10:595-602.
 11. Ahn Y, Lee SH. Outcome predictors of percutaneous endoscopic lumbar discectomy and thermal annuloplasty for discogenic low back pain. *Acta Neurochir (Wien)* 2010; 152:1695-1702.
 12. Choi G, Kang HY, Modi HN, Prada N, Nicolau RJ, Joh JY, Pan WJ, Lee SH. Risk of developing seizure after percutaneous endoscopic lumbar discectomy. *J Spinal Disord Tech* 2011; 24:83-92.
 13. Choi KB, Lee CD, Lee SH. Pyogenic spondylodiscitis after percutaneous endoscopic lumbar discectomy. *J Korean Neurosurg Soc* 2010; 48:455-460.
 14. Kim JE, Kim KH. Piriformis syndrome after percutaneous endoscopic lumbar discectomy via the posterolateral approach. *Eur Spine J* 2011; 20:1663-1668.
 15. Choi G, Lee SH, Raiturker PP, Lee S, Chae YS. Percutaneous endoscopic interlaminar discectomy for intracanalicular disc herniations at L5-S1 using a rigid working channel endoscope. *Neurosurgery* 2006; 58:ONS59-68; discussion ONS59-68.
 16. Ruetten S, Komp M, Merk H, Godolias G. Full-endoscopic interlaminar and transforaminal lumbar discectomy versus conventional microsurgical technique: A prospective, randomized, controlled study. *Spine (Phila Pa 1976)* 2008; 33:931-939.
 17. Lee SH, Kang BU, Ahn Y, Choi G, Choi YG, Ahn KU, Shin SW, Kang HY. Operative failure of percutaneous endoscopic lumbar discectomy: A radiologic analysis of 55 cases. *Spine (Phila Pa 1976)* 2006; 31:E285-E290.
 18. Epstein NE. More nerve root injuries occur with minimally invasive lumbar surgery: Let's tell someone. *Surg Neurol Int* 2016; 7:S96-S101.
 19. Kim HS, Park JY. Comparative assessment of different percutaneous endoscopic interlaminar lumbar discectomy (PEID) techniques. *Pain Physician* 2013; 16:359-367.
 20. Cho JY, Lee SH, Lee HY. Prevention of development of postoperative dysesthesia in transforaminal percutaneous endoscopic lumbar discectomy for intracanalicular lumbar disc herniation: Floating retraction technique. *Minim Invasive Neurosurg* 2011; 54:214-218.
 21. Portenoy R. Development and testing of a neuropathic pain screening questionnaire: ID Pain. *Curr Med Res Opin* 2006; 22:1555-1565.
 22. Bouhassira D, Attal N, Alchaar H, Boureau F, Brochet B, Bruxelle J, Cunin G, Fermanian J, Ginies P, Grun-Overdyking A. Comparison of pain syndromes associated with nervous or somatic lesions and development of a new neuropathic pain diagnostic questionnaire (DN4). *Pain* 2005; 114:29-36.
 23. Dower A, Chatterji R, Swart A, Winder MJ. Surgical management of recurrent lumbar disc herniation and the role of fusion. *J Clin Neurosci* 2015; 23:44-50.
 24. Leven D, Passias PG, Errico TJ, Lafage V, Bianco K, Lee A, Lurie JD, Tosteson TD, Zhao W, Spratt KF. Risk factors for reoperation in patients treated surgically for intervertebral disc herniation: A subanalysis of eight-year SPORT data. *J Bone Joint Surg Am* 2015; 97:1316-1325.
 25. McGirt MJ, Parker SL, Coric D, Kim PK, Cahill KS, Devin CJ, Asher AL. 110 arthrodesis vs revision discectomy for recurrent lumbar disc herniation: Patient-reported outcomes in 417 patients from the N2QOD Registry. *Neurosurgery* 2015; 62:200.
 26. Phillips FM. CORR Insights®: Recurrent versus primary lumbar disc herniation surgery: Patient-reported outcomes in the Swedish Spine Register Swespine. *Clin Orthop Relat Res* 2015; 473:1985-1987.
 27. Suk KS, Lee HM, Moon SH, Kim NH. Recurrent lumbar disc herniation: Results of operative management. *Spine (Phila Pa 1976)* 2001; 26:672-676.
 28. Huang W, Han Z, Liu J, Yu L, Yu X. Risk factors for recurrent lumbar disc herniation: A systematic review and meta-Analysis. *Medicine (Baltimore)* 2016; 95:e2378.
 29. Bosacco SJ, Gardner MJ, Guille JT. Evaluation and treatment of dural tears in lumbar spine surgery: A review. *Clin Orthop Relat Res* 2001; 238-247.
 30. Ahn Y, Lee HY, Lee SH, Lee JH. Dural tears in percutaneous endoscopic lumbar discectomy. *Eur Spine J* 2011; 20:58-64.
 31. Goodkin R, Laska LL. Unintended "incidental" durotomy during surgery of the lumbar spine: Medicolegal implications. *Surg Neurol* 1995; 43:4-12; discussion 12-14.
 32. Saxler G, Kramer J, Barden B, Kurt A, Pfortner J, Bernsmann K. The long-term clinical sequelae of incidental durotomy in lumbar disc surgery. *Spine (Phila Pa 1976)* 2005; 30:2298-2302.
 33. Sin AH, Caldito G, Smith D, Rashidi M, Willis B, Nanda A. Predictive factors for dural tear and cerebrospinal fluid leakage in patients undergoing lumbar surgery. *J Neurosurg Spine* 2006; 5:224-227.
 34. Ahn Y, Lee SH. Postoperative spondylodiscitis following transforaminal percutaneous endoscopic lumbar discectomy: Clinical characteristics and preventive strategies. *Br J Neurosurg* 2012; 26:482-486.

