

## Case Report

## Conus Medullaris Infarction After a Right L4 Transforaminal Epidural Steroid Injection Using Dexamethasone

Christopher Gharibo, MD, Michael Fakhry, MD, Sudhir Diwan, MD, and Alan D Kaye, MD, PhD

From: NYU Langone Medical Center

Address Correspondence:  
Michael Fakhry, MD  
NYU Langone Medical Center  
NYU Center for Musculoskeletal Care  
333 East 38th St, 6th floor  
NY, NY 10003  
E-mail:  
fakhrymi@gmail.com

Free full manuscript:  
www.painphysicianjournal.com

**Background:** For decades, epidural steroid injections have been an effective tool in the management of many pain related conditions, including lumbar radiculopathy. Transforaminal epidural steroid injections in particular have been reported to potentially result in central nervous system infarctions which have not been reported with interlaminar epidural steroid injections, while providing comparable efficacy. This rare, catastrophic complication has been attributed by some authors to be due to vascular injury secondary to vasospasm, thrombus formation, dissection, as well as concerns with placing the needle at the so-called “safe triangle.” Others, however, have proposed it to be secondary to embolization of the vessel by particulate steroids. This has led to the recommendation of the use of soluble steroids such as dexamethasone when performing TFESI’s, despite concerns over its efficacy and potential for neurotoxicity in the literature. Furthermore, there have also been multiple studies which have revealed that IV dexamethasone is analgesic and that peri-neural dexamethasone is no more effective than IV dexamethasone.

**Case History:** The present case involves a 60-year-old patient with right back and radicular leg pain for 3 years. Two right L4 TFESI’s had been performed with betamethasone several years prior with satisfactory results, until the patient presented to the physician with a pain recurrence of 6 weeks of duration. The patient again underwent a right L4 TFESI with dexamethasone, which provided good relief after 2 weeks. The patient underwent a repeat right L4 TFESI with dexamethasone which was followed by a prompt onset of lower extremity numbness, weakness, and incontinence that was discovered to be related to a conus infarction. While this is the first publicly reported case of a conus medullaris infarction following a lumbar transforaminal injection utilizing dexamethasone, the incidence of these reports may rise as the prevalence of dexamethasone use increases in clinical practice.

**Conclusion:** The spinal cord infarction with TFESI’s may occur related to various mechanisms, regardless of the type of particulate or non-particulate steroid used during these procedures.

**Key words:** Dexamethasone, particulate steroids, non-particulate steroids, conus medullaris infarction, cauda equina syndrome, transforaminal epidural steroid injection, epidural steroid injection, safe triangle, methylprednisolone, paralysis

**Pain Physician 2016; 19:E1211-E1214**

**F**or decades, epidural steroid injections have been an effective tool in the management of many pain-related conditions, including lumbar radiculopathy. It is believed that radiculopathy may result, in part, from inflammatory mediators released from a herniated disc, compared to the purely mechanical compression of a nerve root. An injection of solution containing local anesthetic and depot-steroids

into the epidural space is postulated to have analgesic neuromodulatory, irrigative, and anti-inflammatory effects that decrease sensitivity, inflammation, and the size of the nerve root, thereby improving symptoms of radiculopathy (1).

Transforaminal epidural steroid injections have been reported to potentially result in central nervous system infarctions, which have not been re-

ported with interlaminar epidural steroid injections; both approaches provide comparable efficacy. In April 2014, the Food and Drug Administration (FDA) issued a warning that epidural steroid injections can cause "rare but serious adverse events, including loss of vision, stroke, paralysis, and death." This was largely based on case reports of transforaminal epidural steroid injections performed with particulate steroids injected at the "safe triangle" with the occurrence of postprocedural catastrophic complications, including paralysis and death (2). The FDA convened a national panel, including pain medicine experts, to make recommendations in order to reduce potential harm (3). The Multi-Society Pain Workgroup (MPW) made a variety of recommendations that have been the subject of controversy due to their lack support in the literature (4). In the end, the FDA wrote "we find that available data do not currently support either a contraindication or a warning focused only on cervical transforaminal injection of suspension glucocorticoids" and further that "... the available data do not support comparative safety labeling implying that solutions are safer. Such labeling could encourage practitioners to use solutions, even though their relative safety and effectiveness remain an open question" (5).

The rare, catastrophic complication of transforaminal epidural steroid injections has been attributed to vascular injury. Many experts believe that this is beyond just a simple matter of a suspension steroid issue and that there are problems with the transforaminal procedure itself (6,7). The authors have proposed various theories for the mechanism of action including vasospasm, thrombus formation, dissection, and particulate steroid embolization as well as concerns with placing the needle at the so-called "safe triangle" (8).

An examination of the particle size and tendency of aggregation of various steroid particles reveals that those of methylprednisolone were mostly smaller than the size of red blood cells, but aggregations can occur which may potentially lead to obstruction of flow through the blood vessel. By contrast, nonparticulate dexamethasone particles do not aggregate and measure much smaller in diameter than red blood cells (9). Subsequently, some experts have recommended the use of soluble steroids such as dexamethasone when performing transforaminal epidural steroid injections (TFESIs) (10,11), despite concerns in the literature over their efficacy and potential for neurotoxicity (12,13). There have also been multiple studies which have revealed that intravenous dexamethasone is analgesic and that

perineural dexamethasone is no more effective than intravenous dexamethasone (14,15).

### **Case Report**

The present case involves a 60-year-old patient with right back and radicular leg pain for 3 years. Two right L4 TFESIs had been performed with betamethasone several years prior with satisfactory results until the patient presented to the physician with a pain recurrence of 6 weeks' duration. The patient again underwent a right L4 TFESI with dexamethasone, which provided good relief after 2 weeks. The patient underwent a repeat right L4 TFESI with dexamethasone which was followed by a prompt onset of lower extremity numbness, weakness, and incontinence that was discovered to be related to a conus infarction.

### **METHODS**

Both of the patient's most recent TFESIs were performed in a similar fashion. The patient was placed prone and was prepped and draped in a sterile manner. Oblique fluoroscopy was utilized to visualize the relationship of the right L4 pedicle to the superior articular process of L5. The skin was anesthetized with 2% lidocaine. A 22G spinal needle was advanced toward the neural foramen and the appropriate needle tip location was confirmed by anteroposterior and lateral fluoroscopy. After negative aspiration, approximately 2 mL of myelographic contrast medium was injected under live fluoroscopy which revealed expected spread and lack of vascular uptake. This was subsequently followed by an injection of 1.5 mL 4 mg/mL dexamethasone and 1.5 mL of normal saline.

### **RESULTS**

Immediately after the procedure, the patient developed a sensation to urinate, numbness, and weakness in both legs consistent with cauda equina syndrome (CES). After minimal improvement in the postanesthesia care unit, the patient was transported to the emergency department and continued to exhibit CES. An initial STAT magnetic resonance image (MRI) did not reveal any acute findings. A repeat MRI the next day revealed a conus medullaris infarction at T12-L1 (Fig. 1). The patient continues to suffer from the consequences of this infarction without resolution of symptoms.

### **DISCUSSION**

As seen in the present case report, a lumbar TFESI utilizing nonparticulate steroids may potentially result

in the same devastating postprocedural complications which have historically been revealed in case reports involving the injection of particulate steroids. Despite the injection of contrast medium under live fluoroscopy, which indicated a nonvascular pattern, there still appears to be a mechanism of vascular compromise independent of embolization leading to conus infarction. Given that dexamethasone particles do not aggregate and are about 10-times smaller than red blood cells (9), it follows, therefore, that there must be independent mechanisms of vascular injury aside from injectate aggregation and embolization.

We theorize that the needle-tip and injectate either caused vasospasm and/or obstructive anterior spinal artery related to a thrombus formation, intimal flap formation, or dissection which consequently resulted in this catastrophic complication.

While this is the first publicly reported case of a conus medullaris infarction following a lumbar TFESI utilizing dexamethasone, the incidence of these reports may rise as dexamethasone use increases in clinical practice. The recommendations that dexamethasone be used first line for transforaminal injections are concerning and not evidence-based, especially if it comes at the expense of efficacy when compared with its insoluble counterpart. In this regard, there is even a graver concern, given that higher projected numbers of dexamethasone injections may be performed to obtain a desired effect than if particulate steroids were used, potentially exposing our patients to a range of other complications which can result during epidural steroid injections (10).

It is a fundamental fact that there is no absolute and complete safety profile when it comes to epidural steroids and that TFESIs have a risk profile that differs from interlaminar epidural steroid injections.

Spinal cord infarction with TFESIs may occur related to various mechanisms, regardless of the type of particulate or nonparticulate steroid used during these procedures. In some manner, the transforaminal procedure itself appears to be linked to this devastating

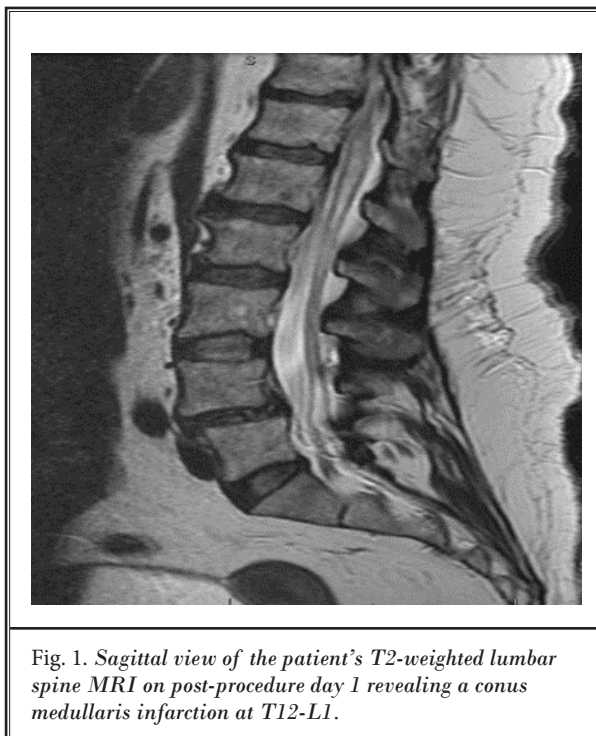


Fig. 1. Sagittal view of the patient's T2-weighted lumbar spine MRI on post-procedure day 1 revealing a conus medullaris infarction at T12-L1.

event. The reported higher number of injections to obtain an appropriate, desired effect with epidural dexamethasone is a serious issue and exposes our patients to other complications of steroid administration. Finally, although the use of computed tomography guidance instead of conventional fluoroscopy provides a better image of relevant anatomy, it does not assure avoidance of these potential adverse events (16,17).

## CONCLUSIONS

In summary, the present case report demonstrates a catastrophic case of administration of dexamethasone, a nonparticulate steroid, with resultant conus medullaris infarction. This report underscores the complexity of this devastating event, in terms of understanding its pathogenesis and in developing consensus best practice strategies in the future.

## REFERENCES

- Wallace MS, Staats P. *Pain Medicine and Management: Just the Facts*. McGraw-Hill, Medical Pub. Division, New York, 2005.
- Feeley IH, Healy EF, Noel J, Kiely PJ, Murphy TM. Particulate and non-particulate steroids in spinal epidurals: A systematic review and meta-analysis. *Eur Spine J* 2016; (Epub ahead of print).
- Manchikanti L, Candido KD, Singh V, Gharibo CG, Boswell MV, Benyamin RM, Falco FJ, Grider JS, Diwan S, Hirsch JA. Epidural steroid warning controversy still dogging FDA. *Pain Physician* 2014; 17:E451-E474.
- Manchikanti L, Falco FJ, Benyamin R, Gharibo CG, Candido KD, Hirsch JA. Epidural steroid injections safety recommendations by the Multi-Society Pain Workgroup (MPW): More regulations without evidence or clarification.

- Pain Physician* 2014; 17:E575-E588.
5. Racoosin JA, Seymour SM, Cascio L, Gill R. Serious neurologic events after epidural glucocorticoid injections – The FDA’s Risk Assessment. *NEJM* 2015; 24:2299-2301.
  6. Benzon HT, Chew TL, McCarthy RJ, Benzon HA, Walega DR. Comparison of the particle sizes of different steroids and the effect of dilution: A review of the relative neurotoxicities of the steroids. *Anesthesiology* 2007; 106:331-338.
  7. Kennedy DJ, Dreyfuss P, April CN, Bogduk N. Paraplegia following image-guided transforaminal lumbar spine epidural steroid injection: Two case reports. *Pain Medicine* 2009; 10:1389-1394.
  8. Tackla RD, Keller JT, Ernst RJ, Farley CW, Bohinski RJ. Conus medullaris syndrome after epidural steroid injection: Case report. *Int J Spine Surg* 2012; 1:6:29-33.
  9. Derby R, Lee SH, Date ES, Lee JH, Lee CH. Size and aggregation of corticosteroids used for epidural injections. *Pain Med* 2008; 9:227-234.
  10. Kennedy DJ, Plastaras C, Casey E, Visco CJ, Rittenberg JD, Conrad B, Singler J, Dreyfuss P. Comparative effectiveness of lumbar transforaminal epidural steroid injections with particulate versus nonparticulate corticosteroids for lumbar radicular pain due to intervertebral disc herniation: A prospective, randomized, double-blind trial. *Pain Med* 2014; 15:548-555.
  11. McCormick ZL, Cushman D, Marshall B, Caldwell M, Patel J, Ghannad L, Eng C, Makovitch S, Babu A, Chu SK, Marciniak C, Walega DR, Press J, Plastaras C, Kennedy DJ. Pain reduction and repeat injections after transforaminal epidural injection with particulate versus nonparticulate steroid for the treatment of chronic painful lumbosacral radiculopathy. *PM R* 2016; pii:S1934-S1482
  12. Williams BA, Hough KA, Tsui BY, Ibinson JW, Gold MS, Gebhart GF. Neurotoxicity of adjuvants used in perineural anesthesia and analgesia in comparison with ropivacaine. *Reg Anesth Pain Med* 2011; 36:225-230.
  13. Williams BA, Murinson BB, Grable BR, Orebaugh SL. Future considerations for pharmacologic adjuvants in single-injection peripheral nerve blocks for patients with diabetes mellitus. *Reg Anesth Pain Med* 2009; 34:445-457.
  14. Rahangdale R, Kendall MC, McCarthy RJ, Tureanu L, Doty R, Weingart A, De Oliveira GS. The effects of perineural versus intravenous dexamethasone on sciatic nerve blockade outcomes: a randomized, double-blind, placebo-controlled study. *Anesth Analg* 2014; 118:1113-1119.
  15. Dawson RL, McLeod DH, Koerber JP, Plummer JL, Dracopoulos GC. A randomized controlled trial of perineural vs intravenous dexamethasone for foot surgery. *Anaesthesia* 2016; 71:285-290.
  16. Somayaji HS, Saifuddin A, Casey AT, Briggs TW. Spinal cord infarction following therapeutic computed tomography-guided left L2 nerve root injection. *Spine* 2005; 30:E106-E108.
  17. Ericson-Neilsen W, Kaye AD. Steroids: pharmacology, complications, and practice delivery issues. *Ochsner J* 2014; 14:203-207.