

## Prospective Evaluation

## Cervical Interlaminar Epidural Injections at High Doses Do Not Increase Optic Nerve Sheath Diameter on a Long-Term Basis

Hyunzu Kim, MD<sup>1</sup>, Joo Hyeon O, MD<sup>1</sup>, Sung Jun Hong, MD, PhD<sup>1</sup>, Keun Man Shin, MD, PhD<sup>1</sup>, Jungchan Park, MD<sup>2</sup>, and Sang Soo Kang, MD, PhD<sup>1</sup>

From: <sup>1</sup>Department of Anesthesiology and Pain Medicine, Kangdong Sacred Heart Hospital, Hallym University College of Medicine, 445, Gil-dong, Gangdong-gu, Seoul, Korea; <sup>2</sup>Department of Anesthesiology and Pain Medicine, Samsung Medical Center, Sungkyunkwan University School of Medicine, 81 Irwon-ro, Gangnam-gu, Seoul, Korea.

Address Correspondence: Sang Soo Kang, MD, PhD  
Department of Anesthesiology and Pain Medicine  
Kangdong Sacred Heart Hospital  
Hallym University College of Medicine  
445 Gil-dong, Gangdong-gu  
Seoul, Korea 134-701  
E-mail: kssege@naver.com

Disclaimer: There was no external funding in the preparation of this manuscript. Conflict of interest: Each author certifies that he or she, or a member of his or her immediate family, has no commercial association (i.e., consultancies, stock ownership, equity interest, patent/licensing arrangements, etc.) that might pose a conflict of interest in connection with the submitted manuscript.

Manuscript received: 04-21-2016  
Revised manuscript received: 05-23-2016  
Accepted for publication: 06-14-2016

Free full manuscript:  
[www.painphysicianjournal.com](http://www.painphysicianjournal.com)

**Background:** Cervical epidural injection (CEI) is widely performed on patients with pain originating from the cervical spine. Studies have shown a good relationship between the optic nerve sheath diameter (ONSD) and the intracranial pressure (ICP).

**Objective:** The aim of this study was to evaluate the changes in the ONSD as a non-invasive surrogate marker of ICP after CEI.

**Study Design:** Prospective observational study.

**Setting:** Hospital and ambulatory pain clinic.

**Methods:** Twenty patients undergoing CEI at the C5-6 level were enrolled in this observational study. The CEIs were performed using a total of 14 mL of mixture volume via the interlaminar approach in the right lateral decubitus position. The ONSD through ultrasonography was measured in the initial supine position (T0, baseline), 30 seconds after the completion of CEI (T0.5), at 30-second intervals for 5 minutes (T0.5~T5), and at one-minute intervals for 5 minutes (T6~T10). Results: The values of the baseline ONSD (T0) in both eyes were  $4.1 \pm 0.4$  mm. The ONSD significantly increased from T1 to T10 ( $P < 0.05$ ) compared with T0. The maximum value of the ONSD was measured as  $5.1 \pm 0.4$  mm at T4, and the mean difference between the baseline ONSD and its maximum value was 1.0 mm, which represented about 27%. There was no increase in ICP-related complications such as dizziness, headache, visual acuity, or retinal hemorrhage.

**Limitations:** This was an observational study without a control group. All patients were presumed to have no intracranial pathology.

**Conclusion:** The 14 mL CEI resulted in an increase in the ONSD by ultrasonography over time. The most critical increase in ONSD was observed 4 minutes after CEI, but this increase was not sustained. Further work is needed to confirm the effects of the speed and volume of the injection and of the position.

**Registration:** Registered in the Clinical Research Information Service of the Korea National Institute of Health (<https://cris.nih.go.kr/cris/index.jsp>), registration number: KCT0001487

**Key words:** Analgesic techniques, epidural block, intracranial pressure, optic nerve sheath diameter, ultrasonography

**Pain Physician 2016; 19:E1173-E1179**

**C**ervical epidural injection (CEI) is widely performed and has been reported to have good efficacy for the treatment of pain of spinal origin. Although CEIs may be performed safely with

great caution, a variety of complications – including spinal cord trauma, dural puncture, hematoma, intravascular uptake of injectate, and infection – can arise (1,2). Other possible complications associated

with suspected intracranial pressure (ICP) change may include headache, syncope, loss of consciousness (LOC), and transient blindness. Although studies have been limited, epidural injection has been shown to increase the ICP both in a porcine model (3) and in humans (4,5).

A few cases of syncope or LOC associated with increased ICP after caudal epidural injections have been reported (6-8). The potential causes include the injection of large volumes, the presence of brain tumors, and severe spinal spondylosis. Ten cases of transient blindness following lumbar epidural injection for back pain have also been reported, and the suspected cause is believed to have been a rapid increase in ICP following the injection (9). Most of the reports and studies have focused on lumbar or caudal epidural injections, and there has been little research on CEI-related incidences and types of complications. As the cervical epidural space is smaller and more adjacent to the brain than the lumbar or caudal spaces, CEI may be more likely to cause increased ICP-related effects than lumbar or caudal epidural injections.

A number of recent clinical studies have confirmed the accuracy of ultrasonographic measurements of the optic nerve sheath diameter (ONSD) for the detection of increased ICP (10-15). Two recent meta-analyses have suggested that the ONSD may be a reliable non-invasive surrogate marker of increased ICP (16,17).

We hypothesized that CEIs would increase the ONSD due to a compressive effect on the subarachnoid space during the injection. The primary aim of the current study was to evaluate the changes in the ONSD as a non-invasive surrogate marker of ICP by ultrasonography (US) after CEI.

## **METHODS**

After obtaining approval from our hospital's Institutional Review Board for human studies and patients' written informed consent, 20 patients were enrolled in the study [registered in the Clinical Research Information Service of the Korea National Institute of Health (<https://cris.nih.go.kr/cris/index.jsp>), registration number: KCT0001487. All the patients received magnetic resonance imaging (MRI) of the cervical spine before enrollment.

The inclusion criteria encompassed patients with bulging or protruded cervical disc herniation at the C5-6 level with a history of function-limiting neck and C6 radicular pain. Patients were aged between 20 and 70 years old, who were competent to understand the study protocol and to provide their voluntary, written

informed consent. Cervical canal stenosis grades 0–2 at C5-6 disc level by Muhle et al's (18) magnetic resonance imaging (MRI) study were included. The exclusion criteria included pre-existing craniectomy or craniotomy, extruded or sequestered cervical disc herniation, cervical canal stenosis grade 3 at C5-6 disc level by Muhle et al's (18) MRI study, pre-existing eye disease or eye surgery (e.g., glaucoma, cataract, or retinal hemorrhage), uncontrolled hypertension or uncomplicated diabetes mellitus, Cushing's syndrome, and allergy to anesthetics, steroids, or contrast agents. The MRI grading system for cervical canal stenosis was followed by Muhle et al's (18) classification according to the following grading system: grade 0, normal; grade 1, partial obliteration of the anterior or posterior subarachnoid space; grade 2, complete obliteration of the anterior or posterior subarachnoid space; and grade 3, cervical cord compression or displacement.

The baseline ONSD was initially measured in the supine position on both sides of the 40 eyeballs (T0, baseline). As it was difficult to measure the ONSD simultaneously in both eyes after the CEI, patients were randomly assigned to one of 2 groups: the left eye group (n = 10) and the right eye group (n = 10) for serial measurements of ONSD following CEI. The CEIs were performed by a single physician from the pain clinic in an ambulatory surgery setting, i.e., in a sterile operating room under fluoroscopy. Our routine position for the CEI was the prone position, although the study procedure was performed in the right lateral decubitus position to remove the possible effects of the prone position on the ICP.

Following skin preparation and local infiltration, a 20-gauge 10 cm Tuohy needle was used. A mixture of 0.2% lidocaine 1 mL with normal saline 4 mL was prepared for loss of resistance technique and irrigation. Access to the epidural space was obtained by using loss of resistance techniques with 0.5 – 1 mL of the prepared mixture. The epidural space was entered between the C5 and C6, and confirmed by an injection of 4 mL of non-ionic contrast under fluoroscopic visualization. Once the needle tip was in the epidural space, the rest of the mixture 4.0 – 4.5 mL was injected for irrigation and an additional mixture of normal saline 4.5 mL with 0.5 mL of non-particulate betamethasone 2 mg was injected. The injection speed was 1.0 mL per second and the total volume of the injected materials was 14 mL. After the injection, the patients were immediately moved from the right lateral decubitus position into the supine position. The ONSD was measured 30

seconds after the CEI (T0.5), at 30-second intervals for 5 minutes (T0.5~T5), and at one-minute intervals for 5 minutes (T6~T10).

Ultrasound examinations of the eyes were carried out in B-mode by a single physician (KHJ) who had experienced performing over 300 transorbital ultrasonographies, using a 4 – 15 MHz linear array “hockey stick” probe (GE Healthcare, Milwaukee, WI, USA) as previously described (19). High-quality video images were acquired digitally and stored on the system’s hard drive. In the subsequent data analysis, the sonographic videos were reviewed to ensure the best achievable image quality and probe positioning, and a retrospective image analysis was performed offline. The transverse diameter of the optic nerve sheath diameter was measured 3 mm behind the globe with an electronic caliper. Each bulb was examined 3 times and the mean value of the ONSD was measured.

### Statistical Analysis

The sample size was estimated in accordance with the results of the pilot study, in which the ONSD of the right or left globe was compared before the CEI and at one-minute intervals for 10 minutes after the CEI in 7 patients. We estimated that 16 patients were needed to provide an effect size of 0.619 with an 80% power at the 5% significance level with one-tailed test. Twenty patients were recruited to allow 20% loss during the analysis.

The differences in the ONSD values at the different time points were determined with a one-way repeated-measure analysis, and the Tukey method was used for the post-hoc analysis. The data were expressed as mean  $\pm$  SD. A *P* value of  $< 0.05$  was considered statistically significant. The statistical analyses were performed with SPSS 13.0 (SPSS Inc., Chicago, IL, USA).

### RESULTS

A total of 20 patients were enrolled in the study. Their characteristics are presented in Table 1. A single level was involved in 3 patients, 2 levels were involved in 10, and more than 3 levels were involved in 7. Bulging disc was seen in 20 disc levels and protruding disc was seen in 28 disc levels. Characteristics of cervical disc herniation at each vertebral level are shown in Table 2.

The baseline ONSD values for the both eyes were not significantly different ( $4.1 \pm 0.4$  mm vs  $4.1 \pm 0.4$  mm, T0), and they were highly correlated (Pearson’s correlation = 0.862,  $P < 0.0001$ ). In reference to the baseline ONSD values, the ONSD of 20 test eyes significantly

Table 1. *Patients’ characteristics (n = 20).*

Age (years)	53.9 $\pm$ 7.2
Gender (F/M)	13/7
Weight (kg)	62.4 $\pm$ 10.8
Height (cm)	162 $\pm$ 5.8

Values are mean  $\pm$  SD.

Table 2. *Characteristics of cervical disc herniation at each vertebral level.*

	Bulging Disc	Protruded Disc	Foraminal Stenosis
C3-4	2	3	
C4-5	6	6	1
C5-6	8	12	8
C6-7	4	7	1

increased from T1 to T10 ( $P < 0.05$ ) and the maximum value of the ONSD was measured as  $5.1 \pm 0.4$  mm at T4. The mean difference between the baseline ONSD and its maximum value was 1.0 mm, which were represented in around 27% (Fig. 1).

In our analysis using a general linear mixed model (LMM) to compare the changes in ONSD between the right and left eyes over time, the overall difference in the ONSD changes between the 2 eyes was significant ( $P < 0.001$ ). However, in the post-hoc analysis, there were no significant differences at any time point.

There were no CEI-related complications, such as inadvertent dural puncture, hematoma, or infection. Moreover, there was no increase in ICP-related complications such as dizziness, headache, visual acuity, or retinal hemorrhage.

### DISCUSSION

The key finding of this study was that a 14 mL CEI administered in the lateral decubitus position resulted in changes in ONSD over time. The most critical increase in ONSD was observed 4 minutes after the CEI, but this increase was not sustained. To the best of our knowledge, this constituted the first description of changes in the ONSD as a non-invasive surrogate marker of ICP following administration of a therapeutic volume of CEI.

CEI has been reported to offer good or fair evidence in the management of cervical disc herniation (20,21). Although CEI may be performed safely with caution, various complications have been reported. In addition to spinal cord injury, dural puncture, hema-

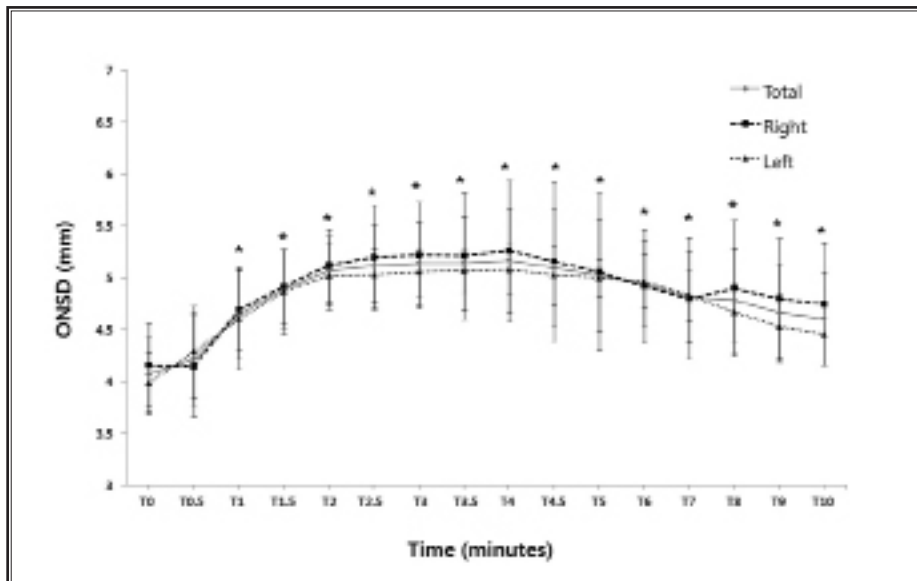


Fig. 1. Changes in optic nerve sheath diameter (ONSD) after cervical epidural injection (CEI). The ONSD was measured by ultrasonography in the initial supine position (T0, baseline), 30 seconds after the CEI (T0.5), at 30-second intervals for 5 minutes (T0.5~T5), and at one-minute intervals for 5 minutes (T6~T10). In reference to the baseline ONSD values, the ONSD significantly increased from T1 to T10 ( $P < 0.05$ ). The maximum value of the ONSD was measured as  $5.1 \pm 0.4$  mm at T4, but this increase was not sustained.

toma, and infection, other complications associated with suspected ICP change can include headache, syncope, LOC, and transient blindness.

A few cases of syncope or LOC associated with an increase in ICP after caudal epidural injections have been reported. A faster injection with a large volume of up to 60 mL was believed to have been the cause of LOC for 20 – 30 seconds accompanied by fine muscle twitching (6). Two parturient women with brain tumors and increased ICP developed apnea, LOC, and severe bradycardia for 5 or 6 minutes after caudal injection (7). Two elderly patients with severe spondylosis developed syncope after caudal injection. One assumption was that the injection into the low compliant extradural space due to a narrowed epidural space triggered an increase in ICP (8). Up to 10 cases of transient blindness following lumbar epidural injection for back pain have been reported (9), and retinal hemorrhages were identified by ophthalmologic examinations in every case. The suspected mechanism may have been due to a rapid increase in ICP following the injection, with a resulting increase in retinal venous pressure causing retinal hemorrhage.

Headaches secondary to epidural block can be categorized into 2 types. The first type is suspected to be caused by decreased ICP from post-dural puncture, while the other is believed to be caused by increased ICP from the volume of the injected materials. The latter is a transient, non-positional headache that resolves within 24 hours. It has not yet received much attention and the exact mechanism is unknown. However, it has broadly been reported as being not uncommon during rapid epidural injection (22), and Botwin et al (23) reported that it most commonly occurred as a minor complication in 3.1% of 322 fluoroscopically guided lumbar transforaminal

epidural injections with 1 – 3 mL injectates.

Although there have been few studies, epidural injection has been shown to increase the ICP both in a porcine model and in humans. Grocott and Mutch (3) demonstrated a correlation between epidural injections and ICP, with a greater than 90% reduction in cerebral blood flow (CBF) and spinal cord blood flow (SCBF) in the porcine model. The prompt return of the CBF and SCBF to their baseline values within 100 – 160 seconds of the epidural injection suggested preserved auto-regulatory mechanisms. Using transducers and pressure tracing records, Usubiaga et al (4) measured the effects of 10 or 20 mL of saline injected into the lumbar epidural space of 24 patients. They reported that the peak epidural pressure was reached immediately after the lumbar epidural injection, and a return to the previous values was observed within 3 to 10 minutes. The magnitude of the pressure rise was found to be proportional to the rate and volume of the injection.

The gold standard for ICP measurement is invasive monitoring. However, its placement can be challenging due to its invasiveness and lack of surgical availability. Non-invasive ICP estimation methods include transcranial Doppler sonography, tympanic membrane displacement, transcranial

near-infrared spectroscopy, visual-evoked potential, and ONSD.

Several studies presented the usefulness of US in CEI (24-25). The major advantages of the US-guided approach include the absence of radiation exposure and increasing the safety of the procedure. The US-guided approach enables visualization of soft tissues, nerves, blood vessels, and others through real-time imaging; it also shows the degree of diffusion for injected medications around nerves and prevents nerve damage by injection needles (26).

ONSD by US is a non-invasive method for the assessment of the risk of raised ICP. The subarachnoid spaces surrounding the optic nerve communicate with the intracranial cavity, and changes in cerebrospinal fluid pressure are transmitted along the optic nerve sheath (15). In the anterior part of the optic nerve – and particularly in the retrobulbar segment –, the nerve is only surrounded by orbital fat. The retrobulbar optic nerve sheath is therefore distensible and can inflate in cases of raised cerebrospinal fluid pressure. Numerous studies have been conducted on the ONSD, and 2 recent meta-analyses suggested that the ONSD may be a reliable non-invasive surrogate marker of increased ICP (16,17). However, the optimal cut-off differs considerably between different studies, lying within a range of 5 – 5.9 mm (16).

Among those, Geeraerts et al quoted ONSD values between  $6.3 \pm 0.6$  mm with ultrasound studies (11) and  $6.3 \pm 0.5$  mm with MRI studies (27) for traumatic brain injury with elevated ICP (i.e., over 20 mmHg). They also reported an ONSD cut-off of 5.8 mm for raised ICP, and suggested that the ONSD changes were strongly correlated with ICP variations in their simultaneous measurements of sonographic ONSD and intraparenchymal ICP (12). Recently, Bäuerle et al (28) reported that the mean ONSD was significantly enlarged in an aneurysmal subarachnoid hemorrhage group as compared with a healthy volunteer group ( $6.2 \pm 0.7$  mm vs.  $5.5 \pm 0.5$  mm).

Post-dural puncture headache (PDPH) is suspected to be caused by decreased ICP, and Dubost et al (29) studied the changes in ONSD by US following a lumbar epidural blood patch in 10 patients with PDPH. The measurements of the ONSD showed 4.8 mm (4.5 – 5.1) at the baseline, 5.2 mm (4.9 – 5.7) at 10 minutes, 5.5 mm (5.1 – 6.0) at 2 hours, and 5.8 mm (5.2 – 6.3) at 20 hours. The authors suggested that a sustained increase in ONSD as a surrogate marker of ICP was associated with successful epidural blood patch.

In this study, although the ONSD increased significantly in the 10 minutes following the CEI, this increase was not sustained. Moreover, there was no increase in ICP-related complications such as dizziness, headache, visual acuity, or retinal hemorrhage. This transient, unsustained increase in ONSD may be explained by Grocott and Mutch's observation of preserved autoregulatory mechanisms in a porcine model (3), which was echoed by Giasi et al's human study (30). Giasi et al (30) reported that the venous plasma level of lidocaine following epidural injection was at its peak 15 minutes after administration, and that it decreased afterwards. The authors suggested that the maximal epidural pressure was not reached after more than 15 minutes, which was indirectly the same as the ICP.

Most reported complications presumed to accompany suspected ICP change (such as headache, syncope, LOC, and transient blindness) stem from lumbar epidural blocks in the prone position. Although we found changes in the ONSD after CEI, we could not verify the effect of the prone position. ONSD values above 5.8 mm have been reported to be associated with a 95% risk of raised ICP (i.e., over 20 mmHg) (31). Although the maximum ONSD value did not reach 5.8 mm in our study ( $5.1 \pm 0.4$  mm), we did not demonstrate that this level of ONSD change may result in increased ICP-related complications in patients with specific conditions such as undetected intracranial pathology or severe spinal spondylosis.

There are several possible limitations of this study. First, selection of 14 mL was based on our routine pain practice and not standardized. Many articles have been reviewed regarding volume of normal saline for loss of resistance technique, contrast, and epidural injection (32-35). Although none of article has proposed a guideline of standardized volume, it is assumed that total volume for injection is from minimally 5 – 6 mL to maximally 12 mL. In this point of view, we admit that 14 mL of total volume is a possible cause of bias. Second, a lack of sonographic experience is an obvious limitation to the use of ocular sonography. However, the single anesthesiologist used in this study had had experience performing over 300 transorbital ultrasonographies. The learning curve as described by Tayal et al (36) seems to be rapid. Furthermore, the reliability of the measurements has been shown to be high, with a previous study demonstrating that the measurements were reproducible and presented low inter-observer variability (37). A third limitation lay in the fact that all patients were presumed to have a normal ICP. We did

not actually confirm the presence of a normal baseline ICP by means of lumbar puncture or another method such as computed tomography scans before enrolling the patients. Lastly, although statistical significance was observed in this study, we enrolled a relatively small number of patients. We recognize that future studies increasing the sample size should be performed, with our results being useful as a reference for further randomized controlled studies.

## CONCLUSION

In conclusion, ONSD by ultrasonography began to increase from one minute after the completion of CEI and the most critical increase in ONSD was observed 4 minutes after CEI. Although this increase was not sustained, this result suggests that more attention should also be paid after the completion of CEI. Further work is needed to confirm the effects of the speed and volume of the injection and of the position.

## REFERENCES

- Abbasi A, Malhotra G, Malanga G, Elovic EP, Kahn S. Complications of interlaminar cervical epidural steroid injections: A review of the literature. *Spine* 2007; 32:2144-2151.
- Candido KD, Knezevic N. Cervical epidural steroid injections for the treatment of cervical spinal (neck) pain. *Curr Pain Headache Rep* 2013; 17:314. doi: 10.1007/s11916-012-0314-7.
- Grocott HP, Mutch WA. Epidural anesthesia and acutely increased intracranial pressure. Lumbar epidural space hydrodynamics in a porcine model. *Anesthesiology* 1996; 85:1086-1091.
- Usubiaga JE, Usubiaga LE, Brea LM, Goyena R. Effect of saline injections on epidural and subarachnoid space pressures and relation to postspinal anesthesia headache. *Anesth Analg* 1967; 46:293-296.
- Hilt H, Gramm HJ, Link J. Changes in intracranial pressure associated with extradural anaesthesia. *Br J Anaesth* 1986; 58:676-680.
- Semple AJ, Bisset WI. Transient loss of consciousness after therapeutic caudal block. *Anaesthesia* 1985; 40:380.
- Abouleish E. Intracranial hypertension and caudal anaesthesia. *Br J Anaesth* 1987; 59:1478-1479.
- Sunagawa H, Murayama T. Syncope after therapeutic caudal epidural block: Report of two cases. *J Anesth* 2006; 20:156-157.
- Young WF. Transient blindness after lumbar epidural steroid injection. *Spine* 2002; 27:E476-E477.
- Hansen HC, Helmke K. Validation of the optic nerve sheath response to changing cerebrospinal fluid pressure: Ultrasound findings during intrathecal infusion tests. *J Neurosurg* 1997; 87:34-40.
- Geeraerts T, Launey Y, Martin L, Kumar M, Gore MA. Ultrasonography of the optic nerve sheath may be useful for detecting raised intracranial pressure after severe brain injury. *Intensive Care Med* 2007; 33:1704-1711.
- Geeraerts T, Merceron S, Benhamou D, Vigue' B, Duranteau J. Non-invasive assessment of intracranial pressure using ocular sonography in neurocritical care patients. *Intensive Care Med* 2008; 34:2062-2067.
- Harbison Kimberly H, Shah S, Marill K, Noble V. Correlation of optic nerve sheath with direct measurement of intracranial pressure. *Acad Emerg Med* 2008; 15:201-204.
- Geeraerts T, Merceron S, Benhamou D, Vigue' B, Duranteau J. Non-invasive assessment of intracranial pressure using ocular sonography in neurocritical care patients. *Intensive Care Med* 2008; 34:2062-2067.
- Moretti R, Pizzi B. Reliability of optic nerve ultrasound for the evaluation of patients with spontaneous intracranial hemorrhage. *Neurocrit Care* 2009; 11:406-410.
- Moretti R, Pizzi B. Ultrasonography of the optic nerve in neurocritically ill patients. *Acta Anaesthesiol Scand* 2011; 55:644-652.
- Dubourg J, Javouhey E, Geeraerts T, Messerer M, Kassai B. Ultrasonography of optic nerve sheath diameter for detection of raised intracranial pressure: A systematic review and meta-analysis. *Intensive Care Med* 2011; 37:1059-1068.
- Muhle C, Metzner J, Weinert D, Falliner A, Brinkmann G, Mehdorn MH, Heller M, Resnick D. Classification system based on kinematic MR imaging in cervical spondylitic myelopathy. *AJNR* 1998; 19:1763-1771.
- Bäuerle J, Lochner P, Kaps M, Nedelmann M. Intra- and interobserver reliability of sonographic assessment of the optic nerve sheath diameter in healthy adults. *J Neuroimaging* 2012; 22:42-45.
- Manchikanti L, Nampiaparampil DE, Candido KD, Bakshi S, Grider JS, Falco FJ, Sehgal N, Hirsch JA. Do cervical epidural injections provide long-term relief in neck and upper extremity pain? A systematic review. *Pain Physician* 2015; 18:39-60.
- Manchikanti L, Falco FJ, Diwan S, Hirsch JA, Smith HS. Cervical radicular pain: The role of interlaminar and transforaminal epidural injections. *Curr Pain Headache Rep* 2014; 18:389. doi: 10.1007/s11916-013-0389-9.
- Warr AC, Wilkinson JA, Burn JM, Langdon L. Chronic lumbosacral syndrome treated by epidural injection and manipulation. *Practitioner* 1972; 209:53-59.
- Botwin KP, Gruber RD, Bouchlas CG, Torres-Ramos FM, Freeman TL, Slaten WK. Complications of fluoroscopically guided transforaminal lumbar epidural injections. *Arch Phys Med Rehabil* 2000; 81:1045-1050.
- Park Y, Ahn JK, Sohn Y, Jee H, Lee JH, Kim J, Park KD. Treatment effects of ultrasound guided selective nerve root block for lower cervical radicular pain: A retrospective study of 1-year follow-up. *Ann Rehabil Med* 2013; 37:658-667.
- Jee H, Lee JH, Kim J, Park KD, Lee WY, Park Y. Ultrasound-guided selective nerve root block versus fluoroscopy-guided transforaminal block for the treatment of radicular pain in the lower cervical spine: A randomized, blinded, controlled study. *Skeletal Radiol* 2013; 42:69-78.
- Narouze S, Peng PW. Ultrasound-guided interventional procedures in pain medicine: A review of anatomy, sonography, and procedures. Part II: Axial structures. *Reg Anesth Pain Med* 2010;

- 35:386-396.
27. Geeraerts T, Newcombe VF, Coles JP, Abate MG, Perkes IE, Hutchinson PJ, Outtrim JG, Chatfield DA, Menon DK. Use of T2-weighted magnetic resonance imaging of the optic nerve sheath to detect raised intracranial pressure. *Crit Care* 2008; 12:R114.
  28. Bäuerle J, Niesen WD, Egger K, Buttlar KJ, Reinhard M. Enlarged optic nerve sheath in aneurysmal subarachnoid hemorrhage despite normal intracranial pressure. *J Neuroimaging* 2016; 26:194-196.
  29. Dubost C, Le Gouez A, Zetlaoui PJ, Benhamou D, Mercier FJ, Geeraerts T. Increase in optic nerve sheath diameter induced by epidural blood patch: A preliminary report. *Br J Anaesth* 2011; 107:627-630.
  30. Giasi RM, D'Agostino E, Covino BG. Absorption of lidocaine following sub-arachnoid and epidural administration. *Anesth Analg* 1979; 58:360-363.
  31. Dubost C, Le Gouez A, Jouffroy V, Roger-Christoph S, Benhamou D, Mercier FJ, Geeraerts T. Optic nerve sheath diameter used as ultrasonographic assessment of the incidence of raised intracranial pressure in preeclampsia: A pilot study. *Anesthesiology* 2012; 116:1066-1071.
  32. Steven D. Waldman MD. Cervical epidural block. In: *Atlas of Interventional Pain Management*. 4th ed. Elsevier Saunders, Philadelphia, 2015, pp 178-187.
  33. Candido KD, Knezevic N. Cervical epidural steroid injections for the treatment of cervical spinal (neck) pain. *Curr Pain Headache Rep* 2013; 17:314. doi: 10.1007/s11916-012-0314-7.
  34. Samuel K. Rosenberg. Cervical epidural steroid injections. *Techniques in Regional Anesthesia and Pain Management* 2005; 9:58-61.
  35. Castagnera L, Maurette P, Pointillart V, Vital JM, Erny P, Sénégas J. Long-term results of cervical epidural steroid injection with and without morphine in chronic cervical radicular pain. *Pain* 1994; 58:239-243.
  36. Tayal VS, Neulander M, Norton HJ, Foster T, Saunders T, Blaivas M. Emergency department sonographic measurement of optic nerve sheath diameter to detect findings of increased intracranial pressure in adult head injury patients. *Ann Emerg Med* 2007; 49:508-514.
  37. Ballantyne SA, O'Neill G, Hamilton R, Hollman AS. Observer variation in the sonographic measurement of optic nerve sheath diameter in normal adults. *European Journal of Ultrasound* 2002; 15:145-149.

