

## Literature Review

## Ganglion Cyst at the Proximal Tibiofibular Joint in a Patient with Painless Foot Drop

Abdulmuhsen Alsahhaf, MD, and Waleed M. Renno, PhD

From: Kuwait University Faculty of  
Medicine  
Safat, Kuwait

Address Correspondence:  
Waleed M. Renno, PhD  
Kuwait University Faculty of  
Medicine  
P.O. Box 24923  
Safat, Kuwait 13110  
E-mail: wrenno@hsc.edu.kw

Disclaimer: There was no external  
funding in the preparation of this  
manuscript.

Conflict of interest: Each author  
certifies that he or she, or a member  
of his or her immediate family, has  
no commercial association (i.e.,  
consultancies, stock ownership,  
equity interest, patent/licensing  
arrangements, etc.) that might pose  
a conflict of interest in connection  
with the submitted manuscript.

Manuscript received: 01-30-2016  
Revised manuscript received: 02-  
06-2016

Accepted for publication:  
03-10-2016

Free full manuscript:  
[www.painphysicianjournal.com](http://www.painphysicianjournal.com)

Entrapment neuropathies of the fibular nerve and its branches are often underdiagnosed due to the lack of reliable diagnosis using clinical examination and electrophysiologic evaluation. Most fibular nerve compressions may be classified into 2 broad categories: (a) mechanical causes, which occur at fibrous or fibro-osseous tunnels, and (b) dynamic causes related to nerve injury during specific limb positioning. Foot drop resulting from weakness of the dorsiflexor muscles of the foot is a relatively uncommon presentation and closely related to L5 neuropathy caused by a disc herniation. However, we herein describe a rare case of usually painless foot drop triggered by a cyst at the proximal tibiofibular joint compressing the deep fibular nerve. The presence of multilevel disc diseases made the diagnosis more difficult. Foot drop is highly troubling, and health care providers need to broaden their search for the imperative and overlapping causes especially in patients with painless drop foot, and the treatment is variable and should be directed at the specific cause. The magnetic resonance imaging (MRI), including high-resolution and 3D MR neurography, allows detailed assessment of the course and anatomy of peripheral nerves, as well as accurate delineation of surrounding soft-tissue and osseous structures that may contribute to nerve entrapment. Knowledge of normal MRI anatomy of the nerves in the knee and leg is essential for the precise assessment of the presence of peripheral entrapment conditions that may produce painless or painful drop foot. In conclusion, we stress the importance of preoperative anatomic mapping of entrapment neuropathies to minimize neurological complications.

**Key words:** Foot drop, fibular nerve, ganglion cyst, proximal tibiofibular joint

**Pain Physician 2016; 19:E1147-E1160**

Lower limb neurologic symptoms are a common clinical grievance. Particularly, sciatica is a frequent complaint in the middle-aged group with the chief symptom being a pain in the lower back extending down one or both lower limbs. Rarely it is accompanied by foot drop when one of its nerve roots (mainly L5) is severely compressed. A herniated disc at L4/5 is usually the most common scenario. The other causes of foot drop include intraneural cyst, synovial cyst, or even syndesmophyte at the proximal (superior) tibiofibular (PTF) joint compressing on the common or the deep fibular nerve. Since the deep fibular nerve is

a motor supply for the anterior compartment of the leg and the dorsum of the foot muscles, it can cause painless foot drop, with a small pure patch between the first and the second web spaces of the toes that is usually too small to be felt.

### **ANATOMY**

The PTF joint is a synovial joint formed by the articulation of the posterolateral aspect of the lateral tibial condyle of the tibia medially and the flat facet of the fibular head laterally forming a plane-type synovial joint. A tense joint capsule surrounds the joint

and attaches to the tibia and fibula at the margin of the articular surface. The anterior and posterior PTF ligaments strengthen the joint capsule that runs in a superomedial direction from the head of the fibula to the tibial condyle. The biceps femoris muscle insertion onto the fibular head and the lateral collateral ligament gives the joint an additional strength and support. The popliteus muscle tendon lies posterior to the joint and is separated from the lateral tibial condyle by the popliteal bursa that communicates with the tibiofibular synovial cavity. In 10 – 60% of adults, variable synovial communication between PTF joint and the knee joint exist and because of this communication, the PTF joint might be seen as a fourth compartment of the knee to explain elusive knee problems (1). The common fibular nerve (CFN) and the nerve to the popliteus innervate the joint. Having an isolated joint injury to the PTF joint is rare. PTF injuries more commonly occur in conjunction with other ligamentous or osseous pathologies.

The sciatic nerve (SN) starts in the pelvis by joining the ventral rami of the L4-S3 SN roots. It leaves the pelvis through the greater sciatic foramen below the piriformis and descends between the ischial tuberosity medially and the greater trochanter laterally in the gluteal region. At the superior angle of the popliteal fossa, the SN divides subsequently into 2 terminal branches the CFN and the tibial nerve (TN). The SN is a mixed nerve that contains both motor and sensory fibers. The motor branches supply the posterior compartment of the thigh muscles as well as hip and knee joint. However, sensory branches supply the whole tibial and foot areas except the anteromedial tibial region and medial margin of the foot.

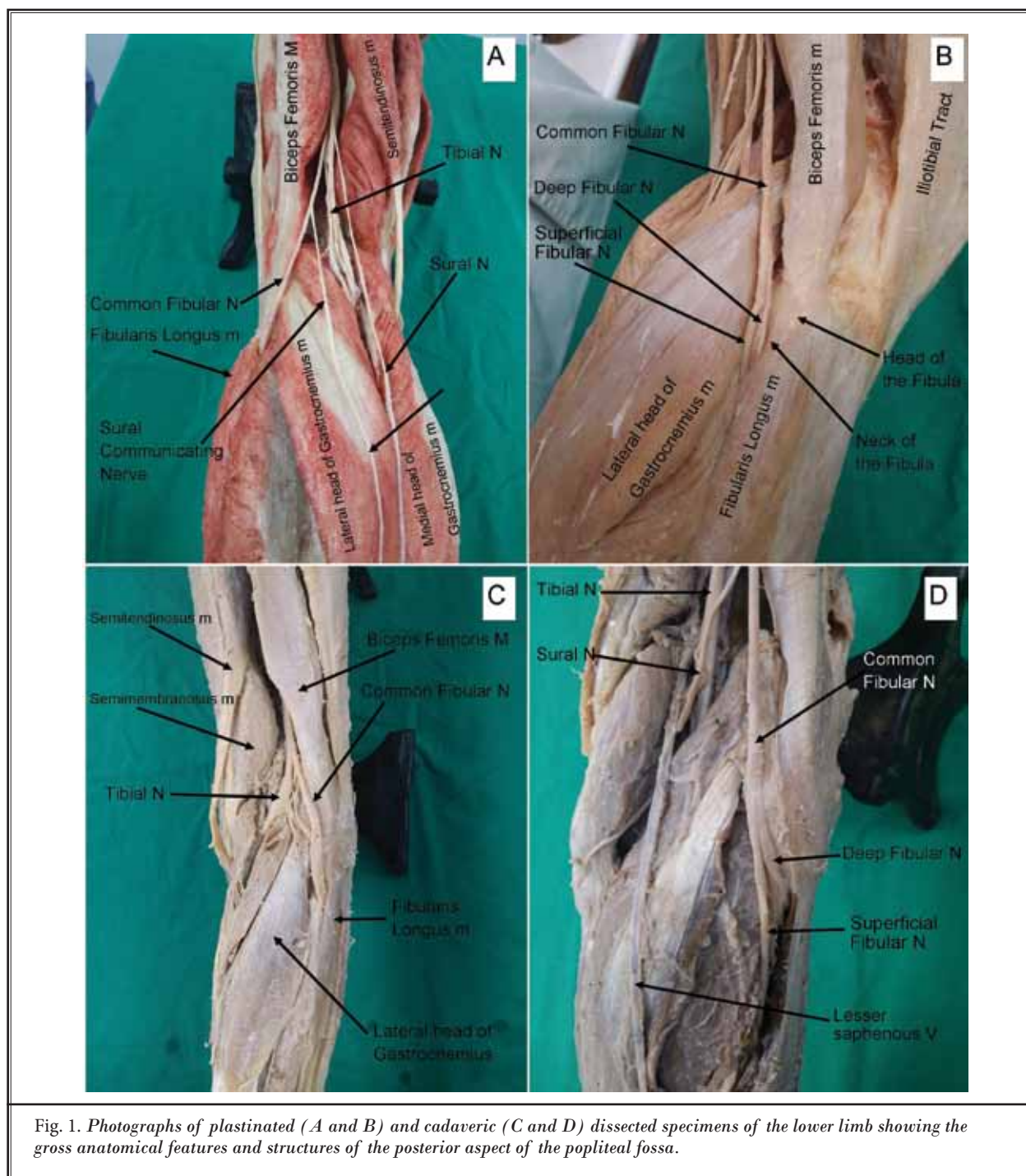
The CFN is the smaller of the 2 terminal branches of the SN. It runs downwards through the popliteal fossa and closely follows the medial border of the biceps tendon muscle. The CPN descends along the lateral aspect of the popliteal fossa and curves around the anterolateral aspects of the fibular head and neck (Fig. 1). It leaves the popliteal fossa by crossing the lateral head of the gastrocnemius superficially and passes behind the head of the fibula. It passes lateral to the anterior compartment musculature, winds laterally around the neck of the fibula, and pierces the peroneus longus muscle. Here, it divides into the superficial and the deep fibular nerves (Fig. 1). As the fibular nerve lies on the lateral aspect of the neck of the fibula, it is subcutaneous and can be easily rolled against the bone and severely damaged by a direct trauma (Fig. 1). Symptoms of CFN injury (foot drop) may include loss of dorsal flexion, pain,

weakness, numbness, loss of function of the foot, and high-stepping walk (steppage gait or foot drop gait).

The DFN is mainly a motor nerve supplying the tibialis anterior, extensor digitorum longus, fibularis tertius, and the extensor hallucis longus. Meanwhile, its sensory superficial cutaneous supply is limited to the first web space between the first and the second toes. It is well accepted that the most common site at which the CFN is affected by compression, trauma, traction, masses, and surgery is within and around the fibular tunnel. A cadaveric study of 26 lower limbs (13 preserved adult cadavers; 11 men and 2 women) showed that several innate, anatomical protective mechanisms may offer the required protection for the nerve. Tethering of the CFN to both the tendon of the biceps femoris and the reinforced fascia and the particular arrangement of the deep fascia, fibular head and soleus, and gastrocnemius muscles are very crucial for its protection (2). To preserve these mechanisms whenever possible when decompressing the CFN, the surgical approach should be planned and varied according to the underlying etiology.

The second branch of the CPN is the superficial fibular nerve (SFN) traveling within the lateral compartment of the leg. Variation of the SFN can, however, exist even at its origin. A cadaveric study by Deutsch and associates (3) has shown that in 10% of legs the CFN divides into deep and superficial branches proximal to the knee joint. In 30% of the specimens, a separate cutaneous branch stemmed from the CFN trunk, a branch that had not previously been identified in the literature (3). Distal to the knee joint at the proximal neck of the fibula, the SFN passes between fibular muscles and the lateral side of extensor digitorum longus and gives off motor branches to the fibularis longus and brevis of the lateral compartment of the leg and sensory innervation to the anterolateral leg (4).

The SFN (L4-S1) anatomy is often described relative to the fasciae of the lower leg. The crural fascia invests all the muscles of the lower leg. Laterally, the crural fascia gives attachment to the intermuscular septum separating the anterior and lateral muscle compartments. Commonly, at about half way down the lower leg, the SFN pierces the deep crural fascia and becomes subcutaneous over the lateral compartment, running superficially over the extensor retinaculum of the ankle. The subcutaneous terminal branches of the SFN (medial dorsal cutaneous nerve and intermedial dorsal cutaneous nerve) supply the majority of the skin on the dorsum of the foot, excluding web space between hallux



and second digit in addition to the anterolateral distal 1/3 of the leg. Clinically, along its course, the SFN may be entrapped and stretched during ankle sprains and ankle twisting or compressed where it exits the deep fascia of the leg leading to pain and paresthesias over

the dorsum of the foot. Also, the SFN may be directly damaged by fractures of the proximal fibula or perforating injury to the lateral leg. These injuries, in turn, may produce loss of eversion (injury of motor supply of fibularis longus and brevis muscles) as well as loss

of sensation over most of the dorsum of the foot and anterolateral aspect of the distal leg.

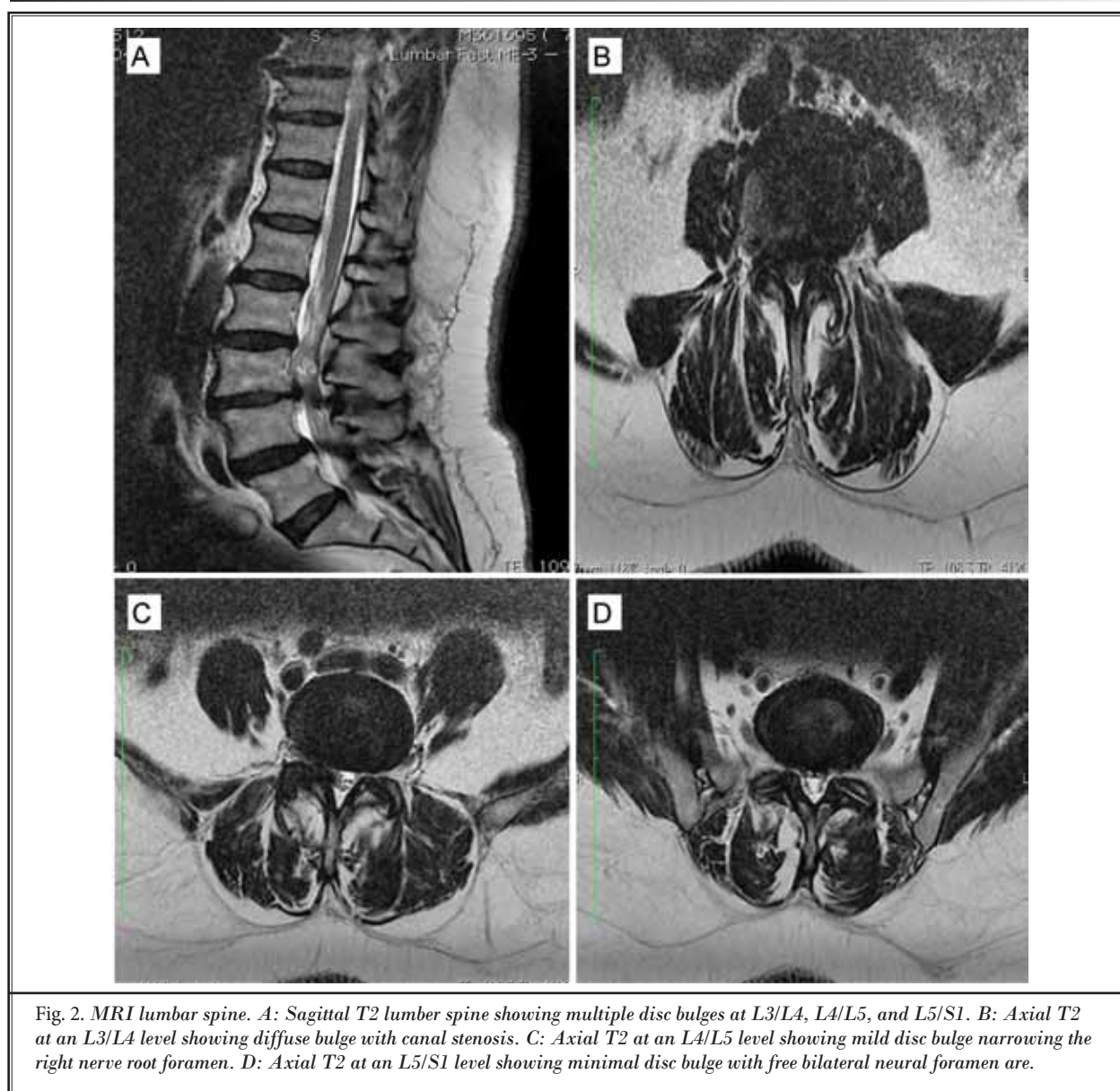
### CASE REPORT

A 52-year-old woman presented to our hospital with a 3-month history of left-sided painless foot drop but with no history of sciatica or lower back pain. She described her foot drop as a sudden onset. Her magnetic resonance imaging (MRI) showed L3/4 diffuse disc bulge causing canal stenosis and L4/5 and L5/S1 mild diffuse disc bulge (Fig. 2). On examination, the patient showed no tenderness on the back. The straight leg

raise (SLR) test was normal bilaterally. She was unable to dorsiflex her left foot compared with a normal right foot dorsiflexion.

The MRI lumbar spine findings were not corresponding with the severity of the patient's symptoms and signs, mainly the painless foot drop, as she never complained of back or sciatica due to L5 nerve root compression.

Therefore, a clinical suspicion of a pathology at the level of the knee joint was raised for which an MRI of the knee joint was ordered. The result came back showing a 1 cm cyst at the PTF joint along the path of the deep fibular nerve (Fig. 3).



### Minimally Invasive Surgical Intervention

Patient consent was obtained for a computed tomography (CT) guided cyst fenestration, pulsed radiofrequency modulation, and steroid injection. Under a complete aseptic environment, a lateral to medial approach of the left knee for needle insertion was used under local anesthesia. The needle was then progressively introduced into the middle of the cyst, and 0.2 mL of contrast media was injected to outline the cyst wall (Fig. 4). Multiple needle tiny fenestrations followed by pulsed radiofrequency modulation (temperature 42° C for 180 seconds, the radiofrequency needle used was 50 mm with a 5 mm active tip, straight and sharp) after confirmation of the motor response of the deep fibular nerve at 0.3 volts that was illustrated by foot plantarflexion. At the end of the procedure, the cyst was injected with 1 mL of dexamethasone (4 mg) and 2 mL of bupivacaine (0.25%).

The patient was referred for a physiotherapy course one week post-surgical procedure to restore the muscle strength. Two months later, the patient was seen again for post-procedural evaluation and assessment. She showed complete resolution of her dorsiflexion of the left foot with normal strength.

### Discussion

Sciatica pain is a common complaint among the middle-aged population. However, the motor deficit is not as common. Many causes may present with sciatica. The disc herniation compressing the fifth lumbar nerve is the commonest cause, the fourth lumbar and the first sacral are less commonly sources of such pain. Patients with painless drop foot due to lumbar degenerative disease usually undergo surgery to improve the dorsiflexion palsy of the ankle. In a recent study of 20 patients presenting with painless drop foot caused mainly by impairment of the L5 nerve root, 65% of the patients recovered from drop foot after lumbar spine surgery for degenerative lumbar diseases (5). The duration of palsy had the greatest effect on recovery and improvement of the strength of the tibialis anterior muscle (5).

In most cases, the etiology of the painless drop foot encompasses a peripheral injury to the CFN. These patients usually present with lower motor neuron findings on clinical examination. In contrast, if upper motor neuron findings are present, a central lesion should be suspected, and appropriate imaging studies are performed.

Other less known causes are compression of the common or the deep fibular nerve at the PTF joint such

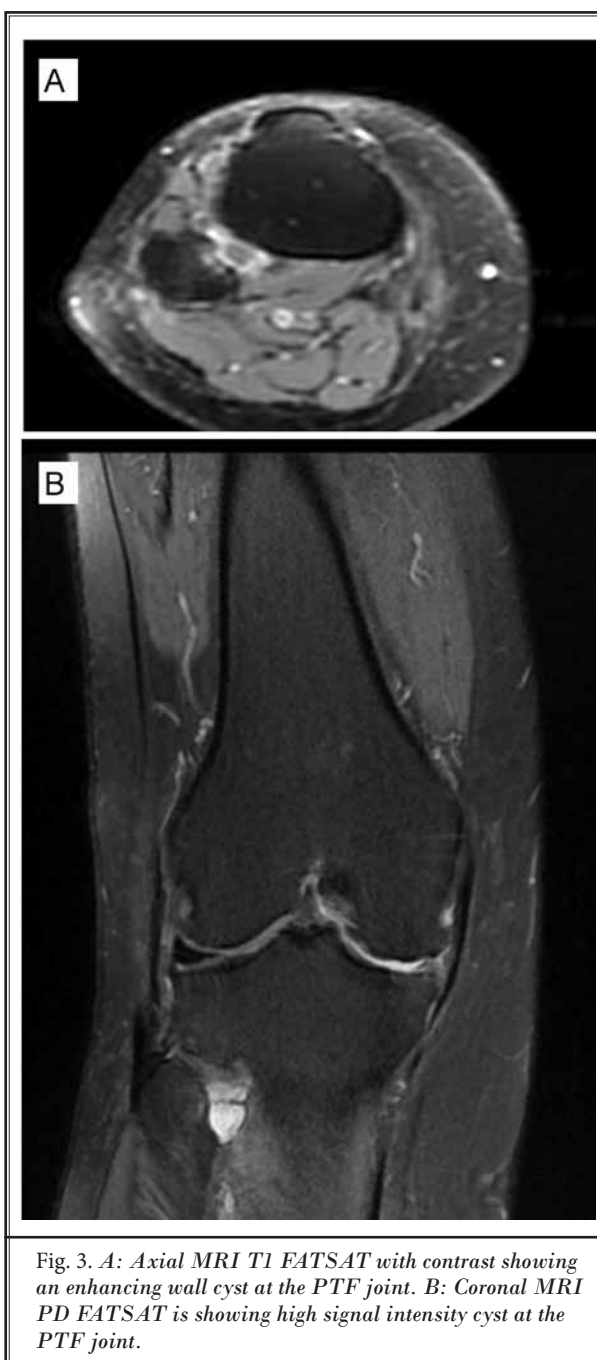


Fig. 3. A: Axial MRI T1 EATSAT with contrast showing an enhancing wall cyst at the PTF joint. B: Coronal MRI PD EATSAT is showing high signal intensity cyst at the PTF joint.

as calcified syndesmosis or tumors (e.g., chondrosarcoma) which sometimes could be diagnosed by plain radiograph. Our case had a unique cause that of a synovial cyst in close vicinity of the DFN that usually cause painless drop foot. This case presented a challenge of double causes in the same region which made the diagnosis even more difficult.

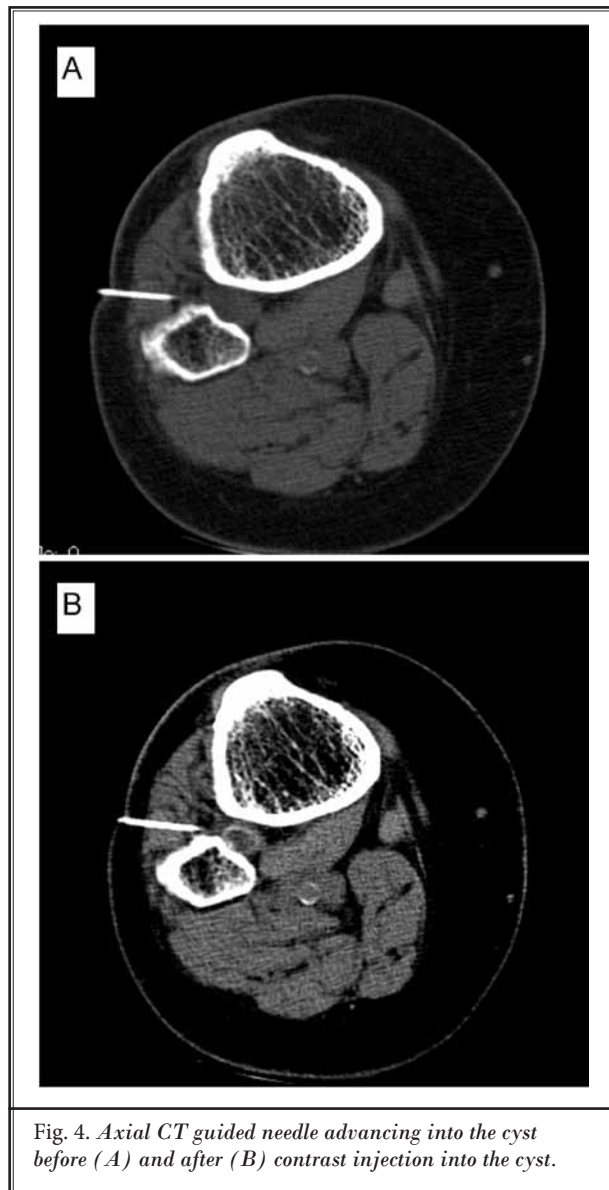


Fig. 4. Axial CT guided needle advancing into the cyst before (A) and after (B) contrast injection into the cyst.

It was clearly explained to the patient that we needed to treat 2 different pathologies, her sciatica due to irritation of the left L4 and L5 nerve roots and the foot drop caused by compression of the DFN at the PTF joint. Earlier, Robin and coworkers (6) reported a painless foot drop case with sudden onset of acute fibular neuropathy during a golf game and axonal loss and probably proximal conduction block resulting from a ganglion cyst. MRI demonstrated a mass arising from the PTF joint extending along the CFN (6). Interestingly, Gilchrist et al (7) described a case with painless foot drop and lower motor findings on examination that

was diagnosed with multiple sclerosis. This case demonstrates that painless foot drop can disguise under multiple sclerosis in some patients (7).

Foot drop can be temporary or permanent and is a symptom of an underlying problem, rather than a disease itself. A variety of specific pathological and clinical conditions could be associated with or causing the drop foot. The causes of foot drop may be allocated into 3 broad categories: neurologic, muscular, and anatomic. Neurological conditions (brain or spinal disorders) include stroke, multiple sclerosis, Parkinson's disease, and motor neuron diseases such as multiple sclerosis, cerebral palsy, and Charcot-Marie-Tooth disease. Most commonly, foot drop is caused by an injury to the fibular nerve because it is located very superficially. It may be damaged easily and is associated with pain or numbness along the shin or the top of the foot. Sports injuries, hip or knee replacement surgery, spending long hours sitting cross-legged or squatting, diabetes, childbirth, a large amount of weight loss, or injury to the nerve roots in the spine are a few of the conditions that damage or press the peroneal nerve. Also, drug toxicities (adverse reactions to drugs or alcohol) may lead to drop foot. Muscle disorders that cause the muscles to weaken progressively or deteriorate may cause foot drop. Although less common, muscle diseases such as muscular dystrophy, amyotrophic lateral sclerosis (Lou Gehrig's disease), or polio may produce drop foot. Foot drop is highly troubling, and health care providers need to be aware that these causes may overlap, and the treatment is variable and should be directed at the specific cause. Broadening the search of the cause of the foot drop is imperative, especially in the patients with painless drop foot.

#### Exceptional Causes of Fibular Nerve Palsy

Common fibular nerve palsy is mostly related to internal or external compression. The external compression may be related to trauma such as knee fractures, total knee arthroplasty, or hematoma after a direct blow. Several unprecedented causes of fibular nerve palsy were reported in the literature. Recently, a case of a DFN palsy in an adolescent boy that coincided with a significant growth spurt and producing transient neurapraxia was reported. This growth spurt resulted in temporary compression of the DFN at the level of the knee (8). In another uncommon fibular nerve palsy, the nerve was entrapped on the head and the neck of the fibula by compression stockings (used for prophylaxis of deep venous thromboembolism after surgery) (9). The

patient had left foot drop and difficulty in walking during gait assessment. The needle electromyography confirmed total axonal degeneration of the left CFN with denervation potentials. After surgery, the compression stockings had rolled down, and a linear impression mark was observed under its upper edge at the proximal part of the left cruris. This case pointed to the importance of the size and length of the compression stockings and proper skin control in avoiding the risk for fibular nerve palsy (9). In another unique case, the DFN as well as the anterior tibial artery and vein were entrapped by a spiral distal tibial shaft fracture, causing partial non-union in the absence of clinical symptoms or signs of neurovascular entrapment. This case stressed the importance of recognizing the distinct possibility of entrapment and injury to the CFN as well as the anterior tibial vessels when managing a fracture involving the distal third of the tibial shaft (10). Entrapment of the DFN may also result from a spiral fibular fracture (11). The CFN palsy also could be due to a posttraumatic hematoma after a sport-related injury that may clinically present with muscle weakness with or without sensory abnormality (12).

The anatomic variant at the knee joint, such as the presence of fabella, may compress the CFN. Fabella is an accessory ossicle or fibrocartilaginous typically found in the lateral head of the gastrocnemius in approximately 20% (range 10 – 30%) of the population. The fabella articulates with its respective (medial or lateral) femoral condyle. A case in a 67-year-old man with pain down the lateral aspect of the left lower limb of 18 months duration was diagnosed with a palpable fabella. Nerve conduction studies confirmed a CFN neuropathy at its level, and the dynamic ultrasound scan and MRI of the knee showed the fabella to be impinging on the nerve (13). The patient recovered fully after one year following the excision of fabella.

Superficial nerve injuries are very common during varicose vein surgery. Preoperative anatomic mapping of the highly variable venous and neural systems in the area of ablation is essential to minimize neurological complications. Although the use of minimally invasive procedures has remarkably reduced the likelihood of neural injury, endovenous laser ablation and endovenous radiofrequency ablation were recently reported to cause neural damage in the lower limb during surgical vein stripping. Shahid and coworkers (14) reported 2 unique cases: ablation of the lesser saphenous vein that resulted in injury to the proximal common peroneal and tibial as well as distal sciatic nerves, and ablation of the vein of

Giacomini that led to a CFN injury. Similarly, another 2 cases of CFN injury after small saphenous vein stripping were described and stressed the importance of careful preoperative ultrasonographic investigation of the anatomy of the vein. Further, determining the location of the saphenopopliteal joint, and careful dissection far from fibular nerve and restricted to the popliteal fossa should be implemented during vein stripping (15).

Though unusual, in a suddenly isolated foot drop caused by an infarction in the primary motor cortex, a patient presented with mimicking lumbar radiculopathy (16). In an unusual incident, Kyavar and Heckmann (17) described a case of a 48-year-old otherwise healthy man presenting with a bilateral common fibular palsy due to lifting weights and his upper body from a deep squatting position with broadly positioned legs akimbo in a hitherto unusual intensity. The authors considered 2 pathophysiological mechanisms. The first is the stretching of the nerve at the fascia of the fibularis longus muscle and along the fibula neck. The second is the compression of the nerve while squatting with weights loaded and with strongly activated anterior tibial and peroneal muscles (17). The possibility of both central and peripheral causes should be always considered when dealing foot drop cases.

In a 6-year-old child presented with subacute foot drop. Neurophysiologic and radiologic studies revealed a fibular nerve compression secondary to fibular exostosis (a benign new growth projecting from a bone surface and characteristically capped by cartilage) (18). Interestingly, further neurophysiologic and ultrasonographic evaluation showed the presence of an accessory fibular nerve branch that caused gastrocnemius involvement. In a study of 17 children with pediatric fibular mononeuropathies, 16 children (94%) and one child (6%) presented with foot drop and lower extremity pain, respectively (19). Causes included compression in 10 children (59%), trauma in 3 children (18%), entrapment in 3 children (18%), and indeterminate in one child (5%). Further, the level of the pediatric fibular mononeuropathic lesion was the CFN in 10 children (59%), the DFN in 2 children (12%), and the SFN in one child (5%) (19). Although very rare, pseudoaneurysms of the popliteal artery in the case of a 4-year-old boy presenting with a painful palpable mass in the right popliteal fossa due to blunt trauma 2 years earlier showed mild, painless right foot-drop and difficulty toe-walking on the same side (20). Neurological examination accompanied with triplex ultrasound and CT-angiography demonstrated a mild, isolated, peripheral mononeuropathy of the right

fibular nerve (20).

In summary, peripheral nerve entrapments are a relatively rare and heterogeneous group of nerve disorders including a wide variety of etiologies and clinical presentations (21). Neuropathies of the lower limbs are often encountered after trauma or iatrogenic injury or by entrapment at areas of anatomic restriction. Symptoms may initially be concealed by concomitant trauma or recovery from surgical procedures (22). A thorough understanding of the motor and sensory functions of the lower limb nerves is crucial in recognizing and localizing nerve injury.

### **Ganglion Cysts**

Ganglion cysts causing peripheral neuropathies in the lower limbs are rare and unlikely to cause severe complications. The most frequent location of occurrence is the CFN and its branches, at the level of the fibular neck. Few cases were reported in the literature describing painless drop foot with rare causes. A case of sudden onset of DFN neuropathy with axonal loss and proximal conduction block resulting from a ganglion cyst was reported in which the MRI demonstrated a mass arising from the PTF joint extending along the fibular nerve (23). Recently, Ozend et al (24) described a case of a patient who was referred to a vascular surgeon with a diagnosis of vascular intermittent claudication and deep venous thrombosis. The Doppler ultrasound examination of the lower extremity and calculation of the ankle-brachial index found no abnormal pathological findings. However, careful physical examination revealed soft swelling and tenderness around the fibular head and neck accompanied by weakness in the foot eversion and dorsiflexion. Unlike our case, the patient had pain and tingling in the distribution of the fibular nerve. Electromyogram assessment and physical examination confirmed a diagnosis of compression neuropathy of the CFN by a lesion at the right PTF region. MRI revealed a fluid-filled, lobulated mass indicating a ganglion cyst. One month after decompression, the patient recovered completely. Fast diagnosis and instantaneous management are essential for rapid and comprehensive recovery (24). A synovial cyst is a rare cause of compression neuropathy, and its differential diagnosis can be misleading but can be treated easily with surgical excision. In a 30-year-old patient admitted with abrupt drop foot was diagnosed with DFN palsy due to compression of a synovial cyst (25). Very recently, Lai and co-workers (26) diagnosed a similar case where a ganglion cyst compressed the CFN at the fibular head causing a

foot drop using a combination of ultrasound imaging and electrodiagnostic studies.

Fibular nerve entrapment is most common in the popliteal fossa but is rarely caused by a ganglion. Synovial cysts are fluid-filled masses lined with synovium and situated within or around joints. The main symptoms are pain and/or neurological deficits. A recent study of 17 cases with clinical compression neuropathy caused by para-articular cysts proposed the unifying articular theory to clarify its true etiologic nature (27). The authors used 8 intraneural and 9 extraneural cysts to propose a diagnostic protocol that includes electromyography and ultrasound, followed by MRI to characterize the cyst and achieve the optimal patient outcome (27). The proposed treatment protocol for all atypical peripheral compression neuropathies comprises of (1) ligation of the pedicle connecting the cyst with the afflicted joint, (2) decompression of the nerve, and (3) disarticulation of the PTF joint (in the case of fibular nerve involvement). This protocol produced good to excellent outcome, and cyst recurrence was only observed in 3 intraneural cases (18%). The early correct diagnosis, simple exoneural dissection, and atraumatic epineurotomy are necessary for the successful treatment of fibular intraneural ganglion. Three cases with fibular-intraneural ganglion were operated on with extraneural decompression and epineurotomy within 4 months after commencing of drop foot, 2 cases demonstrated intraneural ganglion connecting to the articular branch and traversing to the deep and common fibular nerve (28). The disruption of the stalk in the articular branch is a key point to prevent recurrence. In a case of foot drop due to an extraneural ganglion of the PTF syndesmosis palsy the DFN, the diagnosis was made preoperatively using MRI (29). After correctly identifying and tracing the common peroneal nerve and its branches, the ganglion cyst was removed, the patient was pain-free and asymptomatic except for cutaneous anesthesia in the distribution of the deep peroneal nerve (29).

Although compressions of the CFN by synovial cysts are rare, 60 cases have been described since 1921 (30). Ghossain et al (31) reported a case of compression of the fibular nerve by a simple extraneural ganglion and emphasized considering this diagnosis in every patient who is complaining of pain or paralysis in the territory of the fibular nerve (31). The prognosis depends on early diagnosis, non-mutilating surgery for the nerve, and ligation of an eventual stalk joining the ganglion to the articulation. In another 2 cases of unenhanced lesion of mucoid density cysts of the CFN at the knee, CT scanning was



used as a diagnostic tool followed by surgical removal (32). In a 7-year-old child, extrinsic compression palsy of the fibular nerve by a painful synovial cyst developed from the PTF joint was diagnosed by an electromyogram and an MRI (30). In all cases, recurrence is not infrequent and the longer the delay before intervention, the less satisfactory the recovery will be. In 1998, De Schrijver and colleagues (33) reported 3 cases of ganglion cysts arising from the PTF joint and compressing the CFN. In one instance the ganglion cyst arising from the PTF joint found its course along the CFN causing pain, but no neurological deficit. In the other 2 cases, the cysts caused only a progressive fibular nerve palsy (33). In 3 cases of synovial cysts of the PTF joint reported in another study, an intramuscular cyst was found to be responsible for paralysis of the anterolateral leg muscles (34). In a unique case of a 55-year-old man with swelling in the region of the right leg with a one-week history of foot drop, MRI revealed a lobulated, elongated cystic-appearing mass anterior to the head of the fibula (35).

The synovial cysts of the PTF joint exist in 2 macroscopic forms: extraneural cysts and intraneural cysts. A literature review of pediatric cases of CFN palsy due to extraneural cysts showed 3 pediatric cases and about 60 cases reported in adults (6). In children, this uncommon condition must be diagnosed and treated rapidly because a full clinical recovery is conceivable even in the presence of severe clinical and electrophysiological symptoms. However, follow-up is needed because recurrence is possible (6).

### **Pathogenesis of Ganglion Cysts**

The pathogenesis of para-articular cysts is still poorly understood and controversial. The simple (extraneural) cysts are thought to be stemming from joints, but connections do not always exist (articular theory). However, many intraneural ganglion cysts are formed within nerves or vessels according to the degenerative theory. Spinner and coworkers (36-40), who extensively have studied the different aspect of fibular cysts and their pathogenesis and managements, believe that simple and complex ganglion cysts are joint-related (articular theory), but joint connections are often not readily identified with routine imaging or at surgery. A recent review study of 17 cases of clinical compression neuropathy caused by para-articular cysts (8 intraneural and 9 extraneural cysts) were attributed to the articular theory (27). Not identifying and/or treating joint connections frequently leads to cyst recurrence. To enhance the visualization and identification of these joint connections,

the Spinner group created a 3D rendering technique to demonstrate potential joint connections of simple and complex cysts localized to the knee and PTF joints in 4 patients with fibular neuropathy (36). Postoperative MRIs, which were done more than 6 months later, confirmed that there was no recurrence, and the 3D technique allows visualization of "occult" connections not readily identified with standard MRI and reduces the misdiagnosis and cyst recurrence (37). Furthermore, the 3D techniques highlight the important adjacent anatomical structures and their relationships with the ganglionic cysts. The study concluded that the joint-related cysts have a common pathogenesis. These cysts dissect through a capsular rent and follow the path of least resistance. They may form simple cysts by dissecting out into the soft tissue or more complex cysts by dissecting within the epineurium of nerves or adventitia of vessels (along an articular branch) or various combinations of all of these types of cysts (36). Later, analysis of 20 surgically confirmed cases of para-articular cysts arising from the superior tibiofibular joint revealed that 12 cases of fibular intraneural ganglia and 8 cases of extraneural ganglia were connected to the PTF joint (37). The intraneural ganglia were tubular while the extraneural ones were more mass-like. The reproducible MRI identified the joint connection (the tail sign) in para-articular cysts. Further, it distinguished between fibular intraneural and extraneural ganglia (the transverse limb sign and the signet ring sign) at the PTF joint with accuracy and confidence and with subsequent improvement in treatment and patient outcomes (37). Rupture of ganglionic cysts is a frequent complication. In a 20 of 38 intraneural ganglionic cases, Shahid and coworkers (40) showed that the extraneural rupture of an intraneural cyst is due to increased intraarticular pressures transmitted within the cyst and/or elevated extrinsic pressure delivered to the cyst, such as by trauma, similar to the etiology of the rupture of extraneural ganglion cysts (40). The MRI showed signs of rupture as T2 hyperintense fluid surrounding intermuscular fascial planes and enhancement with intravenous contrast consistent with inflammation with a mean maximal diameter of the ruptured intraneural cysts statistically significantly smaller than that of the unruptured cysts (40). Earlier, it was demonstrated that tibial intraneural ganglia in the popliteal fossa are derived from the posterior portion of the PTF joint, in a mechanism similar to that of fibular intraneural ganglia, which arise from the anterior part of the same joint (38).

### Exceptional Ganglion Cysts

The origin of complex intraneural cysts remains unsettled even with recent emerging signs to support their articular origin. The co-existence of intraneural and adventitial cysts has been described due to the proximate neurovascular bundle, i.e., the articular (neural) branch and vessels at the joint capsule. Hébert-Blouin et al (41) described and characterized the adventitial component originating from the PTF joint in patients with fibular (n = 24) and tibial (n = 7) intraneural ganglion cysts. Eleven patients with fibular intraneural ganglion cysts were identified as having a co-existing adventitial component with an extension from the anterior part of the PTF joint capsular vessels and along the anterior tibial vessels. The reproducible anatomy permitted the identification of an imaging pattern: the "vascular U" sign, consisting of cystic anterior tibial vessels running through the interosseous membrane between the proximal tibia and fibula and seen on axial MRIs that were taken at the level of the fibular neck in all cases (41). Intraneural ganglia with extensive longitudinal involvement and remote from a joint have been thought not to have articular connections. The extreme longitudinal propagation of intraneural ganglia makes decompression, and its resection, difficult and leads to intraneural recurrence and poor neurological recovery (42). A patient with a moderate tibial neuropathy was found to have a tibial intraneural ganglion with the cyst's origin from the posterior portion of the PTF joint, with proximal extension within the sciatic nerve to the lower buttock region. Surprisingly, another patient, re-examined 22 years after surgery, had an extensive fibular intraneural ganglion that extended into the SN from the knee to the buttock with a joint connection to the anterior portion of the PTF joint from the fibular articular branch as well as recurrent cyst within the fibular and tibial nerves. The 2 cases demonstrated represent extreme examples of other more typical intraneural cysts and follow the articular (synovial) theory. The degree of longitudinal extension is probably due to high intraarticular pressures within the degenerative joint of origin (42). Alarming progression of a PTF joint ganglion cyst in the fibula that was laid-back for at least 12 years caused destructive and extensive changes in the fibula over a period of 6 years after a total knee arthroplasty (43). Awareness of such a lesion can aid in the diagnosis and prevention of unnecessary aggressive management.

A unique case of intraneural ganglion cyst affecting the DFN was inferred to cystic adventitial disease (CAD)

of the popliteal artery (44). In this case, it was shown that an articular (neural) branch is the conduit between the PTF joint and the main parent nerve for which epineurial dissection of joint fluid can occur. The authors hypothesized that the same principles would apply to CAD and that an articular (vascular) branch would be the conduit from the knee joint leading to dissection of the main parent vessel. Using high-resolution MRI prospectively and intraoperatively, 2 cases with a joint connection through the middle genicular artery (MGA) were identified. The unifying articular theory and the principles introduced for intraneural ganglion cysts apply equally to common and rare sites of adventitial cysts (44). Recently, a new pattern of cyst occurrence in the subparaneurial compartment of the nerve was studied in 63 (56 fibular and 7 tibial) intraneural ganglion cysts in the knee region (45). Six rare cases (5 in the CFN and one in the tibial nerve) were identified with evidence of cyst in the subparaneurial compartment with a new complex lobulated MRI pattern, and their pathogenesis was attributed to the unifying articular theory (45).

### Diagnosis of Fibular Nerve Injury (Foot Drop)

Appropriate diagnosis of drop foot necessitates the skillful attention of experienced neurologists and nerve specialists. The proper diagnosis requires a comprehensive clinical exam, including neurological exams, complete medical history, and electrical testing. Also, imaging studies, such as x-rays or high-resolution 3-Tesla MRI are valuable diagnostic tools. It is crucial to determine the exact cause of foot drop so a proper treatment strategy is planned. The awareness of unique and exceptional causes that may produce painful or painless foot drop is the very essential following basic routine foot drop expected origins.

Electrodiagnostic studies are a valuable diagnostic tool for ganglion cysts. A well-designed electromyography investigation can assist in the confirmation and localization of a nerve lesion, assess severity, and evaluate for other peripheral nerve lesions, such as plexopathy or radiculopathy (22). Further, high-resolution imaging arthrography, especially with physiological loading and delayed imaging, can demonstrate the difficult or undetected communication between the tibiofemoral and PTF joints more consistently than unenhanced anatomic studies (46). The association of ultrasonographic and neurophysiologic studies is crucial in identifying the etiopathological mechanism and anatomical picture and provides clinicians and surgeons with valuable information in planning the best therapeutic approach

(18). As an example, a rare tibial intraneural ganglion cyst (derived from the posterior aspect of the PTF joint) with co-existing adventitial cysts may be visualized with the vascular U sign. This new imaging pattern can improve the identification of adventitial cysts at the level of the PTF joint (41).

It is worth noting that the normal anatomic and pathologic relationships of the CFN in the surrounding area of the fibular neck/head region can be recognized readily and reliably on single axial images. This knowledge assists in the interpretation of the main features of fibular intraneural ganglia and the establishing of their accurate diagnosis (rather than extraneural ganglia) and pathogenesis from an articular origin (rather than from de novo formation). This technique can provide radiologists and surgeons with rapid and reproducible diagnosis and treatment planning. The relative rarity of fibular intraneural cysts and physicians' (radiologists and surgeons) inexperience with them and the complexity of their findings make them frequently misdiagnosed, and joint communications are not appreciated preoperatively or intraoperatively. As a result, outcomes are suboptimal and recurrences are common (39).

Tatagiba and coworkers (47) presented 2 different types of ganglion affecting the peripheral nerves: extraneural and intraneural ganglion. The intraneural ganglion is an uncommon lesion that affects the nerve diffusely, making total removal of all cysts semi-impossible due to the intimate involvement of nerve fascicles within the cysts (30,47). Although still controversial, 2 possibilities are available: the opening of the epineural sheath lengthwise and pressing out the lesion or resection of the affected part of the nerve and performing a nerve reconstruction (47). In contrast, the postoperative clinical evolution of the extraneural ganglion is very favorable. Surgically, a longitudinal incision in the nerve to lay the cyst flat should be made to find and ligature the pedicle that passes by the articular nerve ending of the fibular nerve to avoid recurrence. It is necessary to remove the cyst cautiously and to disconnect it from the nerve endings (30). In 2 cases of compression neuropathy of the CFN caused by an extraneural ganglion, the combination of MRI and ultrasonography was found to be useful for the accurate diagnosis of this condition followed by microsurgical exploration as soon as possible (48).

In a recent retrospective analysis of 22 patients that underwent decompressive surgery of the CFN (49), the pre- and post-operative workup revealed that 74% of

patients (14 out of 19) with motor weakness improved, as did 68% with sensory dysfunction. Sixty-nine percent with foot drop improved to have no foot drop, most of these underwent surgery within 12 months of symptom onset (OR 14.7, 95% CI 1.4 – 133.5). This study concluded that patients with foot drop progressed significantly better if their duration of symptoms before surgery was less than 12 months (49). In another retrospective review of 15 patients (mean age, 32 years) treated with neurolysis, 10, 3, and 2 patients were diagnosed with idiopathic CPN entrapment, indirect nerve injury with CFN paralysis due to an ankle injury, and postural CPN compression, respectively. Mean time to management was 7 months (50). Nine out of 10 patients with idiopathic CPN entrapment syndrome had excellent or good outcomes. Maalla and coworkers study (50) recommended performing surgery between the third and fourth months in patients with persistent symptoms or incomplete recovery, even in forms confined to sensory dysfunction documented by electrophysiological testing. Time to recovery is shorter after surgical decompression than with rehabilitation therapy (50).

The severity and the original cause of the drop foot determine the treatment approach. Treatment for fibular nerve injury (foot drop) could be nonsurgical such as orthotics (braces or foot splints), physical therapy (gait training), or surgical intervention. The surgical approach may be recommended for decompression surgery, nerve sutures, nerve grafting, or nerve transfer or tendon transfer. Surgical fibular nerve decompression for intraneural and extraneural ganglionic cyst is highly recommended following correct diagnosis. Care must be taken to remove the cysts and the articular connections or communications completely (51). The extensive intraneural cysts can be treated successfully by disconnecting the affected articular branch and by resection of the joint of origin, rather than by a more aggressive operation resecting the cyst and cyst wall (42). Recently, the layered "U" technique for fibular intraneural ganglia was used to dissect down in parallel to the U-shaped course of the articular branch to provide optimal visualization and avoid injury to major branches of the nerve (52). This pathoanatomic approach provides direct and safe exposure of the articular branch of the CFN. A study of 9 patients with clinical and radiological diagnosis of a ganglion cyst involving the PTF joint concluded that where there is refractory disease with progressive nerve symptoms and evidence of nerve sheath involvement, joint excision by proximal fibulectomy gives a satisfactory functional result in controlling

disease and preventing further nerve damage (53). The result of the surgical procedure depends on the etiology of the CFN lesion (54).

## CONCLUSIONS

Entrapment neuropathies of the fibular nerve and its branches are often underdiagnosed due to the lack of reliable diagnosis using clinical examination and electrophysiologic evaluation. Most fibular nerve compressions may be classified into 2 broad categories: (a) mechanical causes, which occur at fibrous or fibro-osseous tunnels, and (b) dynamic causes related to nerve injury during specific limb positioning (55). The MRI, including high-resolution and 3D MR neurography, allows detailed assessment of the course and anatomy of peripheral nerves, as well as accurate delineation of surrounding soft-tissue and osseous structures that may contribute to nerve entrapment. Knowledge of

normal MRI anatomy of the nerves in the knee and leg is essential for the precise assessment of the presence of peripheral entrapment conditions that may produce painless or painful drop foot. Complex symptomatic ganglion cysts arising from the PTF joint are not an uncommon presentation in specialist knee clinics and can be managed by aspiration or excision. There is, however, a high rate of recurrence and often there is increasing involvement of the CFN and its branches, and permanent nerve damage may result. These situations can pose substantial diagnostic challenges, owing to both the diversity of symptoms these patients display, along with the anatomic variation that exists between individuals. Precise knowledge of the basic course, the standard motor and sensory distributions of each of the peripheral nerves, and careful use of imaging or electrodiagnostic testing can significantly assist in arriving at a correct diagnosis and treatment (21).

## REFERENCES

- Bozkurt M, Yilmaz E, Atlihan D, Tekdemir I, Havitçiođlu H, Günel I. The proximal tibiofibular joint: An anatomic study. *Clin Orthop Relat Res* 2003; 406:136-140.
- El Gharbawy RM, Skandalakis LJ, Skandalakis JE. Protective mechanisms of the common fibular nerve in and around the fibular tunnel: A new concept. *Clin Anat* 2009; 22:738-746.
- Deutsch A, Wyzkowski RJ, Victoroff BN. Evaluation of the common peroneal nerve. Defining nerve-at-risk in arthroscopically assisted lateral meniscus repair. *Am J Sports Med* 1999; 27:10-15.
- Thompson JC, editor. *Netter's Concise Orthopaedic Anatomy*. 2nd ed. Saunders Elsevier, Philadelphia, 2010, p 336.
- Aono H, Nagamoto Y, Tobimatsu H, Takenaka S, Iwasaki M. Surgical outcomes for painless drop foot due to degenerative lumbar disorders. *Spinal Disord Tech* 2014; 27:E258-E261.
- Robin F, Kuchenbuch M, Sauleau P, Marleix S, Lucas G, Fraisse B, Violas P. Peroneal nerve palsy in children: Uncommon diagnosis of a proximal tibiofibular synovial cyst. *Arch Pediatr* 2015. pii: S0929-693X(15)00382-6. doi: 10.1016/j.arcped.2015.10.005. [Epub ahead of print].
- Gilchrist RV, Bhagia SM, Lenrow DA, Chou LH, Chow D, Slipman CW. Painless foot drop: An atypical etiology of a common presentation. *Pain Physician* 2002; 5:419-421.
- Eleftheriou KI, Beri S, Alavi A, Tennant S. Deep peroneal nerve palsy during growth spurt: A case report. *Eur J Pediatr* 2014; 173:1603-1605.
- Güzelküçük Ü, Skempes D, Kumnerdee W. Common peroneal nerve palsy caused by compression stockings after surgery. *Am J Phys Med Rehabil* 2014; 93:609-611.
- Tan ET, Tan TJ, Poon KB. Entrapment of the deep peroneal nerve and anterior tibial vessels by a spiral tibial fracture causing partial non-union: A case report. *Skeletal Radiol* 2015 [Epub ahead of print].
- Hey HW, Tan TC, Lahiri A, Wilder-Smith EP, Kumar VP, Kagda FH, Lim AY. Deep peroneal nerve entrapment by a spiral fibular fracture: A case report. *J Bone Joint Surg Am* 2011; 5:e113(1-5).
- Girolami M, Galletti S, Montanari G, Mignani G, Schuh R, Ellis S, Di Motta D, D'Apote G, Bevoni R. Common peroneal nerve palsy due to hematoma at the fibular neck. *J Knee Surg* 2013; 26:S132-S135.
- Patel A, Singh R, Johnson B, Smith A. Compression neuropathy of the common peroneal nerve by the fabella. *BMJ Case Rep* 2013. pii: bcr2013202154. doi: 10.1136/bcr-2013-202154.
- Shahid KR, Dellon AL, Amrami KK, Spinner RJ. Sciatic and peroneal nerve injuries after endovascular ablation of lower extremity varicosities: Case reports and review of the literature. *Ann Plast Surg* 2015; 74:64-68.
- de Alvarenga Yoshida R, Yoshida WB, Sardenberg T, Sobreira ML, Rollo HA, Moura R. Fibular nerve injury after small saphenous vein surgery. *Ann Vasc Surg* 2012; 26:e11-e15.
- Kim JY, Kim do K, Yoon SH. Isolated painless foot drop due to cerebral infarction mimicking lumbar radiculopathy: A case report. *Korean J Spine* 2015; 12:210-212.
- Kyavar L, Heckmann JG. Bilateral peroneal palsy after weightlifting. *Clin J Sport Med* 2013; 23:400-402.
- Lucchetta M, Liotta GA, Briani C, Marquez EM, Martinoli C, Coraci D, Padua L. Ultrasound diagnosis of peroneal nerve variant in a child with compressive mononeuropathy. *J Pediatr Surg* 2011; 46:405-407.
- Jones HR Jr, Felice KJ, Gross PT. Pediatric peroneal mononeuropathy: A clinical and electromyographic study. *Muscle*

- Nerve* 1993; 16:1167-1173.
20. Megalopoulos A, Vasiliadis K, Siminas S, Givissis P, Vargiami E, Zafeiriou D, Botsios D, Betsis D. Pseudoaneurysm of the popliteal artery complicated by peroneal mononeuropathy in a 4-year-old child: Report of a case. *Surg Today* 2007; 37:798-801.
  21. Flanigan RM, DiGiovanni BF. Peripheral nerve entrapments of the lower leg, ankle, and foot. *Foot Ankle Clin* 2011; 16:255-274.
  22. Craig A. Entrapment neuropathies of the lower extremity. *PM R* 2013; 5:S31-S40.
  23. Rubin DI, Nottmeier E, Blasser KE, Peterson JJ, Kennelly K. Acute onset of deep peroneal neuropathy during a golf game resulting from a ganglion cyst. *J Clin Neuromuscul Dis* 2004; 6:49-53.
  24. Ozden R, Uruc V, Kalacý A, Dogramacı Y. Compression of common peroneal nerve caused by an extraneural ganglion cyst mimicking intermittent claudication. *J Brachial Plex Peripher Nerve Inj* 2013; 8:5.
  25. Erdil M, Ozkan K, Ozkan FU, Bilsel K, Turkmen I, Senol S, Sarar S. A rare cause of deep peroneal nerve palsy due to compression of synovial cyst - case report. *Int J Surg Case Rep* 2013; 4:515-517.
  26. Lai LP, Chen B, Kumar S, Desai R, Mendoza J, Foye PM, Stitik TP. Ganglion cyst at the fibular head causing common peroneal neuropathy diagnosed with ultrasound and electrodiagnostic examination: A case report. *Am J Phys Med Rehabil* 2014; 93:824-827.
  27. Weyns F, Bringmans T, Vandevenne J, Daenekindt T, Van Goethem A, Wuyts J, Vanormelingen L, Vandersteen M. Peripheral neuropathy caused by joint-related cysts: A review of 17 cases. *Acta Neurochir (Wien)* 2012; 154:1741-1753.
  28. Muramatsu K, Hashimoto T, Tominaga Y, Tamura K, Taguchi T. Unusual peroneal nerve palsy caused by intraneural ganglion cyst: Pathological mechanism and appropriate treatment. *Acta Neurochir (Wien)* 2013; 155:1757-1761.
  29. Nikolopoulos D, Safos G, Sergides N, Safos P. Deep peroneal nerve palsy caused by an extraneural ganglion cyst: A rare case. *Case Rep Orthop* 2015; 2015:861697.
  30. Gayet LE, Morand F, Goujon JM, Pries P, Clarac JP. Compression of the peroneal nerve by a synovial cyst in a 7-year-old child. *Rev Chir Orthop Reparatrice Appar Mot* 1996; 82:762-766.
  31. Ghossain M, Mohasseb G, Dagher F, Ghossain A. Compression of the common peroneal nerve by a synovial cyst. *Neurochirurgie* 1987; 33:412-414.
  32. Gambari PI, Giuliani G, Poppi M, Pozzati E. Ganglionic cysts of the peroneal nerve at the knee: CT and surgical correlation. *J Comput Assist Tomogr* 1990; 14:801-803.
  33. De Schrijver F, Simon JP, De Smet L, Fabry G. Ganglia of the superior tibiofibular joint: Report of three cases and review of the literature. *Acta Orthop Belg* 1998; 64:233-241.
  34. Pagnoux C, Lhotellier L, Marek JJ, Ballard M, Chazerain P, Ziza JM. Synovial cysts of the proximal tibiofibular joint: Three case reports. *Joint Bone Spine* 2002; 69:331-333.
  35. Yazid Bajuri M, Tan BC, Das S, Hassan S, Subanesh S. Compression neuropathy of the common peroneal nerve secondary to a ganglion cyst. *Clin Ter* 2011; 162:549-552.
  36. Spinner RJ, Edwards PK, Amrami KK. Application of three-dimensional rendering in joint-related ganglion cysts. *Clin Anat* 2006; 19:312-322.
  37. Spinner RJ, Desy NM, Amrami KK. Cystic transverse limb of the articular branch: A pathognomonic sign for peroneal intraneural ganglia at the superior tibiofibular joint. *Neurosurgery* 2006; 59:157-166.
  38. Spinner RJ, Mokhtarzadeh A, Schiefer TK, Krishnan KG, Kliot M, Amrami KK. The clinico-anatomic explanation for tibial intraneural ganglion cysts arising from the superior tibiofibular joint. *Skeletal Radiol* 2007; 36:281-292.
  39. Spinner RJ, Luthra G, Desy NM, Anderson ML, Amrami KK. The clock face guide to peroneal intraneural ganglia: Critical "times" and sites for accurate diagnosis. *Skeletal Radiol* 2008; 37:1091-1099.
  40. Shahid KR, Hébert-Blouin MN, Amrami KK, Spinner RJ. Extraneural rupture of intraneural ganglion cysts. *J Surg Orthop Adv* 2011; 20:136-141.
  41. Hébert-Blouin MN, Pirola E, Amrami KK, Wang H, Desy NM, Spinner RJ. An anatomically based imaging sign to detect adventitial cyst derived from the superior tibiofibular joint. *Clin Anat* 2011; 24:893-902.
  42. Spinner RJ, Hébert-Blouin MN, Rock MG, Amrami KK. Extreme intraneural ganglion cysts. *J Neurosurg* 2011; 114:217-224.
  43. Maheshwari AV, Muro-Cacho CA, Temple HT. Aggressive proximal tibiofibular joint ganglion cyst after a total knee arthroplasty: A case report. *Knee* 2008; 15:411-415.
  44. Spinner RJ, Desy NM, Agarwal G, Pawlina W, Kalra M, Amrami KK. Evidence to support that adventitial cysts, analogous to intraneural ganglion cysts, are also joint-connected. *Clin Anat* 2013; 26:267-281.
  45. Prasad NK, Desy NM, Howe BM, Amrami KK, Spinner RJ. Subparaneural ganglion cysts of the fibular and tibial nerves: A new variant of intraneural ganglion cysts. *Clin Anat* 2015. doi: 10.1002/ca.22671. [Epub ahead of print].
  46. Puffer RC, Spinner RJ, Murthy NS, Amrami KK. CT and MR arthrograms demonstrate a consistent communication between the tibiofemoral and superior tibiofibular joints. *Clin Anat* 2013; 26:253-257.
  47. Tatagiba M, Penkert G, Samii M. Ganglia of peripheral nerves. *Zentralbl Neurochir* 1993; 54:171-173.
  48. Rawal A, Ratnam KR, Yin Q, Sinopidis C, Frostick SP. Compression neuropathy of common peroneal nerve caused by an extraneural ganglion: A report of two cases. *Microsurgery* 2004; 24:63-66.
  49. Ramanan M, Chandran KN. Common peroneal nerve decompression. *ANZ J Surg* 2011; 81:707-712.
  50. Maalla R, Youssef M, Ben Lassoued N, Sebai MA, Essadam H. Peroneal nerve entrapment at the fibular head: Outcomes of neurolysis. *Orthop Traumatol Surg Res* 2013; 99:719-722.
  51. Andersen C, Søgård I. Peroneal palsy caused by a ganglion. Compression of the deep peroneal nerve caused by a ganglion cyst. *Ugeskr Laeger* 1990; 152:1598.
  52. Lipinski LJ, Rock MG, Spinner RJ. Peroneal intraneural ganglion cysts at the fibular neck: The layered "U" surgical approach to the articular branch and superior tibiofibular joint. *Acta Neurochir (Wien)* 2015; 157:837-840.
  53. Gulati A, Lechler P, Steffen R, Cosker T, Athanasou N, Whitwell D, Gibbons CL. Surgical treatment of recurrent proximal tibio-fibular joint ganglion cysts. *Knee* 2014; 21:932-9325.

54. Piton C, Fabre T, Lasseur E, André D, Geneste M, Durandeu A. Common fibular nerve lesions. Etiology and treatment. Apropos of 146 cases with surgical treatment. *Rev Chir Orthop Reparatrice Appar Mot* 1997; 83:515-521.
55. Donovan A, Rosenberg ZS, Cavalcanti CF. MR imaging of entrapment neuropathies of the lower extremity. Part 2. The knee, leg, ankle, and foot. *Radiographics* 2010; 30:1001-1019.