

## Case Report



## Complex Regional Pain Syndrome Caused by Lumbar Herniated Intervertebral Disc Disease

Se Hee Kim, MD, Sang Sik Choi, MD, PhD, Mi Kyung Lee, MD, PhD, and Jung Eun Kin, MD, PhD

From: Department of Anesthesiology and Pain Medicine, Korea University Guro Hospital, Seoul, Republic of Korea

Address Correspondence: Sang Sik Choi, MD, PhD  
Department of Anesthesiology and Pain Medicine  
Korea University Guro Hospital, Guro 2-dong, Guro-gu, Seoul, Republic of Korea 152-703  
E-mail: clonidine@empal.com

Disclaimer: There was no external funding in the preparation of this manuscript.

Conflict of interest: Each author certifies that he or she, or a member of his or her immediate family, has no commercial association (i.e., consultancies, stock ownership, equity interest, patent/licensing arrangements, etc.) that might pose a conflict of interest in connection with the submitted manuscript.

Manuscript received: 11-02-2015

Revised manuscript received: 12-20-2015

Accepted for publication: 01-18-2016

Free full manuscript: [www.painphysicianjournal.com](http://www.painphysicianjournal.com)

Most cases of complex regional pain syndrome (CRPS) occur after some inciting injury. There are a few cases of CRPS after an operation for disc disease. CRPS from a mild herniated intervertebral disc (HIVD) without surgical intervention is even rarer than CRPS after an operation for disc disease.

A 22-year-old man was transferred to a pain clinic. He had continuously complained about back and right leg pain. He presented with a skin color change in the right lower leg, intermittent resting tremor, stiffness, and swelling in the right leg. He complained of a pulling sensation and numbness in his right buttock, posterior thigh, lateral calf, and ankle. This symptom was in accordance with L4/5 radiculopathy. Magnetic resonance imaging (MRI) also showed L4/5 HIVD that was central to the bilateral subarticular protrusion.

He was diagnosed as having CRPS, which fits the revised International Association for the Study of Pain (IASP) criteria. He fulfilled 4 symptom categories (allodynia, temperature asymmetry and skin color change, sweating changes, decreased range of motion and motor dysfunction) and 3 of 4 sign categories (allodynia, temperature asymmetry and skin color changes, decreased range of motion and motor dysfunction). The bone scan and thermography also revealed CRPS.

For the past 2 months, we have performed intensive treatments. But, he never became pain-free and walking for 5 minutes led to persistent leg pain. We decided to perform percutaneous nucleoplasty, which can directly decompress a HIVD. On the next day, he achieved dramatic symptom relief. The visual analog scale (VAS) score improved to 3, compared to the VAS score of 9 at the first visit. The skin color change, allodynia, and tremor in the right leg disappeared, and the temperature asymmetry normalized. Motor weakness of the right leg also recovered.

We report an unusual case of CRPS that was caused by L4/5 HIVD without a history of trauma or surgery. It has a clear causal relationship between HIVD and CRPS and definitively fits in the newly revised IASP criteria. In conclusion, mild HIVD can cause CRPS without any trauma. And percutaneous nucleoplasty can be considered as a treatment option.

**Key words:** Complex regional pain syndrome, diagnosis, herniated intervertebral disc, nucleoplasty, radiculopathy, sign, symptom, treatment

**Pain Physician 2016; 19:E901-E904**

**C**omplex regional pain syndrome (CRPS) is a syndrome characterized by continuing, spontaneous, and/or evoked regional pain that is seemingly disproportionate in time or degree to the usual course of any known trauma or other lesion (1). The pain is usually not in a specific nerve territory

or dermatome and has a distal predominance of abnormal sensory, motor, sudomotor, vasomotor, and/or trophic findings (2).

CRPS is a poorly understood pain condition. The cause and pathophysiology of CRPS has not yet been defined. It can occur from various medical conditions.

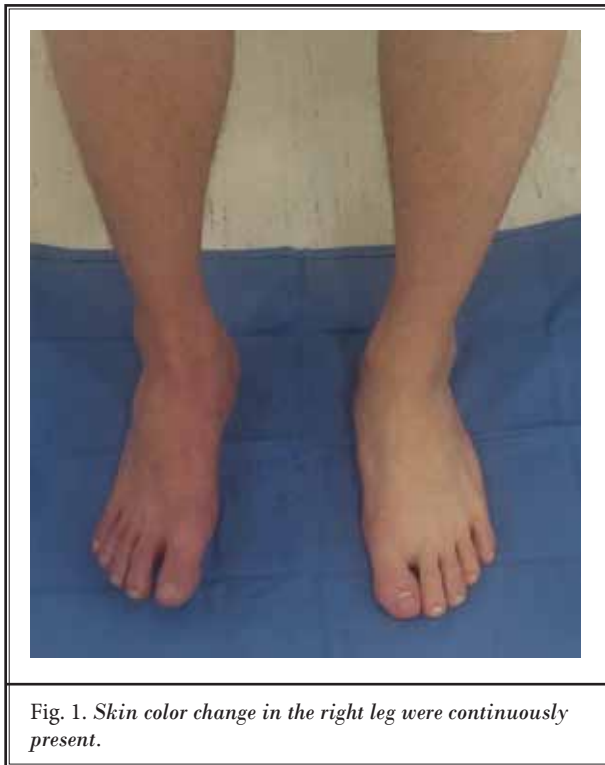

Fig. 1. Skin color change in the right leg were continuously present.

Most cases of CRPS occur after some inciting injury such as sprain, fractures, crush injuries, surgery to a limb, or burns (3,4). However, CRPS can start without any injury or surgery. It can also be triggered by central nervous system damage such as a herniated intervertebral disc (HIVD), spinal cord injury, or stroke. There are few cases of CRPS after an operation for disc disease such as discectomy, artificial disc surgery, and foraminotomy (5,6). CRPS from a mild HIVD without surgical intervention is even rarer than CRPS after an operation for disc disease.

The following report describes an unusual case of CRPS that was caused by L4/5 HIVD without a history of trauma or surgery. It has a clear causal relationship between HIVD and CRPS and fits definitively in the newly revised IASP criteria. We achieved great symptom relief in the patient through percutaneous nucleoplasty.

### CASE REPORT

A 22-year-old man who had severe right leg pain without underlying disease was transferred from rehabilitation medicine to a pain clinic. Severe back pain had begun during training for the army 4 months ago, and radiating pain to the right leg had begun 3 months ago.

He had continuously complained about back and right leg pain. He presented with a skin color change in the right lower leg, intermittent resting tremor, stiffness, and swelling in the right leg on physical examination. During hospitalization in rehabilitation medicine, he had received physical therapy and a nerve root block. Despite these treatments, he had persistently complained of severe back and right leg pain. The medical staff did not find the cause of his severe pain and transferred him to the pain clinic.

When he transferred to the pain clinic, his visual analog scale (VAS) score was 9. He also continuously had a bursting and burning sensation in his right calf. He complained about a pulling sensation and numbness in his right buttock, posterior thigh, lateral calf, and ankle. This symptom was in accordance with L4/5 radiculopathy. Independent walking without a crutch was impossible because of severe leg pain and muscle weakness. At that time, skin color change and intermittent resting tremor in the right leg were continuously present (Fig. 1).

In thermography, the temperature of the right leg was lower than the left leg by more than 1° Celsius. Magnetic resonance imaging (MRI) showed L4/5 HIVD that was central to the bilateral subarticular protrusion. The autonomic nervous system test showed parasympathetic cholinergic dysfunction. The 3-phase bone scan showed decreased asymmetric blood, decreased asymmetric blood pool, and decreased asymmetric uptake in the right lower leg. No specific findings were indicated by electromyography (EMG), sensory evoked potential (SEP), or motor-evoked potential (MEP).

He was diagnosed as having CRPS, which fits the revised IASP criteria (2). He fulfilled 4 symptom categories (allodynia, temperature asymmetry and skin color change, sweating changes, decreased range of motion and motor dysfunction) and 3 of 4 sign categories (allodynia, temperature asymmetry and skin color changes, decreased range of motion and motor dysfunction). The bone scan and thermography also revealed CRPS.

For the past 2 months, we have performed intensive treatments such as medication including narcotics, continuous epidural block, lumbar sympathetic ganglion block (LSGB), alcohol neurolysis, and intrathecal morphine injection. After various treatments, the symptoms showed improvement. The VAS score decreased from 9 to 5, and range of motion was improved. But, he never became pain-free and walking for 5 minutes led to persistent leg pain. We decided to perform percutaneous nucleoplasty, which can directly decompress

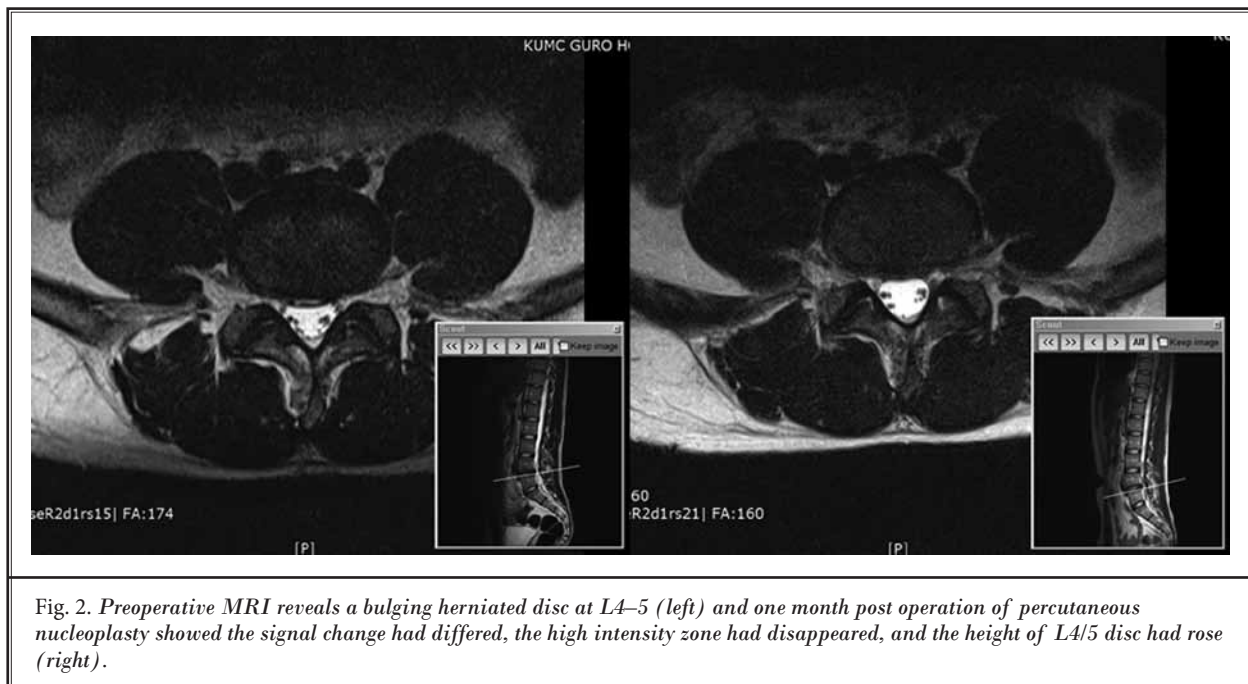


Fig. 2. Preoperative MRI reveals a bulging herniated disc at L4–5 (left) and one month post operation of percutaneous nucleoplasty showed the signal change had differed, the high intensity zone had disappeared, and the height of L4/5 disc had rose (right).

a HIVD (Fig. 2). On the next day, he achieved dramatic symptom relief. The VAS score improved to 3, compared to the VAS score of 9 at the first visit. The skin color change, allodynia, and tremor in the right leg disappeared, and the temperature asymmetry normalized. Motor weakness of the right leg also recovered.

## Discussion

The IASP has recently revised the diagnostic criteria of CRPS. A revised IASP criteria (“Budapest Criteria”) requires the presence of both signs and symptoms of CRPS to make the diagnosis, a change that should reduce false positive diagnoses. The criteria for clinical use are fulfilled if under point 3 more than 2 sign categories are qualified; the criterion for inclusion in scientific studies was if 3 or more sign categories are qualified. The categories include sensory, vasomotor, sudomotor/edema, and motor/trophic (2).

Most CRPS cases involve various precipitating events such as trauma, fractures, tendon injury, or an operation that was performed weeks or months before (7). de Mos et al (8) indicated that patients with CRPS who had a precipitating event accounted for 89.2% of their 238 CRPS patients. The type and range of damage are various, but most CRPS cases have definite causes. Some unusual cases have been reported that developed after a snake bite (9), in association with a malignant peripheral nerve sheath tumor (10), and secondary to

a brachial plexus injury (11). In some cases, CRPS could be initiated by minor trauma or without any specific events such as our patient.

The patient had pain in his right buttock, posterior thigh, lateral calf, and ankle. This finding was in accordance with L4/5 radiculopathy. MRI also showed L4/5 HIVD that was central to the bilateral subarticular protrusion. These findings represented a correlation between CRPS and the HIVD. We strongly suspect that inflammatory mediators or radiating pain caused by HIVD induced CRPS. In addition, a HIVD was detected directly after the onset of symptoms. It is quite evident that the onset of CRPS symptoms and the HIVD occurred at the same time. Judging from achievement of symptom relief by nucleoplasty, we also concluded that HIVD caused CRPS in this patient.

A literature search revealed several old cases of CRPS with HIVD (12-14). However, these reports have some limitations. These reports only described a patient’s symptoms without dividing them into symptoms and signs, and the symptoms did not fit into IASP diagnostic categories. In addition, the causal relationship between the HIVD and CRPS was indefinite. Our case is the first report of CRPS caused by HIVD that clearly fits the IASP diagnostic criteria.

There is a wide spectrum of treatments that range from medications to surgery; however, these treatments may not result in a complete recovery (7). We

also administered early and aggressive treatments such as continuous epidural catheter, lumbar sympathetic ganglion block, alcohol neurolysis, and intrathecal morphine injection; however, the effects were limited. Depending on the size and location of the HIVD, neurologic symptoms and the degree of pain vary from person to person (15). Clinicians must be aware that patients with mild HIVD could complain of severe pain and that it could trigger CRPS.

Percutaneous nucleoplasty is a minimally invasive procedure that aims to decompress a disc lesion without open or endoscopic surgery (16,17). It combines coagulation and tissue ablation to form channels in the nucleus and decompress the herniated disc (18). Shabat et al (19) indicated that patients who underwent nucleoplasty for radicular low back pain had significant pain reduction. In the event that a mild HIVD causes

CRPS, directly removing the cause of the syndrome using percutaneous nucleoplasty could provide significant symptom relief and functional recovery.

## CONCLUSION

In conclusion, mild HIVD can cause CRPS without any trauma. And percutaneous nucleoplasty can be considered as a treatment option for CRPS from HIVD.

## Author Contributions

Sang Sik Choi, M.D., Ph.D., diagnosed this patient and planned various treatments. Mi Kyung Lee, M.D., gave technical support and conceptual advice. And all the procedures were also done by Sang Sik Choi, M.D., Ph.D., Mi Kyung Lee, M.D., Se Hee Kim, M.D., and Jung Eun Kim, M.D.

## REFERENCES

- Harden RN, Bruehl S, Stanton-Hicks M, Wilson PR. Proposed new diagnostic criteria for complex regional pain syndrome. *Pain Med* 2007; 8:326-331.
- Harden RN, Bruehl S, Perez RS, Birklein F, Marinus J, Maihofner C, Lubenow T, Buvanendran A, Mackey S, Graciosa J, Mogilevski M, Ramsden C, Chont M, Vattine JJ. Validation of proposed diagnostic criteria (the "Budapest Criteria") for complex regional pain syndrome. *Pain* 2010; 150:268-274.
- Wasner G, Schattschneider J, Binder A, Baron R. Complex regional pain syndrome--diagnostic, mechanisms, CNS involvement and therapy. *Spinal Cord* 2003; 41:61-75.
- Birklein F. Complex regional pain syndrome. *J Neurol* 2005; 252:131-138.
- Knoeller SM, Ehmer M, Kleinmann B, Wolter T. CRPS I following artificial disc surgery: Case report and review of the literature. *Eur Spine J* 2011; 20:278-283.
- Weisz GM, Houang M, Bogduk N. Complex regional pain syndrome associated with cervical disc protrusion and foraminalotomy. *Pain Med* 2010; 11:1348-1351.
- Harden RN, Oaklander AL, Burton AW, Perez RS, Richardson K, Swan M, Barthel J, Costa B, Graciosa JR. Complex regional pain syndrome: Practical diagnostic and treatment guidelines, 4th edition. *Pain Med* 2013; 14:180-229.
- de Mos M, Sturkenboom MC, Huygen FJ. Current understandings on complex regional pain syndrome. *Pain Pract* 2009; 9:86-99.
- Yong Han Seo, Mi Ran Park, Sie Hyeon Yoo. Development of complex regional pain syndrome after a snake bite: A case report. *Korean J Pain* 2014; 27:68-71.
- Yeong Ho Jeong, Eun Joo Choi, Francis Sahngun Nahm. Concurrence of malignant peripheral nerve sheath tumor at the site of complex regional pain syndrome type 1 - a case report. *Korean J Pain* 2013; 26:160-163.
- Chee Kean Chen, Vui Eng Phui, Abd Jalil Nizar, Sow Nam Yeo. Percutaneous T2 and T3 radiofrequency sympathectomy for complex regional pain syndrome secondary to brachial plexus injury: A case series. *Korean J Pain* 2013; 26:401-405.
- Condon F, Kenny PJ, Griffin JG, O'Rourke K. Reflex sympathetic dystrophy associated with extraforaminal disc herniation at the L5-S1 level. *J Spinal Disord* 1998; 11:448-451.
- Ballard EM, Ellenberg M, Chodoroff G. Reflex sympathetic dystrophy syndrome secondary to L5 radiculopathy. *Arch Phys Med Rehabil* 1991; 72:595-597.
- Bernini PM, Simeone FA. Reflex sympathetic dystrophy associated with low lumbar disc herniation. *Spine* 1981; 6:180-184.
- Bajpai J, Saini S, Singh R. Clinical correlation of magnetic resonance imaging with symptom complex in prolapsed intervertebral disc disease: A cross-sectional double blind analysis. *J Craniovertebr Junction Spine* 2013; 4:16-20.
- Yakovlev A, Tamimi MA, Liang H, Eristavi M. Outcomes of percutaneous disc decompression utilizing nucleoplasty for the treatment of chronic discogenic pain. *Pain Physician* 2007; 10:319-328.
- Cincu R, Lorente Fde A, Gomez J, Eiras J, Agrawal A. One decade follow up after nucleoplasty in the management of degenerative disc disease causing low back pain and radiculopathy. *Asian J Neurosurg* 2015; 10:21-25.
- Manchikanti L, Falco FJ, Benyamin RM, Caraway DL, Deer TR, Singh V, Hameed H, Hirsch JA. An update of the systematic assessment of mechanical lumbar disc decompression with nucleoplasty. *Pain Physician* 2013; 16:25-54.
- Shabat S, David R, Folman Y. Nucleoplasty is effective in reducing both mechanical and radicular low back pain: A prospective study in 87 patients. *J Spinal Disord Tech* 2012; 25:329-332.