

Retrospective Assessment

Elastoplasty: A Silicon Polymer as a New Filling Material for Kyphoplasty in Comparison to PMMA

Rahel Bornemann, MD, Yorck Rommelspacher, MD, Tom R. Jansen MD, Kirsten Sander, PhD, Dieter C. Wirtz, MD, and Robert Pflugmacher, MD

From: Klinik und Poliklinik für Orthopädie und Unfallchirurgie, Universitätsklinikum Bonn, Germany

Address correspondence: Rahel Bornemann, Klinik und Poliklinik für Orthopädie und Unfallchirurgie, Universitätsklinikum Bonn, Sigmund-Freud-Str.25, 53105 Bonn, Germany
E-mail: rahel.bornemann@gmail.com

Disclaimer: There was no external funding in the preparation of this manuscript. Conflict of interest: Each author certifies that he or she, or a member of his or her immediate family, has no commercial association (i.e., consultancies, stock ownership, equity interest, patent/licensing arrangements, etc.) that might pose a conflict of interest in connection with the submitted manuscript.

Manuscript received: 4-30-2015
Revised manuscript received: 6-25-2015
Accepted for publication: 3-15-2016

Free full manuscript: www.painphysicianjournal.com

Background: Painful vertebral compression fractures (VCF) caused by osteoporosis are a common health problem in the elderly population. If conservative treatments are unsuccessful, surgical treatments like vertebroplasty or kyphoplasty are recommended. But the use of Polymethylmethacrylat (PMMA) bone cement for augmentation surgery is associated with risks.

Objectives: Evaluation of the effectiveness and safety of a newly developed silicon polymer (VK100) that can be used instead of PMMA bone cement for kyphoplasty treatments.

Study Design: A retrospective study of 30 patients comparing the outcomes of kyphoplasty treatments conducted with PMMA and VK100.

Setting: Clinic for Orthopedics and Trauma Surgery Bonn, Germany.

Methods: Thirty patients with one to 3 VCF were treated either with balloon kyphoplasty using VK100 or balloon kyphoplasty using PMMA bone cement. Data from both groups was compared by a matched pair analysis. The medial vertebral height was measured at each examination radiologically. The patients stated their pain intensity using the Visual Analogue Scale (VAS) and the patient's functional impairment was evaluated with the Oswestry-Disability-Index (ODI).

All data were assessed before surgery, and 3 days, 3 months, 6 months, and 12 months after surgery. Intraoperative and postoperative adverse events were documented.

Results: The patients' functional impairment and pain improved significantly after surgery. The course of ODI and VAS was comparable in both treatment groups, but the improvement in the VK group was significantly ongoing until the 12 month follow-up. Vertebral height improvement was significant in both groups, but the PMMA group achieved a better absolute restoration. The vertebral height stayed constant during the follow-up in the VK group and worsened significantly in the PMMA group. There was no significant difference between groups concerning the occurrence of additional fractures; and no other types of complications or surgery-related adverse events were observed in either the PMMA group or in the VK group.

Limitations: The study is only a matched pair analysis of 15 patients for each procedure and the amount of injected filling material was not recorded.

Conclusion(s): The study results demonstrate that the clinical outcome of VAS and ODI of using the silicon polymer VK100 is comparable or slightly better than using PMMA. VK 100 shows a trend to minor additional fractures during the follow-up. However, height restoration is not satisfactory in comparison to PMMA, although vertebral height stayed more or less constant in the VK group. To address the augmentation success further, it would be necessary to study a larger patient group over a longer study period and to assess additional parameters such as bone density and injected amount of filling material.

Key words: Vertebral compression fracture, kyphoplasty, augmentation, osteoporosis, back pain, VK 100, elastoplasty

Pain Physician 2016; 19: E885-E892

Painful vertebral compression fractures (VCF) caused by osteoporosis are a common health problem in the elderly population (1). If conservative treatments are unsuccessful in improving the symptoms and patients suffer from persistent pain and limited mobility, surgical interventions such as vertebroplasty or kyphoplasty are often recommended (2,3). Commonly, these treatments were conducted with polymethylmethacrylate (PMMA) bone cement, which is instilled into the vertebrae via different mechanisms (4). Augmentation of the vertebral body with PMMA is highly successful in correction of spinal deformities. This intervention leads to pain reduction and an improved quality of life for the patients (5,6). However, some limitations and risks of PMMA have been reported which vary between different application methods (7,8). PMMA leakage is reported in 4.8 – 39% of balloon kyphoplasty treatments (9) and it is the cause of the most common surgery associated complications. Leakage may lead to soft tissue damage, nerve root pain, and nerve compression, and spinal cord compression (2,6,10). Injuries of the surrounding tissues are mainly caused by high temperatures during the polymerization process of the PMMA and are especially harmful to neural structures. However, most leakage is paraspinal or intradiscal and is primarily asymptomatic (9). But epidural, pulmonary, and foraminal leakage may require immediate surgical interventions. Associated complications such as pulmonary embolism, respiratory and cardiac failure, abdominal intrusions/ileus, and death have been reported (2,6,10,11). In vertebroplasty treatments, intradiscal leakage was identified as a predictor for new vertebral fractures (12). Furthermore, PMMA does not always adhere sufficiently to bone and it is harder and stiffer than natural bone. This may result in a differential spinal load, causing adjacent vertebral fractures. It has been debated whether adjacent fractures are caused by this changed load or primarily by osteoporosis itself (13). Additionally, PMMA has a reduced working time compared to other less viscous alternative augmentation materials. The use of high viscous bone cements may reduce leakage, but the limited working time can complicate the procedure (14). Cement extravasation can be reduced by the use of higher viscosity PMMA and sequential application (14,15). To overcome that problem new types of bone cement have been developed, for example highly viscous cement which has a prolonged working time, due to energy responsiveness and specific application mechanisms like radiofrequency kyphoplasty To

improve application and to reduce extravasations, new delivery techniques have been developed. For example, in radiofrequency targeted augmentation, radioactivated high-viscous bone cement is injected into previously created channels (16,17). In the KIVA VCF treatment system an implant made of PEEK-OPTIMA® is inserted into the vertebra and bone cement is injected into the implant (18). However, complications associated with bone cement still exist. Therefore, in the past few years different kinds of bone cement have been developed. Calcium phosphate cement (CPC) is a bioactive and biodegradable material, which can be resorbed and replaced by bone. However, it has a very low impact resistance and relatively low tensile strength which limits a wide clinical application (19). Furthermore, calcium sulfate cement (CSC) has been developed. It has a higher strength but degrades much faster as CPC (20). Therefore The manufacturer Bonwrx (Phoenix, AZ, USA) developed a silicon filling material named VK100. VK100 is biocompatible, biodegradable, non-exothermic, and more elastic than bone cement. It is a radio-opaque silicon polymer, which sticks to itself and adheres to bone. Furthermore, its viscosity increases gradually, resulting in a longer working time. The viscosity of bone cement is a significant parameter for leakage (21). An optimal viscosity of PMMA is approximately 4.3 minutes at room temperature (22) compared to approximately 15 minutes of working time for VK100. For VK100 the ambient temperature is important, because the working time is strongly dependent on the temperature which can extend or diminish the viscosity and working time, respectively. Eichler et al (23) detected an obvious working curve for identifying the correct working viscosity and achieving reduced leakage rates.

To assess the treatment results for balloon kyphoplasty (BKP) performed with VK100, a comparison to BKP using PMMA was conducted.

METHODOLOGY

Patients

All patients suffered from fresh acute osteoporotic VCFs of one to three vertebrae which were assessed diagnosed by preoperative magnetic resonance imaging (MRI). The vertebrae showed a decreased vertebral height of at least 5% and the fracture was categorized as A1.1, A1.2, or A1.3. After being treated conservatively, all patients had a pain value higher than 70 measured at by visual analogue scale (VAS) after 2 – 6 weeks of treatment, or a VAS > 50 after more than 6 weeks

of conservative therapy. Additionally, the functional impairment (Oswestry-Disability Index) was higher than 30%. Patients fulfilling one or more of the following criteria were excluded:

- less than 18 years old
- a shorter life expectancy than the study period
- affected by a traumatic, osteonecrotic, or tumor related fracture
- a BMI of more than 35
- cancer or HIV patient
- alcohol or drug abuser
- pregnant women, or women planning a pregnancy within the study period
- has an infection
- has an allergy or an intolerance to the surgical instruments and materials
- has had past spinal surgeries at the affected level or spinal stenoses or compressions of the neuroforamen or nerve root
- systemic diseases
- long time chronic steroid therapy (> 30 mg/d for > 3 months)
- hemorrhagic diathesis
- uncontrolled psychiatric diseases or dementia

Intervention

Augmentation surgery was either performed with balloon kyphoplasty BKP (Kyphon Inc., Sunnyvale, California, USA) using VK100 (Bonwrx, Phoenix, AZ, USA) as filling material (VK group) or BKP using PMMA (PMMA group).

Patients in the PMMA group were treated in the university hospital Bonn between 2009 and 2012 and patients in the VK group between 2011 and 2013.

Measurements

All study procedures were conducted in accordance with the ethical principles as stated in the Declaration of Helsinki. Patients underwent 5 examinations. Prior to the surgery, a complete physical examination was conducted, including radiological examinations/MRIs in order to confirm the presence, location, and severity of the VCF. Furthermore, medial the average vertebral height was measured radiologically by measuring the anterior and medial height of the vertebrae and calculating the mean height. Patients stated their pain intensity using the 100 mm VAS) and the patient's functional impairment was evaluated with the Oswestry Disability Index (ODI).

Follow-up examinations took place 3 days post-op-

erative and 3 months, 6 months, and 12 months after surgery. At all examinations ODI, VAS, and vertebral height were assessed. Intraoperative and post-operative adverse events were documented. A computed tomography (CT) scan for leakage evaluation was omitted due to high radiation exposure and because of conclusions of past studies which stated found that a post-procedural CT scan is not warranted and should be conducted only for clinically symptomatic patients (24).

Statistical Analysis

A matched pairs analysis was conducted to compare the outcomes of both treatment groups. Defined criteria for matched pairs were affected number of levels, gender, age \pm 9 years, and the level of effect as similar as possible.

Data were analyzed using the statistic program PSPP (GPL version 3).

All data were reported as mean \pm standard deviation and the level of statistical significance was set to $P = 0.05$ (CI 95%). To analyze changes within groups and to conduct the matched pairs analysis, the paired Wilcoxon rang test was used. Comparison of adverse events such as occurred leakage and additional fractures was done with the Fisher's Exact Test.

RESULTS

Thirty patients were analyzed; 15 from the VK group and 15 from the PMMA group. Patients' characteristics of both groups are summarized in Table 1.

A radiological illustration of the postoperative comparison of both procedures is given in figure 1. Figure 1 demonstrates post-operative anterior-posterior and lateral radiographs comparing both procedures.

Both treatment groups showed an improved VAS score directly after surgery with a reduction from 89.3 ± 11 mm to 28 ± 7.7 mm ($P < 0.001$) in the PMMA group and 83.5 ± 10.1 mm to 18.9 ± 11 mm ($P < 0.001$) in the VK group, respectively. The PMMA group showed a further slight improvement from the 3days examination third post-operative day to 22.5 ± 12.2 mm at 12 months ($P = 0.07$). The VK group showed a further significant reduction of VAS to 9.4 ± 11.3 mm at 12 months ($P = 0.007$).

The ODI course was comparable to the VAS course in both treatment groups. Both groups showed a significantly improved ODI 3 days after the surgery with a reduction from 83.5 ± 7.9 to $39.9 \pm 3.4\%$ ($P < 0.001$) in the PMMA group and from $45.7 \pm 16\%$ ($P < 0.001$) in the VK group, respectively. In At the 12 month follow-

Table 1. Patients' characteristics of both treatment groups.

| | VK group | PMMA group |
|--|---|---|
| Age | 72.93 ± 7.27 years | 71.87 ± 6.93 years |
| Gender | 8 females 7 males | 8 females 7 males |
| Number of affected vertebrae | 1 (n = 8) 2 (n = 5) 3 (n = 2) | 1 (n = 8) 2 (n = 5) 3 (n = 2) |
| Level and average height of affected vertebrae | T7 (n = 2) (preoperative: 25.0 ± 1.0 mm; postoperative: 25.0 ± 1.0 mm) T8 (n = 1) (preoperative: 20.0 ± 0.0 mm; postoperative: 20.0 ± 0.0 mm) T9 (n = 2) (preoperative: 22.5 ± 0.5 mm; postoperative: 23.0 ± 1.0 mm) T10 (n = 2) (preoperative: 19.0 ± 1.0 mm; postoperative: 19.5 ± 1.5 mm) T11 (n = 2) (preoperative: 19.5 ± 0.5 mm; postoperative: 20.0 ± 1.0 mm) T12 (n = 2) (preoperative: 23.5 ± 1.5 mm; postoperative: 23.5 ± 1.5 mm) L1 (n = 3) (preoperative: 19.3 ± 1.2 mm; postoperative: 19.7 ± 1.7 mm) L2 (n = 3) (preoperative: 21.7 ± 3.3 mm; postoperative: 21.7 ± 3.3 mm) L3 (n = 3) (preoperative: 22.7 ± 0.9 mm; postoperative: 22.7 ± 0.9 mm) L4 (n = 2) (preoperative: 22.0 ± 0.0 mm; postoperative: 22.0 ± 0.0 mm) L5 (n = 2) (preoperative: 24.0 ± 1.0 mm; postoperative: 24.0 ± 1.0 mm) | T5 (n = 1) (preoperative: 20 ± 0.0 mm; postoperative: 24 ± 0.0 mm) T9 (n = 1) (preoperative: 18 ± 0.0 mm; postoperative: 22 ± 0.0 mm) T10 (n = 4) (preoperative: 20.3 ± 1.3 mm; postoperative: 23.8 ± 1.9 mm) T11 (n = 3) (preoperative: 22.3 ± 3.9 mm; postoperative: 24.7 ± 0.9 mm) T12 (n = 2) (preoperative: 25.5 ± 2.5 mm; postoperative: 27.0 ± 1.0 mm) L1 (n = 4) (preoperative: 24.3 ± 1.9 mm; postoperative: 26.3 ± 0.8 mm) L2 (n = 5) (preoperative: 23.4 ± 1.2 mm; postoperative: 27.8 ± 1.0 mm) L3 (n = 2) (preoperative: 23.0 ± 2.0 mm; postoperative: 26.5 ± 0.5 mm) L4 (n = 1) (preoperative: 22.0 ± 1.0 mm; postoperative: 22.0 ± 1.0 mm) L5 (n = 1) (preoperative: 22.0 ± 0.0 mm; postoperative: 24.0 ± 0.0 mm) |

up the PMMA group showed a more or less equal an almost equivalent ODI as identified in at the 3days examination third post-operative day with $37.4 \pm 5.4\%$ ($P = 0.09$). In the VK group, however, the ODI was significantly improved to $20.2 \pm 7.1\%$ from the third post-operative day to the 12 month examination ($P = 0.001$).

Vertebral height improved significantly in both groups after the surgery, from 22.6 ± 2.8 mm to 25.71 ± 2.03 mm ($P < 0.001$) in the PMMA group and from 21.74 ± 2.5 mm to 21.9 ± 2.48 mm ($P = 0.045$) in the VK group. In the follow-up examination, the vertebral height worsened significantly in the PMMA group to 25.22 ± 2.04 mm ($P = 0.005$). In the VK group the vertebral

height stayed more or less stable during the follow-up period with 21.8 ± 2.6 mm at the 12 month examination ($P = 0.083$). Both groups showed a significantly improved height compared to the initial vertebral height, but the increase was significantly better in the PMMA group ($P < 0.001$).

Leakage was observed in 6.7% ($n = 1$) of the patients in the PMMA group and in 13.3% ($n = 2$) of patients in the VK group, such that no significant difference was given between both groups ($P = 0.5$).

Adjacent fractures occurred in 33.3% ($n = 5$) of patients in the PMMA group and in 6.7% ($n = 1$) of patients of the VK group. Although there was a significant

clinical difference between groups, no statistically significant difference was observed between groups concerning the occurrence of additional adjacent fractures ($P = 0.08$).

No other types of complications or surgery-related adverse events were observed in either the PMMA group or in the VK group.

Discussion

Elastoplasty is a new development of kyphoplasty, which uses a silicon polymer instead of PMMA as filling material for overcoming PMMA related complications. The VK100 is assumed to act more similarly to natural bone than PMMA because its stiffness is considerably lower than the stiffness of PMMA. Furthermore, the composition of VK100 may reduce the rate of surgery or device-related adverse events. VK100 cures non-exothermally at body temperature, it adheres to bone and sticks to itself, and the silicon polymers cannot be degraded by body substances except for gastric acid.

Our study compared the use of the silicon polymer VK100 and PMMA as filling materials for augmentation of VCFs.

Both materials lead to an improvement in vertebral height. However, the height restoration was greater using PMMA compared to VK100. But post-operative vertebral height was more or less constant in VK patients. PMMA patients showed a significant height reduction during the post-operative study period. Differences are possibly caused by material stiffness which lead to different spinal loads affecting the vertebral structure. Zhao et al (25) concluded that the long-term sustainability of height restoration is less likely in those patients who experienced a greater restored vertebral height, but further investigations are necessary to clarify the causes. Furthermore, reachable height restoration depends on many influencing factors, like bone mineral density, preoperative kyphosis angle, and fracture age (26). The lower viscosity of VK100 in comparison to PMMA could possibly lead to a more careful injection into the vertebrae to avoid

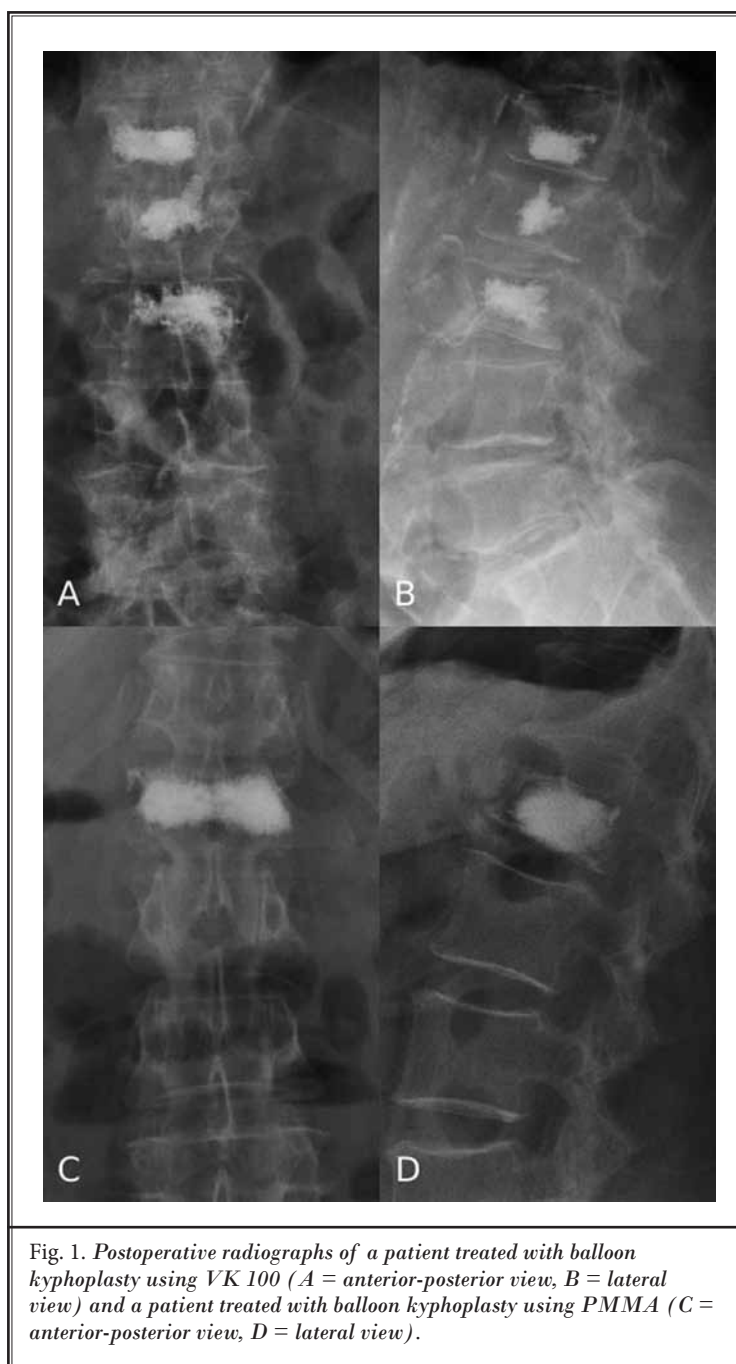


Fig. 1. Postoperative radiographs of a patient treated with balloon kyphoplasty using VK 100 (A = anterior-posterior view, B = lateral view) and a patient treated with balloon kyphoplasty using PMMA (C = anterior-posterior view, D = lateral view).

leakage, which may result in a smaller injected amount of material. A smaller amount could be possibly not sufficient to reach an adequate increased height. Unfortunately, we did not document the amount of injected VK100 and PMMA, but leakage was not significantly different in both treatment groups. In another retrospective study using VK100 as filling material, the authors made similar observations. It was identified that the occurred

leakage in VK100 treatment was essentially higher within the first 30 treated patients and that the key to reduced leakage is employing the correct waiting time for reaching injection viscosity (23). All occurred leakages occurrences were asymptomatic, but the patient groups were small in the conducted study and further investigations are necessary to verify the comparable results for PMMA and VK100. It is conceivable that there will be a positive effect of the VK100 in comparison to PMMA regarding exothermic damage of neural structures, because VK100 reacts non-exothermically and cures rapidly at body temperature whereas PMMA polymerizes exothermically.

During the exothermic polymerization of PMMA, temperatures increase to 82°C – 86°C in the vertebrae (27). It has been shown that tissues are seriously impacted from a temperature of 50° onwards (28). It is still under discussion whether the PMMA-kyphoplasty itself leads to pain relief, or whether the heat of polymerization destroys the pain fibers. Ex-vivo studies of vertebroplasty treatments showed controversial results and the influence of thermal injury on pain reduction is still unsolved. This is also because of model limitations and missing in-vivo studies (29). A pain reducing effect caused by thermic destroyed pain fibers is out of the question using VK100, because of its non-exothermic performance.

Furthermore, VK100 sticks to the bone and itself which may decrease embolizations and symptomatic leakages. The clinical outcome of VAS and ODI development is nearly equal in both treatment groups with the VK-group showing. However, the VK group showed a further significant post-operative improvement during the follow-up, slightly better results, because of a postoperative constant significant improvement. Other studies showed have shown comparable improvements for PMMA usage (6). In Eicheler et al (23), the VAS improved after VK100 treatment, which slightly worsened by the 3 month examination with no remarkable change afterward; the ODI was reduced significantly after treatment but did not change significantly between follow-up examinations. The ability to restore vertebral height with VK100 treatment was not documented by Eicheler et al (23). The restoration of vertebral height shows no direct correlation to pain relief (30). It is possible that pain relief and improvements of functional impairment are not only solely results of height restoration, but are caused mainly by the stabilization of the vertebra.

It seems to be an advantage of VK100, that the silicon polymer distributes deeper into the trabecular bone and adheres to bone. PMMA may not allocate as finely as VK100, because of the higher viscosity. Furthermore, PMMA does not adhere to bone (21) and in other studies a gap between PMMA and bone was observed (19). It may be possible that the less stiff VK100 does not upset the spinal load as PMMA has been observed to do, which may lead to a more positive effect of stabilization. It could be also an explanation for less occurred additional fractures in the VK100 group. Other studies assumed that the distribution of bone cement as peripheral interdigitation may lead to less additional fractures, because of a more uniform load transfer between vertebral endplates (22). The more uniform load transfer could be achieved by VK100, because of its bone like stiffness.

However, additional adverse events associated with PMMA were also reported for VK100 usage, especially in terms of pulmonary embolism (23). Besides the reported leakage and additional fractures, no adverse events occurred in our study, either in the PMMA group or in the VK-group.

The inspissation of VK100 deep into the trabecular bone in combination with the bone bonding qualities of VK100 are advantages not afforded to PMMA since PMMA does not adhere to bone (28). In studies, a gap between PMMA and native bone has been observed (23). It is possible that the reduced stiffness of VK100 does not disrupt the spinal load to the same degree as PMMA. This may lead to a more uniform effect of stabilization. The reduction in stiffness could also explain the reduced incidence of additional fractures in the VK group compared to the PMMA group. Studies have also attributed a decrease in the number of additional fractures in the VK group to its peripheral inspissation which reduces vertebral body stiffness. Other studies suggest that peripheral inspissation and more uniform distribution of VK100 reduces the number of additional fractures by producing a uniform load transfer between vertebral endplates (31). The similarity in stiffness of VK100 and of native bone could explain this uniform load transfer.

Despite reported adverse events such as pulmonary embolism occurring with both VK100 and PMMA (32), we had no additional adverse events except for the reported leakage and additional fractures in either the PMMA or VK group.

CONCLUSION

The study results demonstrate indicate that the use of VK100 leads to a clinical outcome of reduction in VAS and ODI comparable to or slightly better to than PMMA usage, probably with minor additional fracture occurrence. Both treatments lead to significantly improved vertebral heights. However height restoration

of VK100 is not satisfactory when compared to PMMA usage after 12 months. The VK group showed a worse height restoration, but a more stable height over the follow-up period. To address the augmentation success further, it would be necessary to study a larger patient group over a longer study period and to assess additional parameters such as bone density and injected amount of filling material.

REFERENCES

- Kanis JA, Pitt FA. Epidemiology of osteoporosis. *Bone* 2005; 13:7-15.
- Garfin SR, Yuan HA, Reiley MA. New technologies in spine: Kyphoplasty and vertebroplasty for the treatment of painful osteoporotic compression fractures. *Spine* 2001; 26:1511-1515.
- Bornemann R, Hanna M, Kabir K, Goost H, Wirtz DC, Pflugmacher R. Continuing conservative care versus crossover to radiofrequency kyphoplasty: A comparative effectiveness study on the treatment of vertebral body fractures. *Eur Spine J* 2012; 21:930-936.
- Robinson Y, Heyde CE, Försth P, Olerud C. Kyphoplasty in osteoporotic vertebral compression fractures – guidelines and technical considerations. *J Orthop Surg Res* 2011; 6:43.
- Hulme PA, Krebs J, Ferguson SJ, Berlemann U. Vertebroplasty and kyphoplasty: A systematic review of 69 clinical studies. *Spine (Phila Pa 1976)* 2006; 31:1983-2001.
- Papanastassiou ID, Phillips FM, Meirhaeghe JV, Berenson JR, Anderson GBR, Chung G, Small BJ, Aghayev K, Vrionis FD. Comparing effects of kyphoplasty, vertebroplasty, and non-surgical management in a systematic review of randomized and non-randomized controlled studies. *Eur Spine J* 2012; 21:1826-1843.
- Bornemann R, Koch EMW, Wollny M, Pflugmacher R. Treatment options for vertebral fractures an overview of different philosophies and techniques for vertebral augmentation. *Ejost* 2014; 24:131-143.
- Alexandru D, So W. Evaluation and management of vertebral compression fractures. *Perm J* 2012; 16:46-51.
- Ruiz Santiago F, Santiago Chinchilla A, Guzmán Álvarez L, Pérez Abela AL, Castellano García Mdel M, Pajares López M. Comparative review of vertebroplasty and kyphoplasty. *World J Radiol* 2014; 6:329-343.
- Burton AW, Rhines LD, Mendel E. Vertebroplasty and kyphoplasty: A comprehensive review. *Neurosurg Focus* 2005; 18:E1.
- Robinson Y, Tschöke SK, Stahel PF, Kayser R, Heyde CE. Complications and safety aspects of kyphoplasty for osteoporotic vertebral fractures: A prospective follow-up study in 102 consecutive patients. *Patient Saf Surg* 2008; 2:2.
- Komemushi A, Tanigawa N, Kariya S, Kojima H, Shomura Y, Komemushi S, Sawada S. Percutaneous vertebroplasty for osteoporotic compression fracture: Multivariate study of predictors of new vertebral body fracture. *Cardiovasc Intervent Radiol* 2006; 29:580-585.
- Zou J, Mei X, Zhu X, Shi Q, Yang H. The long-term incidence of subsequent vertebral body fracture after vertebral augmentation therapy: A systematic review and meta-analysis. *Pain Physician* 2012; 15:E515-E522.
- Lador R, Liberman S, Ben-Galim P, Dreinagel N, Reitman CA, Hipp JA. A cadaver study to vertebral augmentation with high-viscosity cement to augmentation with conventional lower-viscosity cement. *J Spinal Disord Tech* 2013; 26:68-73.
- Hoppe S, Wangler S, Aghayev E, Gantenbein B, Boger A, Benneker LM. Reduction of cement leakage by sequential PMMA application in a vertebroplasty model. *Eur Spine J* 2015; (EPub ahead of Print).
- Elgeti FA, Marnitz T, Kröncke TJ, Gebauer B. DFine Radiofrequenzkyphoplastie (RFK) – Kyphoplastie mit ultrahochviskösem Zement. *Rofö* 2010; 182:803-805.
- Georgy BA. Comparison between radiofrequency targeted vertebral augmentation and balloon kyphoplasty in the treatment of vertebral compression fractures: Addressing factors that affect extravasation and distribution. *Pain Physician* 2013; 16:E513-E518
- Otten LA, Bornemann R, Jansen TR, Kabir K, Pennekamp PH, Wirtz DC, Stuwe B, Pflugmacher R. Comparison of balloon kyphoplasty with the new KIVA® VCF system for the treatment of vertebral compression fractures. *Pain Physician* 2013; 16:E505-E512.
- Ambard AJ, Mueninghoff L. Calcium phosphate cement: Review of mechanical and biological properties. *Journal of Prosthodontics* 2006; 15: 321-328.
- Zhou W, Xue Y, Ji X, Yin G, Zhang N, Ren Y. A novel injectable and degradable calcium phosphate/calcium sulfate bone cement. *African Journal of Biotechnology* 2011; 10:19449-19457.
- Giannitsios D, Ferguson S, Heini P, Baroud G, Steffen T. High cement viscosity reduces leakage risk in vertebroplasty. *European Cells and Materials* 2005; 10:54.
- Boger A, Wheeler KD, Schenk B, Heini PF. Clinical investigations of polymethylmethacrylate cement viscosity during vertebroplasty and related in vitro measurements. *Eur Spine J* 2009; 18:1272-1278.
- Eichler MK, Göktas V, Hölper M, Joechel P. Clinical evaluation of elastoplasty, a percutaneous augmentation of vertebral compression fractures with an elastic silicon-based polymer. *J Spine Surg* 2013; 1:80-85.
- Zhi L, Caifang N, Long C, Zhiyong S, Chao Y, Xin Z, Yanwei W. Kyphoplasty versus vertebroplasty for the treatment of malignant vertebral compression fractures caused by metastases: A ret-

- rospective study. *Chinese Medical Journal* 2014; 127:1493-1496.
25. Zhao Y-L, Yang H-L, Konrad J, Liu J, Moral M, Xu Y-Z, Geng D-C, Ebraheim NA. Kyphoplasty does not maintain all restored height post-operatively: A prospective, comparative study. *Orthopedics* 2010; 33: doi: 10.3928/01477447-20100625-03.
 26. Shen M, Wang H, Chen G, Gan M, Yuan Q, Wang Z, Liu L, Yang H. Factors affecting kyphotic angle reduction in osteoporotic vertebral compression fractures with kyphoplasty. *Orthopedics* 2013; 36:e509-e514.
 27. Vaishya R, Chauhan M, Vaish A. Bone cement. *J Clin Orthop Trauma* 2013; 4:157-163.
 28. Provenzano MJ, Murphy KPJ, Riley III LH. Bone cements: Review of their physiochemical and biomechanical properties in percutaneous vertebroplasty. *Am J Neuroradiol* 2004; 25:1286-1290.
 29. Belkoff SM. Biomechanics of vertebroplasty. In: Lewandrowski K-U, Wise D, Trantolo DJ, Yeszemeski MJ, White III AA (eds). *Advances in Spinal fusion: Molecular Science, Biomechanics, and Clinical Management*. Marcel Dekker Inc., New York, 2004, pp 23-32.
 30. Röllinghoff M, Hagel A, Siewe J, Gutteck N, Delnak KS, Steinmetz A, Zarghooni K. Ist eine Höhenrekonstruktion mit vergleichsweise wenig Zement für die Radiofrequenz-Kyphoplastie über einen monopedikulären Zugang möglich? *Z Orthop Unfall* 2013; 151:156-162.
 31. Bornemann R, Jansen TR, Kabir K, Pennekamp PH, Stüwe B, Wirtz DC, Pflugmacher R. Comparison of radiofrequency-targeted vertebral augmentation with balloon kyphoplasty for the treatment of vertebral compression fractures: 2-year results. *J Spinal Disord Tech* 2013; [Epub ahead of print].
 32. Uurlings TAJ, van der Linden E. Elastoplasty: First experience in 12pPatients. *Cardiovasc Intervent Radiol*, 2013; 36:479-483.